

# The Role of Podocalyxin in Health and Disease

Julie S. Nielsen\* and Kelly M. McNagy†

\*Trev & Joyce Deeley Research Centre, British Columbia Cancer Agency, Victoria and †The Biomedical Research Centre, University of British Columbia, Vancouver, British Columbia, Canada

## ABSTRACT

Podocalyxin, a sialomucin most closely related to CD34 and endoglycan, is expressed by kidney podocytes, hematopoietic progenitors, vascular endothelia, and a subset of neurons; aberrant expression has recently been implicated in a range of cancers. Through interactions with several intracellular proteins and at least one extracellular ligand, podocalyxin regulates both adhesion and cell morphology. In the developing kidney, podocalyxin plays an essential role in the formation and maintenance of podocyte foot processes, and its absence results in perinatal lethality. Podocalyxin expression in the hematopoietic system correlates with cell migration and the seeding of new hematopoietic tissues. In addition, it is abnormally expressed in subsets of breast, prostate, liver, pancreatic, and kidney cancer as well as leukemia. Strikingly, it is often associated with the most aggressive cases, and it is likely involved in metastasis. Thus, a thorough investigation of the normal activities of podocalyxin may facilitate the development of new cancer treatment strategies.

*J Am Soc Nephrol* 20: 1669–1676, 2009. doi: 10.1681/ASN.2008070782

Podocalyxin is an extensively O-glycosylated and sialylated type I transmembrane protein that is implicated in a wide range of cancers and is normally expressed in kidney podocytes, hematopoietic progenitor cells, vascular endothelia, and a subset of neurons (Figure 1).<sup>1–18</sup> Podocalyxin's C-terminal PDZ-binding motif, DTHL,<sup>2,5,6</sup> facilitates interactions with Na<sup>+</sup>/H<sup>+</sup> exchanger regulatory factor 1 (NHERF1) and NHERF2.<sup>19–21</sup> These two adaptor proteins form complexes with a multitude of proteins and are implicated in protein trafficking, ion transport, and signaling.<sup>22–25</sup> Podocalyxin also associates with the actin-binding protein ezrin.<sup>3,26</sup> Thus, podocalyxin likely affects a variety of important cellular functions through its association with NHERF proteins, ezrin, and the actin cytoskeleton.

Podocalyxin is most closely related to the hematopoietic stem cell marker

CD34 and the recently discovered sialomucin, endoglycan.<sup>2,27,28</sup> These proteins have similar protein and gene structures and partially overlapping expression patterns.<sup>28,29</sup> Although CD34 has been extensively studied, its function is still not entirely clear. In specialized lymph node endothelial cells, called high endothelial venules, modified forms of CD34 and podocalyxin act as adhesive ligands for L-selectin on circulating lymphocytes and thereby regulate cell trafficking<sup>8,30</sup>; however, in most other situations, CD34 and its relatives seem to act in the opposite capacity, as regulated blockers of adhesion. For example, in the hematopoietic system, they facilitate cell migration and prevent nonspecific adhesion.<sup>11,31,32</sup>

Interestingly, we also defined a novel role for podocalyxin in establishing cell morphology.<sup>33</sup> When expressed ectopically in breast or kidney epithelial cells, podocalyxin dramatically increases mi-

crovillus formation (Figure 2A).<sup>33</sup> This is dependent on indirect association of podocalyxin with the actin cytoskeleton, because disruption of actin polymerization abolishes the phenotype.<sup>33</sup> Similarly, blocking podocalyxin expression prevents tubule formation in a kidney tubulogenesis model.<sup>34</sup> Moreover, podocalyxin is essential for extension of foot processes in kidney podocytes (discussed in the Podocalyxin in the Developing Kidney section).<sup>2</sup> Thus, mounting evidence suggests a role for podocalyxin in cellular morphogenesis. Here we outline the normal activities of podocalyxin and describe how its dysregulation facilitates malignant behavior of tumor cells.

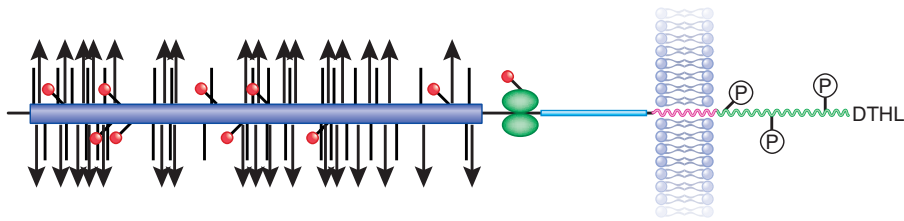
## DIVERSE ROLES OF PODOCALYXIN IN A VARIETY OF TISSUES

Podocalyxin was initially identified in kidney glomeruli, where it is not only abundant but also essential for kidney development.<sup>1,2</sup> In addition, it is found in all three germ layers during embryogenesis, as well as hematopoietic progenitors, megakaryocytes and platelets, vascular endothelia, mesothelial cells lining organs, and a subset of neurons.<sup>2,6,9,12,14</sup>

Published online ahead of print. Publication date available at [www.jasn.org](http://www.jasn.org).

**Correspondence:** Dr. Kelly M. McNagy, The Biomedical Research Centre, 2222 Health Sciences Mall, Vancouver, British Columbia, V6T 1Z3 Canada. Phone: 604-822-7824; Fax: 604-822-7815; E-mail: [kelly@brc.ubc.ca](mailto:kelly@brc.ubc.ca)

Copyright © 2009 by the American Society of Nephrology



**Figure 1.** Podocalyxin's structure. Podocalyxin has an extensively O-glycosylated (vertical lines) and sialylated (triangles) extracellular mucin domain (purple), several sites of N-glycosylation (red circles), and a cysteine-containing globular domain (green). This is followed by a juxtamembrane stalk (blue), a single-pass transmembrane domain (pink), and an intracellular domain (green) with putative phosphorylation sites and a C-terminal DTHL sequence for interaction with PDZ domains.

### Podocalyxin in the Developing Kidney

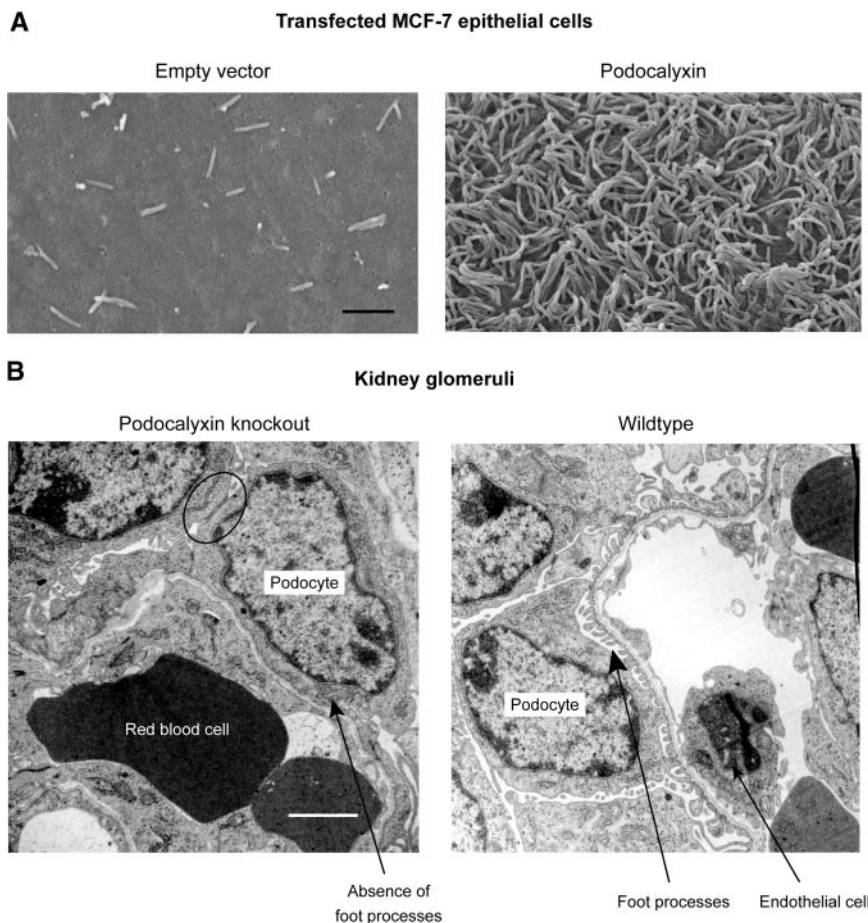
Kidney glomeruli, responsible for filtration and urine formation, include capillary loops, a glomerular basement membrane,

and epithelial cells called podocytes.<sup>35</sup> Podocytes display an unusual architecture consisting of a cell body, major processes extending around capillary loops, and actin-rich interdigitating foot processes (Fig-

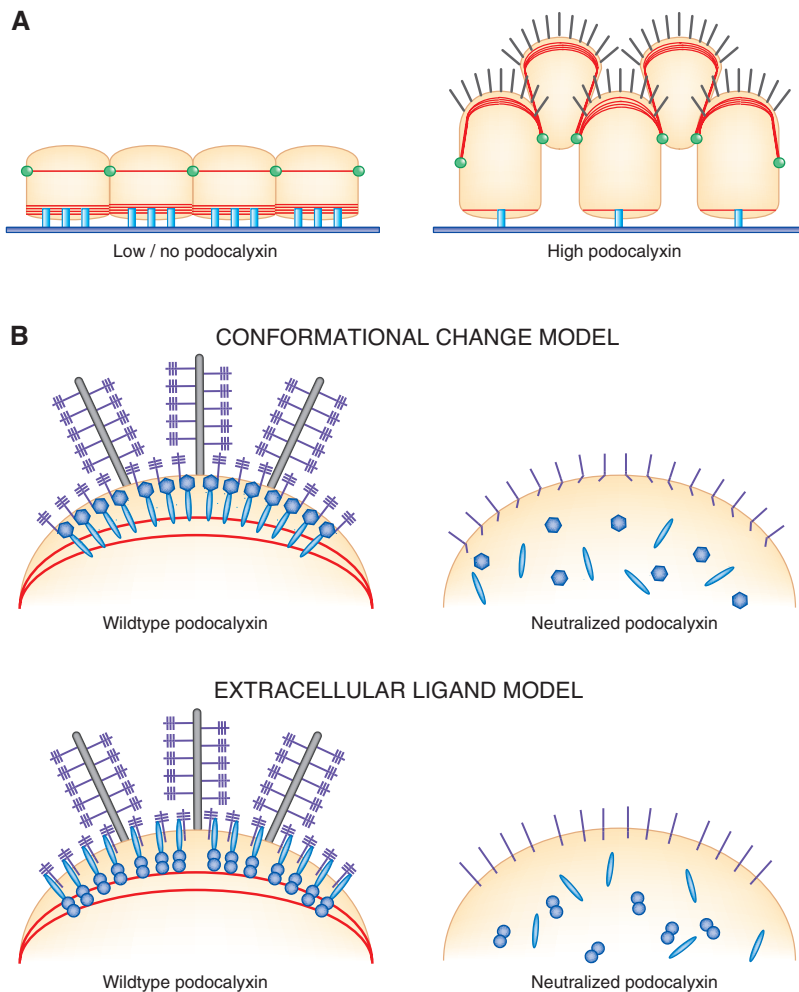
ure 2B).<sup>36,37</sup> The apical surface of podocytes, which faces the urinary space, is coated by a sialic acid-rich glycocalyx that is designated the epithelial polyanion and is composed mainly of podocalyxin.<sup>1,38</sup>

Glomerular development proceeds through a series of stages.<sup>39,40</sup> The initial steps involve formation of mesangial cells, glomerular epithelial cells (podocytes), proximal tubule cells, and capillary endothelium. Podocytes then proliferate, and junctional proteins migrate from apical surfaces basolaterally toward the glomerular basement membrane.<sup>40</sup> Extensive morphologic rearrangements whereby foot processes extend and junctions redistribute between foot processes subsequently occur; junctions are later replaced by slit diaphragms.<sup>40,41</sup> Podocalyxin first appears just before formation of foot processes and slit pores, and its redistribution correlates with that of junctions: It is expressed as junctional proteins migrate basolaterally and is always found along the apical surface of podocyte cell bodies and foot processes above the level of slit diaphragms.<sup>1,40–42</sup>

Maintenance of the intricate glomerular podocyte architecture is essential for optimal filtration; numerous human diseases and animal models of glomerular malfunction involve loss of structural integrity,<sup>43</sup> a phenotype often attributed to abnormal podocalyxin. Diabetic nephropathy, a leading cause of chronic kidney failure and ESRD, involves broadening of foot processes and is accompanied by a decrease in glomerular sialic acid content; loss of foot process structure is also the main morphologic abnormality in patients with nephrotic syndrome.<sup>44–46</sup> In two animal models of glomerular disease (puromycin aminonucleoside nephrosis and protamine sulfate perfusion), podocalyxin's negative charge is neutralized, foot process architecture is disrupted, and slit diaphragms are displaced or completely replaced by leaky, discontinuous junctions; intraperitoneal injection of sialidase produces similar effects.<sup>35,42,47–51</sup> Podocalyxin-deficient mice provide further evidence that podocalyxin maintains the unique podocyte morphology. Podocalyxin-null mice have fewer major processes and lack foot processes and slit diaphragms



**Figure 2.** Podocalyxin expression dramatically affects cell morphology. (A) Ectopic expression of podocalyxin in MCF-7 breast epithelial cells induces microvillus formation. Bar = 1  $\mu\text{m}$ .<sup>33</sup> (B) Podocalyxin is required for normal formation of kidney podocytes. Bar = 2  $\mu\text{m}$ .<sup>2</sup> Podocytes are shown surrounding capillaries. Loss of podocalyxin prevents dissolution of tight junctions (circled) between neighboring podocytes and results in a complete absence of podocyte foot processes (arrows).



**Figure 3.** Podocalyxin expression induces morphologic changes in a manner dependent on its extracellular domain. (A) Podocalyxin-induced morphologic changes: Formation of microvilli (black), actin recruitment (red), migration of cell junctions (green), and disruption of adhesion complexes (blue). (B) Podocalyxin-induced morphologic changes (including actin recruitment and microvillus or foot process formation) require podocalyxin's extracellular domain. Two models are depicted to explain this observation. Purple: Podocalyxin, with the negatively charged extracellular glycosylations shown as perpendicular lines. In the conformational change model, neutralization of podocalyxin leads to a conformational change and disruption of interactions with intracellular binding partners (blue). In the extracellular ligand model, neutralization of podocalyxin alters the binding site for an unknown transmembrane protein (light blue), responsible for indirectly linking podocalyxin to the actin cytoskeleton.

entirely (Figure 2B).<sup>2</sup> Moreover, podocyte cell bodies envelop capillary loops, and there is a striking presence of junctional complexes between adjacent podocytes.<sup>2</sup> Thus, although podocalyxin was originally thought to provide a charge-selective barrier for glomerular filtration, it is now known to play a role in podocyte morphogenesis and maintenance of structural integrity,<sup>1,2,52,53</sup> a function that fits with its onset of expression as well as the *in vitro*

microvillus formation studies described already (Figure 2A).<sup>33</sup>

Because neutralization of podocalyxin's extracellular domain alters podocyte morphology, the three aforementioned disease models were used to decipher the mechanisms involved. Podocalyxin is normally linked to the actin cytoskeleton through NHERF proteins and ezrin,<sup>3,19,54</sup> but it disengages from the cytoskeleton in all three

models, either through disruption of the podocalyxin/NHERF2/ezrin complex or by dissociation of the entire complex from actin.<sup>54,55</sup> This arrangement provides a likely explanation for the morphologic changes noted in podocytes. In support of this, mice with reduced core1- $\beta$ 1, 3-galactosyltransferase activity express hypoglycosylated podocalyxin and have distorted glomerular architecture.<sup>56</sup> Similarly, deletion of podocalyxin's extracellular domain abolishes the microvillus formation phenotype induced by ectopic expression of podocalyxin *in vitro*.<sup>33</sup> How exactly an alteration in the surface charge of podocalyxin affects the complex is not known, but it may be that neutralization of the charge induces a conformational change in the cytoplasmic tail of podocalyxin, which prevents binding, or that modification of podocalyxin's extracellular domain directly affects an as-yet-unknown ligand-binding domain (Figure 3). We favor the second possibility because microvillus formation is unaffected by deletion of virtually all of podocalyxin's intracellular domain.<sup>33</sup> Thus, early studies suggested a very important role for podocalyxin in kidney development, an expectation that was clearly fulfilled by the generation of podocalyxin-null mice.

The podocyte phenotypes observed in podocalyxin-deficient mice are consistent with a role for podocalyxin in decreasing cell adhesion and affecting cell morphology. As in developing glomeruli, the podocytes in podocalyxin-null animals retain apical junctions; cell-cell junctions do not migrate basolaterally and develop into slit diaphragms.<sup>2</sup> Thus, these cells retain an immature architecture. It seems likely that under normal conditions, either podocalyxin alters distribution of tight junction proteins by means of its cytoplasmic interaction partners or simply that expression of high levels of this bulky, negatively charged molecule on the apical surface may physically displace junctions to a more basal location. The strikingly abnormal podocytes in podocalyxin-deficient animals prohibit kidney function and are the apparent cause of perinatal lethality in all mice lacking this molecule.<sup>2</sup>

## Podocalyxin in the Hematopoietic System

Podocalyxin is expressed in all hematopoietically active tissues throughout development, predominantly by hematopoietic progenitors and erythroblasts.<sup>6,11,57</sup> It is first expressed in embryonic days 10 through 12 (E10 through 12) murine yolk sac and peripheral blood, and, interestingly, expression decreases over time.<sup>11</sup> Then, as hematopoiesis shifts to fetal liver at E15, 75% of fetal liver cells express podocalyxin, and, again, expression gradually decreases.<sup>11</sup> Similarly, fetal spleen and bone marrow both contain podocalyxin-positive populations upon acquisition of hematopoietic activity, and expression then decreases to virtually undetectable levels by birth<sup>11</sup>; however, there is a distinct burst of expression in hematopoietic tissues immediately after birth.<sup>11</sup> Thus, the establishment of each hematopoietically active tissue and/or the seeding of hematopoietic cells into new tissues coincide tightly with increased podocalyxin expression.

In adult, podocalyxin expression in the hematopoietic system is much more restricted. At steady state, it is expressed only on cells of the megakaryocytic lineage and a rare population of cells with a stem cell phenotype that give rise to myeloid and lymphoid lineages in serial transplantation experiments.<sup>6,9,11</sup> Moreover, although erythroid cells in adult do not normally express podocalyxin, it is rapidly upregulated by erythroid progenitors under conditions of extensive erythroid expansion.<sup>11</sup> For example, podocalyxin is expressed in response to phenylhydrazine-induced hemolytic anemia<sup>11</sup> and upon direct induction of erythroid expansion by erythropoietin injection.<sup>58</sup> Experiments with erythropoietin receptor mutants and *in silico* analysis of podocalyxin's promoter sequence indicated that erythropoietin-induced expression is dependent on STAT5 signaling.<sup>58</sup> Thus, podocalyxin seems to be upregulated by erythroid progenitors only when high rates of erythropoiesis are required, such as throughout development and under conditions of erythropoietic stress.

Despite the substantial expression of podocalyxin in the developing hematopoietic system, there are no detectable differences in frequencies of any hematopoietic lineages in podocalyxin-deficient mice.<sup>11</sup> Interestingly, though, short-term homing assays demonstrate that cells lacking podocalyxin or CD34 display decreased migration *in vivo*.<sup>11</sup> Thus, although podocalyxin is not essential for hematopoiesis, it may facilitate the crossing of endothelial barriers during migration to distant hematopoietic microenvironments.<sup>11</sup> Hematopoietic cells of the yolk sac become less adherent to leave blood islands, precursors in fetal liver must cross into the vasculature to migrate to spleen and bone marrow, and severe anemia leads to an efflux of erythroid progenitors from bone marrow to establish additional sites of erythropoiesis. Each of these situations corresponds to an increase in podocalyxin expression.

Podocalyxin is also a universal marker of vasculature.<sup>10–12</sup> It is found on endothelial cells lining a wide range of vessels, from the coronary artery to the specialized postcapillary high endothelial venules.<sup>8,10,12</sup> Despite this, the vasculature seems normal in developing podocalyxin-null animals.<sup>2</sup> CD34 may functionally compensate for loss of podocalyxin, though, because it is also ubiquitously expressed in vasculature and is upregulated in podocalyxin-null mice.<sup>2,59</sup> Furthermore, although there are no obvious defects in the vasculature, approximately 25% of podocalyxin-deficient embryos exhibit mild to severe edema, which could be attributed to leaky blood vessels.<sup>2</sup>

### Additional Sites of Podocalyxin Expression and Defects in Podocalyxin-Null Animals

One of the most recently described sites of podocalyxin expression is the brain, where it is detected in many regions, with the highest expression in cerebral cortex and cerebellum postnatally.<sup>13,14</sup> Expression in migrating cells in the developing cerebellum suggests that antiadhesive forces may aid in the detachment and

migration of neuronal cells and leading processes or that podocalyxin may be actively involved in axonal path finding through its interactions with PDZ domain-containing proteins.<sup>3,14</sup>

Finally, podocalyxin is expressed by mesothelial cells lining body cavities.<sup>2</sup> Loss of podocalyxin from these cells prevents retraction of the embryonic gut from the umbilical cord during development, presumably by increasing adhesion, and thus 30% of podocalyxin-null animals are born with gut herniation or omphalocele.<sup>2</sup> Under normal circumstances, this physiologic omphalocele is resolved during embryogenesis (E16 in mice) as the peritoneal cavity expands.<sup>60</sup> Thus, in another tissue where CD34 cannot functionally compensate for podocalyxin's absence, there seems to be an increase in cell adhesion.

## PODOCALYXIN IN CANCER

Up to this point, we have described the normal function and expression pattern of podocalyxin, but much can be learned from assessing disease states in which podocalyxin expression is dysregulated. Podocalyxin has been implicated in numerous malignant situations, including breast cancer, testicular cancer, prostate cancer, and leukemia.<sup>15–18</sup>

### Podocalyxin in Breast Cancer

Using a 272-case tissue microarray of invasive breast carcinomas, we showed that podocalyxin is upregulated in a subset of tumors and is correlated with very poor outcome.<sup>16</sup> The mean survival time was 6 yr less for patients with very highly podocalyxin-positive tumors than for all other patients.<sup>16</sup> Although there were no significant differences in histologic subtype or tumor size between groups, there were proportionally more high-grade, estrogen receptor-negative tumors in the high-podocalyxin group.<sup>16</sup> Importantly, highly podocalyxin-positive tumors are often found in patients who do not initially present with lymph node metastases, and podocalyxin overexpression is a statistically significant independent pre-

dicator of poor outcome with an eight-fold relative risk.<sup>16</sup>

### Podocalyxin in Prostate Cancer

Podocalyxin mutation, rather than overexpression, is associated with aggressive prostate cancer.<sup>18</sup> Initially, a genome-wide screen of >500 affected siblings strongly implicated chromosome 7q32-q33 in tumor aggressiveness,<sup>61</sup> a finding confirmed in subsequent studies.<sup>62,63</sup> This region also exhibits a high frequency of allelic imbalance in prostate tumors, with the podocalyxin locus (*podxl*) contained within the smallest region of imbalance.<sup>64</sup> Mutational analysis was therefore performed on genomic *podxl* from 17 previously identified families, and the relationship among prostate cancer, tumor aggressiveness, and *podxl* variants was assessed in a family-based association study.<sup>18</sup> Several common mutations were identified, including a variable in-frame deletion and several missense mutations.<sup>18</sup> The in-frame deletion variant led to loss of serine and proline residues in podocalyxin's extracellular domain and increased the relative risk for developing more aggressive prostate cancer.<sup>18</sup> The presence of missense mutations increased the risk for developing prostate cancer by approximately 50% but had no effect on aggressiveness.<sup>18</sup> Although the functional implications of these mutations are still under investigation, it is likely that alteration of podocalyxin's negative charge would increase cell motility and invasiveness or disrupt the association of podocalyxin with the actin cytoskeleton, as described in the kidney.

### Podocalyxin in Testicular Cancer

Podocalyxin was first reported in patients with cancer in 2003, when it was described as a marker of nonseminomatous germ cell tumors (NSGCT).<sup>15</sup> It is also found in the supernatants of cultured embryonal carcinoma cell lines and may therefore be a useful serum marker for detection of NSGCT.<sup>65</sup> Interestingly, the NSGCT form of podocalyxin seems to undergo additional post-translational modifications,<sup>15</sup> which may have functional implications.

### Podocalyxin in Pancreatic Ductal Adenocarcinoma

Although normal pancreatic tissue is negative or very weakly positive for podocalyxin, a large percentage of pancreatic ductal adenocarcinomas (PDAC) are positive, and higher grade tumors are more frequently positive (53% of grade 3 versus 18% of grade 1 tumors).<sup>66</sup> In general, individual, noncohesive, invasive tumor cells exhibit the strongest levels of podocalyxin expression.<sup>66</sup> Although a larger study is required to determine whether podocalyxin is an independent negative prognostic marker of PDAC, it is a good diagnostic tool for distinguishing PDAC from carcinomas originating in other related sites.<sup>66</sup>

### Podocalyxin in Hepatocellular Carcinoma

Two groups have reported podocalyxin upregulation and/or altered staining patterns in hepatocellular carcinoma,<sup>67,68</sup> a form of cancer that is detected very late, with a resulting exceptionally low 5-yr survival rate.<sup>69</sup> Whereas normal vessels lining the hepatic sinusoid allow free diffusion of macromolecules but not larger particles, vasculature within tumors is often abnormally permeable, allowing passage of larger molecules and even metastasis of cancerous cells through widened cell-cell junctions, larger fenestrations, transcellular holes, and an irregular basement membrane.<sup>68,70</sup> Thus, it is thought that podocalyxin may contribute to the leakiness of hepatocellular carcinoma vasculature. Regardless of the functional implications of its expression, however, podocalyxin may be a useful marker for earlier detection of this type of cancer.

### Podocalyxin in Leukemia

Podocalyxin expression in leukemia was assessed for several reasons: The related protein, CD34, is expressed by many but not all leukemic blasts; podocalyxin is expressed by normal hematopoietic progenitors; and the podocalyxin transcriptional regulator Wilms' tumor 1 is expressed by the majority of blasts in acute myeloid leukemia (AML) and acute lymphoblastic leukemia (ALL).<sup>11,17,71-73</sup> Using tissue microarrays and biopsy speci-

mens, podocalyxin was detected in blasts in a large majority of AML and ALL cases, with strong expression in 41 and 22%, respectively.<sup>17</sup> Podocalyxin was also expressed in myeloid sarcomas, with very high expression in 53% of cases; this is suggestive of a role in facilitating tissue infiltration.<sup>17</sup> A second study reported high podocalyxin in 18% of AML cases, with the majority of cells being a monocytic phenotype.<sup>74</sup> Because these are generally associated with poor prognosis, this is another example of increased correlation of podocalyxin expression with worse outcome.<sup>74</sup> Again, the functional relevance of podocalyxin expression in this type of cancer has not been conclusively demonstrated, but its presence could be used as a marker to increase the sensitivity of assays designed to detect leukemia.

### Podocalyxin in Wilms' Tumor

Wilms' tumor is the most common pediatric kidney cancer<sup>75</sup>; in contrast to the other cancers described herein, podocalyxin expression is significantly reduced in Wilms' tumors relative to normal fetal kidney, according to a cDNA microarray analysis of 64 tumor samples.<sup>76</sup> Importantly, though, there is a significant increase in podocalyxin expression in the more aggressive, anaplastic tumors.<sup>76</sup> Because p53 is usually mutated in anaplastic Wilms' tumors and it has been shown to regulate negatively podocalyxin expression,<sup>76</sup> this may explain why podocalyxin is expressed more highly in these cases. Functionally, podocalyxin may contribute to the increased metastasis of this subset of tumors.

## CONCLUSIONS

Podocalyxin has an important role in normal development and cancer progression. Adhesion and morphogenesis both are extremely important activities throughout development. Adhesion—or lack thereof—regulates proper migration of cells, whereas morphogenesis is critical for the generation of many specialized cell types. Podocalyxin is clearly important in facilitating formation of intricate podocyte foot

processes, but it may also play a role in generation of neuronal processes and the megakaryocytic extensions involved in platelet production. In addition, it may be involved in global cell migration and movement of hematopoietic cells across endothelial barriers when colonizing new niches. Expression on vascular endothelial cells likely prevents nonspecific adhesion and facilitates transendothelial migration of hematopoietic cells, as well as preventing collapse of capillary lumens as a result of adhesion of opposing membranes. Furthermore, the coating of podocalyxin on mesothelial cells lining body cavities likely protects organs from damage. This is especially evident in podocalyxin knockout animals, which are inefficient at retracting physiologic omphaloceles late in development. Thus, podocalyxin expression throughout development and in adult likely regulates adhesion and cell morphogenesis in a variety of tissues.

Podocalyxin has also been associated with a wide variety of cancers. It is upregulated in hepatocellular carcinoma and a subset of testicular cancers, and it is also found in leukemias.<sup>15,17,68</sup> Importantly, it is upregulated or mutated in highly aggressive breast cancers, prostate cancers, pancreatic ductal adenocarcinomas, and Wilms' tumors.<sup>16,18,66,76</sup> There are several possible reasons for podocalyxin dysregulation in malignant circumstances, but, in some cases, it is likely due to abnormal p53 expression, because podocalyxin is negatively regulated by p53.<sup>76</sup> In support of this, we have shown that high podocalyxin expression is positively correlated with abnormal p53 staining in invasive breast carcinomas.<sup>16</sup>

Although the mechanistic implications of podocalyxin dysregulation in these malignant situations are not entirely clear, its association with the most aggressive cases and its role in regulating cell adhesion suggest it may facilitate metastasis. Ectopic expression leads to increased invasion, as shown in prostate and breast cancer cell lines.<sup>77</sup> Furthermore, it is likely that expression of podocalyxin results in a generalized disruption of cell adhesion, particularly in situations in which apical domains expand as a result of a loss of polarity.<sup>33</sup>

Importantly, podocalyxin expression leads to a dramatic recruitment of NHERF-1 to the apical cell surface.<sup>33</sup> This has widespread downstream implications, because it may affect NHERF-1's interactions with a multitude of signaling proteins.<sup>33</sup> Podocalyxin also recruits f-actin and ezrin, leading to modification of downstream signaling pathways as well as upregulation of matrix metalloproteases.<sup>26,33,77</sup> Moreover, solid tumors, which require increased nutrients and therefore increased blood flow, may become more aggressive as a result of podocalyxin-mediated angiogenesis. Thus, podocalyxin is not only essential for development but also an important consideration in malignancy.

## ACKNOWLEDGMENTS

This study was supported by The Canadian Institutes for Health Research grant MOP-64278, a Grant in Aid from the Heart and Stroke Foundation of British Columbia and the Yukon, and an Allergen Network Centre of Excellence Grant. K.M.M. is a Michael Smith Foundation for Health Research Senior Scholar.

## DISCLOSURES

None.

## REFERENCES

- Kerjaschki D, Sharkey DJ, Farquhar MG: Identification and characterization of podocalyxin: The major sialoprotein of the renal glomerular epithelial cell. *J Cell Biol* 98: 1591–1596, 1984
- Doyonnas R, Kershaw DB, Duhme C, Merckens H, Chelliah S, Graf T, McNagny KM: Anuria, omphalocele, and perinatal lethality in mice lacking the CD34-related protein podocalyxin. *J Exp Med* 194: 13–27, 2001
- Orlando RA, Takeda T, Zak B, Schmieder S, Benoit VM, McQuistan T, Furthmayr H, Farquhar MG: The glomerular epithelial cell anti-adhesin podocalyxin associates with the actin cytoskeleton through interactions with ezrin. *J Am Soc Nephrol* 12: 1589–1598, 2001
- Hilkens J, Ligtenberg MJ, Vos HL, Litvinov SV: Cell membrane-associated mucins and their adhesion-modulating property. *Trends Biochem Sci* 17: 359–363, 1992
- Kershaw DB, Beck SG, Wharram BL, Wiggins JE, Goyal M, Thomas PE, Wiggins RC: Molecular cloning and characterization of human podocalyxin-like protein: Orthologous relationship to rabbit PCLP1 and rat podocalyxin. *J Biol Chem* 272: 15708–15714, 1997
- McNagny KM, Pettersson I, Rossi F, Flamme I, Shevchenko A, Mann M, Graf T: Thrombomucin, a novel cell surface protein that defines thrombocytes and multipotent hematopoietic progenitors. *J Cell Biol* 138: 1395–1407, 1997
- Takeda T, Go WY, Orlando RA, Farquhar MG: Expression of podocalyxin inhibits cell-cell adhesion and modifies junctional properties in Madin-Darby canine kidney cells. *Mol Biol Cell* 11: 3219–3232, 2000
- Sasseti C, Tangemann K, Singer MS, Kershaw DB, Rosen SD: Identification of podocalyxin-like protein as a high endothelial venule ligand for L-selectin: Parallels to CD34. *J Exp Med* 187: 1965–1975, 1998
- Miettinen A, Solin ML, Reivinen J, Juvonen E, Vaisanen R, Holthofer H: Podocalyxin in rat platelets and megakaryocytes. *Am J Pathol* 154: 813–822, 1999
- Miettinen A, Dekan G, Farquhar MG: Monoclonal antibodies against membrane proteins of the rat glomerulus: Immunochemical specificity and immunofluorescence distribution of the antigens. *Am J Pathol* 137: 929–944, 1990
- Doyonnas R, Nielsen JS, Chelliah S, Drew E, Hara T, Miyajima A, McNagny KM: Podocalyxin is a CD34-related marker of murine hematopoietic stem cells and embryonic erythroid cells. *Blood* 105: 4170–4178, 2005
- Horvat R, Hovorka A, Dekan G, Poczewski H, Kerjaschki D: Endothelial cell membranes contain podocalyxin: The major sialoprotein of visceral glomerular epithelial cells. *J Cell Biol* 102: 484–491, 1986
- Garcia-Frigola C, Burgaya F, Calbet M, Lopez-Domenech G, de Lecea L, Soriano E: A collection of cDNAs enriched in upper cortical layers of the embryonic mouse brain. *Brain Res Mol Brain Res* 122: 133–150, 2004
- Vitureira N, McNagny K, Soriano E, Burgaya F: Pattern of expression of the podocalyxin gene in the mouse brain during development. *Gene Expr Patterns* 5: 349–354, 2005
- Schopperle WM, Kershaw DB, DeWolf WC: Human embryonal carcinoma tumor antigen, Gp200/GCTM-2, is podocalyxin. *Biochem Biophys Res Commun* 300: 285–290, 2003
- Somasiri A, Nielsen JS, Makretsov N, McCoy ML, Prentice L, Gilks CB, Chia SK, Gelman KA, Kershaw DB, Huntsman DG, McNagny KM, Roskelley CD: Overexpression of the anti-adhesin podocalyxin is an independent predictor of breast cancer progression. *Cancer Res* 64: 5068–5073, 2004

17. Kelley TW, Huntsman D, McNagny KM, Roskelley CD Hsi ED: Podocalyxin: A marker of blasts in acute leukemia. *Am J Clin Pathol* 124: 134–142, 2005
18. Casey G, Neville PJ, Liu X, Plummer SJ, Cicek MS, Krumroy LM, Curran AP, McGreevy MR, Catalona WJ, Klein EA, Witte JS: Podocalyxin variants and risk of prostate cancer and tumor aggressiveness. *Hum Mol Genet* 15: 735–741, 2006
19. Li Y, Li J, Straight SW, Kershaw DB: PDZ domain-mediated interaction of rabbit podocalyxin and Na<sup>+</sup>/H<sup>+</sup> exchange regulatory factor-2. *Am J Physiol Renal Physiol* 282: F1129–F1139, 2002
20. Takeda T: Podocyte cytoskeleton is connected to the integral membrane protein podocalyxin through Na<sup>+</sup>/H<sup>+</sup>-exchanger regulatory factor 2 and ezrin. *Clin Exp Nephrol* 7: 260–269, 2003
21. Tan PC, Furness SG, Merkens H, Lin S, McCoy ML, Roskelley CD, Kast J, McNagny KM: Na<sup>+</sup>/H<sup>+</sup> exchanger regulatory factor-1 is a hematopoietic ligand for a subset of the CD34 family of stem cell surface proteins. *Stem Cells* 24: 1150–1161, 2006
22. Donowitz M, Cha B, Zachos NC, Brett CL, Sharma A, Tse CM, Li X: NHERF family and NHE3 regulation. *J Physiol* 567: 3–11, 2005
23. Shenolikar S, Voltz JW, Cunningham R, Weinman EJ: Regulation of ion transport by the NHERF family of PDZ proteins. *Physiology (Bethesda)* 19: 362–369, 2004
24. Voltz JW, Weinman EJ, Shenolikar S: Expanding the role of NHERF, a PDZ-domain containing protein adapter, to growth regulation. *Oncogene* 20: 6309–6314, 2001
25. Weinman EJ: New functions for the NHERF family of proteins. *J Clin Invest* 108: 185–186, 2001
26. Schmieder S, Nagai M, Orlando RA, Takeda T, Farquhar MG: Podocalyxin activates RhoA and induces actin reorganization through NHERF1 and Ezrin in MDCK cells. *J Am Soc Nephrol* 15: 2289–2298, 2004
27. Sassetti C, Van Zante A, Rosen SD: Identification of endoglycan, a member of the CD34/podocalyxin family of sialomucins. *J Biol Chem* 275: 9001–9010, 2000
28. Nielsen JS, Doyonnas R, McNagny KM: Avian models to study the transcriptional control of hematopoietic lineage commitment and to identify lineage-specific genes. *Cells Tissues Organs* 171: 44–63, 2002
29. Furness SG, McNagny K: Beyond mere markers: Functions for CD34 family of sialomucins in hematopoiesis. *Immunol Res* 34: 13–32, 2006
30. Baumhueter S, Singer MS, Henzel W, Hemmerich S, Renz M, Rosen SD, Lasky LA: Binding of L-selectin to the vascular sialomucin CD34. *Science* 262: 436–438, 1993
31. Drew E, Merzaban JS, Seo W, Ziltener HJ, McNagny KM: CD34 and CD43 inhibit mast cell adhesion and are required for optimal mast cell reconstitution. *Immunity* 22: 43–57, 2005
32. Nielsen JS, McNagny KM: Influence of host irradiation on long-term engraftment by CD34-deficient hematopoietic stem cells. *Blood* 110: 1076–1077, 2007
33. Nielsen JS, Graves ML, Chelliah S, Vogl AW, Roskelley CD, McNagny KM: The CD34-related molecule podocalyxin is a potent inducer of microvillus formation. *PLoS ONE* 2: e237, 2007
34. Cheng HY, Lin YY, Yu CY, Chen JY, Shen KF, Lin WL, Liao HK, Chen YJ, Liu CH, Pang VF, Jou TS: Molecular identification of canine podocalyxin-like protein 1 as a renal tubulogenic regulator. *J Am Soc Nephrol* 16: 1612–1622, 2005
35. Gao F, Maiti S, Sun G, Ordonez NG, Udtham M, Deng JM, Behringer RR, Huff V: The Wt1+/R394W mouse displays glomerulosclerosis and early-onset renal failure characteristic of human Denys-Drash syndrome. *Mol Cell Biol* 24: 9899–9910, 2004
36. Andrews PM: Glomerular epithelial alterations resulting from sialic acid surface coat removal. *Kidney Int* 15: 376–385, 1979
37. Adler S: Characterization of glomerular epithelial cell matrix receptors. *Am J Pathol* 141: 571–578, 1992
38. Michael AF, Blau E, Vernier RL: Glomerular polyanion: Alteration in aminonucleoside nephrosis. *Lab Invest* 23: 649–657, 1970
39. Guo JK, Menke AL, Gubler MC, Clarke AR, Harrison D, Hammes A, Hastie ND, Schedl A: WT1 is a key regulator of podocyte function: reduced expression levels cause crescentic glomerulonephritis and mesangial sclerosis. *Hum Mol Genet* 11: 651–659, 2002
40. Reeves W, Caulfield JP, Farquhar MG: Differentiation of epithelial foot processes and filtration slits: Sequential appearance of occluding junctions, epithelial polyanion, and slit membranes in developing glomeruli. *Lab Invest* 39: 90–100, 1978
41. Schnabel E, Dekan G, Miettinen A, Farquhar MG: Biogenesis of podocalyxin—the major glomerular sialoglycoprotein—in the newborn rat kidney. *Eur J Cell Biol* 48: 313–326, 1989
42. Kurihara H, Anderson JM, Kerjaschki D, Farquhar MG: The altered glomerular filtration slits seen in puromycin aminonucleoside nephrosis and protamine sulfate-treated rats contain the tight junction protein ZO-1. *Am J Pathol* 141: 805–816, 1992
43. Economou CG, Kitsiou PV, Tzinia AK, Panagopoulou E, Marinos E, Kershaw DB, Kerjaschki D, Tsilibary EC: Enhanced podocalyxin expression alters the structure of podocyte basal surface. *J Cell Sci* 117: 3281–3294, 2004
44. Pagtalunan ME, Miller PL, Jumping-Eagle S, Nelson RG, Myers BD, Rennke HG, Coplon NS, Sun L, Meyer TW: Podocyte loss and progressive glomerular injury in type II diabetes. *J Clin Invest* 99: 342–348, 1997
45. Cardenas A, Schadeck C, Bernard A, Lauwerys R: Depletion of sialic acid without changes in sialidase activity in glomeruli of uninephrectomized diabetic rats. *Biochem Med Metab Biol* 46: 416–421, 1991
46. Farquhar MG, Vernier RL, Good RA: Studies on familial nephrosis: II. Glomerular changes observed with the electron microscope. *Am J Pathol* 33: 791–817, 1957
47. Gelberg H, Healy L, Whiteley H, Miller LA, Vimr E: *In vivo* enzymatic removal of alpha 2->6-linked sialic acid from the glomerular filtration barrier results in podocyte charge alteration and glomerular injury. *Lab Invest* 74: 907–920, 1996
48. Kerjaschki D, Vernillo AT, Farquhar MG: Reduced sialylation of podocalyxin—the major sialoprotein of the rat kidney glomerulus—in aminonucleoside nephrosis. *Am J Pathol* 118: 343–349, 1985
49. Seiler MW, Rennke HG, Venkatachalam MA, Cotran RS: Pathogenesis of polycation-induced alterations (“fusion”) of glomerular epithelium. *Lab Invest* 36: 48–61, 1977
50. Bohrer MP, Baylis C, Robertson CR, Brenner BM, Troy JL, Willis WT: Mechanisms of the puromycin-induced defects in the transglomerular passage of water and macromolecules. *J Clin Invest* 60: 152–161, 1977
51. Farquhar MG, Palade GE: Glomerular permeability: II. Ferritin transfer across the glomerular capillary wall in nephrotic rats. *J Exp Med* 114: 699–716, 1961
52. Sawada H, Stukenbrok H, Kerjaschki D, Farquhar MG: Epithelial polyanion (podocalyxin) is found on the sides but not the soles of the foot processes of the glomerular epithelium. *Am J Pathol* 125: 309–318, 1986
53. Farquhar MG: Editorial: The primary glomerular filtration barrier—Basement membrane or epithelial slits? *Kidney Int* 8: 197–211, 1975
54. Takeda T, McQuistan T, Orlando RA, Farquhar MG: Loss of glomerular foot processes is associated with uncoupling of podocalyxin from the actin cytoskeleton. *J Clin Invest* 108: 289–301, 2001
55. Whiteside CI, Cameron R, Munk S, Levy J: Podocytic cytoskeletal disaggregation and basement-membrane detachment in puromycin aminonucleoside nephrosis. *Am J Pathol* 142: 1641–1653, 1993
56. Alexander WS, Viney EM, Zhang JG, Metcalf D, Kauppi M, Hyland CD, Carpinelli MR, Stevenson W, Croker BA, Hilton AA, Ellis S, Selan C, Nandurkar HH, Goodnow CC, Kile BT, Nicola NA, Roberts AW, Hilton DJ: Thrombocytopenia and kidney disease in mice with a mutation in the C1galt1 gene. *Proc Natl Acad Sci U S A* 103: 16442–16447, 2006
57. Suonpaa P, Kohonen P, Koskela K, Koskinemi H, Salminen-Mankonen H, Lassila O: Development of early PCLP1-expressing haematopoietic cells within the avian dorsal aorta. *Scand J Immunol* 62: 218–223, 2005
58. Sathyanarayana P, Menon MP, Bogacheva O,

- Bogachev O, Niss K, Kapelle WS, Houde E, Fang J, Wojchowski DM: Erythropoietin modulation of podocalyxin and a proposed erythroblast niche. *Blood* 110: 509–518, 2007
59. Fina L, Molgaard HV, Robertson D, Bradley NJ, Monaghan P, Delia D, Sutherland DR, Baker MA, Greaves MF: Expression of the CD34 gene in vascular endothelial cells. *Blood* 75: 2417–2426, 1990
  60. Kaufman MH: *The Atlas of Mouse Development*, San Diego, CA, Academic Press, 1998, pp 249–250
  61. Witte JS, Goddard KA, Conti DV, Elston RC, Lin J, Suarez BK, Broman KW, Burmester JK, Weber JL, Catalona WJ: Genomewide scan for prostate cancer-aggressiveness loci. *Am J Hum Genet* 67: 92–99, 2000
  62. Witte JS, Suarez BK, Thiel B, Lin J, Yu A, Banerjee TK, Burmester JK, Casey G, Catalona WJ: Genome-wide scan of brothers: Replication and fine mapping of prostate cancer susceptibility and aggressiveness loci. *Prostate* 57: 298–308, 2003
  63. Paiss T, Worner S, Kurtz F, Haeussler J, Hautmann RE, Gschwend JE, Herkommer K, Vogel W: Linkage of aggressive prostate cancer to chromosome 7q31–33 in German prostate cancer families. *Eur J Hum Genet* 11: 17–22, 2003
  64. Neville PJ, Conti DV, Paris PL, Levin H, Catalona WJ, Suarez BK, Witte JS, Casey G: Prostate cancer aggressiveness locus on chromosome 7q32–q33 identified by linkage and allelic imbalance studies. *Neoplasia* 4: 424–431, 2002
  65. Schopperle WM, Armant DR, DeWolf WC: Purification of a tumor-specific PNA-binding glycoprotein, gp200, from a human embryonal carcinoma cell line. *Arch Biochem Biophys* 298: 538–543, 1992
  66. Ney JT, Zhou H, Sipos B, Buttner R, Chen X, Kloppel G, Gutgemann I: Podocalyxin-like protein 1 expression is useful to differentiate pancreatic ductal adenocarcinomas from adenocarcinomas of the biliary and gastrointestinal tracts. *Hum Pathol* 38: 359–364, 2007
  67. Heukamp LC, Fischer HP, Schirmacher P, Chen X, Breuhahn K, Nicolay C, Buttner R, Gutgemann I: Podocalyxin-like protein 1 expression in primary hepatic tumours and tumour-like lesions. *Histopathology* 49: 242–247, 2006
  68. Chen X, Higgins J, Cheung ST, Li R, Mason V, Montgomery K, Fan ST, van de Rijn M, So S: Novel endothelial cell markers in hepatocellular carcinoma. *Mod Pathol* 17: 1198–1210, 2004
  69. El-Serag HB, Mason AC, Key C: Trends in survival of patients with hepatocellular carcinoma between 1977 and 1996 in the United States. *Hepatology* 33: 62–65, 2001
  70. Hashizume H, Baluk P, Morikawa S, McLean JW, Thurston G, Roberge S, Jain RK, McDonald DM: Openings between defective endothelial cells explain tumor vessel leakiness. *Am J Pathol* 156: 1363–1380, 2000
  71. Palmer RE, Kotsianti A, Cadman B, Boyd T, Gerald W, Haber DA: WT1 regulates the expression of the major glomerular podocyte membrane protein Podocalyxin. *Curr Biol* 11: 1805–1809, 2001
  72. Kerosuo L, Juvonen E, Alitalo R, Gylling M, Kerjaschki D, Miettinen A: Podocalyxin in human haematopoietic cells. *Br J Haematol* 124: 809–818, 2004
  73. Menssen HD, Renkl HJ, Rodeck U, Maurer J, Notter M, Schwartz S, Reinhardt R, Thiel E: Presence of Wilms' tumor gene (wt1) transcripts and the WT1 nuclear protein in the majority of human acute leukemias. *Leukemia* 9: 1060–1067, 1995
  74. Riccioni R, Calzolari A, Biffoni M, Senese M, Riti V, Petrucci E, Pasquini L, Cedrone M, Lo-Coco F, Diverio D, Foa R, Peschle C, Testa U: Podocalyxin is expressed in normal and leukemic monocytes. *Blood Cells Mol Dis* 37: 218–225, 2006
  75. Miller RW, Young JL Jr, Novakovic B: Childhood cancer. *Cancer* 75: 395–405, 1995
  76. Stanhope-Baker P, Kessler PM, Li W, Agarwal ML, Williams BR: The Wilms tumor suppressor-1 target gene podocalyxin is transcriptionally repressed by p53. *J Biol Chem* 279: 33575–33585, 2004
  77. Sizemore S, Cicek M, Sizemore N, Ng KP, Casey G: Podocalyxin increases the aggressive phenotype of breast and prostate cancer cells *in vitro* through its interaction with ezrin. *Cancer Res* 67: 6183–6191, 2007