



Diaphragm pacers as a treatment for congenital central hypoventilation syndrome

Maida Lynn Chen, Mary Anne Tablizo, Sheila Kun and Thomas G Keens[†]

Congenital central hypoventilation syndrome is a rare syndrome present from birth, and is defined as the failure of automatic control of breathing. All patients with congenital central hypoventilation syndrome require life-long ventilatory support during sleep, although approximately a third of patients require ventilatory support 24 h per day. Diaphragm pacers offer a modality of ventilatory support that affords congenital central hypoventilation syndrome patients with maximal mobility for full-time ventilatory patients, and they may allow for a more normal lifestyle in the appropriate patient. They may permit tracheostomy decannulation in those requiring only support during sleep. Diaphragm pacing entails surgical placement of an electrode onto the phrenic nerve, connected to a subcutaneous receiver. There is an external battery-operated transmitter and antenna placed on the skin over the receiver. The transmitter emits energy, similar to radio transmission, which is converted into an electrical current by the receiver. This stimulates the phrenic nerve resulting in a diaphragmatic contraction. Settings on the transmitter include respiratory rate and electrical voltage, and are adjusted to give enough tidal volume to allow for adequate oxygenation and ventilation. Therefore, diaphragm pacing is an attractive alternative mode of mechanically assisted ventilation for many patients with congenital central hypoventilation syndrome.

Expert Rev. Med. Devices 2(5), 577–585 (2005)

Congenital central hypoventilation syndrome

Ondine's curse, or more preferably, congenital central hypoventilation syndrome (CCHS), is a rare disorder where patients appear to breathe reasonably well while awake, but severely hypoventilate and/or become apneic during sleep. The incidence of CCHS is unknown, but it is generally considered to be rare [1]. It is present at birth and appears to be a life-long disorder. There is no known cure.

CCHS is a failure of automatic control of breathing [1–6]. Since breathing during quiet sleep is controlled almost entirely by the automatic respiratory control system located in the brainstem, ventilation is most severely affected during quiet sleep. Ventilation is better in active, or rapid eye movement (REM) sleep, when cortical input is at its greatest, although still not normal. While asleep, children with CCHS experience progressive hypercapnia and hypoxemia. They have absent or negligible

ventilatory sensitivity to hypercapnia and hypoxemia during sleep and wakefulness [7]. Based on physiologic studies, too extensive to be reviewed here, CCHS appears to represent a primary physiologic abnormality of integration of chemoreceptor input to central ventilatory controllers, rather than abnormalities in the chemoreceptors themselves [2,3]. More current studies have shown that CCHS children lack neural responses when compared with controls on functional magnetic resonance imaging (fMRI) in response to hypoxic, hypercapnic and cold pressor challenges in various sites, including the basal ganglia and deep cerebellar nuclei [8–10].

Diagnosis

The diagnosis of CCHS depends on the documentation of hypoventilation during sleep (usually in a respiratory physiology laboratory) in the absence of primary neuromuscular,

CONTENTS

Congenital central hypoventilation syndrome

Diaphragm pacing

Expert commentary & five-year view

Key issues

References

Affiliations

[†] Author for correspondence
 Childrens Hospital Los Angeles,
 Division of Pediatric Pulmonology,
 4650 Sunset Boulevard, Box #83,
 Los Angeles, CA 90027, USA
 Tel.: +1 323 669 2101
 Fax: +1 323 664 9758
 tkeens@chla.usc.edu

KEYWORDS:
 congenital central
 hypoventilation syndrome,
 diaphragm pacers

lung, cardiac or metabolic disease, or an identifiable brainstem lesion [1,3]. Confounding variables, including asphyxia, infection, trauma, tumor and infarction, must be delineated from CCHS. This disorder is associated with autonomic nervous system (ANS) dysfunctions [11–13] and Hirschsprung disease [14], which is caused by a lack of appropriate bowel innervation. While the cause of CCHS has not been completely elucidated, those with CCHS have mutations of the PHOX2b gene, which is involved in generalized ANS formation [15]. However, not all areas of neural abnormalities seen on fMRI in CCHS are populated by cells which would be affected by the PHOX2b mutations [16]. There are reports of CCHS women who have given birth to children with CCHS [17,18], and the disease has also been reported amongst twins and siblings [1].

Clinical course

During the first few years of life, CCHS infants may be very unstable. Affected infants may have intermittent duskiness, cyanosis and hypercapnia. As their oxygen saturations fall and their CO₂ levels rise, affected infants demonstrate no increase in respiratory rate or effort and usually do not arouse or appear distressed. Without the aid of objective monitoring, their hypoxia/hypercapnia is detected only at a late stage, when severe cyanosis and CNS depression have started [3]. These children, if undetected or misdiagnosed, will die from respiratory failure or will present at a later age with right heart failure and pulmonary hypertension from prolonged periods of hypoxia and hypercapnia.

As they mature, these patients usually become more stable if appropriately treated. All patients with CCHS will need supported ventilation while asleep, but approximately 65% of CCHS patients are able to come off assisted ventilation while awake [3,5]. In general, those patients who cannot persistently maintain end-tidal CO₂ pressure (P_{ET}CO₂) less than 45 torr and oxygen saturation (SaO₂) greater than 93% while spontaneously breathing must be fully supported 24 h/day. Children with CCHS can have prolonged survival, with several patients now in young adulthood and most have a good quality of life. Long-term follow-up and neurodevelopmental outcomes reveal a broad range of results with a great deal of variability, usually correlating to the degree of severity of their CCHS [5].

Treatment

Trying to compensate for a young child who functionally 'forgets to breathe' when asleep is challenging. The treatment of CCHS is to ensure adequate ventilation for the patients who are unable to achieve adequate gas exchange during spontaneous breathing, or simply put, to breathe for them. This requires mechanical-assisted ventilation as no pharmacologic respiratory stimulants have shown to be effective [1,3]. Supplemental oxygen alone is not sufficient treatment for hypoventilation and will not prevent pulmonary hypertension. Thus, CCHS children require home mechanical ventilation. Since children with CCHS usually do not have severe lung disease, they have many options for different techniques to provide mechanically assisted ventilatory support at home. While it should be

emphasized that children with CCHS are not candidates for weaning off mechanically assisted ventilation while asleep, mobility and quality of life are maximized if the child can breathe unassisted for portions of time while awake.

While diaphragm pacing will be the focus of the remainder of this article, other modalities of home mechanical ventilation which remain vital to the treatment of those with CCHS will be briefly reviewed here.

Portable positive pressure ventilator via tracheostomy

Portable positive pressure ventilation (PPV) via tracheostomy is the most common method of providing home mechanical ventilation, especially for infants and younger children [3]. Commercially available positive pressure ventilators have the capability for battery operation, are relatively portable and thus, maximize mobility. The tracheostomy leak can be compensated for by using the ventilator in a pressure-limited modality, also known as pressure plateau ventilation [19]. This technique is very successful in home mechanical ventilation of infants and small children. Home ventilators have been shown to be safe, and, in one large study, ventilator failures did not have any adverse patient outcomes [3,19].

Bi-level positive airway pressure ventilation

Noninvasive intermittent PPV is delivered via a nasal mask or face mask using a bi-level positive airway pressure ventilator. Bi-level ventilators are smaller, less expensive and generally easier to use than conventional ventilators, and do not require a tracheostomy [20,21]. Only the spontaneous/timed and timed modes guarantee breath delivery and should be used in CCHS patients, because these patients cannot be trusted to generate their own adequate respirations. Bi-level ventilation has been used successfully in treating children with CCHS as young as 6 weeks of age [22]. Bi-level ventilation is not as powerful as PPV via tracheostomy, and generally delivers lower pressures. Bi-level ventilation should not be used 24 h/day, since the mask interferes with daily activities and social interaction.

Negative pressure chest shell (cuirass) ventilator, wrap ventilator or port-a-lung

Negative pressure ventilation (NPV) works by generating a negative inspiratory pressure outside the chest and abdomen to cause an inspiration. Negative pressure ventilators are not as portable as electronic positive pressure ventilators. Airway occlusion can occur when breathing is generated by a negative pressure ventilator during sleep, especially in young children and infants, which may make this a less optimal technique. Nevertheless, NPV has worked successfully in some patients with CCHS [23]. Due to its lack of portability, this is not as popular a method of ventilation as the others.

Diaphragm pacing

Diaphragm pacing via phrenic nerve stimulation has been used to treat respiratory insufficiency for nearly 50 years in adults, and for approximately 30 years in infants and children [24–27].

Successful implantation and usage of diaphragm pacers relies on an intact phrenic nerve and functional diaphragm. Currently, it is estimated that over 1000 patients have had pacers placed. There is currently only one manufactured system (Avery Biomedical Devices, Inc.) that is approved by the US Food and Drug Administration (FDA). Another system (Atrotech Oy) has provisional FDA approval as an investigational device. As of this review, Avery Biomedical Devices reports that over 400 children have had their system placed both domestically and abroad.

Patient selection

Diaphragm pacing requires a functional diaphragm and intact phrenic nerve to be successful. It will not work in those with primary motor neuropathies (spinal muscular atrophy, amyotrophic lateral sclerosis or polio) or primary myopathies (muscular dystrophy). Conversely, diaphragm pacing has been, and is currently used in those with quadriplegia, as these patients have an intact phrenic nerve–diaphragmatic motor neuron communication. Children with CCHS are ideal candidates for diaphragm pacing, as they usually have little intrinsic lung disease, are not usually confined to a wheelchair and can have a relatively normal lifestyle if treated.

The authors' center has followed 19 patients who have had diaphragm pacers placed between 1980 and 2005. In total, 16 have CCHS, two have Chiari malformations and one is a quadriplegic. The average age of pacer implantation was 6.6 years [28].

In most children with CCHS, the simple act of a spontaneous breath demonstrates adequacy of the phrenic nerve and the diaphragm for potential pacing. However, in those whom this is questionable, visualizing spontaneous diaphragmatic movement with fluoroscopy should be employed, with adequate movement defined as two intercostal spaces. When performing fluoroscopy, asking the patient 'to take a deep breath' usually results in breath from intercostals and accessory muscles, not the diaphragm. Thus, in order to ensure diaphragmatic excursion, the patient should be instructed to sniff. In those with quadriplegia, the presence of an intact phrenic nerve (i.e., C3–5) roots and subsequent diaphragm movement can be demonstrated with percutaneous stimulation of the phrenic nerve in the cervical region. However, this is a technically challenging procedure given the numerous vitally important structures in this area and should only be performed by one familiar with the procedure. In CCHS children, this is not usually an issue.

Currently, diaphragm pacing is usually only used for 12–16 h/day, since fatigue occurs after this time. Therefore, children who require full-time ventilatory assistance cannot rely on pacers alone. These children will continue needing mechanically assisted ventilation while sleeping with PPV via tracheostomy or noninvasive bi-level ventilation. Since this technique is portable, it allows patient mobility and freedom from cumbersome equipment. Pacers can be used during the daytime in ambulatory children who require full-time ventilatory support, which allows for daytime mobility. Those children who are only night-time ventilator dependent can be transitioned to

diaphragm pacers for their sole method of ventilatory assistance while sleeping. Of the authors' 16 CCHS patients with pacers, eight needed full-time ventilatory support with a combination of daytime pacing and night-time PPV via tracheostomy, while the other eight required support (pacing) only while sleeping [28]. One of the authors' CCHS patients with pacers went backpacking in the Sierra Nevada mountains of California, USA, which would not be possible with other forms of mechanical ventilation.

An upper airway evaluation is another preoperative assessment that can be helpful before pacer placement, especially in those where tracheostomy decannulation is being considered. Increasing the size of the upper airway with tonsillectomy and/or adenoidectomy prior to pacers may help minimize upper airway obstruction. Those with tracheostomy present at the time of implantation need to be forewarned that the tracheostomy will probably not be decannulated for several months after pacer placement.

Successful implementation of a diaphragm system requires the patient to have highly motivated caregivers, a supportive primary care physician and an easily accessible pulmonologist with an affiliated center that has experience with diaphragm pacers. Pacers are generally placed in those whose quality of life improves with pacer placement.

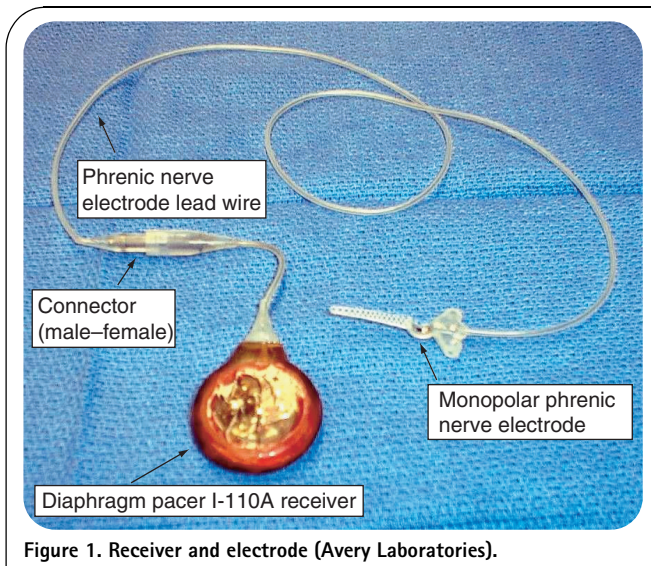
System

Diaphragm pacing generates breathing using the child's own diaphragm as the respiratory pump [24–27]. Electrical stimulation of each phrenic nerve results in a contraction of the ipsilateral hemidiaphragm, resulting in an inspired breath. Components of the system include the following:

- Electrodes that are surgically placed on the phrenic nerves bilaterally
- Lead wires that connect the electrodes to receivers implanted below the patient's skin
- Antennas that are taped on the skin over the receivers
- An external, battery-operated transmitter which is small enough to be placed near the body or worn in a small backpack (FIGURES 1 & 2)

The transmitter generates a train of pulses for each breath, which is transmitted through the antenna to the receiver under the skin, similar to radio transmission. The receiver converts this energy to standard electrical current, which is directed to the phrenic nerve electrode by the lead wires. The amount of electrical voltage is proportional to the diaphragmatic contraction or tidal volume (FIGURE 3). The transmitter contains the controls for frequency of breaths, individual controls for both right and left pacers' voltage strength (which translates into tidal volume), pulse interval, pulse width and slope of pulses (FIGURE 4).

Different types of electrodes have been used on the phrenic nerve. A monopolar electrode is used by Avery Biomedical Devices, and a quadripolar electrode system is employed by Atrotech [29]. As the quadripolar system does not currently have full FDA approval, the monopolar system is the one with



which the authors have the most experience. For more information on the Atrotech system, the authors refer readers to the Weese-Mayer and colleagues study on quadripolar systems [29]. For the rest of this review, the authors will focus on the Avery system, as this is the only system that the authors' patients have had implanted.


Surgical techniques

The surgical techniques for pacer placement have been described in detail in other studies, and are not the primary scope of this review. While unilateral pacing has been performed, the pediatric population usually requires bilateral pacing to ensure adequate ventilation. In adults and larger children, some centers implant the phrenic nerve electrodes in the neck. However, for smaller children, intrathoracic placement of the electrodes is generally required. Actual surgical techniques vary greatly by center; the authors will discuss only the techniques that have been employed by the authors' center. There are two general methods that are used; traditional placement using open thoracotomy and less invasive thoracoscopic placement. At the authors' institution, nine patients have had open thoracotomies, all occurring before 1998, and the other ten have had thoracoscopic placement of their pacers. In the open surgical technique, an incision is made at the third intercostal space in the mammary line, and the thoracic phrenic nerve is identified and dissected from adjacent tissue. In the thoracoscopic technique, trocars are placed in the fifth, seventh and ninth intercostal spaces along the posterior axillary line. In this technique, the lung is deflated (one side at a time) [30]. The (monopolar) electrode is positioned below the nerve and sutured into place, allowing some slack to avoid traction tension on the nerve itself. The wire off the electrode is then brought down through the thoracic cavity and tunneled out through the diaphragm into a separately created subcutaneous pocket immediately inferior to the 12th rib. The electrode wire is then connected to the receiver. Extra length of wire, the connector and the receiver are then placed into a Gortex® or Silastic® pouch. This

pouch, which decreases scar-tissue formation, is then placed as one unit into the subcutaneous pocket, with only the electrode wire extruding out of the pocket and into the thoracic cavity. The pouch contains extra length of wire to accommodate the child's somatic growth. Both sides are usually placed in one operation. It is currently not likely that a quadripolar electrode will be implantable using a thoracoscopic method.

Of utmost importance is testing the electrode before the thoracic cavity is closed to make sure a diaphragmatic contraction results from electrode stimulation. A person familiar with the equipment should be present in the operating room for this testing. Immediately after electrode placement, the wire should be connected to the receiver and the system tested, simply to make sure that there is adequate contact between the electrode and the nerve. Therefore, pharmacologic muscle blockade during surgery does not allow for adequate system testing during placement, and these paralytics should not be used.

CCHS children require vigilant monitoring perioperatively in an intensive care unit, as they will demonstrate no signs of respiratory depression or distress, such as retractions or labored breathing [3]. Without question, CCHS children require mechanically assisted ventilation perioperatively, especially in recovery from anesthesia, until they are fully awake. Even a slight amount of residual anesthetic can have profound respiratory depression on a patient with CCHS. They should have continuous pulse oximetry and intermittent blood gases or $P_{ET}CO_2$ readings to assure adequate oxygenation and ventilation. Pacers are generally not used in the immediate post-operative period due to pain at the incision sites, therefore another method must be used, such as PPV via endotracheal tube, tracheostomy or noninvasively.



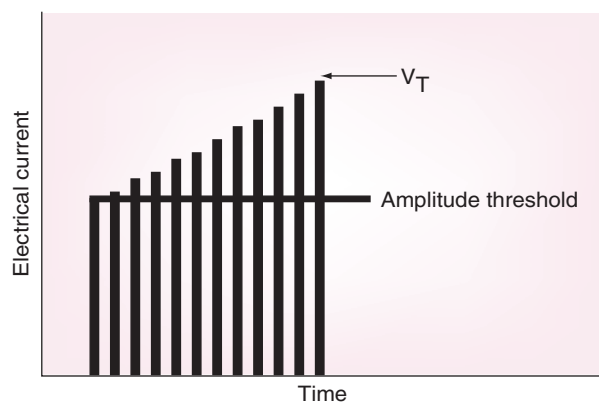


Figure 3. Train of pulses. Each black vertical line represents a pulse of electrical current. The width of each black line is known as the pulse width. The time between each pulse is known as the pulse interval. The total time of all the pulses is the inspiratory time. V_T : Tidal volume.

The incision sites bilaterally (whether they are open or from the trocars) heal quickly. Immediate postoperative complications are those related to standard surgeries, including an increased chance of atelectasis/pneumonia due to lung deflation during the surgical procedure. Owing to increased risk of infection from implanting foreign bodies, intravenous antibiotics (vancomycin) should be administered postoperatively for 24–48 h after surgery. Pain medication is warranted for the incisions, but should not be needed for a prolonged period of time. Most children will be discharged home 3–7 days after placement, depending on method of placement.

Initiation of pacing

Pacing is gradually initiated at least 4–6 weeks after placement, which allows for tissue reaction around the electrodes to stabilize. Beginning pacing prior to fibrosis of the site requires frequently changing settings. Both full- and night-time only ventilated patients are admitted to the hospital to establish settings for initiation of pacing. If night-time pacing is to be used, the initiation of pacing is optimally performed in the sleep laboratory, to optimize oxygenation and ventilation while sleeping. Initially, diaphragm pacing results in fatigue (decreasing diaphragmatic contraction for the same electrical stimulus) after

60–90 min. Thus, aerobic training of these muscle fibers is required to sustain pacing for the desired 12–16 h/day. The authors start pacing at 1–2 h/day, and gradually increase this by 30–60 min/day each week. Thus, a training period of up to 3–4 months is usually required to achieve full pacing.

The settings on the transmitter must be set in a monitored situation, with a pulse oximeter and either $P_{ET}CO_2$ monitor or transcutaneous CO_2 monitor at the very least. Children with CCHS should be paced so that their SaO_2 remains above 95% and with CO_2 kept at or below 35 torr, awake or asleep. Maintaining mild hyperventilation in these children provides a cushion to allow for daytime hypoventilation, acute illness, less vigilant airway care at home than in a hospital setting, and produces more successful daytime sprinting [3,5,31]. The respiratory rate is set close to the physiologic rate for age, as CCHS patients cannot be trusted to generate their own rate. Voltage is adjusted for a tidal volume with maximal oxygenation and ventilation using minimal voltage. Usually, the preset pulse interval (50 ms) and pulse width (150 μs) on the transmitter from Avery Biomedical Devices do not need to be adjusted, with adequate settings achieved by altering the rate and voltage, which are easily done. Inspiratory time can also be adjusted. In those children without a tracheostomy, a longer inspiratory time (which decreases overall negative intrathoracic force) may be helpful in reducing obstructive apneas. The slope of increase in voltage during a breath can also be adjusted. In general, the authors use a flat slope (i.e., the voltage remains the same at the beginning and end of the breath).

Titration/evaluation

Like those children who have more traditional mechanically assisted ventilation for CCHS, those with diaphragm pacers need to be routinely assessed in a respiratory physiology or sleep laboratory to have their settings adjusted as they grow and have changing respiratory needs. The authors recommend that once initial pacer settings have been established and patients have been clinically stable, younger toddlers and children should be evaluated every 6 months, while older children and adults be evaluated annually. Pacers should be titrated accordingly during these studies to ensure adequate oxygenation and ventilation at the lowest possible setting. Referred shoulder




Figure 4. Mark IV diaphragm pacer transmitter, Avery Laboratories. The external settings are as shown. Internal settings include inspiratory time, pulse width, pulse interval, slope. 1: Left tidal volume setting; 2: Left antenna; 3: Left side on/off; 4: Respiratory rate; 5: Right side on/off; 6: Right antenna; 7: Right tidal volume setting.

pain or upper airway noise with contractions are often a sign that the voltage is too high. Failure of the diaphragm to contract, or persistent hypercarbia and/or hypoxia are signs that the voltage or rate is not high enough.

Home care

Immediate postoperative care of the pacer system is relatively benign, since the pacer system is not used for weeks post-operatively, and is reviewed above. After the skin incisions have healed, the most important element of home care is to avoid injury to the subcutaneous pocket where the receiver resides. For this reason, children with pacers are not encouraged to participate in contact sports. Younger active children should also be monitored for rough play. In children who are paced while awake, care should be taken with any exercise since the pacers have a set rate that will not increase with the increased respiratory requirements associated with exercise. However, in most of our patients this has not been problematic since exercise stimulates spontaneous breathing in CCHS [32].

The antennas are secured over the receivers in a number of ways to ensure placement while awake and moving, as well as asleep in bed. Often, this takes experimentation with different methods by the family. Some simply tape the antennas onto the skin, which can cause skin irritation/breakdown and often will not hold the antennas in place all night. Many need to use both tape and an abdominal wrap (binder or elastic bandage) that further secures placement.

If paced while asleep, the transmitter usually sits on a bedstand next to the bed. While awake, the transmitter is often carried on the patient in a small backpack or fanny pack, and should be wrapped in some cushioning insulation. The antennas, especially the transmitter, should not become wet.

Tracheostomy decannulation

Once adequate ventilation is achieved overnight using the noninvasive technique with open tracheostomy, the authors begin to downsize the tracheostomy. Sleep studies with oxygen saturation and end-tidal monitoring are used to ensure adequate gas exchange. Finally, if a child can sustain adequate ventilation with a small tracheostomy plugged, the tracheostomy is removed. The authors find the use of home pulse oximetry and $P_{ET}CO_2$ monitoring to be helpful when completing the transition to noninvasive forms of ventilation. In eight of the authors' CCHS-paced patients who use pacers solely during sleep, four had their tracheostomies successfully decannulated and two have been scheduled for decannulation in the near future [28].

Problems with pacing

Diaphragm pacers can work well, but they require frequent attention and often require tinkering. Thus, successful diaphragm pacing requires proximity to, and frequent communication with, a medical team willing to maintain this system. It would be ideal if patients could have a back-up transmitter and antenna at all times. However, due to insurance constraints and

the high monetary cost, a back-up transmitter is sometimes not provided. If a problem occurs, the patient should go to the closest emergency room and have that local physician contact their physician who is familiar with the intricacies of pacing. In an emergency, if the patient still has a tracheostomy, PPV via tracheostomy can be used until diaphragm pacing can be restored. If they have been decannulated, the authors have successfully used noninvasive PPV until pacing is restored.

Upper airway obstruction can occur with paced breaths, particularly in sleep [3,25,26,33]. In normal spontaneous inspiration, the body's respiratory center initiates a breath by stimulating the muscles of respiration (diaphragm and intercostals) to contract while coordinating the muscles of the upper airway to maintain patency. However, when paced, the diaphragm contracts without this centrally coordinated effort which predisposes a patient's upper airway to collapse. This predisposition is more exaggerated in sleep, particularly REM sleep, when skeletal muscles become more relaxed, making the muscles of the upper airway even more prone to collapse due to intrathoracic pressure created by the diaphragm. Infants and younger children are also at higher risk due to their inherently smaller airways and partially adducted vocal cords at rest. Consequently, it is not uncommon for patients without a tracheostomy to snore during sleep. However, airway occlusion can usually be avoided by careful titration of pacer settings (i.e., increased inspiratory time and decreased amplitude of diaphragm contraction). All patients should have an upper airway evaluation before pacer placement, and some patients may benefit from tonsillectomy/adenoidectomy preoperatively.

Once diaphragm pacers are placed, the patient cannot have MRI due to the magnetic field. While the average CCHS patient does not require routine MRI for anything pertaining to their CCHS after pacer implantation, care related to other health problems may be affected, especially with the increasingly common use of MRI for many problems, given its lack of radiation. For instance, MRIs of joints (knees and shoulders) have become a standard of practice in orthopedic services for common injuries, and diaphragm pacers would preclude this standard. As with cardiac pacemakers, diaphragm pacers may also present problems with metal detection devices used at airports and so on. A letter from a primary physician describing the patient's condition and pacers should be carried with the patients at all times, and patients should be warned to arrive at places known to use metal detection screening well ahead of time. Diaphragm pacemakers may theoretically interfere with the function of cardiac pacemakers due to closely placed electromagnetic fields, although this has not been the authors' experience. It has been recommended that diaphragm pacers be placed 10 cm from a cardiac pacemaker to avoid interference [AVERY BIOMEDICAL DEVICES, PERS. COMM.], although this is not always possible in small children. This potential problem can be circumvented by using a bipolar cardiac pacemaker, placing the phrenic nerve electrode in the lower thoracic cage if possible, and testing both pacer circuits in the operating room at maximal outputs to see if interaction occurs before electrode placements are finalized.

As with any noninvasive forms of mechanically assisted ventilation in CCHS, patients must be monitored with vigilance, as they do not demonstrate signs of respiratory distress. Pulse oximetry should be routinely used while being paced during sleep to monitor for airway obstruction or pacer malfunction. Diaphragm pacing causes artifacts in transthoracic impedance-based cardiorespiratory monitors, and therefore cannot be used [26]. Pacers may also not provide enough ventilatory support if CCHS patients become acutely ill or have major surgical procedures, and these children may need intubation with PPV on a temporary basis in these situations. This being said, the authors have had a young woman with CCHS supported only with diaphragm pacers throughout a full-term pregnancy, albeit with vigilant and frequent physiologic monitoring [18].

Finally, diaphragm-pacing systems are very costly [25,33]. It has been estimated that including the actual system, surgery with general anesthesia, hospitalizations and continued care costs at least US\$100,000. However, the monthly cost of maintaining a child at home with a tracheostomy and portable ventilator is comparable, after the cost of long-term equipment replacement/rental, medical and nursing care are considered.

Complications

Long-term outcomes of those with phrenic nerve pacers have not been well studied in large groups of children. Adults have shown no diaphragm or phrenic nerve problems after as long as 30 years of diaphragm pacing [27]. Before surgical techniques were modified, phrenic nerve entrapment could occur either due to inappropriate electrode placement or due to persistent traction on the nerve from the lead wire. However, these complications are not seen today due to improvements in surgical technique.

If a patient reports possible malfunction, determining the site of malfunction, which can occur at any site along the system, may be difficult. Referred, ipsilateral shoulder pain can be due to broken wire encapsulation or receiver malfunction. In one series by Weese-Mayer and colleagues, the most common component failure was receiver failure (Avery Biomedical Devices) [25,26,34]. However, this receiver has since been redesigned, and the newer model is proving to last much longer. To investigate the site of malfunction, one should first ensure that the external components are functioning. If neither side is working, the likely source of the problem is a transmitter malfunction. One should ensure that there are fresh batteries, and that there are no obvious breaks in antenna wires. If the transmitter is not working, it needs to be exchanged for a functional one as soon as possible. If only one side is nonfunctional, for example the right side, an attempt should be made to stimulate the right-sided pacer using the left side of the transmitter and left antenna. If this attempt elicits a diaphragm contraction on the right side, then the problem is in the right side of the transmitter, or right-sided antenna. If this attempt does not result in contraction, then the problem lies within the surgically implanted right-sided components, and surgical exploration is needed. If the receiver is damaged, a new one can be replaced back into the same subcutaneous pocket and pacing can resume

in 1–2 days. This is easily done since the receiver is connected to the electrode via a male–female connector. The connection wires in the subcutaneous pocket can be twiddled by the patient, breaking the wire (FIGURE 5) [35]. If the wire is broken on the receiver end (distal to the male–female connector), this can be replaced easily. However, if the wire is broken on the electrode end (proximal to the male–female connector), a new electrode and wire will need to be implanted on the phrenic nerve. In some instances, only the insulation surrounding the wire is broken and can be patched using silastic cement, which can be found in central-line repair kits. This patching, if successful, prevents the need to implant an entire new electrode and wire. If the electrode has been damaged, it should not be removed due to the fibrotic mass formed around it and the phrenic nerve. Attempting to dissect the electrode and fibrotic mass away from the phrenic nerve risks nerve damage. An entire new electrode must be placed distally from the old electrode, which is left in place. As with initial placement, the entire system should be checked while under anesthesia to ensure that full function has been restored.

Infections can occur along any part of the system, and can be very serious. All of the components are foreign substances that once infected, usually need to be removed in order for the infection to completely resolve in conjunction with prolonged broad-spectrum antibiotics.

In the authors' cohort of patients, no phrenic nerve injuries were reported. Two patients have had postsurgical infections, and both required surgical removal and replacement. Six have had internal lead wire problems; three close to the electrode end and the other three in proximity of the receiver.

Expert commentary & five-year view

Diaphragm pacing in children with CCHS has been established as an effective method of mechanically assisted ventilation, and allows for maximal mobility. With time, the authors hope that diaphragm pacing becomes more commonplace with more centers and physicians gaining familiarity in their placement and continued care. Long-term outcome data needs to be continually assessed and published so that others may benefit from the lessons of more experienced centers. From a technical standpoint, the authors hope that transmitters will become

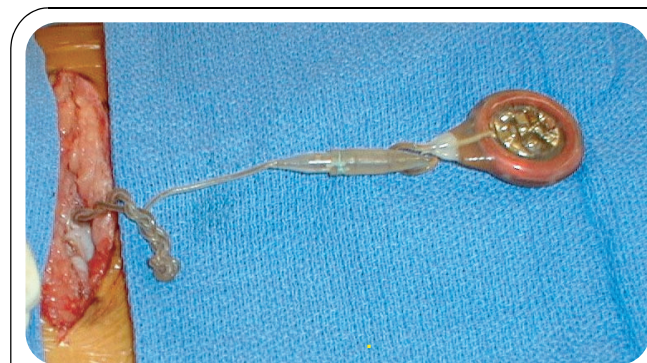

Figure 5. Twiddling receiver with broken electrode wire.

smaller and more efficient. Potentially, advancing technology will allow for successful 24 h/day diaphragm pacing through improved electrode–nerve interfaces, as well as more durable connecting wires/receivers. In fact, laparoscopic implantation of electrodes directly onto the diaphragm at the phrenic nerve motor point, which allows for 24 h/day pacing by sparing direct phrenic nerve stimulation, have been successfully carried

out in a few tetraplegic adults [36]. There has been discussion on the development of a completely implantable system, much like current cardiac pacemakers, eliminating the need to carry any external equipment. While this may be cosmetically appealing, technology would need to develop a way in which the pacer could be adjusted noninvasively to accommodate for growing children and changing respiratory needs.

Key issues

- Congenital central hypoventilation syndrome (CCHS) is a rare life-long syndrome, and is defined as the failure of automatic control of breathing. It is characterized primarily by progressive hypoventilation and hypoxia most pronounced during sleep. All patients with CCHS require life-long ventilatory support at least during sleep, and some require full-time ventilation.
- Diaphragm pacers can provide adequate ventilatory support and offer an improved lifestyle with maximal mobility to those with CCHS. However, they can only be used 12–16 h/day. Pacers may allow some CCHS children to have tracheostomy decannulation.
- Diaphragm pacing requires a functional diaphragm and intact phrenic nerve to be successful. It will not work in those with primary motor diseases or neuropathies.
- The diaphragm-pacing system involves surgical placement of an electrode onto the phrenic nerve (usually in the thoracic cavity). This electrode is connected by a wire to a subcutaneous receiver. Via an antenna taped over the receiver, an external battery-operated transmitter then emits energy, similar to radio transmission, which is converted into an electrical current resulting in a diaphragmatic contraction.
- The pacer system can be implanted either via thoracotomy or thoroscopically. Since the system should be tested in the operating room, paralytics should not be used during surgery. CCHS children require vigilant perioperative monitoring due to their inability to demonstrate signs of respiratory depression or distress.
- Pacing is initiated 4–6 weeks after implantation to allow for healing and fibrosis around the electrode. Pacing should be started in a controlled setting (hospital or sleep laboratory) to monitor oxygen saturations and carbon dioxide. Pacing is performed only 1–2 h/day at the beginning due to diaphragm fatigue and increased slowly; a training period of 3–4 months is required to achieve full pacing.
- Common problems with diaphragm pacing are upper airway obstruction, inability to have magnetic resonance imaging and possible interference with cardiac pacemakers and commonly used metal detectors. Complications include infection, malfunction and rarely phrenic nerve damage.
- Diaphragm pacers can work well, but require frequent attention. Patients with pacers should be cared for by physicians familiar with both CCHS and diaphragm pacers.

References

Papers of special note have been highlighted as:

• of interest

•• of considerable interest

- 1 Weese-Mayer DE, Shannon DC, Keens TG, Silvestri JM. Idiopathic congenital central hypoventilation syndrome: diagnosis and management. *Am. J. Respir. Crit. Care Med.* 160, 368–373 (1999).
- 2 Gozal D. Congenital central hypoventilation syndrome: an update. *Pediatr. Pulmonol.* 26, 273–282 (1998).
- 3 Chen ML, Keens TG. Congenital central hypoventilation syndrome: not just another rare disorder. *Paediatr. Resp. Rev.* 5, 182–189 (2004).
- 4 Oren J, Kelly H, Shannon DC. Long-term follow-up of children with congenital central hypoventilation syndrome. *Pediatrics* 80, 375–380 (1987).
- 5 Marcus CL, Jansen MT, Poulsen MK *et al.* Medical and psychosocial outcome of children with congenital central hypoventilation syndrome. *J. Pediatr.* 119, 888–895 (1991).
- 6 Weese-Mayer DE, Silvestri JM, Menzies LJ, Morrow-Kenny AS, Hunt CE, Hauptman SA. Congenital central hypoventilation syndrome: diagnosis, management, and long-term outcome in thirty-two children. *J. Pediatr.* 120, 381–387 (1992).
- 7 Paton JY, Swaminathan S, Sargent CW, Keens TG. Hypoxic and hypercapnic ventilatory responses in awake children with congenital central hypoventilation syndrome. *Am. Rev. Respir. Dis.* 140, 368–372 (1989).
- 8 Macey PM, Woo MA, Macey KE *et al.* Hypoxia reveals posterior thalamic, cerebellar, midbrain, and limbic deficits in congenital central hypoventilation syndrome. *J. Appl. Physiol.* 98, 958–969 (2005).
- 9 Harper RM, Macey PM, Woo MA *et al.* Hypercapnic exposure in congenital central hypoventilation syndrome reveals CNS respiratory control mechanisms. *J. Neurophysiol.* 93, 1647–1658 (2005).
- 10 Macey PM, Macey KE, Woo MA, Keens TG, Harper RM. Aberrant neural responses to cold pressor challenges in

- congenital central hypoventilation syndrome. *Pediatr. Res.* 57, 500–509 (2005).
- 11 Weese-Mayer DE, Silvestri JM, Huffman AD *et al.* Case/control family study of autonomic nervous system dysfunction in idiopathic congenital central hypoventilation syndrome. *Am. J. Med. Genet.* 100, 237–245 (2001).
 - 12 Chen ML, Lin Z, Khoo MCK, Davidson Ward SL, Keens TG. Cardiorespiratory uncoupling in congenital central hypoventilation syndrome. *Proc. Am. Thorac. Soc.* 2, A461 (2005).
 - 13 Lin Z, Chen ML, Keens TG, Davidson Ward SL, Khoo MCK. Model-based assessment of autonomic system dysfunction in congenital central hypoventilation syndrome. *Proc. Am. Thorac. Soc.* 2, A460 (2005).
 - 14 Haddad GG, Mazza NM, Defendini R *et al.* Congenital failure of automatic control of ventilation, gastrointestinal motility and heart rate. *Medicine (Baltimore)* 57, 517–526 (1978).
 - 15 Weese-Mayer DE, Berry-Kravis EM. Genetics of congenital central hypoventilation syndrome: lessons from a seemingly orphan disease. *Am. J. Respir. Crit. Care Med.* 170, 16–21 (2004).
 - 16 Gaultier C. Functional brain deficits in congenital central hypoventilation syndrome. *Pediatr. Res.* 57, 471–472 (2005).
 - 17 Silvestri JM, Chen ML, Weese-Mayer DE *et al.* Idiopathic congenital hypoventilation syndrome: the next generation. *Am. J. Med. Genet.* 112, 46–50 (2002).
 - 18 Sritippayawan S, Hamutcu R, Kun SS, Ner Z, Ponce M, Keens TG. Mother–daughter transmission of congenital central hypoventilation syndrome. *Am. J. Respir. Crit. Care Med.* 166, 367–369 (2002).
 - 19 Keens TG, Davidson Ward SL. Ventilatory treatment at home. In: *Respiratory Control Disorders in Infants and Children*. Beckerman RC, Brouillette RT, Hunt CE (Eds), Williams and Wilkins, IL, USA, 371–385 (1997).
 - **Overview of all home mechanically assisted ventilation modalities.**
 - 20 Marcus CL. Ventilator management of abnormal breathing during sleep: continuous positive airway pressure and nocturnal noninvasive positive pressure ventilation. In: *Sleep During Development and in Pediatrics*. Loughlin GM, Marcus CL, Carroll JL (Eds), Marcel Dekker, NY, USA, 797–811 (2000).
 - **Overview of noninvasive positive pressure ventilation in children.**
 - 21 Schafer T, Schafer C, Schlafke ME. From tracheostomy to non-invasive mask ventilation: a study in children with congenital central hypoventilation syndrome. *Med. Klin.* 94, 66–69 (1992).
 - 22 Tibballs J, Henning RD. Noninvasive ventilator strategies in the management of a newborn infant and three children with congenital central hypoventilation syndrome. *Pediatr. Pulmonol.* 36, 544–548 (2003).
 - 23 Hartmann H, Samuels MP, Noyes JP, Southall DP. Negative extrathoracic pressure ventilation in infants and young children with central hypoventilation syndrome. *Pediatr. Pulmonol.* 23, 155–157 (1997).
 - 24 Glenn WWL, Holcomb WG, Gee JBL, Bath R. Central hypoventilation syndrome: long-term ventilatory assistance by radio-frequency electrophrenic respiration. *Ann. Surg.* 172, 755–773 (1970).
 - 25 Weese-Mayer DE. Diaphragm pacing in infancy and childhood. In: *Sleep During Development and in Pediatrics*. Loughlin GM, Marcus CL, Carroll JL (Eds), Marcel Dekker, NY, USA, 813–824 (2000).
 - **Comprehensive review of pediatric diaphragm pacing.**
 - 26 Weese-Mayer DE, Hunt CE, Brouillette RT. Diaphragm pacing in infants and children. In: *Respiratory Control Disorders in Infants and Children*. Beckerman RC, Brouillette RT, Hunt CE (Eds), Williams and Wilkins, IL, USA, 386–399 (1992).
 - **Comprehensive review of pediatric diaphragm pacing.**
 - 27 Glenn WWL, Brouillette RT, Dentz B, Fodstad *et al.* Fundamental considerations in pacing of the diaphragm for chronic ventilatory insufficiency: a multi-center study. *Pacing Clin. Electrophysiol.* 11, 2120–2127 (1988).
 - 28 Kun SS, McComb JG, Shaul DB, Atkinson JB, Keens TG. 23 years of diaphragm pacing in children. *Am. J. Respir. Crit. Care Med.* 169, A894 (2004).
 - 29 Weese-Mayer DE, Silvestri JM, Kenny AS *et al.* Diaphragm pacing with a quadripolar phrenic nerve electrode: an international study. *Pacing Clin. Electrophysiol.* 19, 1311–1319 (1996).
 - 30 Shaul DB, Danielson PD, McComb JG, Keens TG. Thoracoscopic placement of phrenic nerve electrodes for diaphragmatic pacing in children. *J. Pediatr. Surg.* 37, 974–978 (2002).
 - **Provides detailed overview of pacer placement using thoracoscopy.**
 - 31 Gozal D, Keens TG. Passive night-time hypocapnic hyperventilation improves daytime eucapnia in mechanically ventilated children. *Am. J. Respir. Crit. Care Med.* 157(3), A779 (1998).
 - 32 Paton JY, Swaminathan S, Sargent CW, Hawksworth A, Keens TG. Ventilatory response to exercise in children with congenital central hypoventilation syndrome. *Am. Rev. Respir. Dis.* 147, 1185–1191 (1993).
 - 33 Nishino T. Problems associated with diaphragm pacing. *Respiration* 69, 12–13 (2002).
 - 34 Weese-Mayer DE, Morrow AS, Brouillette RT, Ilbawai MN, Hunt CE. Diaphragm pacing in infants and children: a life-table analysis of implanted components. *Am. Rev. Respir. Dis.* 139, 974–979 (1989).
 - 35 Fitzgerald D, Davis GM, Gottesman R, Fecteau A, Guttman F. Diaphragmatic pacemaker failure in congenital central hypoventilation syndrome: a tale of two twiddlers. *Pediatr. Pulmonol.* 22, 319–321 (1996).
 - 36 Onders RP, DiMarco AF, Ignagni AR, Aiyar H, Mortimer JT. Mapping the phrenic nerve motor point: the key to a successful laparoscopic diaphragm pacing system in the first human series. *Surgery* 136, 819–826 (2004).

Affiliations

- Maida Lynn Chen, MD
University of Southern California,
Division of Pediatric Pulmonology
Childrens Hospital Los Angeles,
Keck School of Medicine,
Los Angeles, CA 90027, USA
- Mary Anne Tablizo, MD
University of Southern California,
Division of Pediatric Pulmonology
Childrens Hospital Los Angeles,
Keck School of Medicine
Los Angeles, CA 90027, USA
- Sheila Kun, RN, MS
University of Southern California,
Division of Pediatric Pulmonology
Childrens Hospital Los Angeles,
Keck School of Medicine
Los Angeles, CA 90027, USA
- Thomas G Keens, MD
Childrens Hospital Los Angeles, Division of
Pediatric Pulmonology, 4650 Sunset Boulevard,
Box #83, Los Angeles, CA 90027, USA
Tel.: +1 323 669 2101
Fax: +1 323 664 9758
tkeens@chla.usc.edu