

CODEN [USA]: IAJPBB

ISSN: 2349-7750

**INDO AMERICAN JOURNAL OF
PHARMACEUTICAL SCIENCES**Available online at: <http://www.iajps.com>

Research Article

**ANTI-ACNE ACTIVITY OF LIPIDO-STEROLIC EXTRACT
OF SERENOA REPENS AND HYDRO-ALCOHOLIC
EXTRACT OF GLYCYRRHIZA GLABRA IN SYRIAN
HAMSTER EAR MODEL**V. Laxmi Sravani^{1*}, Dr. B. Chandrasekhar Rao¹, Dr. D. Ravi Krishna Babu²¹Department of Pharmacology, RGR Siddhanthi College of Pharmacy, Secunderabad.²Aurigene Discovery Technologies Pvt Ltd. Miyapur, Hyderabad.**Abstract:**

Acne vulgaris is the most commonly encountered dermatological disease of pilosebaceous unit. Androgens, which increase during puberty, stimulate the sebaceous gland to produce sebum and cause retention of keratinocytes around the sebaceous hair follicle orifice causing partial to complete blockage and leading to colonization with Propionibacterium acnes, which participates in the production of pro inflammatory mediators. For treatment of acne one of the approaches is to reduce sebum production, the main stimulus to acne; then all other pathogenic factors will diminish. A comprehensive approach combining the natural medicine with anti-androgenic activity would be fruitful area for anti-acne therapy. In this context the well documented anti-androgenic herbs like liquorice and saw palmetto were selected and screened in Syrian hamster ear model using spironolactone as standard. Topical application (3% w/v, 40 µl b.i.d), of Hydroalcoholic extract of roots of liquorice and Combination group showed a significant reduction in the area of hamster ear sebaceous glands. The present results suggest the potential for the use of liquorice for anti-acne therapy.

Key words: Glycyrrhiza glabra Linn, Glycocoumarins, Lipocoumarins, Glycirin**Corresponding author:****V. Laxmi Sravani,**Department of Pharmacology,
RGR Siddhanthi College of Pharmacy,
Secunderabad.

QR code



Please cite this article in press as V. Laxmi Sravani et al, *Anti-Acne Activity of Lipido-Sterolic Extract of Serenoa Repens and Hydro-Alcoholic Extract of Glycyrrhiza Glabra in Syrian Hamster Ear Model*, Indo Am. J. P. Sci, 2017; 4(08).

INTRODUCTION:

Acne is the most common dermatologic condition encountered in clinical practice, though rarely life threatening, it is a bane of almost every adolescent face. Acne vulgaris affects adolescents, with prevalence rates of 70–87%[1]. Acne usually lasts several years in the affected individual and represents a condition that continuously changes in its clinical appearance rather than an acute disease. Currently, the understanding of acne has been refined towards a 'chronic disease', overcoming the misconception of acne as a simple, self-limited affliction of adolescents [2]. In recent years, multifactorial nature of acne has been elucidated. An improved understanding of the pathophysiology Inflammation [5-8

of acne will lead to rational therapy for treating acne successfully [3]. Sebaceous gland is an androgen target organ, stimulated to produce sebum at puberty and beyond by androgens. Sebaceous glands present the highest androgen receptor density in human skin. Androgen binding capacity in sebaceous glands may be important factor for the development of acne [4].

Pathophysiology of Acne:

Pathogenesis of acne underlies four major factors:
 Sebaceous Gland Hyperactivity
 Changes in Follicular Keratinization
 The Influence of Bacteria

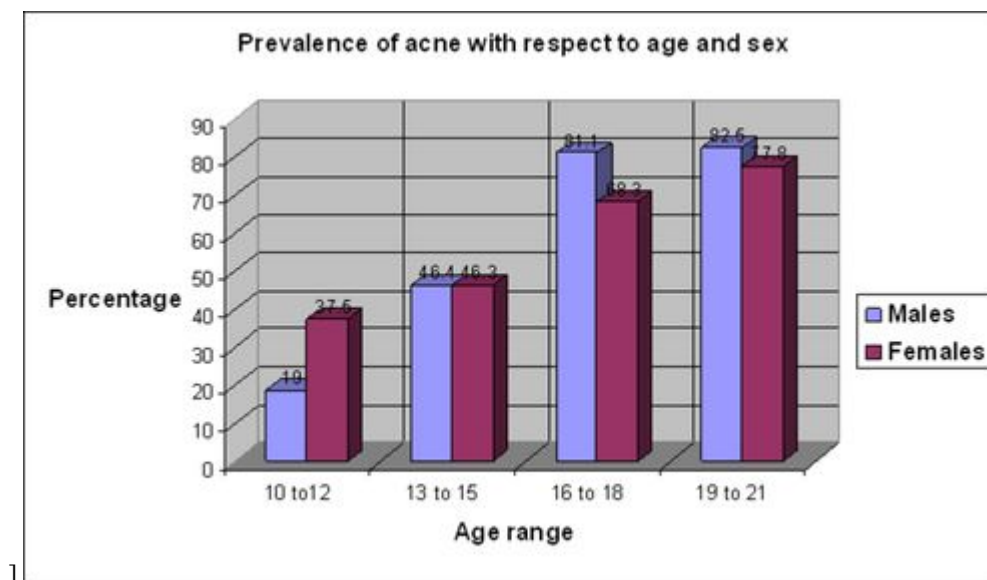


Fig 1: The prevalence of acne with respect to age and sex.

Plant Description:

Glycyrrhiza glabra:



Fig 2: *Glycyrrhiza glabra*

Glycyrrhiza glabra Linn. is the esteemed crude drug used in traditional medicine across the globe for its ethnopharmacological values to cure various ailments. It is also known as Liquorice or sweet wood which is native to Mediterranean and certain areas of Asia [9].

Glycyrrhiza glabra Linn. is a hardy perennial shrub, attaining a height upto 2.5m. The leaves are compound, imparipinnate, alternate having 4-7 pairs of oblong elliptical or lanceolate leaflets. The flowers are narrow, typically papilionaceous borne in axillary spikes, lavender to violet in colour. The fruit is compressed legume or pod. The underground stem grows horizontally up to 2m length, highly branched consisting of short taproot with large number of rhizomes [10].

Chemical Constituents:

The roots of *Glycyrrhiza glabra* Linn. consist of water soluble constituents Glycyrrhizin responsible for its sweet taste. Glycyrrhizin is a saponin compound comprised of triterpenoid aglycone, glycyrrhetic acid conjugated with disaccharide of glucuronic acid. As a tribasic acid Glycyrrhizin forms variety of salts and occurs naturally in liquorice roots [11,12]. Other constituents present in liquorice are Liquiritigenin, Liquiritin (Flavones), Isoliquiritigenin, Isoliquiritin (Chalcones), Genistein, Glicoricone, Glisoflavone, Isoangustone A (Isoflavones), Glycyrrhizoflavone, Glyasperin F, Licoisoflavonone, Glyasperin C, Glyasperin D, Glabridin, Licoricidin, Glycocomarins, Lipocomarins, Glycirin and others [13].

Taxonomical classification:

Table: 1

Kingdom	Plantae
Subkingdom	Tracheobionta
Superdivision	Spermatophyta
Division	Magnoliophyta
Class	Magnoliopsida
Subclass	Rosidae
Order	Fabales
Family	Fabaceae
Genus	Glycyrrhiza L.
Species	Glycyrrhiza glabra L.

Serenoa repens:



Fig 3: *Serenoa repens*

Saw palmetto, scientifically named *Serenoa repens* (also called *Serenoa serrulata*, *Sabal serrulata*, *Sabalis serrulata*, pan palm, dwarf American palm, or dwarf palmetto) is the hardiest of the palms (the Arecaceae family) and grows widely over large areas in the Southern part of the United States and the West Indies. Native Americans used these berries for the treatment of various urinary problems in men, as well as for women with breast disorders. The plant is an evergreen shrub, usually 2 to 10 feet tall, with creeping or horizontal rhizomes and occasionally reaches up to 20 to 25 feet, the size of a small tree [14,15]. The shrubs bloom from April through June and the fruits begin to ripen in mid-August. As ripening occurs, fruits turn in color from green (May-June) to yellow (mid-August), to orange (September), and then to bluish-black (September-October) when ripe.

Taxonomical Classification

Table:2

Kingdom	Plantae
Subkingdom	Tracheobionta
Super division	Spermatophyta
Division	Magnoliophyta
Class	Liliopsida
Subclass	Arecales
Order	Arecales
Family	Arecaceae
Genus	Serenoa Hook. f.
Species	Serenoa repens (W. Bartram)

Chemical Constituents:

The major chemical constituents of the ripe fruits include phyosterols, fatty acids, carbohydrates, monoacylglycerides, and other compounds. The biologically active compounds are the phyosterols, fatty acids and their ethyl esters, and monoacylglycerides. Commercial products from saw palmetto fruits include dried or partially dried fruit powder or liposterolic extracts in liquid or powder form standardized to contain predetermined levels of fatty acids (capric acid, caproic acid, caprylic acid, lauric acid, myristic acid, oleic acid, linoleic

acid, linolenic acid, palmitoleic acid, palmitic acid, and stearic acid). As reported in the USP monograph, a mixture of 11 methyl esters of fatty acids (methyl laurate, methyl oleate, methyl myristate, methyl palmitate, methyl palmitoleate, methyl linoleate, methyl linolenate, methyl caproate, methyl caprylate, methyl caprate, and methyl stearate) serve as marker compounds to confirm the identity of saw palmetto¹⁶.

MATERIALS AND METHODS:

Animals:

Male Syrian golden hamsters procured from NIN Hyderabad and were quarantined under the supervision of veterinarian and acclimatized in observation room for minimum period of 1 week. Animals were fed with NIN rodent diet and water ad libitum. The experiments were performed with hamsters at 9-10 weeks of age in accordance with Institute of Animal Ethics Committee. The animals were placed in laboratory cages and Cage card indicating number of animals; animal number and different dose group were attached. The animals were fed with NIN powder and pellet feed and RO water was provided ad libitum in polypropylene bottles freshly filled twice a week.

Test Item details:

Serenoa repens fruit extract (saw palmetto)

Glycyrrhiza glabra root extract (Liquorice, glycyrrhizine >20%)

Formulation: Vehicles:

60% Ethanol + 40% Milli Q water

Transcutol

MilliQ water

Reagents:	Alcohol : water (4 :1) Spironolactone (Sigma, S-3378, Lot : 071M1669V) Lipidosterolic extract of ripe berries of Serenoa repens (Xena Bio-Herbals) Aqueous extract of dried roots of Glycyrrhiza glabra (Nuzen Labs)
-----------	---

Topical Formulations

Preparation of Serenoa repens (3% w/v):

21 mg of Serenoa repens fruit extract + 700 µL of Transcutol.

Preparation of Glycyrrhiza glabra (3% w/v):

21 mg of Glycyrrhiza glabra root extract + 700 µL mixture of (60 % of Ethanol + 40 % of Milli Q water).

Preparation of Spironolactone solution:

40 mg of Spironolactone dissolved in 800 µl of Ethanol + water vehicle (1mg/kg)

Ethanol+ water vehicle preparation: 0.8 ml of Ethanol mixed with 0.2ml M.Q water

Serenoa repens (3% w/v), Glycyrrhiza glabra (3% w/v), Spironolactone (5% w/v) were applied on ventral lobe of right ear and on twice daily up to end of study.

Methods:

1. To establish a method to measure sebaceous glands area using stripped skin planimetry.
2. Evaluation of sebaceous gland modulation of spironolactone in male hamsters.
3. Evaluation of effect of anti-androgens in modulating sebaceous gland in male hamsters.

Study design:

Study: 1 Establishment of stripped skin planimetry.

Stripped skin planimetry is a method developed to measure the ear sebaceous gland areas. The ear skin was manually separated from the cartilage and observed under a microscope. Using stripped skin planimetry, it was demonstrated that the sebaceous gland size was greatest at the basal region of the ear and decreased towards the apex. The regional variations in densities of sebaceous glands were also observed. 8 animals of uniform body weight are taken and quarantined for 1 week. Animals are sacrificed and both left and right ears are collected and stored in 10%NBF.

Study: 2 Evaluation of sebaceous gland modulation of spironolactone in male hamsters

About 16 male Syrian golden hamsters were taken for the study. The animals were divided into 2 groups. Group 1 contains 8 animals; they were treated with vehicle (Ethanol: water) topically for 15 days twice daily. Group 2 was treated with spironolactone solution 40 µl (10 mg/ml) b.i.d for 15 days.

On day 15, after 1 hr of application animals were sacrificed under CO₂ asphyxia and then both the right and left ear lobes of hamsters were collected and stored in 10% neutral buffered formalin (NBF). The sebaceous glands in the ears were then observed by stripped skin planimetry and measured using image analyzer software

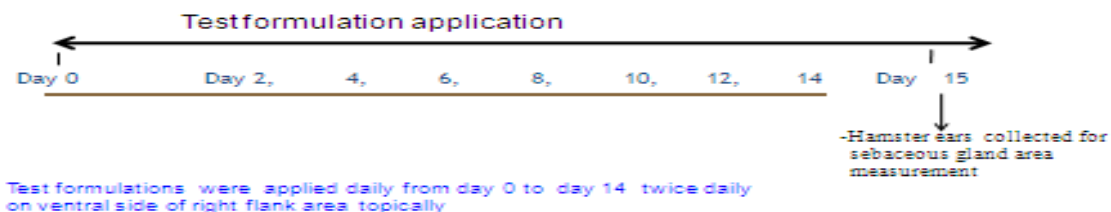
S.no	Groups	Dosage regimen
1.	Vehicle control	40µl of vehicle b.i.d
2.	Spironolactone 5% w/v	40µl b.i.d

Animals were grouped based on body weight in to 2 groups.

Study Design:

Group 1: Normal control(n=8)

Group 2: Spironolactone 5% w/v (n=8)



Test formulations were applied daily from day 0 to day 14 twice daily on ventral side of right flank area topically

Vogel; Noto et al; 1991

Study 3: Evaluation of effect of anti-androgens in modulating sebaceous gland in male hamsters.

About 28 male Syrian golden hamsters were taken for the study. The animals were divided into 4 groups. Group 1 contains 7 animals; they were treated with vehicle (Ethanol:water, Transcutol) topically for 15 days twice daily. Group 2 was treated with Saw palmetto 3%w/v 40 μ l (1 mg/ml) b.i.d for 15 days. Group 3 were treated with Liquorice 3% w/v 40 μ l (1 mg/ml) b.i.d for 15 days and Group 4 were treated with spironolactone 5%w/v 40 μ l (1 mg/ml) b.i.d for 15 days.

On day 15, after 1 hr of application animals were sacrificed under CO₂ asphyxia and then both the right and left ear lobes of hamsters were collected and stored in 10% neutral buffered formalin (NBF).

The sebaceous glands in the ears were then observed by stripped skin planimetry and measured using image analyzer software.

Animals were grouped based on body weight in to 4 groups.

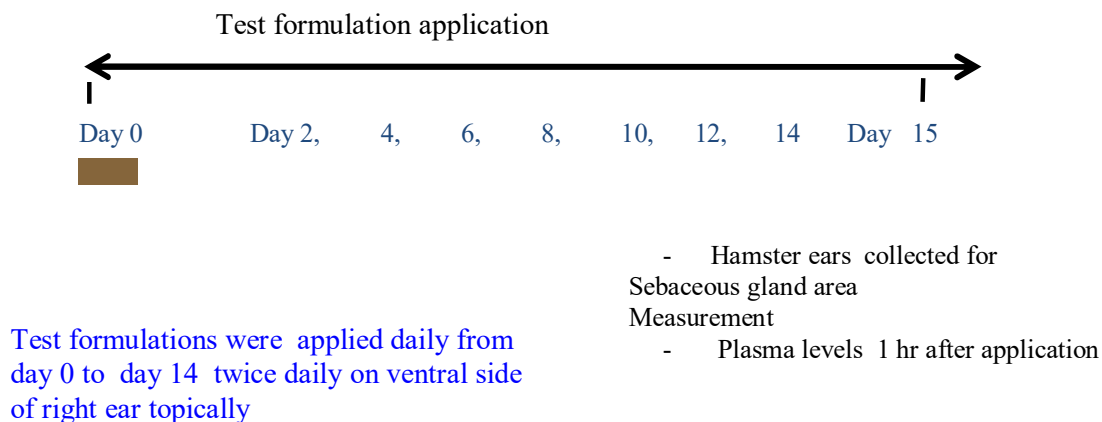
Group 1: Vehicle control (n=7)

Group 2: Saw palmetto Topical (3 %w/v) (n=7) b.i.d

Group 3: Liquorice Topical (3 %w/v) (n=7) b.i.d

Group 4: Combination of saw palmetto and Liquorice (3% w/v) b.i.d

Group 5: Spironolactone topical (5%w/v) (n=7) b.i.d



Test formulations were applied daily from day 0 to day 14 twice daily on ventral side of right ear topically

Assessment of sebaceous glands

- Image was captured using a microscope at (4x) magnification
- The image was analyzed using a image analyzer software
- The number of sebaceous glands in 1mm² area and the size of 10 sebaceous glands were measure.

Statistical analysis:

The data was analyzed by using graph pad prism. The values of control right ears were compared with standard and test formulations right ear sebaceous gland area by One way ANOVA followed by Dunnett's test.

Contra lateral ear sebaceous glands (left ear) of the groups were compared to the treated right ear sebaceous glands by One way ANOVA followed by Dunnett's test.

RESULTS AND DISCUSSION:**Study1: Model validation**

Table: 3

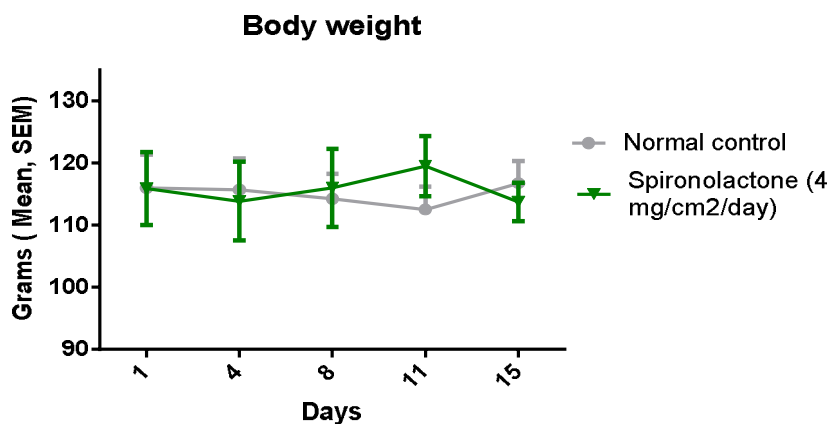
Animal no.	Mean	Sem
1	0.075	0.007
2	0.080	0.005
3	0.100	0.011
4	0.108	0.003
5	0.122	0.006
6	0.127	0.009
7	0.137	0.008
8	0.133	0.010

Hamster ear stripping was performed and the area of sebaceous glands was calculated And was found to be 0.111 ± 0.007

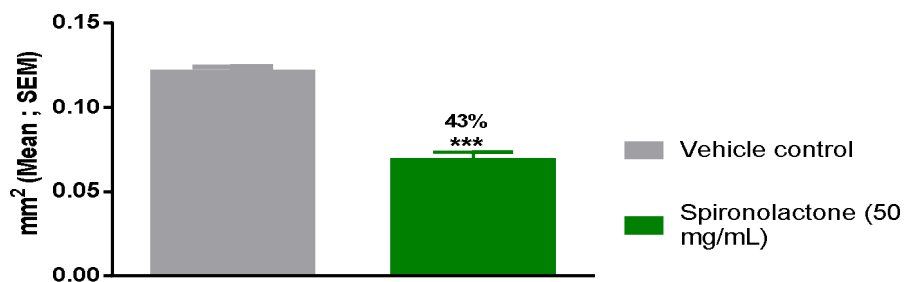
Study 2: Evaluation of sebaceous gland modulation of spironolactone in male hamsters

Table:4

Ear sebaceous gland	% Change in Ear sebaceous gland size	
	Normal control	Spironolactone 5% w/v
Left	0.116 ± 0.006	0.102 ± 0.004
Right	0.121 ± 0.003	0.068 ± 0.005

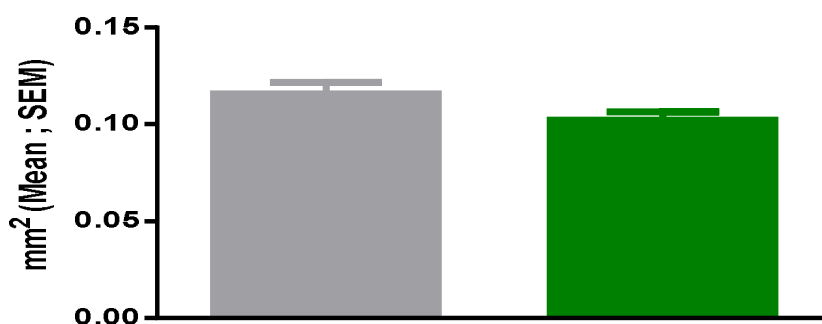


Body weights were constantly monitored throughout the study and there is no significant decrease in body weights during the study.

Right ear-Ipsilateral sebaceous gland area

***p<001 Oneway ANOVA followed by Dunnett's test

The area of sebaceous glands of right ears of normal animals, and Spironolactone (1 mg/kg) was calculated and it was found to be, 0.121±0.003 and 0.068±0.005mm² respectively.

Left ear (Contralateral) sebaceous gland area

The area of sebaceous glands of left ears of normal animals, and Spironolactone (1 mg/kg) was calculated and it was found to be, 0.116±0.006 and 0.102±0.004 mm² respectively.

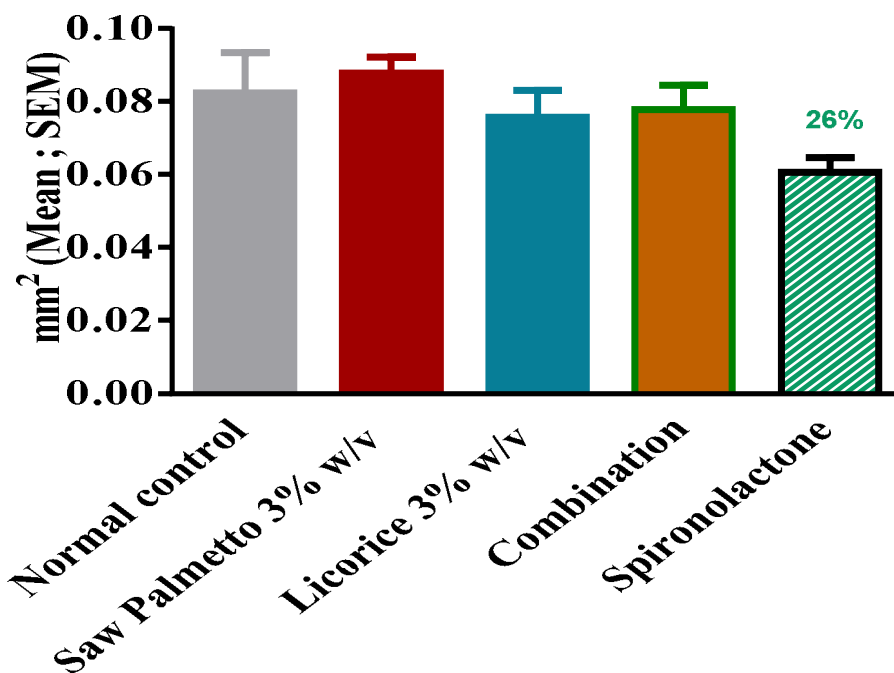
- Topical application of Vehicle did not show significant reduction in ipsilateral and contralateral ear sebaceous gland area.
- Topical application of spironolactone to right ears showed a significant reduction in sebaceous gland area.

Study 3: Evaluation of effect of anti-androgens in modulating sebaceous gland in male hamsters

Table: 5

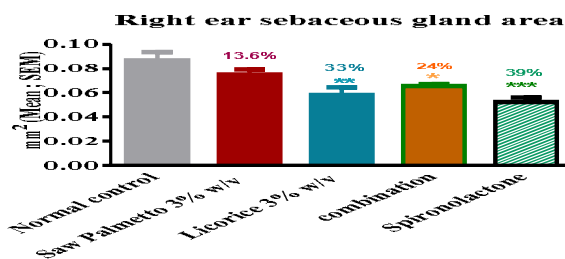
Ear sebaceous gland	% Change in Ear sebaceous gland size				
	Normal control	Saw Palmetto 3%w/v	Liquorice 3%w/v	Combination	Spironolactone 5% w/v
Left	0.082±0.011	0.088±0.004	0.076±0.006	0.078±0.007	0.061±0.004
Right	0.087±0.007	0.075±0.004	0.058±0.006	0.065±0.002	0.052±0.004

Left ear sebaceous gland area



One way ANOVA followed by Dunnett's test

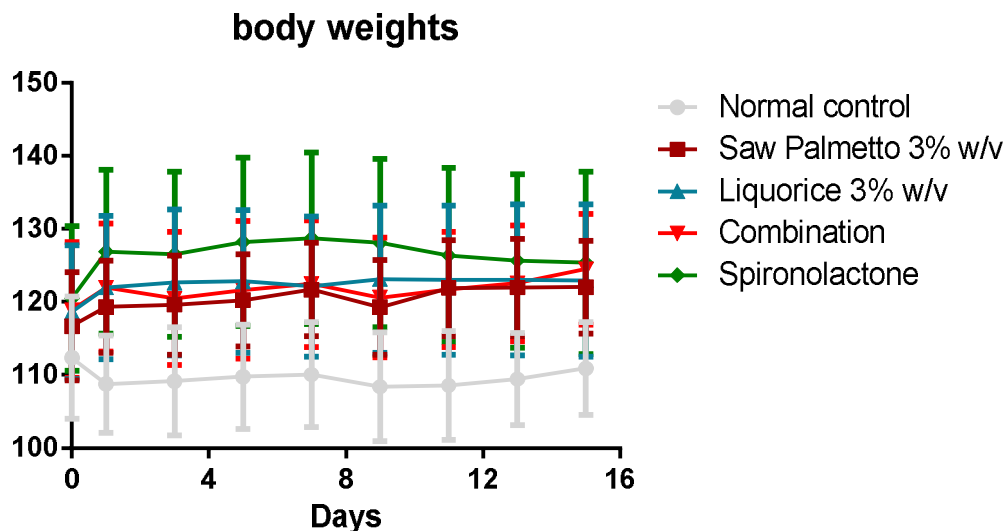
The area of sebaceous glands of left ears of normal animals, Saw palmetto(3%w/v), Liquorice(3%w/v) and Spironolactone (1 mg/kg) was calculated and it was found to be, 0.082 ± 0.011 , 0.088 ± 0.004 , 0.076 ± 0.006 , and 0.061 ± 0.004 mm² respectively.



**P<0.01, Vs Normal control

One way ANOVA followed by Dunnett's test

The area of sebaceous glands of right ears of normal animals, Saw palmetto(3%w/v), Liquorice(3%w/v) and Spironolactone (1 mg/kg) was calculated and it was found to be, 0.087 ± 0.007 , 0.075 ± 0.004 , 0.058 ± 0.006 and 0.052 ± 0.004 mm² respectively.



Body weights were constantly monitored throughout the study and there is no significant decrease in body weights during the study.

- Topical application of saw palmetto 3% w/v, liquorice 3% w/v and combination 3%w/v showed a significant reduction in ipsilateral ear sebaceous gland area.
- Topical application of Spironolactone 5% w/v, showed a significant reduction in ipsilateral ear sebaceous gland area.

CONCLUSION:

In the present study, method validation was carried out for androgen sensitive Syrian hamster ear sebaceous gland model using spironolactone and *Serenoa repens* fruit extract and *Glycyrrhiza glabra* root extract were screened for their sebaceous gland modulation potential in Syrian hamster ear model. Acne vulgaris is the most commonly encountered dermatological disease of pilosebaceous unit. Androgens, which increase during puberty, stimulate the sebaceous gland to produce sebum and cause retention of keratinocytes around the sebaceous hair follicle orifice causing partial to complete blockage and leading to colonization with *Propionibacterium acnes*, which participates in the production of proinflammatory mediators.

A comprehensive approach combining the natural medicine with anti-androgenic activity would be fruitful area for anti-acne therapy. In this context the well documented anti-androgenic herbs like saw palmetto and liquorice have been screened in this study.

The probable mechanism of Saw Palmetto extract is inhibitory activity on 5α - reductase, which catalyses the metabolism of testosterone into its active metabolite DHT. Several in vitro studies carried out

by certain workers on human tissue such as skin fibroblasts, primary cultures of BPH cells and other models which have demonstrated a decrease in DHT levels, thought to be due to inhibition of 5α -reductase types 1 and 2 activity. In an in vivo study conducted on BPH patients DHT levels were significantly decreased throughout the prostate in men receiving Permixon (saw palmetto marketed product) and testosterone levels were elevated, suggesting an inhibitory effect on 5α - reductase.

In the present study topical administration of Hydro alcoholic extract of liquorice, alcoholic extract of saw palmetto and combination group showed a significant reduction (33%, 13.4 and 24% respectively) in the size of hamster ear sebaceous glands. The main focus of this work is to find out the anti acne potential of anti-androgenic herbs. The presented data indicates the usage of lipidosterolic extract of ripe berries of *Serenoa repens* and hydroalcoholic extract of roots of *Glycyrrhiza glabra* for anti acne therapy.

REFERENCES:

1. Dreno B, Poli F. Epidemiology of acne. *Dermatology* 2003; 206:7-10.
2. Gollnick HP, Finlay AY, Shear N. Can we define acne as a chronic disease? If so, how and when? *Am. J. Clin. Dermatol.* 2008; 9(5), 279-284.
3. Eichenfield LF, Leyden JJ. Acne: Current concepts of pathogenesis and approach to rational treatment. *Paediatrician* 1991; 18: 218-23.
4. Ch.C. Zouboulis, L. Xia, H. Akamatsu, H. Seltmann, M. Fritsch, S. Hornemann, R. Rühl, W. Chen, H. Nau, C.E. Orfanos. The Human Sebocyte Culture Model Provides New Insights into Development and Management of Seborrhoea and Acne. *Dermatology* 1998; 196:21-3.

5. Reed, M.J. and Franks, S. Anti-androgens in gynaecological practice (1988). *Baillieres Clin Obstet Gynaecol.* 2(3):581-95.
6. Jonathan R. Matias, and Norman Orentreich. The hamster ear sebaceous glands. I. examination of regional variation by stripped skin planimetry (1983). *The journal of investigative Dermatology*, 81:43-46.
7. Luderschmidt C, Bidlingmaier F, Plewig G: Inhibition of sebaceous gland activity by spiranolactone in Syrian hamster. *J Invest Dermatol* 1982; 78:253-255.
8. Burton JL, Cunliffe WJ, Stafford et al, The prevalence of acne vulgaris in adolescence. *Br J Dermatol* 1971 ; 85:85 119-26.
9. Briley M, Carilla E, Fauran F. Permixon, a new treatment for prostatic benign hyperplasia, acts directly at the cytosolic androgen receptor in rat prostate. *Br. J. Pharmacol* 1983; 79: 327.
10. Schweikert HU, Schluter M, Romalo G. Intracellular and nuclear binding of (3H)-Dihydrotestosterone in cultured genital skin fibroblast of patients with severe hypospadias. *J. Clin. Invest.* 1989; 83: 662-68.
11. Breu W, Hagenlocher M, Redl K, Tittel G, Stadler F, Wagner H. Anti-inflammatory activity of sabal fruit extracts prepared with supercritical carbon dioxide. *In vitro* antagonists of cyclooxygenase and 5-lipoxygenase metabolism. *Arzneimittelforschung* 1992; 42:547-51.
12. Fong YK.et.al., Role of Phytotherapy in men with lower urinary tract symptoms. *Curr. Opin. Urol.* 2005; 15(1) : 45-8.
13. Habib et.al., *Serenoa repens* (permixon) inhibits the 5 α reductase activity in human prostate cancer cell lines without interfering with PSA expression. *Int J Cancer.* 2005; 114(2); 190-4.
14. Wagner H, Flachsbart H, Vogel G. Ube rein neues antiphlogistisches wirkprinzip aus Sabal serrulata I. *Planta Med.* 1981; 41: 244-51.
15. Vela Navarrete R, Garcia Cardoso JV, Barat A, Manzarbeitia F, Lopez Farre A. BPH and inflammation: pharmacological effects of Permixon on histological and molecular inflammatory markers. Results of a double blind pilot clinical assay. *Eur Urol* 2003; 44: 549-55.
16. Wadsworth et.al., Saw palmetto extract suppresses insulin like growth factor 1 signaling and induces stress activated protein kinase/ C- Jun N- terminal kinase phosphorylation in human prostate epithelial cells, *Endocrinology*, 2004; 145(7); 3205-14.