



## **Effect of Oral Administration of Methanolic Extract of *Ocimum gratissimum* on Intestinal Ischemia-Reperfusion Injury in Rats**

J. F. Akinrinmade<sup>1\*</sup> and A. S. Akinrinde<sup>2</sup>

<sup>1</sup>*Department of Veterinary Surgery and Reproduction, Faculty of Veterinary Medicine, University of Ibadan, Nigeria.*

<sup>2</sup>*Department of Veterinary Physiology, Biochemistry and Pharmacology, Faculty of Veterinary Medicine, University of Ibadan, Nigeria.*

### **Authors' contributions**

*All the authors have cordially supported the work and preparation of manuscript. Author JFA designed the study and surgical protocols with interpretations of the results. Author ASA managed the biochemical analyses of the study and computational work and prepared the first draft of the manuscript. All the authors have read and approved the final manuscript.*

**Research Article**

**Received 19<sup>th</sup> June 2013**  
**Accepted 17<sup>th</sup> July 2013**  
**Published 27<sup>th</sup> August 2013**

### **ABSTRACT**

**Aim:** The effect of the methanolic extract of *Ocimum gratissimum* (OG) leaves on the tissue damage induced by ischemia-reperfusion (IR) injury in the rat intestine was investigated.

**Study Design:** Randomized controlled experiment.

**Place and Duration of Study:** Experimental Animal Unit and Faculty of Veterinary Medicine, University of Ibadan, Nigeria from March to May, 2013.

**Methodology:** 18 rats were divided randomly into 3 groups of 6 rats each. Group I served as control; Group II had IR injury by laparotomy with clamping of the Superior mesenteric artery (SMA) for 30 minutes followed by removal of the clamp for 45 minutes; Group III was pre-treated orally for 7 days with methanolic extract of *Ocimum gratissimum* (MEOG) followed by IR injury. Sections of the duodenum and ileum were cut for histopathological examination. The remaining tissues were processed for the determination of biochemical markers of oxidative stress including Hydrogen peroxide (H<sub>2</sub>O<sub>2</sub>), Malondialdehyde (MDA) and Glutathione concentrations.

**Results:** Mean values of MDA and H<sub>2</sub>O<sub>2</sub> levels were significantly elevated (P=0.004 and

\*Corresponding author: Email: [fadeyemiakinrinmade@yahoo.com](mailto:fadeyemiakinrinmade@yahoo.com);

P=0.03, respectively) in intestinal tissues following IR compared to control while reduced glutathione (GSH) levels were not significantly altered. OG (500mg/kg) caused significant reduction (P=0.02 and P=0.04) in MDA concentrations and H<sub>2</sub>O<sub>2</sub> generation, respectively compared with the IR group. Histopathological examination revealed erosions and stunting of the villi tips in the duodenum and ileum, with severe mononuclear infiltration at the mucosal surface in the IR group. No visible lesions were observed in the intestine of the control group, with no significant alterations in the intestinal epithelium of the OG-treated rats.

**Conclusion:** The results suggest that OG may provide some protection against intestinal mucosal injury induced by ischemia-reperfusion, through its anti-oxidative effects.

**Keywords:** *Ocimum gratissimum*; ischemia; reperfusion; intestine; antioxidant; rats.

## 1. INTRODUCTION

The syndrome of ischemia reperfusion (IR) plays a fundamental role in the pathophysiology of several clinical-surgical conditions [1], including those involving the gastro-intestinal system. Intestinal ischemia may be caused by intestinal intussusception, acute mesenteric arterial occlusion and hemodynamic shock [2]. Ischemia in the intestine may also occur by means of arterial occlusive processes such as thrombi or embolisms, or more commonly by non-occlusive processes that cause low mesenteric flow such as in cardiac insufficiency, sepsis or administration of alpha-adrenergic agents or digitalis [3]. Blockage of arterial blood supply to tissues causes alterations in tissues by restricting oxygen supply and impeding aerobic energy metabolism, with resultant tissue injury [4].

Re-introduction of oxygen to the tissues during re-perfusion can exacerbate tissue injury caused by ischemia with release of pro-inflammatory substances and the formation of oxygen-derived free radicals [5]. Reperfusion of ischemic tissues results in the formation of toxic reactive oxygen species (ROS), including superoxide anions, hydroxyl radicals, hypochlorous acid (HOCl), hydrogen peroxide (H<sub>2</sub>O<sub>2</sub>), and nitric oxide-derived peroxynitrite.

Pathophysiological mechanisms for the generation of ROS in ischemia-reperfusion injury have been described [6]. During ischemia, cellular ATP is degraded to form hypoxanthine. Normally, hypoxanthine is oxidized by xanthine dehydrogenase to xanthine. However, during ischemia, xanthine dehydrogenase is converted to xanthine oxidase. Unlike xanthine dehydrogenase, which uses nicotinamide adenine dinucleotide as its substrate, xanthine oxidase uses oxygen and therefore, during ischemia, is unable to catalyze the conversion of hypoxanthine to xanthine, because of reduced levels of oxygen resulting in a buildup of excess tissue levels of hypoxanthine. Therefore, when oxygen is re-introduced during reperfusion, conversion of the excess hypoxanthine by xanthine oxidase results in the formation of toxic ROS.

Reactive oxygen species, such as superoxide and hydroxyl radicals are known to cause tissue damage directly or indirectly [7]. Early research supports the hypothesis that the intestine appears to be the most sensitive to IR injury among the other internal organs [8,9]. Since the phenomenon of ischemia and reperfusion is almost inevitable in many surgical procedures, efforts have focused on minimizing the extent of damage to tissues produced as a result of the process. Research efforts in this direction have focused mainly on the use of antioxidant compounds. Antioxidants are substances that can delay or inhibit the oxidation of lipids or other molecules by inhibiting the initiation or propagation of oxidative chain reactions

as a result of reactive oxygen species [10]. Antioxidants protect other molecules from oxidation when they are exposed to free radicals and reactive oxygen species [11]. Several antioxidant compounds have been experimentally studied for their potential in ameliorating the damage produced during IR injury in intestinal tissues. They include Vitamin E, Vitamin C, Mannitol, dimethylthiourea, allopurinol, N-acetyl cysteine, Iron chelators, among others [5, 12, 13, 14].

Pre-treatment of patients prior to surgery with potent and relatively cheap antioxidants may represent a viable means of preventing extensive damage to tissue that result from clamping of major vessels and re-establishment of blood flow that characterizes most surgeries associated with gastro-intestinal tract tissues. Recently, there has been a great increase in interest in natural antioxidant phytochemicals of plant origin since they are viewed as promising therapeutic drugs for free radical pathologies [15,16].

*Ocimum gratissimum* (OG) is an erect herb belonging to the family Lamiaceae. The plant is indigenous to tropical areas, including India and West Africa. In Nigeria, It is found in the Savannah and coastal areas [17]. It has a characteristic pleasant aroma due to its volatile oil [18]. The plant is well known in Nigeria folk medicine to manage different diseases, including rheumatism, paralysis, epilepsy, diarrhea, influenza and gonorrhoea [19, 20]. In addition, the plant is used as a spice and condiment in the southern part of Nigeria. OG is cultivated widely in the tropics and is reported for several therapeutic properties which include anti-diarrhea effects [21]; gastro-protective properties [22]; anti-bacterial activity [23]; anti-fungal properties [24]; anti-mutagenic activity [25], etc.

Methanolic extracts of OG has been observed to possess potent 2,2-diphenyl-1-picrylhydrazyl (DPPH) radical, hydroxyl radical, superoxide radical and nitric oxide radical scavenging activities [26]. It was found to be able to prevent lipid peroxidation and is thought to have huge potential as a therapeutic agent for the control of oxidative damage caused by reactive oxygen species.

The aim of this study was to determine whether the methanolic extract of *Ocimum gratissimum* (MEOG) could attenuate intestinal ischemia-reperfusion injury in rats.

## 2. MATERIALS AND METHODS

### 2.1 Collection and Identification of Plant Material

*Ocimum gratissimum* (OG) leaves were obtained within the premises of the University of Ibadan, Nigeria. They were botanically identified and authenticated by Mr. Esimenkhuai Donatus and a voucher specimen was deposited at the Department of Botany, University of Ibadan, Nigeria.

### 2.2 Extraction

Fresh leaves of OG were cleaned, air-dried and crushed into coarse powder using an electric blender. The powdered leaf was macerated in 2.5 litres of methanol for 24 hours and agitated at intervals. The mixture was filtered thereafter and filtrate was concentrated in vacuo at 40°C using a rotary evaporator to give a residue methanolic extract of OG.

### 2.3 Animal Protocol

Male Wistar rats (150-200g) obtained from the Experimental Animal Unit, Faculty of Veterinary Medicine, University of Ibadan, Nigeria, were used for this study. They were kept in a well-ventilated animal house and provided with rat pellets and water ad-libitum for the period of the study. The animals received humane care according to the criteria outlined in the 'Guide for the care and Use of Laboratory Animals' published by the National Institute of Health. The ethic regulations were followed in accordance with National and Institutional guidelines of the University of Ibadan Ethical Committee for the protection of animal welfare during experiments.

### 2.4 Experimental Design

18 rats were randomly assigned to 3 groups of 6 rats per group. Group I received distilled water in the same volume as that of treated rats; group II animals were the IR group. Rats in group III were pre-treated with methanolic extract of *Ocimum gratissimum* (MEOG, 500mg/kg) for 7 days, before induction of IR. The dose of MEOG was chosen based on previous studies [22]. MEOG was administered orally using a calibrated 1 mL syringe with attached cannula.

### 2.5 Induction of Ischemia-Reperfusion Injury

Rats were anesthetized with Ketamine (40mg/kg; i.m.) and Xylazine (5mg/kg; i.m.). A ventral midline laparotomy was performed after shaving and local cleaning with antiseptic solution. To induce ischemia, the superior mesenteric artery (SMA) was dissected out and carefully clamped with an atraumatic micro-vascular clip. Thereafter, the intestines were returned into the abdomen and the incision was closed temporarily with Prolene (Ethicon®). The clip was removed following 30 minutes of occlusion of the SMA and reperfusion was allowed for 45 minutes. The animals were thereafter sacrificed by cervical dislocation. The small intestines from the duodenum to the ileum were removed. They were everted inside out. Portions of the ileum (about 5 cm proximal to the cecum) and duodenum (about 5 cm distal to the stomach) were cut and fixed in 4% formalin and embedded in paraffin for section and histological assessment, which was performed by an independent assessor who was blind to the treatments. The remaining segments of the small intestine were washed in normal saline. These were homogenized in 50mM Tris-HCl buffer (pH 7.4) containing 1.15% Potassium chloride and the homogenate was centrifuged at 10,000g for 15 minutes at 4°C. The supernatant was collected for the estimation of biochemical parameters.

### 2.6 Biochemical Assays

Supernatants from the intestinal homogenate were used in the estimation of Malondialdehyde (MDA) content, hydrogen peroxide (H<sub>2</sub>O<sub>2</sub>) generation and reduced glutathione (GSH) concentration. GSH was determined at 412nm using the method described by Beutler et al [27]. Hydrogen peroxide generation was assessed by the method of [28]. MDA as an index of lipid peroxidation in the intestinal tissues was quantified according to the method described by Farombi et al [29] and expressed as micromoles of MDA/g tissue, using a molar extinction coefficient of  $1.56 \times 10^5 \text{ M}^{-1} \text{ cm}^{-1}$  [30].

## 2.7 Statistical Analysis

Statistical analyses were done using one-way analysis of variance (ANOVA) to compare the experimental groups. Student's t-test with SPSS (Student version 7.5, SPSS Inc. UK) was also used for comparisons between the groups and P values less than 0.05 were considered statistically significant.

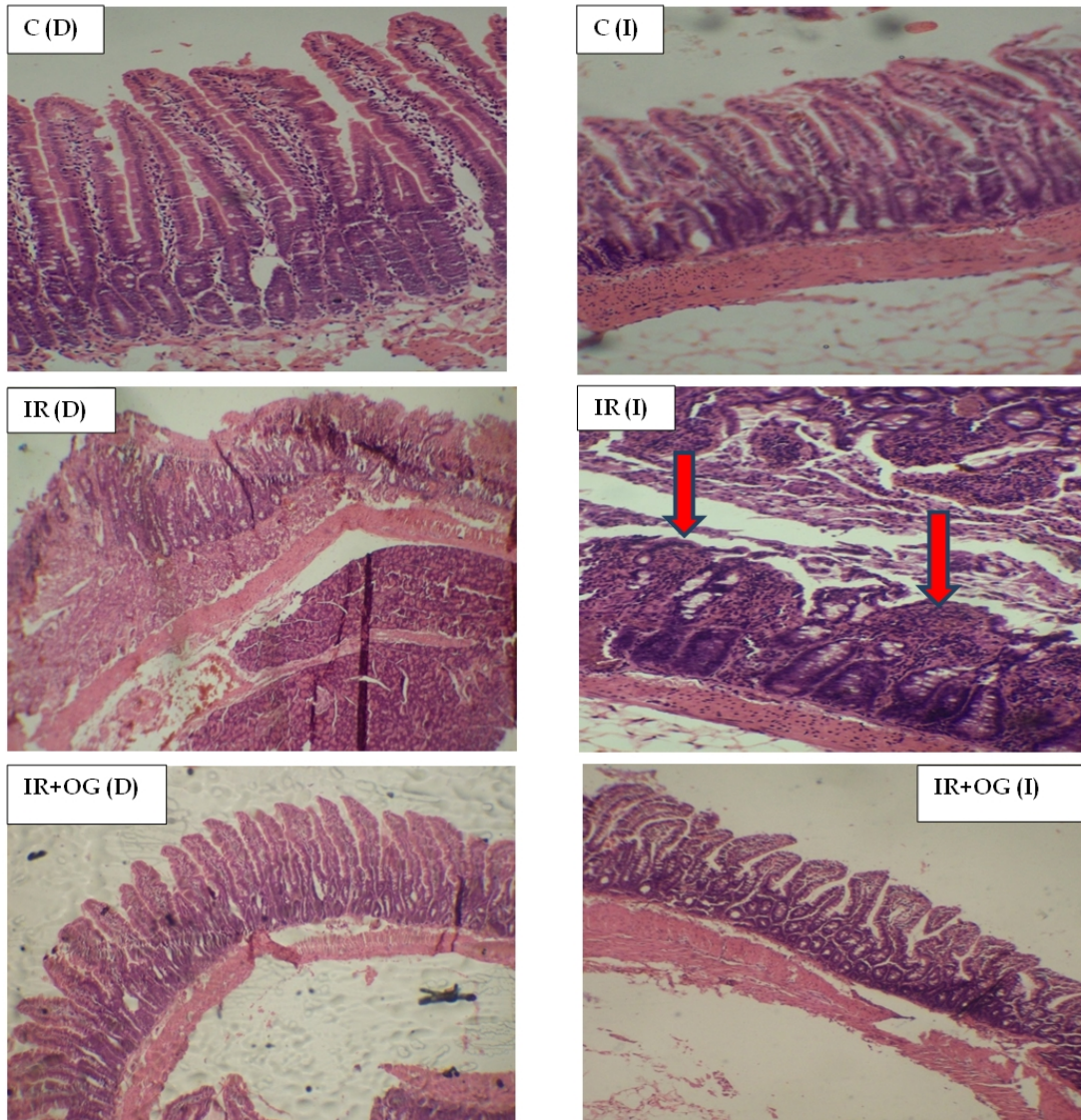
## 3. RESULTS

### 3.1 Histopathology

Details of the histological appearance of the mucosa of duodenum and ileum in the different groups are presented in Table 1. Representative photomicrographs are presented in Fig. 1. Injury to the intestinal mucosa was very evident and severe in the IR group compared with control rats and those pre-treated with OG.

**Table 1. Description of Histological appearance of duodenum and ileum mucosae in the experimental groups**

<b>Group</b>	<b>Histological appearance</b>
C(D)	Normal appearance of villi and glands; no visible lesions seen.
C(I)	Normal appearance of villi and glands; no visible lesions seen.
IR(D)	Moderate erosion at the villi tips; they are covered with pink staining material.
IR(I)	Moderate erosion of the mucosa. The villi are severely stunted. There is severe mononuclear cellular infiltration at the mucosal surface.
IR+OG(D)	Normal epithelium; no lesions observed.
IR+OG(I)	Normal epithelium; no lesions observed.

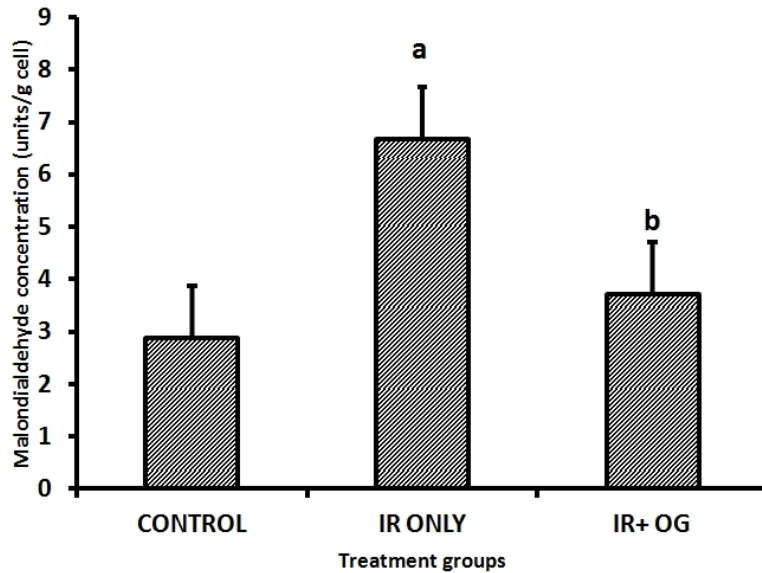


**Fig. 1. Histological appearance of the small intestine in rats**

C: control; IR: Ischemia/reperfusion; IR + OG: Ischemia reperfusion + *Ocimum gratissimum*; D: duodenum; I: ileum. (Mag. X 100)

### 3.2 Biochemical Parameters

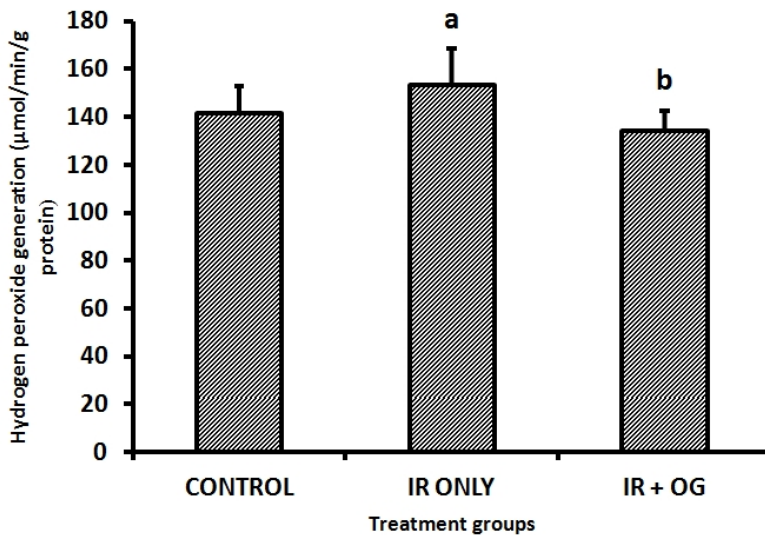
MDA levels were increased significantly ( $P=.004$ ) in the IR group ( $6.68\pm 1.02$ ), compared to control ( $2.87\pm 0.96$ ). However, significant reduction ( $P=.03$ ) in MDA levels were observed in the rats pre-treated with OG ( $3.72\pm 0.92$ ), compared to IR-treated rats (Fig. 2).



**Fig. 2. Effect of *Ocimum gratissimum* (500mg/kg) on Malondialdehyde concentration in acute intestinal IR injury in rats (mean±standard deviation)**

<sup>a</sup>Significant difference ( $p<0.05$ ) versus control; <sup>b</sup>Significant difference ( $p<0.05$ ) versus IR only

In a similar fashion, hydrogen peroxide levels were significantly higher ( $P=0.02$ ) in IR group ( $153.33\pm0.76$ ) compared to the control ( $141.67\pm0.52$ ). Pre-treatment with OG also caused significant reduction ( $P=0.04$ ) in Hydrogen peroxide generation in group III rats ( $134.10\pm0.49$ ) compared to the IR group (Fig. 3).

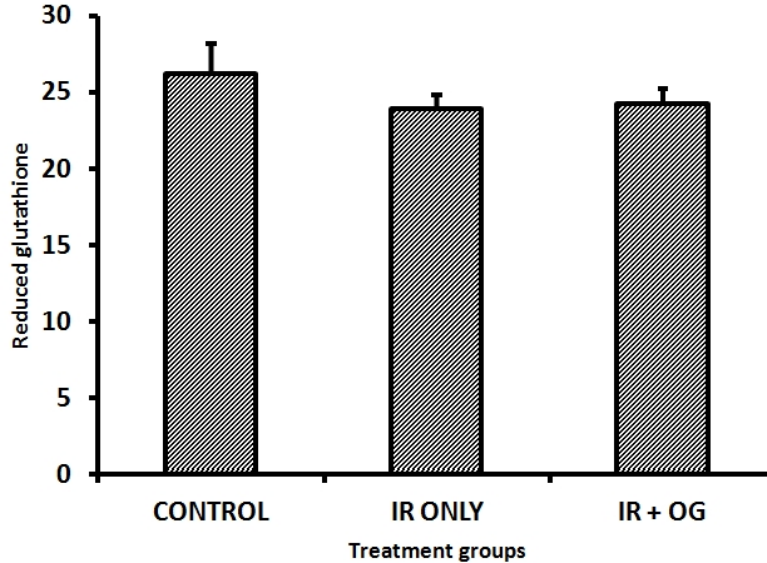


**Fig. 3. Effect of *Ocimum gratissimum* (500mg/kg) on Hydrogen peroxide generation in acute intestinal IR injury in rats (mean±standard)**

<sup>a</sup>Significant difference ( $p<0.05$ ) versus control; <sup>b</sup>Significant difference ( $p<0.05$ ) versus IR only.



Levels of GSH were reduced insignificantly ( $P=0.15$ ) in the IR group ( $23.90\pm0.57$ ) when compared to control rats ( $26.20\pm0.57$ ). GSH levels in OG-treated rats ( $24.30\pm0.35$ ) were not significantly different ( $P=0.28$ ) from those of the IR-group (Fig. 4).



**Fig. 4. Effect of *Ocimum gratissimum* (500mg/kg) on reduced glutathione (GSH) concentration in acute intestinal IR injury in rats (mean±standard)**

<sup>a</sup>Significant difference ( $p<0.05$ ) versus control; <sup>b</sup>Significant difference ( $p<0.05$ ) versus IR only

#### 4. DISCUSSION

Ischemia and reperfusion of the small intestine can provoke a number of consequences which include rupture of the mucosa barrier, bacterial translocation and the activation of inflammatory responses, together with electrolyte and acid-base disturbances which can be manifested in distant organs [31, 32].

Early studies recognized the involvement of oxygen-derived free radicals in the pathogenesis of ischemia-reperfusion-induced damage in the gastro-intestinal tract [33, 34, 35]. Superoxide radicals and hydrogen peroxide are considered to be the major free radicals contributing to gastro-intestinal injury after ischemia-reperfusion injury [36]. In addition, the oxidant stress in ischemia-reperfusion injury is accompanied by consumption of reduced glutathione with the formation of oxidized glutathione in the gastro-intestinal mucosa [37, 38].

In the present study, acute IR injury induced in the intestinal mucosa produced a significant increase in hydrogen peroxide generation. Dismutation of the superoxide radical, either spontaneously or catalyzed by superoxide dismutase (SOD) produces hydrogen peroxide. Typically, the reaction of superoxide radical and hydrogen peroxide, both of which are relatively less reactive, produces the highly reactive and harmful hydroxyl radical (OH) by the Haber-Weiss reaction. OH<sup>•</sup> causes tissue damage by stimulating chain reactions involving attack on membrane phospholipids, resulting in lipid peroxidation [9]. In line with the increase in hydrogen peroxide generation, there was also a corresponding significant increase in malondialdehyde (MDA) contents of the intestinal mucosa of rats subjected to IR



injury in this study. GSH levels in this study were not significantly altered, although there was a decrease in GSH levels in the IR group compared to control rats. These markers point to significant oxidative stress in the intestinal tissues following the induction of ischaemia-reperfusion injury.

The intestine has been observed to be very susceptible to IR stress as it is composed of labile enterocytes that are easily injured by episodes of ischemia and subsequent reperfusion causing further damage to the intestinal mucosa [39]. It is known that the enterocytes located at the villi tips are more sensitive to the effect of ischemia than those at the crypts, because they are located at the end of blood supply of a central arteriole and so experience a relative lack of collateral blood flow [40]. There is, therefore, the likelihood of lower partial pressures of oxygen in the distal enterocytes when compared with those of the crypts.

The histological examination of the intestinal mucosa from rats subjected to IR injury in this study revealed erosions of the villi tips in both the duodenum and ileum segments with stunting of the villi and severe mononuclear cell infiltration at the mucosal surface. On the contrary, intestinal mucosa of control rats were completely normal.

Pre-treatment of rats daily for 7 days with the methanolic extract of *Ocimum gratissimum* (500mg/kg) produced significant reductions in Hydrogen peroxide levels and MDA concentration in the intestinal tissues compared to those subjected to IR only. GSH levels in those rats pre-treated with MEOG were not significantly affected. Previous phytochemical studies on leaves of OG have shown that it contains alkaloids, tannins, saponins, flavonoids, sterols among others. Tannins and flavonoids, especially, are compounds with antioxidant properties [41]. The dosage of MEOG was carefully chosen according to previous acute toxicity studies performed on the extract [22]. The histological appearance of the mucosa of duodenum and ileum in rats pre-treated with MEOG also appeared largely normal.

From the results of this study, the MEOG appears to hold promise as a potent antioxidant in ameliorating oxidant stress induced by ischemia-reperfusion injury in the intestinal mucosa of rats. If properly standardized, the extract could be a good addition to the pre-medication regimen prescribed for patients undergoing gastro-intestinal elective surgery and possibly a good supplement in the post-surgical management of the same category of patients.

#### **4. CONCLUSION**

The inevitability of occlusion and re-introduction of blood supply during surgical procedures involving the gastro-intestinal tissues requires adequate intervention to manage the accompanying oxidant stress that may cause tissue damage following surgery. *Ocimum gratissimum*, from the present study showed promise for attenuating ischemia-reperfusion injury in rats and could therefore be further explored for this beneficial effects.

#### **CONSENT**

Not applicable.

## ETHICAL APPROVAL

All authors hereby declare that "Principles of laboratory animal care" (NIH publication No. 85-23, revised 1985) were followed, as well as specific national laws where applicable. All experiments have been examined and approved by the appropriate ethics committee.

## COMPETING INTERESTS

Authors have declared that no competing interests exist.

## REFERENCES

1. Cerqueira NF, Hussni CA, Yoshida WB. Pathophysiology of mesenteric ischemia/reperfusion: a review. *Acta Cirurgica Brasileira*. 2005;20(4):336-343.
2. Steffanutti G, Vejchapipat P, Williams SR, Pierro A, Eaton S. Heart energy metabolism after intestinal ischemia and reperfusion. *J. Pediatr Surg*. 2004;39:179-83.
3. Storey RJ, Cunningham CG. Acute mesenteric ischemia. *Surgery*. 1993;114:489-90.
4. Grace PA. 1994. Ischemia-reperfusion injury *Br. J. Surg*. 1994;81:637-47.
5. Cuzzocrea S, Chatterjee P, Mazzon E, Dugo L, De Sarro A, Van de Loo FAJ, Caputi AP, Thiernemann C. Role of induced nitric oxide in the initiation of the inflammatory response after post-ischemic injury. *Shock*. 2002;18:169-76.
6. Collard CD and Gelman S. Pathophysiology, Clinical Manifestations, and Prevention of Ischemia-Reperfusion Injury. *Anesthesiology*. 2001;94:1133-8.
7. Lee JL, Lin CT, Chueh LL, Chang CJ. Autocrine/paracrine secreted Frizzled-related protein 2 induces cellular resistance to apoptosis: a possible mechanism of mammary tumorigenesis. *J. Biol. Chem*. 2004;279:14602-14609.
8. Granger DN, Hollwarth ME, Parks DA. Ischemia-reperfusion injury: role of oxygen-derived free radicals. *Acta. Physiol. Scand. Suppl*. 1986;548:47-63.
9. Granger DN. Role of xanthine oxidase and granulocytes in ischemia-reperfusion injury. *Am. J. Physiol*. 1988;255:H1269-H1275.
10. Gulcin I. Antioxidant properties of resveratrol: A structure-activity insight. *Innovative Food Sci. Emerging Technol*. 2010;11:210-218.
11. Halliwell B, Gutteridge JMC. Free radicals, antioxidants and human diseases: Where are we now? *J. Lab. Clin. Med*. 1992;119:598-620.
12. Schoenberg MH, Berger HG. Reperfusion injury after intestinal ischemia. *Crit. Care Med*. 1993;9:1376-1385.
13. Barry MC, Grace PA. Ischemia reperfusion injury. *Surgery*. 1997;15:68-72.
14. Balogh N, Krausz F, Levai P, Ribiczeyne PS, Vajdovich P, Gaal T. Effect of deferoxamine and L-arginine treatment on lipid peroxidation in an intestinal ischaemia-reperfusion model in rats. *Acta Vet Hung*. 2002;50(3):343-356
15. Cuzzocrea S, Mazzon E, Costantino G, Serraino I, De Sarro A, Caputi AP. Effects of N-acetylcysteine in a rat model of ischemia and reperfusion injury. *Cardiovasc Res*. 2000;47(3):537-548.
16. Kitt DD, Wijewickreme AN, Hu C. Antioxidant properties of a North American ginseng extract. *Mol. Cell Biochem*. 2000;203:1-10.
17. Nogochi NE. Phenolic antioxidants; a rationale for design and evaluation of novel antioxidant drugs for atherosclerosis. *Free Rad. Biol. Med*. 2000;28:1538-1546.
18. Prabhu KS, Lobo AA, Shirwaikar AA, Shirwaikar A. *Ocimum gratissimum*: A Review of its chemical, Pharmacological and Ethnomedicinal Properties. *The open Complementary Medicine Journal*. 2009;1:1-15.

19. Dalziel JM. Plants Description, Useful Plants of West Tropical Africa. 1993;3:431-433.
20. Dhawan BN, Patnik GR, Rastogy RAT, Singh KK, Tandol, TS. Screening of Indian plants for biological activity. YL India Exp. B. 1997;15:108.
21. Sofowora LA. Medicinal plants and traditional medicine Africa. Spectrum Books, Ltd, Ibadan. 1993;55-71.
22. Offiah VN, Chikwendu UA. Antidiarrhoeal effects of *Ocimum gratissimum* leaf extract in experimental animals. Journal of Ethnopharmacology. 1999;68:327-330.
23. Akah PA, John-Africa L, Nworu CS. Gastro-protective properties of *Ocimum gratissimum* L. against experimental ulcers in rat. Int. J. Pharmacol. 2007;3:461-467.
24. Orafidiya OO, Elujoba AA, Iwalewa FO, Okeke IN. Evaluation of antidiarrhea properties of *Ocimum gratissimum* volatile oil and its activity against enteroaggregative *Escherichia coli*. Pharm. Pharmacol. Lett. 2000;10:9-12.
25. Njoku CJ, Asuzu IU. The anthelmintic effects of the leaf extract of *Ocimum gratissimum* (L.). Phytomedicine. 1998;5(6):485-8.
26. Obaseki-Ebor EE, Odukora K, Telikepalli H, Mtscher LA, Shankel DM. Antimutagenic activity of extracts of leaves of four common edible vegetable plants in Nigeria (West Africa). Mutat. Res. 1993;302:109-117.
27. Awah FM, Verla AW. Antioxidant activity, nitric oxide scavenging activity and phenolic contents of *Ocimum gratissimum* leaf extract. J. Medicinal Plants. Res. 2010;4(24):2479-2487.
28. Beutler E, Duron O, Kelly BM. Improved method for the determination of blood glutathione. J. Lab Clin. Med. 1963;61:882-888
29. Wolff SP. Ferrous ion oxidation in the presence of ferric ion indicator xylenol orange for measurement of hydroperoxides. Methods Enzymol. 1994;233:182-189
30. Farombi EO, Tahnteng JG, Agboola AO, Nwankwo JO, Emerole GO. Chemoprevention of 2-acetylaminofluorene-induced hepatotoxicity and lipid peroxidation in rats by Kolaviron- a *Garcinia kola* seed extract. Food Chem Toxicol. 2000;38:535-541
31. Adam-Vizi V, Seregi M. Receptor dependent stimulatory effect of noradrenalin on Na<sup>+</sup>-K<sup>+</sup> ATPase in rat brain homogenate. Role of lipid peroxidation. Biochem. Pharmacol. 1982;31: 2231-2236.
32. Joao AS, Alencar SSS, Medeiros AC, Diniz SOF, Cardoso VN, Brandt CT. Translocation of <sup>99m</sup>Tc labeled bacteria after intestinal ischemia and reperfusion. Acta Cir. Bras. 2004. [serial online] v. 19. Disponível em: <http://www.scielo.br/acb> [also in CD-ROM]. Acesso em: 15 ago 2004
33. Turnage RH, Guice KS, Oldham KT. Endotoxemia and remote organ injury following intestinal reperfusion. J. Surg. Res. 1994;56:571-8
34. Granger DN, Rutili G, McCord JM. Superoxide radicals and feline intestinal ischemia. Gastroenterology 1981;81:22-29
35. Parks DA, Bulkley GB, Granger DN, Hamilton SR, McCord JM. Ischemic injury in the cat small intestine: role of superoxide radicals. Gastroenterology. 1982;82:9-15.
36. Itoh M, Guth PH. Role of oxygen-derived free radicals in hemorrhagic shock-induced gastric lesions in the rats. Gastroenterology. 1985;88:1162-1168.
37. Yoshikawa T, Naito Y, Tanigawa T, Yoneta T, Yasuda M, Ueda S, Oyamada H, Kondo M. Effect of zinc-carnosine chelate compound (Z-103), a novel antioxidant, on acute gastric mucosal injury induced by ischemia-reperfusion in rats. Free Radic. Res. Commun. 1991;14:289-296
38. Younes M, Mohr A, Schoenberg MH, Schildberg FW. Inhibition of lipid peroxidation by superoxide dismutase following regional intestinal ischemia and reperfusion. Res. Exp. Med. (Berl). 1987;187:9-17.

39. Sasaki M, Takahashi Joh. Oxidative stress and Ischemia-reperfusion injury in gastrointestinal tract and antioxidant protective agents. *J. Clin. Biochem Nutr.* 2007;40(1):1-12.
40. Takeyoshi I, Zhang S, Nakamura K, Ikoma A, Zhu Y, Starzl TE, Todo S. Effect of ischemia on the canine large bowel: a comparison with the small intestine; 1996.
41. Olayinka OI, Nta HA, Adeagbo G. Effect of natural antioxidant – *Ocimum gratissimum* in modulating neurodegenerative changes in rats fed with high concentration of lead acetate. *J. Med. Plants Res.* 2011;5(13):2743-2747.

---

© 2013 Akinrinmade and Akinrinde; This is an Open Access article distributed under the terms of the Creative Commons Attribution License (<http://creativecommons.org/licenses/by/3.0>), which permits unrestricted use, distribution, and reproduction in any medium, provided the original work is properly cited.

*Peer-review history:*

*The peer review history for this paper can be accessed here:*  
<http://www.sciencedomain.org/review-history.php?iid=253&id=13&aid=1928>