

Retrospective Analysis of Patients with Juvenile Laryngeal Papillomatosis in ENT-CCF at CNHU-HKM/Benin: Literature Review.

Lawson Afouda S¹, Gankpè O¹, Avakoudjo F², Medji S¹, Guézo D¹, Vodouhè U², do Santos Zounon A¹, Rijckaert M³, Van Der Vorst S³, Lawson G³ and Adjibabi W¹

¹Ear Nose Throat - ENT-CCF Department, National University Hospital Center HKM-Cotonou (Benin)

²ENT-CCF Department, Suru-Léré Zone Hospital, Cotonou (Benin)

³ENT Department, Catholic University Hospital of Louvain, NAMUR (Belgium)

***Corresponding Author:** Lawson Afouda Sonia, Ear Nose Throat - ENT-CCF Department, National University Hospital Center HKM-Cotonou (Benin).

Received: September 07, 2023; **Published:** September 21, 2023

Abstract

Objective: Laryngeal papillomatosis is a rare benign tumor affecting the laryngeal mucosa. Its precise etiopathogenesis remains unknown to date. The aim of this study was to investigate the epidemiological profile, diagnostic characteristics, therapeutic approaches, and outcomes of patients with laryngeal papillomatosis.

Method: This was a descriptive cross-sectional study conducted at the Ear, Nose, and Throat (ENT) Clinic of CNHU-HKM/BENIN from January 1, 2010, to December 31, 2020. Laryngeal papillomatosis was confirmed through laryngeal biopsy. The variables studied included frequency, age, gender, clinical presentation, paraclinical findings, therapeutic approaches, and patient outcomes.

Results: Twenty-eight (28) cases of laryngeal papillomatosis were identified over an 11-year period, resulting in an annual incidence rate of 2.54 cases. The average age of the patients was 13.74 years, with a range from 19 months to 45 years. Females were more commonly affected, with a sex ratio of 0.6 (15/24). Dyspnea was the primary reason for consultation in 17 out of 24 patients, even though all patients initially reported hoarseness as a symptom. In nine out of seventeen (09/17) patients, emergency tracheostomy was required due to severe laryngeal dyspnea at stage III according to the Chevalier Jackson and Pineau classification. Laryngeal biopsy was performed in all patients, confirming the diagnosis of laryngeal papillomatosis. Surgical debulking was performed in all patients, and in two cases, it was combined with CO2 laser vaporization of lesions outside of our hospital. Recurrences were frequent, ranging from 1 to 9, with at least one recurrence observed in 13 out of 24 patients. Two patients regained a normal voice, while the remaining patients experienced varying degrees of persistent phonatory sequelae. Four (04) patients were successfully decannulated, but one out of the five (1/5) remaining patients with a tracheostomy tube unfortunately passed away.

Conclusion: Laryngeal papillomatosis is a condition that is predominantly common in children. This study conducted in Benin highlights that the primary treatment approach for this condition is surgical, specifically through endoscopy. The limitation of available medical equipment and technology hinders the exploration of other therapeutic alternatives.

Keywords: Dysphonia; Dyspnea; Laryngeal Papillomatosis; Peeling; Tracheotomy

Citation: Lawson Afouda S, Gankpè O, Avakoudjo F, Medji S, Guézo D, Vodouhè U, do Santos Zounon A, Rijckaert M, Van Der Vorst S, Lawson G and Adjibabi W. (2023). Retrospective Analysis of Patients with Juvenile Laryngeal Papillomatosis in ENT-CCF at CNHU-HKM/Benin: Literature Review. *Journal of Otolaryngology - Head and Neck Diseases* 5(1).

Introduction

Laryngeal papillomatosis, a condition with low incidence, is a benign tumor proliferation that occurs within the laryngeal mucosa. Although its etiopathogenesis remains unknown, the etiological role of the papillomavirus has been demonstrated, even though the primary mechanism remains uncertain. Subtypes HPV 6 and HPV 11 are responsible for laryngeal papillomatosis [1]. Clinical signs allow suspicion of the diagnosis of laryngeal papillomatosis. Patients initially present with intermittent dysphonia that eventually leads to aphonia. Dyspnea follows dysphonia and is accompanied by noises resembling snoring or stridor [2]. Laryngeal papillomatosis has been known for a long time, but modern medical advancements have not yet definitively mastered its treatment, leading to frequent recurrences. The purpose of this study was to examine the epidemiological profile, diagnostic characteristics, therapeutic approaches, and progression of patients with laryngeal papillomatosis.

Materials and Methods

The study was conducted at the ENT-CCF University Clinic of CNHU-HKM. Data were collected from medical records of selected patients, and information was extracted from consultation, hospitalization, and operating room registers, which was then transcribed onto data collection forms.

This was a descriptive cross-sectional study that spanned from January 1, 2010, to December 31, 2020, and included all patients who were treated for laryngeal papillomatosis in the department.

Patients of all ages who sought medical care at the clinic during the study period and were diagnosed with laryngeal papillomatosis based on medical history and clinical data, confirmed by anatomopathological examination, were included in the study.

All patients underwent microforceps debulking, and in some cases, laser vaporization was also performed. Tracheotomy for life-saving purposes was indicated for some patients with severe laryngeal dyspnea at stage III according to the Chevalier Jackson and Pineau classification.

Patient progress was monitored through regular check-ups and evaluated based on their clinical condition. Progress was considered favorable in cases of improved voice, respiration, absence of postoperative complications, and unfavorable in cases of complications or death.

Exclusion criteria included patients who did not undergo nasofibroscopy and/or laryngoscopy with biopsy, or those whose anatomopathological examination results did not support a diagnosis of laryngeal papillomatosis despite strong clinical suspicion.

Non-probabilistic convenience sampling was used, with laryngeal papillomatosis as the dependent variable and socio-demographic, clinical, paraclinical, therapeutic, and evolutionary criteria as independent variables.

Data collected were entered into the Google Drive platform using Google Forms. Statistical analysis was performed using STAT 14, and graphical representations were created using Excel 2016.

Results

Epidemiological Aspects

Over an 11-year period, we identified 28 confirmed cases of laryngeal papillomatosis, resulting in an average of 2.54 cases per year. Despite histopathological confirmation of the lesion, twenty-four (24) patients met all inclusion criteria. The average age of the patients was 13.74 years, with a range from 19 months to 45 years. Females predominated in our sample with 15 out of 24 cases, and the sex ratio was 0.6. At the time of diagnosis, the majority of patients were school-age children (17 out of 24 cases).

Diagnostic Aspects

Ten (10) patients sought consultation within a range of 1 to 6 months. Dyspnea was the primary reason for consultation in 17 out of 24 patients, but initial dysphonia was reported by all patients. Among patients who presented with laryngeal dyspnea, nine (09) were at stage III according to the Chevalier Jackson and Pineau classification.

Suspension laryngoscopy under general anesthesia allowed visualization of a well-mobile glottis. Furthermore, it identified mature-looking lesions, either solitary or clustered, sometimes obstructing the laryngeal airway. The glottis was the most affected location in twelve (12) cases, while the lesions involved the glottis-subglottic region in eight (08) cases. Except for one (01) case with extension into the esophageal mouth, no other extra-laryngeal extension sites were found in the other patients. We considered a benign laryngeal tumor while not ruling out malignant laryngeal tumors. The early onset of symptoms at a young age, the chronic nature of initial dysphonia, and glottic mobility during suspension laryngoscopy led us to suspect laryngeal papillomatosis, the most common benign laryngeal tumor in children.

Citation: Lawson Afouda S, Gankpè O, Avakoudjo F, Medji S, Guézo D, Vodouhè U, do Santos Zounon A, Rijckaert M, Van Der Vorst S, Lawson G and Adjibabi W. (2023). Retrospective Analysis of Patients with Juvenile Laryngeal Papillomatosis in ENT-CCF at CNHU-HKM/Benin: Literature Review. *Journal of Otolaryngology - Head and Neck Diseases* 5(1).

Histologically, examination of biopsy specimens from laryngeal lesions revealed papillomas. Histologically, it consists of neoplastic squamous epithelium with exophytic finger-like projections covering fibrovascular support nuclei. No malignant lesions were found. Human Papillomavirus (HPV) testing was conducted in 02 patients, and the results confirmed the presence of the virus.

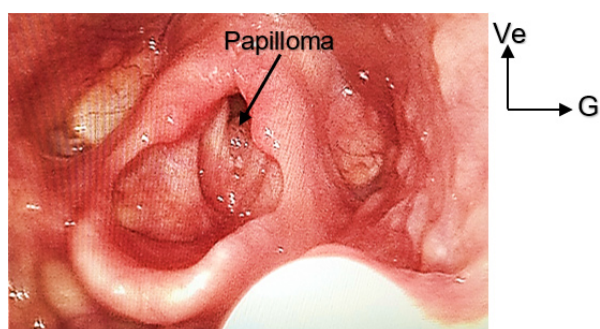


Figure 1: Endoscopic view of the larynx showing a glottic papillomatosis lesion in an 11-year-old patient. Clinical Photo Library, University Clinic of ENT-CCF, CNHU-HKM, 2022.

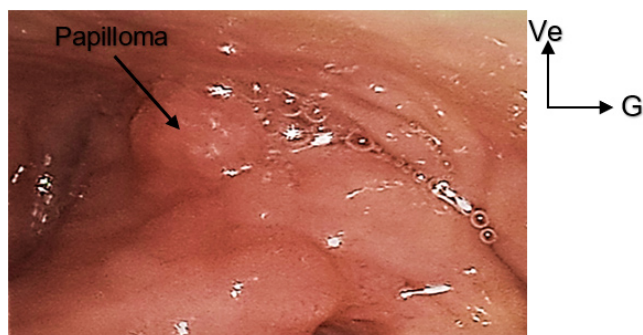


Figure 2: Endoscopic view showing a papillomatosis lesion between the right arytenoid and the right piriform sinus in a 15-year-old adolescent girl. Clinical Photo Library, University Clinic of ENT-CCF, CNHU-HKM, 2022.

Therapeutic Aspects

The treatment was primarily surgical and involved microforceps peeling of papilloma clusters via endoscopy in all cases. Two (02) patients received a combination treatment, starting with peeling using forceps followed by CO2 laser treatment. Among patients who presented with stage III laryngeal dyspnea and required an initial tracheotomy, one out of nine (1/9) was unable to undergo peeling due to financial constraints.

Evolutionary Aspects

Follow-up varied from 01 month to 10 years, with the longest follow-up being 10 years. Recurrence cases were common, with the number of recurrences ranging from one (01) to nine (09) per patient. At least one recurrence was observed in 13 out of 24 patients, with half of the sample experiencing recurrences within 6 to 12 months.

Among the nine (09) patients who underwent tracheotomy, four (04/09 cases) were successfully decannulated. The remaining five (05) patients could not be weaned off their tracheostomy tubes, and one of them passed away with the tracheostomy tube before peeling.

During short and medium-term follow-up, phonatory function improved in sixteen (16) patients. It was observed that only two (02) patients regained a normal voice in the long term. Seventeen out of twenty-four (17/24) patients were lost to follow-up after respiratory function was restored and/or voice quality improved. The social and professional reintegration of patients was not always straightforward. In the pediatric population, there was a child who had never attended school, and one case of school dropout imposed by parents. Among adults, professional reintegration occurred without significant difficulties.

Discussion

Epidemiological Aspects

Laryngeal papillomatosis, a benign tumor induced by the Human Papilloma Virus (HPV), has an incidence that is difficult to quantify [3]. In the United States, it is estimated that laryngeal papillomatosis affects 1.8 per 100,000 adults and 4.3 per 100,000 children [4]. It is a relatively rare condition in Benin. The data from the current study reported an incidence of 2.54 cases per year. In the subregion, the incidence varied from 03 to 3.5 cases per year for Ndour or Maliki and for Pegbessou or Koné; incidences that are similar to ours [5-8]. Laryngeal papillomatosis can be discovered at any age, with extremes ranging from one day to 84 years, according to Derkay [3]. The results of our study found an average age of 13.74 years, with extremes of 19 months and 45 years, similar to those reported by Pegbessou and colleagues in Lomé [7]. Females predominated in our sample (15/24 cases) with a sex ratio of 0.6 (9/15); however, in the literature, males were more commonly represented [7;9].

Diagnostic Aspects

The diagnosis of laryngeal papillomatosis is often delayed in our developing countries due to patients' delays in seeking medical care. This delay is often related to the fact that there is no subsidy for the management of this condition. Maïga and colleagues noted an average delay to consultation of 4.5 years, with extremes of one (01) month and 26 years [10]. Laryngeal papillomatosis typically presents with initial dysphonia, characterized by a hoarse voice that gradually worsens over time. Although all patients reported it, it was not always the sole reason for seeking medical attention. In our study population, 17 out of 24 patients sought consultation for dyspnea, with nine (09) at stage III according to the Chevalier Jackson and Pineau classification. Other studies have also reported laryngeal dyspnea seen at an evolving stage, reflecting the laryngeal obstructive nature of papillomas, whether solitary, disseminated, clustered, or florid [9]. The majority of lesions were localized to the glottis, as in this study, and this has been reported by several authors. However, variations in the frequency of lesions at other sites are possible [5-7;10]. Several authors have reported cases of extra-laryngeal localization of papillomas, including Zouak and colleagues who encountered a case of tracheal involvement [11], and Ndour and colleagues found a case of extension into the uvula in a pregnant woman [5]. In our study, extra-laryngeal extension occurred into the esophageal mouth in one (01) patient. The anatomopathological examination confirmed the presence of papillomas without any malignant lesions, thus confirming the diagnosis of laryngeal papillomatosis. These results are comparable to those of some African authors such as Koné and Ouraini [8;12].

Therapeutic Aspects

Definitive treatment for laryngeal papillomatosis is not yet available. However, two approaches are commonly used [13]. The surgical approach via endoscopy is the most common and is practiced by all schools. In this case, technologically advanced countries have varying means, including the use of microdebriders, lasers, or cold instruments. The laser is the most commonly used method, whereas in developing countries, as in this study, we resorted to peeling papillomas with microforceps. For many African authors, this method was the only treatment available to patients [6-8;11]. Currently, other therapeutic alternatives, in order of frequency of use, include Cidofovir, anti-HPV vaccination, and Bevacizumab. Treatment is administered intralesionally for Bevacizumab and Cidofovir. Although the results are promising, there are no official recommendations for their use. Nevertheless, they remain the only options after surgical

treatment fails, depending on the indications [14-16]. Emergency tracheotomy was a lifesaving procedure for 09/24 patients who presented with laryngeal dyspnea. In African series, tracheotomy has also been a lifesaving procedure. Koné and Maïga performed emergency tracheotomy in 31.2% and 20.8% of cases, respectively [8;10]. This practice also allowed for the safe removal of papillomas. Tracheotomy was performed alternately from one hemilarynx to another during successive peeling sessions to reduce local postoperative complications. In developed countries where access to healthcare is generally early, tracheotomy is rarely considered, let alone performed.

Evolutionary Aspects

Complications are primarily related to the natural progression of the disease. There is a risk of respiratory decompensation in cases of obstructive papillomatosis, especially during induction.

Scarring complications can occur after surgery, whether performed with lasers or cold instruments. These complications may manifest as stenosis or residual dysphonia due to post-therapeutic fibrosis. In this series, there are two (02) cases of normal voice in the long term; other patients experienced an improvement in phonatory function with residual dysphonia.

Laryngeal papillomatosis is a recurrent condition with an unpredictable course, often requiring repeated hospital stays. In this study, 13 out of 24 patients experienced recurrences, ranging from one (01) to nine (09) recurrences within an interval of 6 to 12 months in half of the cases. Additionally, two-thirds (2/3) of the patients experienced at least one recurrence. Maïga and Ndour found 29/48 cases and 19/31 cases of recurrences, respectively, with average recurrence intervals of ten (10) months and nine (09) months [10;5]. Pegbessou and colleagues found recurrences in all patients with an average number of recurrences of 4.42 [7]. It has been acknowledged that treatment with bevacizumab and cidofovir reduces the number of surgical interventions per year and, consequently, the recurrence rate [14-15]. However, in children, the combination of Bevacizumab with surgical treatment has been disappointing [17].

Four out of nine patients (04/09 cases) who underwent tracheotomy were successfully decannulated. The remaining five (05) could not be weaned off the tracheostomy tube. In the studies conducted by Zouak and Maïga, decannulation was achieved in 09/14 cases and 09/10 cases, respectively [10;11]. In the study by Maliki, all patients were decannulated [6].

Citation: Lawson Afouda S, Gankpè O, Avakoudjo F, Medji S, Guézo D, Vodouhè U, do Santos Zounon A, Rijckaert M, Van Der Vorst S, Lawson G and Adjibabi W. (2023). Retrospective Analysis of Patients with Juvenile Laryngeal Papillomatosis in ENT-CCF at CNHU-HKM/Benin: Literature Review. *Journal of Otolaryngology - Head and Neck Diseases* 5(1).

Laryngeal papillomatosis can progress to laryngeal dysplasia, with a significant variability in malignant transformation occurring in about 20% of cases. This is rare and is mainly associated with HPV 11 [18-19]. Malignant transformation of laryngeal papillomatosis into carcinoma has been documented in several case reports [3;20-23].

Cases of dysplasia have been reported in adults by Ndour and colleagues in Senegal, who identified ten (10) cases of different grades without malignant degeneration; Pegbessou in Togo identified two (02) cases of malignant degeneration; Zouak in Morocco reported a case of malignant transformation after five (05) years of evolution requiring laryngectomy [5;7;11].

In our series, there were no cases of malignant transformation. The case of death involved a patient who returned home against medical advice due to financial constraints that prevented her from continuing her treatment. She had undergone a tracheotomy and was awaiting suspension laryngoscopy for peeling. The exact cause of death could not be determined by the parents, but it is likely due to cannula obstruction or accidental decannulation due to tumor proliferation. Several cases of death have been reported in other studies in Africa [5;7;10].

The mode of management takes into account social security. However, this is not the case in our developing countries. Treatments prescribed in low-income countries like Benin are often costly and borne by the patient. As for laser treatment, it is only available in a few private healthcare facilities in Benin. Furthermore, the utilization of new adjuvant therapies is limited due to their challenging accessibility.

Conclusion

Laryngeal papillomatosis is a benign tumor of the larynx. It has a low incidence rate and is most commonly encountered in children. Diagnosis is relatively straightforward and confirmed through anatomopathological examination. It is an unpredictable condition that can progress to recurrences. As a result, it requires regular and rigorous monitoring. Its management comes with a significant financial cost and may also entail a potentially significant psychological burden for the patient.

References

1. BUCHINSKY FJ., DONFACK J., DERKAY C.S., CHOI S.S., CONLEY S.F., MYER III C.M. (2008). Child's age, more than HPV type, is associated with the clinical course of recurrent respiratory papillomatosis. *PLoS ONE*. 3(5): e2263.
2. JAMES M., KATUNDU D., CHUSSI D., SHIJA P. (2018). Prevalence, clinical presentations, associated risk factors, and recurrence of laryngeal papillomatosis among inpatients attended at a Tertiary Hospital in the Northern zone of Tanzania. *Pan African Medical Journal*. 30: 209.
3. DERKAY C.S. (2001). Recurrent respiratory papillomatosis. *Laryngoscope*. 111: 57-69
4. WELSCHMEYER A., BERKE S.G. (2021). An updated review of the epidemiological factors associated with recurrent respiratory papillomatosis. *Laryngoscope Investigative Otolaryngology*. 6: 226-233
5. NDOUR N., MAIGA S., HOURA A., DEGUENONVO R.E.A., NDIAYE C., PILOR N. (2020). Laryngeal papillomatosis in adults: assessment for ten years at the ENT department of National University Hospital of Fann (Dakar, Senegal). *International Journal of Otolaryngology*.
6. MALIKI O., NOURI H., ZIAD T., ROCHDI Y., ADERDOUR L., RAJI A. (2012). Laryngeal papillomatosis in children: epidemiological, therapeutic, and evolutionary aspects. *Journal of Pediatrics and Child Care*. 25: 237-241
7. PEGBESSOU E., AMANA B., TAGBA E., DARRE T., AMEGBOR K., BOKO E. (2014). Laryngeal papillomatosis: epidemiological, diagnostic, and therapeutic profiles. *Dakar Med*. 59(2): 54-59
8. KONE F.I., SINGARE K., TRAORE K., COULIBALY O., CISSE N., SOUMAORO S. (2020). Epidemiological, clinical, and therapeutic aspects of laryngeal papillomatosis in Mali. *International Journal of Otorhinolaryngology*. 6(1): 1-5
9. LAWSON AFOUDA S., HOUNKPATIN S., AVAKOUDJO F., BRUN L., ADJIBABI W. (2015). Juvenile laryngeal papillomatosis in Benin: epidemiological, diagnostic, therapeutic, and evolutionary aspects. *Otolaryngology (Sunnyvale)*. 5: 207.
10. MAIGA S., NDIAYE C., DIOUF M., DIALLO B.K., NDIAYE M., DIOUF R. (2018). Laryngeal papillomatosis in Senegal: a ten-year experience. *European Annals of Otorhinolaryngology. Head and Neck Diseases*. 135(3): 221-224
11. ZOUAK A., RAJI A. (2011). Laryngeal papillomatosis: diagnostic, therapeutic, and evolutionary aspects: about 20 cases. [Doctoral thesis in Medicine]. Marrakech: Faculty of Medicine and Pharmacy - ENT and Cervico-facial Surgery Department of CHU Mohammed VI.

Citation: Lawson Afouda S, Gankpè O, Avakoudjo F, Medji S, Guézo D, Vodouhè U, do Santos Zounon A, Rijckaert M, Van Der Vorst S, Lawson G and Adjibabi W. (2023). Retrospective Analysis of Patients with Juvenile Laryngeal Papillomatosis in ENT-CCF at CNHU-HKM/Benin: Literature Review. *Journal of Otolaryngology - Head and Neck Diseases* 5(1).

12. OURAINI S., BENCHAFAI I., SAHLI M., ROUIHI A., NAKKABI I., JAHIDI A. (2015). Laryngeal papillomatosis in adults: clinical and therapeutic aspects. *Journal of Applied Sciences And Research*. 3(5): 1-4
13. SFORL. (2000). Clinical practice recommendation. Diagnostic and therapeutic approach to viral infections in ENT: In SFORL. Laryngeal papillomatosis. ANAES. 99-103
14. JACKOWSKA J., PIERSIALA K., KLIMZA H., WIERZBICKA M. (2018). Results of treatment with bevacizumab and cidofovir in recurrent respiratory papillomatosis associated with HPV - a literature review. *Otolaryngol Pol*. 72(4): 1-8.
15. SLAIM L., RUBIN F., BONFILS P. LACCOURREYE O. Laryngeal papillomatosis in adults. EMC [20-705-A-10].
16. AYELINO M., ZAIDEN T., GOMES R. (2013). Surgical treatment and adjuvant therapies for recurrent respiratory papillomatosis. *Braz J Otorhinolaryngol*. 79(5): 636-42
17. BADAY Y. I., ONGKASUWAN J., VENKATRAMANI R. (2020). Systemic bevacizumab for recurrent respiratory papillomatosis. *Int J Pediatr Otorhinolaryngol*. 138: 110352.
18. KHAN M., NAIDU T.K. (2019). Risk factors associated with severe recurrent respiratory papillomatosis. *Southern African Journal of Infectious Diseases*. 34(1): a69
19. WELLER M.D., NANKIVELL P.C., McCONKEY C., PALERI V., MEHANNA H.M. (2010). The risk and interval to malignancy of patients with laryngeal dysplasia; a systematic review of case series and meta-analysis. *Clinical Otolaryngology*. 35: 364-372
20. SYRJANEN S., SYRJANEN K. (2021). HPV-associated benign squamous cell papillomas in the upper aero-digestive tract and their malignant potential. *Viruses*. 13(8): 1624.
21. OUDA A.M., ELSABAGH A.A., ELMAKATY I.M., GUPTA I., VRANIC S., AL-THAWADI H. (2021). HPV and recurrent respiratory papillomatosis: a brief review. *Life*. 11: 1279.
22. OMLAND T., LIE K.A., AKRE H., SANDILE L.E., JEBSEN P., SANDVIK L. (2014). Recurrent respiratory papillomatosis: HPV genotypes and risk of high-grade laryngeal neoplasia. *PLoS ONE*. (6): e9914.
23. EGAWA N., DOORBAR J. (2017). The low-risk papillomaviruses. *Virus Research*. 2.

Benefits of Publishing with EScientific Publishers:

- ❖ Swift Peer Review
- ❖ Freely accessible online immediately upon publication
- ❖ Global archiving of articles
- ❖ Authors Retain Copyrights
- ❖ Visibility through different online platforms

Submit your Paper at:

<https://escientificpublishers.com/submission>