

Late Onset Sterile Infiltrate after Accelerated Corneal Cross-Linking

Srwa Sulaiman Ismael^{1*}, Didar Sddeg Anwar²

Author's Information

1. MBChB, Department of Ophthalmology, Eye Teaching Hospital, Erbil
2. FIBMS, Consultant ophthalmologist, Corneal Specialist, North Eye Center, Erbil

Corresponding author:
Srwa Sulaiman Ismael
swa.s.ismail@gmail.com

Funding information
Self-funded

Conflict of interest
None declared by author

Received : July, 2023
Published: September, 2023
DOI: 10.5281/zenodo.8361429

ABSTRACT

Background: Collagen crosslinking is a therapeutic technique designed to strengthen the cornea and halt the progression of keratoconus. Late onset sterile infiltrate is one of the complications of the corneal Collagen crosslinking.

Objective: This study aimed to describe the prevalence, clinical manifestations, potential risk factors and therapeutic options for late-onset sterile infiltration following corneal Collagen crosslinking.

Methods: 2400 patients with a diagnosis of mild to advanced-stage progressive keratoconus underwent accelerated Collagen crosslinking treatment at North eye center (Erbil-Iraq) between April 2018 and March 2022 were included in this study.

Result: Nine patients (0.4%) developed late-onset sterile infiltrates between 3 months and 6 years following Collagen crosslinking. three (33.3%) of them were male and the remaining six (66.6%) were female.

Patients complained of pain, redness, photophobia, swelling, watering and sometimes decreased vision in one eye, the recurrent conditional eventually became bilateral.

Three eyes experienced a decrease in BCVA. No significant association was found between age of the patient, duration of the light exposure, atopic diseases and the development of sterile infiltrate. All patients responds to steroid treatment, however, six (66.6%) of them had recurrent recurrences in the same or the other eye.

Conclusion: Sterile infiltrate is a rare complication in the late postoperative period following uneventful accelerated corneal Collagen crosslinking. It is a treatable condition, responds quickly to steroid eye drops and has a good visual prognosis.

Keywords: Sterile Infiltrate, keratoconus, accelerated corneal crosslinking.

This article is open access published under CC BY-NC Creative Commons Attribution Non-Commercial License: This License permits users to use, reproduce, disseminate or display the article provided that the author is attributed as the original creator and that the reuse is restricted to non-commercial purposes, (research or educational use).



1. INTRODUCTION

Keratoconus (KC) is the most common primary ectatic condition of the cornea and the most typical reason for corneal transplantation in developing countries. It is bilateral, asymmetrical, degenerative, non-inflammatory, and is characterized by progressive corneal thinning brought on by structural changes in the corneal collagen, steepening of the central and inferior portions of the cornea, irregular astigmatism, myopia, biomechanical instability, and visual loss (1, 2, 3). Despite the fact that the precise physiopathology of KC advancement is yet not understood, environmental and genetic variables have been implicated, and frequent, forceful eye rubbing is a known risk factor for its development (1). KC generally develops throughout adolescence and progresses in a variety of ways until the third or fourth decade of life. According to a recent meta-analysis, the estimated prevalence of KC worldwide is 1.38/1000 (2). However, prevalence and incidence figures vary between nations and rely on the diagnostic tools used. The use of glasses, contact lenses, or more invasive procedures like keratoplasty are all options for treating KC. Wantsak et al. first proposed corneal Collagen crosslinking (CXL) as the primary therapy for stabilizing the cornea and halting the progression of the illness in individuals with progressive KC in 1998. The effectiveness and safety of the corneal CXL surgery as a corneal stabilizing technique for treating KC have been highlighted in numerous research. After therapy, it is common to find some visual improvement in the corneal parameters and the refractive result (4, 5). Several complications of CXL have been reported such as postoperative infection/ulcer, corneal haze, persistent epithelial defect and corneal melt, peripheral sterile infiltrates, herpes reactivation, endothelial damage, treatment failure, corneal opacity (6, 7). This study is aimed to describe the prevalence, clinical manifestations, potential risk factors and therapeutic options for late-onset sterile infiltration after uneventful accelerated (A)-CXL, in addition to determine the origins of sterile keratitis following A-CXL and to assess possible contributing factors to sterile corneal infiltrates following uneventful accelerated corneal CXL.

2. METHODOLOGY

This retrospective analysis conducted at North eye center (Erbil-Iraq), records of 2400 patients who received A-CXL treatment between April 2018 and March 2022 and had a diagnosis of mild to advanced-stage progressive KC were examined. All of the participants in this study had undergone A-CXL to stabilize progressive KC in one or both eyes. Exclusion criteria were ocular surface diseases other than KC, especially infectious keratitis. At our facility, A-CXL was performed on various days for the nine patients who experienced post-procedure late onset sterile infiltrate. Conjunctival swabs are not typically sent preoperatively because CXL is a relatively safe technique. A-CXL was performed in the operation room, the patient is laid on his/her back, and using topical anesthesia consisting of tetracaine hydrochloride 0.5% under aseptic conditions. The eye was kept open with the help of a lid speculum. Using an epithelial scraper, the central 8.0 mm of the corneal epithelium was removed. Using 10 mg of riboflavin-5-phosphate (in 10 mL of 20% wt/vol dextran 500) in a riboflavin 0.1% photosensitizer solution onto the debrided central cornea every 5 minutes. The corneas were subsequently exposed to 5.4 J/cm² (9 mW/cm² for 10 minutes) of radiation. All patients received topical antibiotics (moxifloxacin hydrochloride 0.5%) 4 times per day for one week, topical steroids (predforte drop) taped in 1 month, and soft contact lenses that were worn until full re-epithelialization.

3. RESULTS

Over a six-year period, a total of 2400 patients were enrolled in this study. The average age of the patients was 24.5 years and ranged from (10-39) years. In the studied group, 9 patients had late-onset sterile infiltrates. They ranged in age from (13 to 35) years, with a mean age of 25.3 years. Only three (33.3%) of the patients with sterile infiltrates were male and the remaining six (66.6%) were female. The frequency of discovery of infiltration after surgery was 0.4% and was detected between three months and six years after surgery (**Table 1 & 2**). Patients complained of swelling, pain in the CXL-treated eye, and decreased vision. Slit lamp examination revealed one or more circumlimbal lesions that were gray-white at the edge of the epithelial debridement zone (**Figure 1**). The infiltrates were stained with

fluorescein (**Figure 2**). Swabs and scrapings were taken from the lesion in all patients to rule out an infectious corneal infiltrate, and the results of microbiologic testing were negative. Patients received ptdforte drops every two hours, in some cases every hour and one patient needed systemic steroid to respond. Gradual regression occurred in all patients who had sterile infiltrates. However, six (66.6%) of them had recurrence in the same or the other eye. The retreating infiltration left opacification in the stroma in two cases (22.2%).

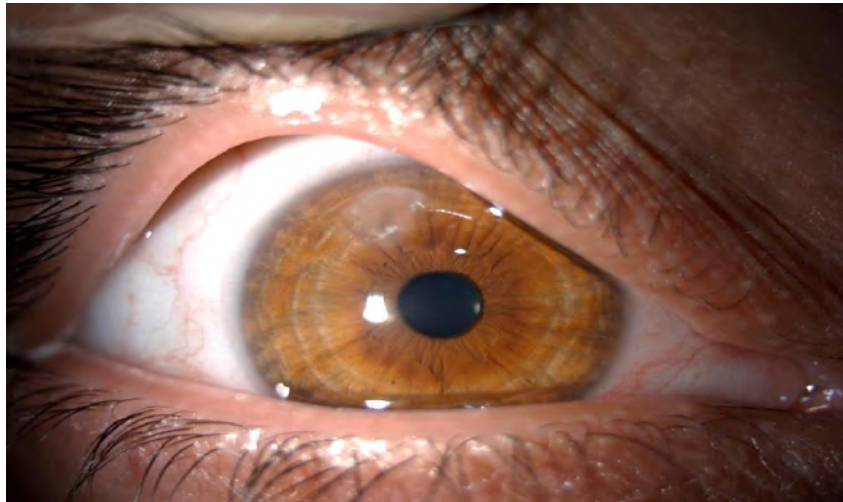


Figure 1. Slit-lamp image 6 months after A-CXL procedure showing peripheral sterile infiltrate in a 28-year-old female patient.

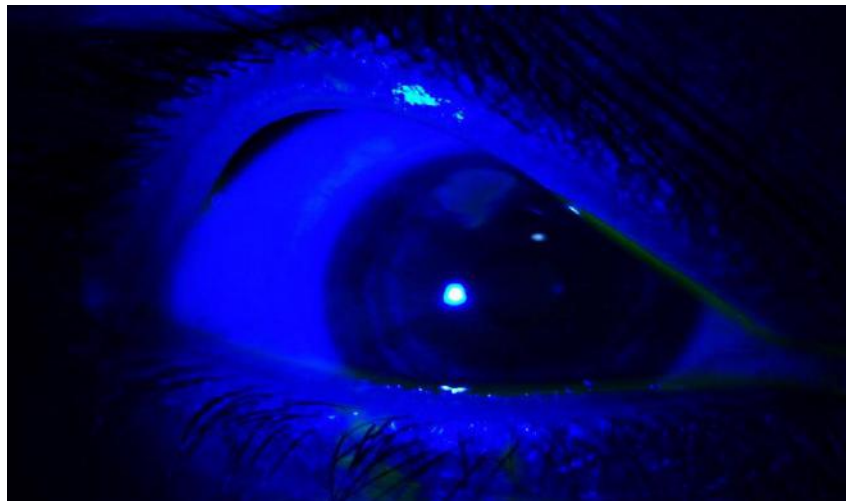


Figure 2. Slit-lamp postoperative image showing PUK staining with fluorescein 6 months after the A-CXL procedure.

Table 1. Pre A-CXL Data of patients having late onset sterile infiltrate.

Patient	Age	Gender	Eye	SE OD	SE OS	Allergy	Visual acuity	Mean K
1	28	Female	OU	-4.25	-1.75	present	0.8 – 0.8	47.63 45.38
2	29	Female	OU	-2.25	-3.25	none	0.1 – 0.1	46.63 48.63
3	13	Male	OS	-1.75	-2.5	none	0.2	44.88 45.38
4	14	Female	OD		-12	none	0.1	55.00 57.00
5	35	Female	OU	-3.25	-4.25	none	0.3 – 0.5	44.75 47.50
6	28	Male	OU	-2.75	-3	none	0.2 – 0.2	44.88 45.63
7	29	Female	OU	-5.5	-4	none	0.1 – 0.3	48.25 46.75
8	35	Female	OD	-1.25	-0.75	none	0.2	47.00 46.75
9	17	Male	OU	-14.25	-16.75	none	0.7 – 1.0	57.88 60.50

Table 2. Post A-CXL Data of patients having late onset sterile infiltrate.

Patient	Sterile infiltrate	Visual acuity
1	OU	0.6 – 0.8
2	OU	0.1 – 0.1
3	OS	– 0.3
4	OD	0.1
5	OU	0.3 – 0.5
6	OU	0.2 – 0.2
7	OU	0.1 – 0.3
8	OD	0.2
9	OU	0.7 – 0.8

4. DISCUSSION

The use of CXL in the treatment of KC results in the stabilization of the condition and the avoidance of keratoplasty, but the procedure is not without risk; numerous complications have been reported in the initial phases following CXL. It should be emphasized that sterile infiltrate do not seem to be limited to the CXL technique; they are also known to be a reaction to LASIK (9, 10), photorefractive keratectomy (11) and contact lenses (12), among other procedures. The small number of patients who developed late onset sterile infiltrate makes the study challenging to pinpoint the cause and process of their development. It is a rare complication when measured against the total number of CXL operations performed worldwide. It is important to remember that early diagnosis affects the course of treatment and any potential late complications. CXL problems, which can vary from moderate stromal haze to vision-threatening haze, infectious keratitis, and sterile corneal melting, are mentioned in a number of case reports and original investigations. Late onset PUK are a rare consequence following A-CXL, albeit they have been documented (6, 7, 8). To the best of our knowledge, only one study has ever been done on late-onset PUK post-crosslinking, and our report is the second to do so. This new problem was discovered to be developing months to years after surgery in 0.4% of the treated eyes at our center through long-term follow-up.

In a retrospective research by Chanbour et al. (13), a late-onset sterile infiltration was observed in 1.4% of 771 eyes that had received both the standard and accelerated CXL protocols. 771 eyes that had received both the standard and A-CXL regimen revealed 1.4% of late-onset sterile infiltrates. They claimed that older age-related UVB light exposure was linked to PUK. In our investigation, the development of a sterile infiltrate was discovered in 9 cases (0.4%), however' there was no statistically significant correlation between the age of the patient and the development of an immune infiltrate. According to research in the literature, sterile infiltrates may be related to atopy. However, our analysis revealed that none of the patients had atopic illnesses (14, 15). We therefore believe that our results do not support the offered ideas that link keratitis to the duration of epithelial or endothelial exposure to UVB light. Despite receiving a shorter course of treatment (10 minutes as opposed to the standard 30 minutes of full UVB exposure), all of the affected patients still experienced ulcerative keratitis. Peripheral ulceration manifested unilaterally in two of the

eight patients (with the exception of patient number 4), all of whom underwent surgery on both eyes. The fellow eyes' topographic characteristics were comparable, the same surgeon operated on them, and the UVB light was held at the same distance from the cornea with the same radiant energy (9.0 mW/cm²) for all of the eyes. Thus, we are able to rule out any operational incident or UVB light malfunction as the origin of the reported issue. Comparing the pre-CXL visual acuities to the post-sterile infiltrate treatment vision, it was found that 3 eyes (patient numbers 1, 8, and 9) experienced a decrease in BCVA. Based on our experience and the development of the clinical picture, we made the diagnosis of late-onset sterile infiltration. Since the signs and symptoms pointed to an immune-mediated inflammatory process rather than an infectious one and the patients' responses to anti-inflammatory drugs support our diagnosis of sterile PUK, in addition to Swabs and scrapings were taken from the lesion in all patients and the results of testing were negative.

5. CONCLUSIONS

After CXL, in the late postoperative period, sterile corneal infiltrates with or without corneal haze can form. It has a good visual prognosis and responds quickly to steroid eye drops and, in recurring cases, a combination of topical and systemic steroid. The limitations of this study appear to be the small number of patients who experienced issues relative to the total number of patients who underwent CXL treatment and the retrospective nature of the investigation. The nature, traits, pathogenesis, and management of late-onset sterile corneal ulcer post-CXL may be better understood with the use of a multicenter study analysis with a larger sample size.

Ethical Approval:

All ethical issues were approved by the author. Data collection and patients enrollment were in accordance with Declaration of Helsinki of World Medical Association , 2013 for the ethical principles of researches involving human. Signed informed consent was obtained from all participants and data were kept confidentially.

6. BIBLIOGRAPHY

1. Saad S, Saad R, Jouve L, Kallel S, Trinh L, Goemaere I, Borderie V, Bouheraoua N. Corneal crosslinking in keratoconus management. *Journal francais d'ophtalmologie*. 2020 Dec 1;43(10):1078-95.
2. Pedrotti E, Chierigo C, Bonacci E, De Gregorio A, De Rossi A, Zuliani A, Fasolo A, Marchini G. New treatments for keratoconus. *International Ophthalmology*. 2020 Jul;40:1619-23.
3. Antoun J, Slim E, El Hachem R, Chelala E, Jabbour E, Cherfan G, Jarade EF. Rate of corneal collagen crosslinking redo in private practice: risk factors and safety. *Journal of Ophthalmology*. 2015 (2015):690961.
4. Elbaz U, Shen C, Lichtinger A, Zauberman NA, Goldich Y, Chan CC, Slomovic AR, Rootman DS. Accelerated (9-mW/cm²) corneal collagen crosslinking for keratoconus—a 1-year follow-up. *Cornea*. 2014 Aug 1;33(8):769-73.
5. Çınar Y, Cingü AK, Türkcü FM, Çınar T, Yüksel H, Özkurt ZG, Çaça I. Comparison of accelerated and conventional corneal collagen cross-linking for progressive keratoconus. *Cutaneous and ocular toxicology*. 2014 Sep 1;33(3):218-22.
6. Evangelista CB, Hatch KM. Corneal Collagen Cross-Linking Complications. *Semin Ophthalmol*. 2018;33(1):29-35.
7. Dhawan S, Rao K, Natrajan S. Complications of corneal collagen cross-linking. *Journal of ophthalmology*. 2011 (2011): 869015.
8. Çerman E, Özcan DÖ, Toker E. Sterile corneal infiltrates after corneal collagen cross-linking: evaluation of risk factors. *Acta Ophthalmologica*. 2017 Mar;95(2):199-204.
9. Haw WW, Manche EE. Sterile peripheral keratitis following laser in situ keratomileusis. *Journal of Refractive Surgery*. 1999 Jan 1;15(1):61-3.
10. Ambrósio R, Periman LM, Netto MV, Wilson SE. Bilateral marginal sterile infiltrates and diffuse lamellar keratitis after laser in situ keratomileusis. *Journal of refractive surgery*. 2003 Mar 1;19(2):154-8.
11. Geggel HS. Delayed sterile keratitis following radial keratotomy requiring corneal transplantation for visual rehabilitation. *Journal of Refractive Surgery*. 1990 Jan 1;6(1):55-8.
12. Szczotka-Flynn L, Jiang Y, Raghupathy S, Bielefeld RA, Garvey MT, Jacobs MR, Kern J, Debanne SM. Corneal inflammatory events with daily silicone hydrogel lens wear. *Optometry and vision science*. 2014 Jan 1;91(1):3-12.
13. Chanbour W, Mokdad I, Mouhajer A, Jarade E. Late-onset sterile peripheral ulcerative keratitis post-corneal collagen crosslinking. *Cornea*. 2019 Mar 1;38(3):338-43.

14. Wittig-Silva C, Franzco MW, BScOptom RG, Franzco LJ, Franzco GR. A randomized controlled trial of corneal collagen cross-linking in progressive keratoconus: preliminary results. *Journal of refractive surgery*. 2008 Sep 1;24(7):S720.
15. Ghanem RC, Netto MV, Ghanem VC, Santhiago MR, Wilson SE. Peripheral sterile corneal ring infiltrate after riboflavin–UVA collagen cross-linking in keratoconus. *Cornea*. 2012 Jun 1;31(6):702-5.

Citation:

Ismael S.S, Anwar D.S Late Onset Sterile Infiltrate after Accelerated Corneal Cross-Linking. *AJMS* 2023; 9 (3): 266-74. DOI: 10.5281/zenodo.8361429