



# Port site tuberculosis after laparoscopic cholecystectomy: A rare complication with review of literature

Shahbaz Habib Faridi, Bushra Siddiqui<sup>1</sup>, Kaushal Deep Singh, Mohammad Aslam

Departments of Surgery and <sup>1</sup>Pathology, JN Medical College, Aligarh Muslim University, Aligarh, Uttar Pradesh, India

## ABSTRACT

Laparoscopic procedures are routinely performed in most surgical centers today. Surgical site infections at port sites following laparoscopy are not uncommon. However, port site tuberculosis (TB) is a rare complication following a laparoscopic procedure. The possible causes of its development include improper sterilization of instruments, use of tap water containing resistant atypical mycobacteria to clean these instruments before immersion into glutaraldehyde solution; and seeding at the port site due to gall bladder TB. We report here a case of a young female who underwent laparoscopic cholecystectomy outside our hospital and then developed a discharging sinus at the epigastric port site. Three attempts of debridement and wound closure had already been done before and every time there was a recurrence. Sinus tract was excised after getting the sinogram, and the histopathology showed features consistent with TB. The patient was put on anti-tubercular therapy, and she had no recurrence after 3 months of follow-up.

**Key words:** Laparoscopy cholecystectomy, nonhealing sinus, port site infection, sterilization, tuberculosis

## INTRODUCTION

Tuberculosis (TB) is still one of India's major public health problems. It also remains among the infectious diseases with the widest array of presentations. Surgical site infections are the most common healthcare-associated infections (HAIs), accounting for 31% of all HAIs among hospitalized patients.<sup>[1]</sup> Port site infective complications are not uncommon.<sup>[2]</sup> But port site TB is a rare complication following a laparoscopic procedure with only a few isolated cases reported in the literature.<sup>[3-5]</sup> We report here a case of a young female who underwent laparoscopic cholecystectomy (LC) outside our hospital and then presented to us with a discharging sinus at the epigastric port site.

## CASE REPORT

A 28-year-old female presented to us with complaints of discharge of purulent fluid coming from a wound on her abdominal wall. The patient had undergone LC 6 months back for symptomatic gallstones in a peripheral hospital. Postoperative period was uneventful, but patient's epigastric port wound did not heal even after 1 month. She developed a small discharging opening over her anterior abdominal wall at the port site for which debridement of the wound was done thrice over a period of 5 months at the same hospital but every time there was recurrence within 2–3 weeks. There was no history of loss of appetite, evening

**Address for correspondence:** Dr. Shahbaz Habib Faridi, Department of Surgery, JN Medical College, Aligarh Muslim University, Aligarh - 202 002, Uttar Pradesh, India.  
E-mail: shahbazfaridi@yahoo.com

### Access this article online

Quick Response Code:



**Website:**  
www.ijhas.in

**DOI:**  
10.4103/2278-344X.180431

This is an open access article distributed under the terms of the Creative Commons Attribution-NonCommercial-ShareAlike 3.0 License, which allows others to remix, tweak, and build upon the work non-commercially, as long as the author is credited and the new creations are licensed under the identical terms.

**For reprints contact:** reprints@medknow.com

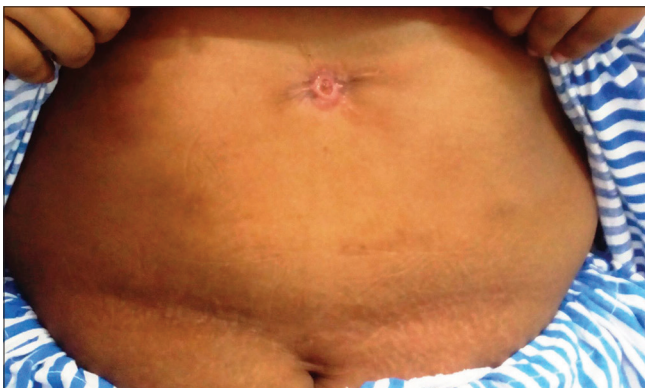**How to cite this article:** Faridi SH, Siddiqui B, Singh KD, Aslam M. Port site tuberculosis after laparoscopic cholecystectomy: A rare complication with review of literature. *Int J Health Allied Sci* 2016;5:123-5.

rise of temperature, cough with expectoration, hemoptysis, weight loss or abdominal pain or any anti-tubercular therapy (ATT) in the past. On examination, a small opening with scanty serous discharge was present in the epigastric port wound site [Figure 1]. Margins of the wound were undermined with unhealthy granulation tissue. There was no erythema or tenderness and rest of the per-abdominal examination was normal. Her laboratory investigations were unremarkable except for the raised erythrocyte sedimentation rate which was 30 mm in the 1<sup>st</sup> h. Mantoux test was positive with induration of 18 mm × 20 mm and X-ray chest of this patient was within normal limit. The culture was taken from the discharge which showed no growth. Acid-fast bacilli (AFB) could not be demonstrated by Ziehl–Neelsen (ZN) staining nor was there any growth on Löwenstein–Jensen media after 6 weeks of incubation or BACTEC media after 2 weeks. A sinogram was done which showed nonbranching sinus tract ending present just below anterior abdominal wall in the epigastric region. Cytology of the discharge showed predominant lymphocytes in a fibrous background. Complete excision of sinus tract was done after delineation of tract with methylene blue dye under general anesthesia. Per-operatively, there was a blind ending, nonbranching tract present in the epigastric region which

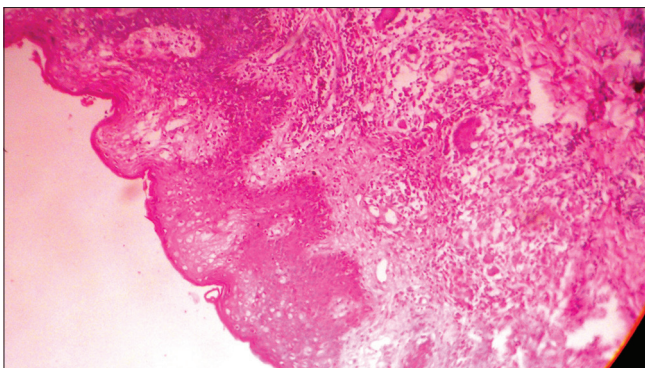
ended preperitoneally [Figure 2]. After achieving complete hemostasis, margins were approximated with nonabsorbable 3-0 polyamide sutures and a mini vacuum suction drain was placed which was taken out on the 3<sup>rd</sup> postoperative day. The histopathological examination (HPE) report of excised tract showed chronic granulomatous lesion along with epithelioid cells in a lymphoid background suggestive of TB [Figure 3]. AFB could not be demonstrated in the specimen on ZN staining. ATT with four drugs that is rifampicin, pyrazinamide, isoniazid, and ethambutol was started. The patient had no recurrence after 3 months of follow-up [Figure 4]. ATT is planned for 9 months (2 months intensive phase with 4 drugs followed by 7 month continuation phase with 2 drugs).

## DISCUSSION

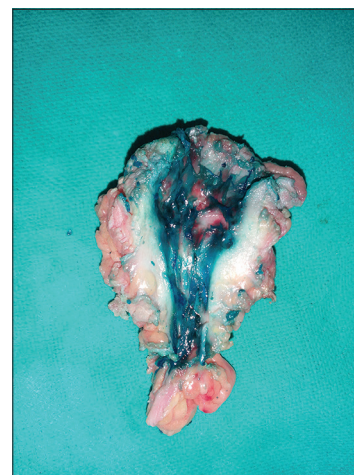
Laparoscopic procedures are being increasingly performed worldwide at most surgical centers today. They are



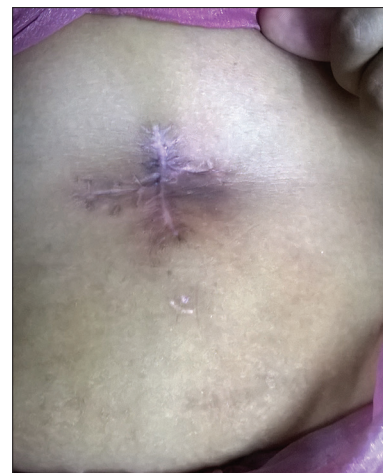**Figure 1:** Preoperative photograph of sinus tract at epigastric port site with scanty serous discharge



**Figure 3:** Microscopic picture of tubercular granuloma at ×400 showing characteristic features



**Figure 2:** Completely excised sinus tract after delineating it with methylene blue



**Figure 4:** Postoperative photograph of healed wound without any recurrence

associated with some unique set of complications apart from other common surgical complications.<sup>[6]</sup> Port site infections (PSI's) are not uncommon.<sup>[2]</sup> However, only isolated reports of PSI with tubercular and nontubercular mycobacteria presenting as nonhealing discharging sinus tract exist.<sup>[3-5,7-9]</sup> Cases of port site TB have been reported after LC, laparoscopic oophorectomy, hysterectomy, adhesiolysis, laparoscopic inguinal hernia repair, laparoscopic appendectomy.<sup>[3-5,10]</sup> This assumes paramount importance to tackle this complication in developing country like India in the view that ours is the highest TB burden country in the world regarding absolute number of incident cases that occur each year.<sup>[11]</sup> Port site mycobacterial infection is commonly exogenous, but it can be endogenous also. Exogenous modes of transmission include improper sterilization of instruments and use of tap water containing resistant atypical mycobacteria to clean these instruments before immersion into glutaraldehyde solution.<sup>[12,13]</sup> Mansoor *et al.* reported port site TB at the epigastric port during gall bladder (GB) extraction in a case of GB TB.<sup>[4]</sup> Cunnigaiper and Venkatraman reported port site TB, which occurred after diagnostic laparoscopy for primary infertility and peritoneal tubercles were found per-operatively.<sup>[7]</sup> In our case, the patient was operated at a peripheral hospital, and the exact policy adopted for sterilization is not known. Furthermore, the excised GB of this patient was not sent for HPE. In our patient, there was no focus of TB so the possibility of transmission of TB to port site through infected laparoscopic instruments is a possibility.

The presentation in such a case is typically the presence of nonhealing wound at the port site.<sup>[3,13]</sup> Usually, the epigastric port site (in cases of LC) or specimen retrieval site (in other laparoscopic procedures) is almost always involved as that port is associated with maximal handling during surgery. The investigations in such cases include pus culture and sensitivity to rule out any primary PSI or associated secondary infection in cases of mycobacterial infection. ZN staining can also be used for direct demonstration of AFB. Polymerase chain reaction has very high negative predictive value for demonstrating mycobacterial DNA and is very useful in such isolated cases.<sup>[14]</sup> Delineation of tract can be done by X-ray sinography and per-operatively with methylene blue dye. Treatment of patients with such a presentation may comprise starting ATT on high suspicion basis or after confirming the diagnosis by biopsy from port site. Patients' wound may heal with ATT only as reported by Jain *et al.*<sup>[15]</sup> Gupta *et al.* confirmed TB by HPE from the wound site and it was followed by sinus tract excision followed by ATT as was done in our case.<sup>[5]</sup>

## CONCLUSION

With the expanded usage of laparoscopy, mycobacterial infection of the port site is an increasingly recognized complication, and it undermines the benefits conferred by laparoscopy. This can be controlled by implementing rigorous protocols of laparoscopic instrument sterilization and HPE of all the resected specimens to prevent endogenous infections. Such patients are optimally managed by careful meticulous complete excision of sinus tract followed by ATT.

## Financial support and sponsorship

Nil.

## Conflicts of interest

There are no conflicts of interest.

## REFERENCES

1. Magill SS, Hellinger W, Cohen J, Kay R, Bailey C, Boland B, *et al.* Prevalence of healthcare-associated infections in acute care hospitals in Jacksonville, Florida. *Infect Control Hosp Epidemiol* 2012;33:283-91.
2. Karthik S, Augustine AJ, Shibumon MM, Pai MV. Analysis of laparoscopic port site complications: A descriptive study. *J Minim Access Surg* 2013;9:59-64.
3. Ramesh H, Prakash K, Lekha V, Jacob G, Venugopal A, Venugopal B. Port-site tuberculosis after laparoscopy: Report of eight cases. *Surg Endosc* 2003;17:930-2.
4. Mansoor T, Rizvi SA, Khan RA. Persistent port-site sinus in a patient after laparoscopic cholecystectomy: Watch out for gallbladder tuberculosis. *Hepatobiliary Pancreat Dis Int* 2011;10:328-9.
5. Gupta P, Guleria S, Mathur SR, Ghosh R. Port site tuberculosis: A case report and review of literature. *Indian J Tuberc* 2012;59:32-5.
6. Sasmal PK, Mishra TS, Rath S, Meher S, Mohapatra D. Port site infection in laparoscopic surgery: A review of its management. *World J Clin Cases* 2015;3:864-71.
7. Cunnigaiper ND, Venkatraman S. Port site tuberculosis: Endogenous or exogenous infection? *Surg Infect (Larchmt)* 2010;11:77-8.
8. Chaudhuri S, Sarkar D, Mukerji R. Diagnosis and management of atypical mycobacterial infection after laparoscopic surgery. *Indian J Surg* 2010;72:438-42.
9. Abd-Elhamid N, Kasim K. Port-site non-tuberculous mycobacterial infection after laparoscopic cholecystectomy: A case series study. *TAF Prev Med Bull* 2013;12:481-4.
10. Bhandarkar DS, Bhagwat S, Punjani R. Port-site infection with *Mycobacterium chelonae* following laparoscopic appendectomy. *Indian J Gastroenterol* 2001;20:247-8.
11. Park K. Communicable diseases: Tuberculosis. In: Park's Textbook of Preventive and Social Medicine. 22<sup>nd</sup> ed. Jabalpur, Madhya Pradesh, India: Banarsidas Bhanot; 2013.
12. Jagdish N, Sameer R, Omprakash R. Port-site tuberculosis: A rare complication following laparoscopic cholecystectomy. *Scand J Infect Dis* 2002;34:928-9.
13. Sethi S, Sharma M, Ray P, Singh M, Gupta A. *Mycobacterium fortuitum* wound infection following laparoscopy. *Indian J Med Res* 2001;113:83-4.
14. Honoré-Bouakline S, Vincensini JP, Giacuzzo V, Lagrange PH, Herrmann JL. Rapid diagnosis of extrapulmonary tuberculosis by PCR: Impact of sample preparation and DNA extraction. *J Clin Microbiol* 2003;41:2323-9.
15. Jain SK, Stoker DL, Vathianathan R. Port-site tuberculosis following laparoscopic cholecystectomy: A case report and review of literature. *Indian J Surg* 2005;67:205-6.