

## Case Report

# Ocular prosthesis: Patient rehabilitation - A Case Report

**Kirti Somkuwar, Robin Mathai, \*Panambily Jose**

Department of Prosthodontics, \* Department of Oral Medicine, People's College of Dental Sciences & Research Centre, People's Campus Bhanpur, Bhopal - 462037 (M.P.)

### Abstract:

The loss of the facial structures can have a physical, social and psychological impact on those affected. Maxillofacial prostheses which restore and replace stomatognathic and associated facial structures with artificial substitutes, aim to improve the patient aesthetics, restore and maintain health of the remaining structures and consequently provide physical and mental well being. Accurate impressions of these tissues facilitate a close adaptation of the custom prosthesis to the tissue bed resulting in better potential for movement by the patient. Treatment of such cases includes implants and acrylic eye prosthesis. Due to economic factors it may not be advisable in all patients. A custom-made ocular prosthesis is a good alternative. A case of a custom-made ocular acrylic prosthesis is presented here, which had acceptable fit, retention and esthetics.

**Key Words:** Maxillofacial prosthesis, stomatognathic, scleral shell prosthesis.

### Introduction:

The disfigurement associated with the loss of an eye can cause significant physical and emotional problems (Lubkin & Solan, 1990). The rehabilitation of a patient who has suffered the psychological trauma of an ocular loss requires a prosthesis that will provide the optimum cosmetic and functional result. Refinement in the details of custom made ocular construction has produced a superior restoration delivered more readily.

An ocular prosthetic does not provide vision; this would be a visual prosthetic. Someone with an ocular prosthesis is totally blind on the affected side and has monocular (one sided) vision which affects depth perception. The Scleral Shell Prosthesis is a thin hard acrylic shell-like artificial eye. This type of eye prosthesis is worn over a damaged, disfigured eye or eviscerated globe. The Shell Prosthesis covers the entire surface of the eye, restoring it to a natural appearance. In most cases, there is no surgery involved in obtaining the Scleral Shell Prosthesis. The fitting process involves making an impression of the cosmetically blemished eye. This will allow the Ocularist to create an anatomically correct and comfortable prosthesis. An impression fit shell will also provide maximum comfort, movement, and wearing time.

**Corresponding Author:** Dr.Kirti Somkuwar, Old jail complex Arera hills, Jhangribad, Bhopal-462004, M.P.

**Phone No:** 9981833467

**E-mail:** kirtisomkuwar@gmail.com,

Before starting the design of the prosthesis, it is essential to assess the psychological component in order to gain the confidence of the patient, in addition to a detailed medical history that includes the condition that led to the excision and enucleation in order to alert the possibility of recurrence (Cain, 1982).

### A Brief History of Ocular Prosthesis:

The art of making artificial eyes has been practiced since ancient times. Egyptian priests made the first ocular prosthesis, called Ectblepharons, as early as the 5<sup>th</sup> century BC. In those days, artificial eyes were made of enameled metal or painted clay and attached to cloth and worn outside the socket.

The first in-socket artificial eye made in the 15<sup>th</sup> century was made of gold with coloured enamel. In the latter part of the 16<sup>th</sup> century, the Venetian glass artisans discovered a formula that could be tolerated inside the eye socket. These early glass eyes were crude, uncomfortable to wear and very fragile.

Today the vast majority of patients all around the world wear ocular prosthesis made of acrylic. Several techniques have been used in fitting and fabricating artificial eyes. Empirically fitting a stock eye, modifying a stock eye by making an impression of the ocular defect (Taicher et al, 1985), and the custom eye technique (Benson, 1977) are the most commonly used techniques. The fabrication of a custom acrylic resin eye provides more esthetic and gives precise results

because an impression establishes the defect contours, and the iris and the sclera are custom fabricated and painted.

Keeping these in mind we at the Department of Prosthodontics, People's College of Dental Sciences & Research Centre successfully rehabilitated a patient for an ocular prosthesis of which the case description is as follows:

**Case report:**

A 62 year old female patient reported in the Department of Prosthodontics, with the chief complaint of difference in colour with the present artificial eye and its impingement while she was wearing it during the night (Fig. I). She had lost her right eye as a result of an episode of chickenpox at the age of 6-7 years. She had her first artificial eye constructed at the age of 25years. Since then she has changed her prosthesis thrice and the one which she was wearing at the time of presenting to our Department was 2 years old.

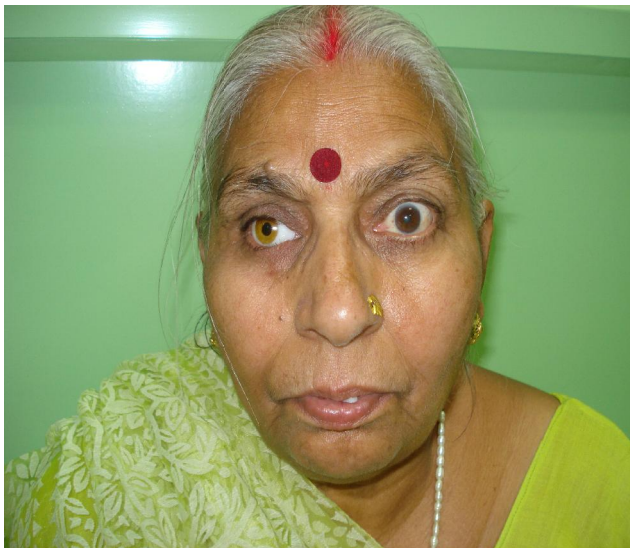


Fig. I: Photograph showing patient with previous prosthesis.

On examination of the defective eye socket it was found that she had a defect with a shrunken orbit and intact tissue bed (Fig. II).

**Overview of construction:**

Armamentarium & material included light, medium and putty consistency (additional polyvinyl siloxane) impression material (Manufacturer: Coltane/Whaledent AG, Switzerland), the dispensing gun with a fine tip and Vaseline.

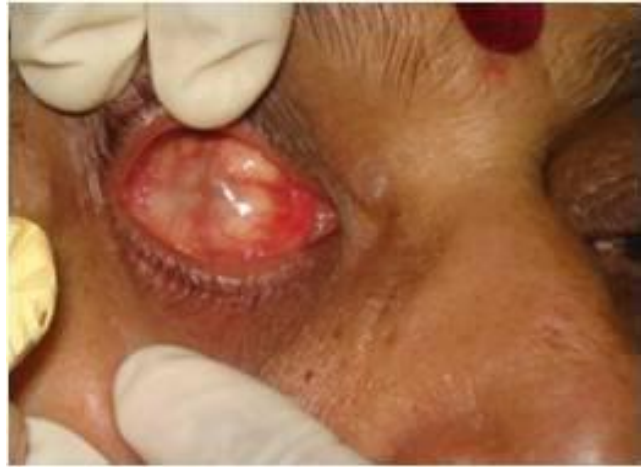

Fig. II: Photograph showing the ocular defect of the patient.

**Procedure:**

Primary impression: Sykes (1996) used medium viscosity polyvinyl siloxane impression material. A modification of the technique described by Taicher et al (1985) was performed by Sykes. We used the same basic technique in this case.

The patient's eye socket was coated with a thin layer of vaseline and an impression was made using medium body addition silicone impression material (Fig. III). Impression was made by injecting the material first into the depth below the upper eye lid and then into the lower. This was done so as to record the proper extensions of the defect. After that the whole eye socket was filled with material and the patient was asked to close her eye so that the excess material could flow

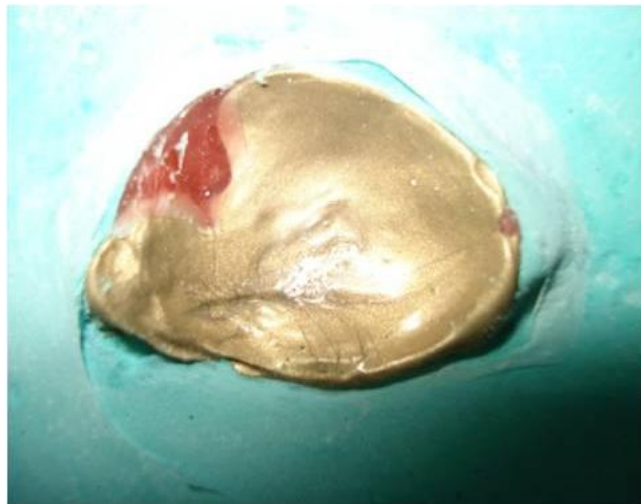

Fig. III: Photograph showing Primary impression of the patient eye socket.

out. Patient was then asked to move her eye to the right then to the left, then up and down and finally in a circular motion, so that the functional impression of the defect could be obtained . The impression was then retrieved when it had completely set. This impression was then invested to obtain a primary sectional cast. (Fig. IV).



Fig. IV: Photograph showing how Primary impression was invested for special tray fabrication.




Fig.V: Photograph showing Special tray fabricated to make final Impression

The first half of sectional cast was poured while keeping the impression surface facing upwards and after which the indexing of the first pour was done so as to allow orientation of the second half. After complete setting the two halves of the cast were separated and a special tray with clear acrylic was fabricated, finished and polished (Fig. V).

**Secondary impression:** This impression was made using soft putty consistency polyvinyl siloxane and light body addition silicone impression material. Firstly the gross extent of the defect was recorded with soft putty and the final impression was then made using light body

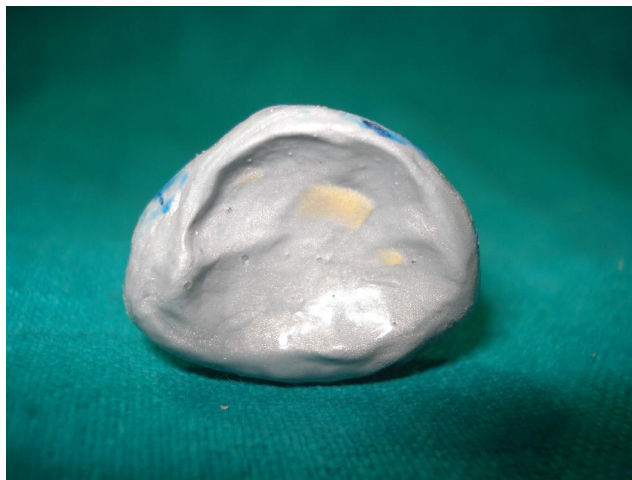

Fig. VI: Photograph showing final impression of the tissue bed.

as a wash material. By this the whole extent of the defect was recorded, keeping in mind the various movements as mentioned earlier so as to achieve a functional impression of the tissue bed (Fig.VI). Acrylic sprue was attached to the tray handle to act as a sprue channel for pouring modelling wax into the mold space later on. This impression was then poured in the same manner as the primary impression except keeping in mind the handle length and position ( Fig.VII).




Fig. VII: Photograph showing final impression invested from wax pattern fabrication.

Then the two halves of casts were separated and the final impression retrieved so as to keep the mold space ready for wax pattern fabrication for which molten wax was poured into the secondary cast through the sprue channel (Fig.VIII). When the wax had set the cast was separated and the wax pattern was retrieved and carved.

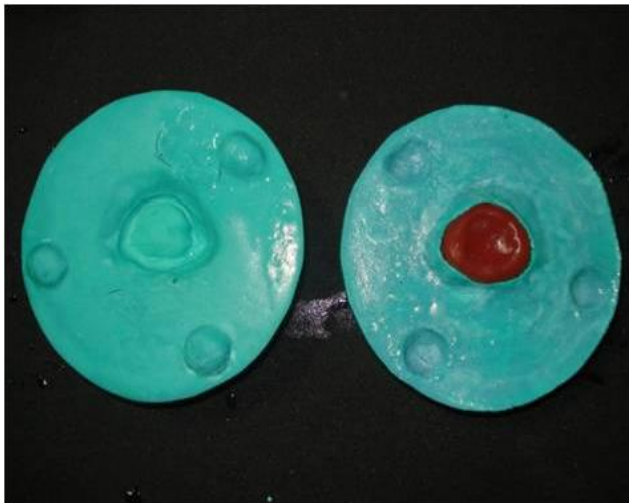


Fig.VIII: Photograph showing fabricated wax pattern.

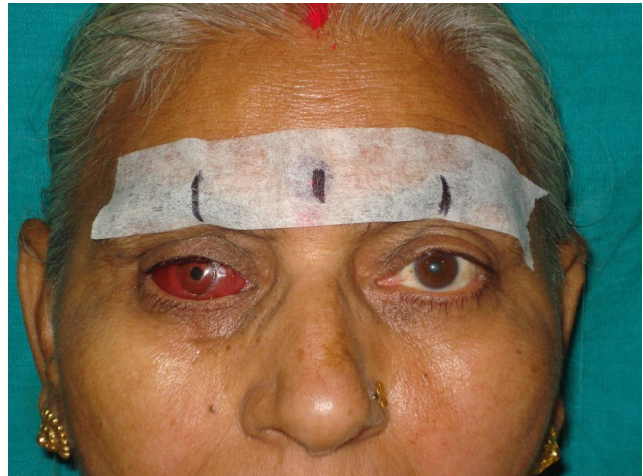

Fig. X: Photograph showing wax pattern trial.

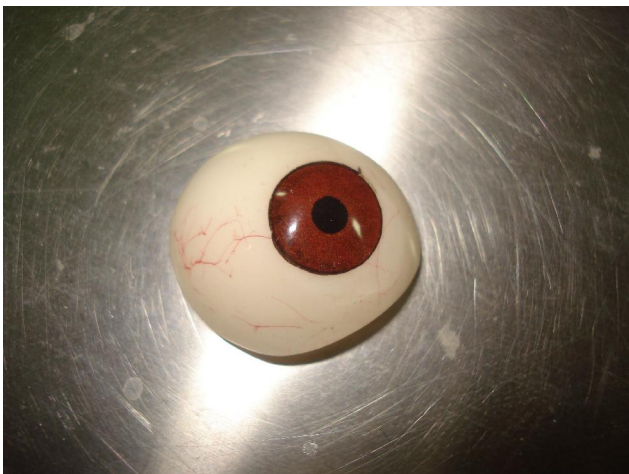

Fig. IX: Photograph showing stock eye from which section of the iris was taken.

The selection of the iris for the patient was done by trimming and modifying a commercially available stock eye which had almost matching resemblance to her unaffected natural eye (Fig. IX).

### Wax pattern trial

First of all the fullness of the both palpabre and the eye socket was checked along with the extensions, this was confirmed by asking the patient to close her eyes and patient was inspected from the profile view. During tryin the iris was placed keeping in mind the symmetry with the iris of the adjacent unaffected right natural eye of the patient. To achieve this exact location, a micro tape was secured on the fore head and the midline of face was marked along with the position of the natural iris while she was looking straight ahead to a distant object (Fig. X).

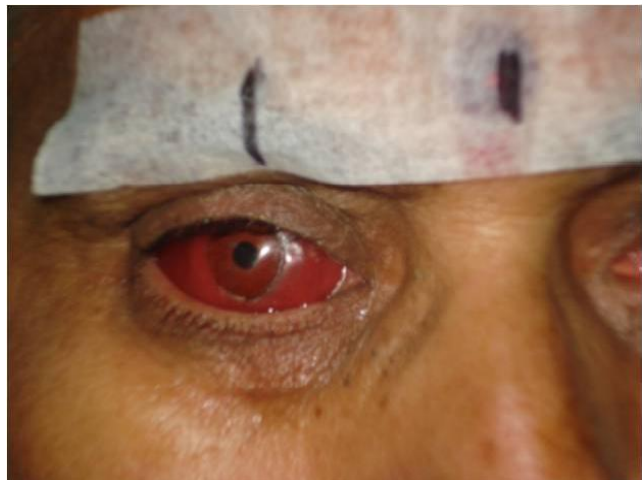


Fig. XI: Photograph showing iris placement.

The distance was measured from the midline to the centre of the pupil of the natural eye and the same distance to the left side was marked and engraved into the wax pattern. The pattern was taken out and keeping this position in mind, the iris was placed and adjusted according to the horizontal and vertical axis (Fig.XI). Also her eye movements were checked for symmetry and function and it was found that the wax tryin moved and synchronised in harmony with the patient's natural eye movements. This gave a realistic feeling and instilled confidence in the patient.

### Flasking

After the trial of wax pattern the secondary impression cast was trimmed about the size of the flask. On to this the wax pattern was sealed and the whole assembly invested as in the case of a complete denture laboratory procedures. A handle was attached to the iris which




Fig. XII: Photograph showing wax pattern invested with handle attachment (acrylic stick)

was made of cold cure acrylic so as to prevent the displacement of the iris during dewaxing.

Dewaxing

The second pour was poured in such a way that the handle attached to the iris was embedded into the plaster of the counter flasking. Then the dewaxing was done after the final set, taking care so that there was complete wax elimination from the mold space.




Fig. XIII: Photograph showing dewaxing of flased wax pattern.

Packing and flasking

This step is the most important, as it involves the characterisation of the prosthesis before packing with tooth coloured heat cured polymethylmethacrylate of appropriate shade, matching with the colour of the sclera of normal eye of the patient. A thin layer of heat cured clear acrylic was spread evenly in and around the iris. The characterisation is done so as to achieve the vitality necessary to give it a life like appearance and blend with the patient's natural appearance and cosmetics. After the characterisation, the mold was packed with heat cured tooth coloured acrylic resin of appropriate shade and kept for bench curing to enable complete polymerisation and prevention of any excess unreacted monomer. This enables the minimisation of

porosities and gives a good finish to the prosthesis.

We used long curing cycle of 4-6 hours so as to prevent the presence of any residual monomer in the prosthesis which is very essential. It prevents any untoward irritation or sensitivity and thereby rejection of the prosthesis by the patient. The eye socket is extremely sensitive and the residual conjunctiva and related structures react to any surface roughness and irregularities.

Final finishing and polishing of the prosthesis

Finished prosthesis requires a highly polished surface which would have a glass like finish to provide maximum adaptation and overall success of the prosthesis (Fig.XIV).

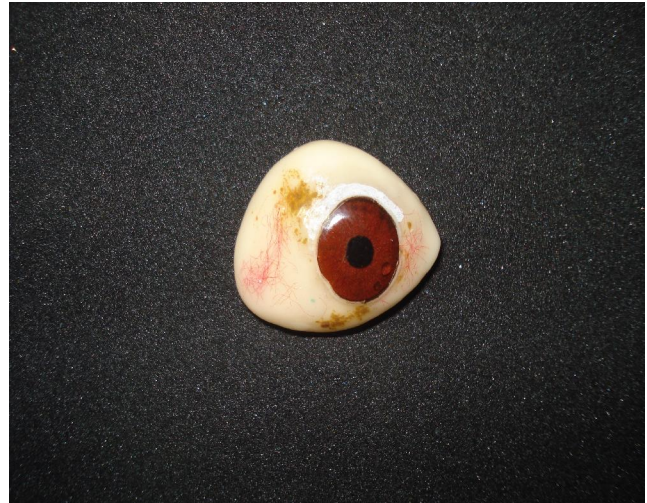

Fig.XIV:Photograph showing finished prosthesis with characterization.



Fig.XV: Photograph with finished ocular prosthesis in place.

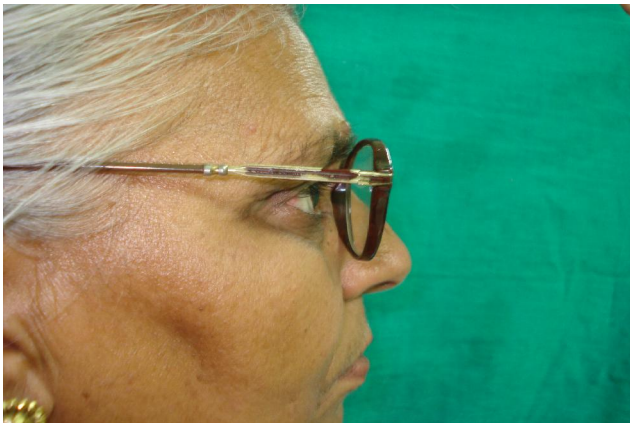

Fig.XVI: Photograph showing patient profile view of finished prosthesis.

The final outcome of the prosthesis was ascertained from the satisfied look on the face of the patient and from the follow up a week later. (Fig. XV & XVI). The patient was given instruction for wearing the prosthesis and it's home care protocol which is given below:

- Prosthesis should be handled with care and with clean hands.
- Removal of Acrylic prosthesis during night is ideal. It should be soaked in an antibacterial solution to kill the surface bacteria.
- Routine polishing of prosthesis should be done every year to prevent deposition of protein and bacteria.
- Children and those living in arid climates require polishing every six month.

### Discussion:

A well-made and properly planned ocular prosthesis maintains its orientation when patient performs various movements. With the development of newer materials the socket can be finely recorded on which custom made ocular acrylic prosthesis (Sykes, 1996) can be fabricated with exact fit and esthetics although the prosthetic rehabilitation may be enhanced with the use of implants, can coordinate the movements with natural eye, as they are not always possible or feasible. More, over the use of stock ocular prosthesis of appropriate size and colour cannot be neglected, a custom made ocular prosthesis provide better results functionally as well as aesthetically (Doshi & Aruna, 2005).

### Conclusion:

The use of custom-made ocular prosthesis has been a boon to the patients who cannot afford for the

implant replacements. Also, as discussed above, the esthetic and functional outcome of the prosthesis was far better than the stock ocular prosthesis (Cain, 1982). Although the patient cannot see with this prosthesis, it has definitely restored her self-esteem and allowed her to confidently face the world.

### Bibliography:

1. Benson P: The fitting and fabrication of a custom resin artificial eye. *The Journal of Prosthetic Dentistry*, 1977; 38(5):532-538.
2. Cain JR: Custom Ocular Prosthetic. *The Journal of Prosthetic Dentistry*, 1982; 48(6):690-694.
3. Doshi PJ, Aruna B: Prosthetic management of patient with ocular defect. *The Journal of Indian Postodontic Society*, 2005 :5(1): 37-38.
4. Lubkin V, Sloan S: Enucleation and psychic trauma. *Advances in Ophthalmic Plastic and Reconstructive Surgery*, 1990; 8:259-262.
5. Sykes LM: Custom made ocular prosthesis: A clinical report. *The Journal of Prosthetic Dentistry*, 1996;75(1): 1-3.
6. Taicher S, Steinberg HM, Tubiana I, Sela M: Modified stock-eye ocular prosthesis. *The Journal of Prosthetic Dentistry*, 1985; 54(1):95-98.
7. Trawnik JR: Dallas eye Prosthetics cited from [www.dallaeye.net](http://www.dallaeye.net).