



CODEN [USA]: IAJPBB

ISSN : 2349-7750

**INDO AMERICAN JOURNAL OF
PHARMACEUTICAL SCIENCES**

SJIF Impact Factor: 7.187

Available online at: <http://www.iajps.com>

A Case Report

**MANAGEMENT OF DEEP VENOUS THROMBOSIS IN MAY-
THURNER SYNDROME CASE REPORT****Qais Abbushi, Abrar Nasser Almaghrabi, Mahmoud Amjad Keemawi,****Moayad Zeyad Aljuhani**

Specialized Medical Center Hospital - Riyadh

Abstract:

This is a case of a 37-year-old previously healthy female who presented to the hospital with new-onset left leg pain, which was diagnosed and treated as an ankle sprain. Latter on presented with leg swelling and left flank pain; a doppler ultrasound revealed extensive deep venous thrombosis involving the left lower limb, from the common femoral vein to the posterior tibial veins and the greater and lesser saphenous veins. She was started on therapeutic enoxaparin with no response, then she was on heparin infusion, unfortunately without any clinical response. A CT scan of the abdomen was requested before inferior vena cava (IVC) filter insertion revealed compression of the left common iliac vein where it passes behind the left common iliac artery, suggesting May-Thurner syndrome. A decision was made for Catheter-directed Thrombolysis and IVC Filter insertion. The patient underwent mechanical thrombectomy and lysis of a vascular clot, with successful results. The final venogram showed clear patency and no residual clot, and an IVC filter was inserted. The patient is currently stable and has shown improvement in symptoms and mobility.

Key words: Deep venous thrombosis; Iliac vein compression syndrome; May-Thurner syndrome; Thrombolysis; Coagulation disorders.

Corresponding author:**Qais Abbushi,**

Specialized Medical Center Hospital – Riyadh

QR code



Please cite this article in press *Qais Abbushi et al, Management Of Deep Venous Thrombosis In May-Thurner Syndrome Case Report, Indo Am. J. P. Sci, 2023; 10 (08).*

INTRODUCTION:

May-Thurner Syndrome (MTS) is a condition with venous compression in the ileocecal region by the arterial system.^[1] The condition occurs when the left common iliac vein is compressed between the lumbar spine and right common iliac artery^[2]

MTS is also known as Cockett syndrome or iliac vein compression syndrome. Compression of the left iliofemoral vein by the right common iliac artery was first observed in 1851 by Dr. Rudolph Virchow in the cadavers of patients with left iliofemoral thrombosis. However, the phenomenon of intraluminal fibrous bands being present in the left iliofemoral vein via compression of the right common iliac artery was officially recognized in 1957 by Dr. May and Dr. Turner.^[4] In this case we will demonstrate extensive clot in deep and superficial veins of the lower limb of an otherwise healthy female where the abdominal CT scan reveals abnormality of the iliac vein system causing the extensive DVT.

Due to its rare nature, the precise incidence and prevalence of MTS is not entirely known; however, it is believed that the data we have today is underestimated from reality.^[5] The condition is believed to affect young and middle-aged women more so than their male counterparts. May-Thurner syndrome is thought to be the root cause of 2% to 5% of all deep vein thrombosis (DVT). However, the frequency has been reported to be significantly greater in numerous retrospective cadaveric and radiographic studies. Numerous postmortem studies on randomly chosen people revealed an incidence of MTS ranging

from 14% to 32%. According to radiographic investigations, which exclusively targeted individuals with left lower extremity DVT, MTS incidence ranged from 22% to 76% in these patients.^[6] According to a thorough analysis of the research, women have MTS two times more frequently than males do. Additionally, it seems that men had more severe symptoms including higher degrees of pain and swelling in their left leg whereas the majority of women with the condition were of younger age and had a higher incidence of pulmonary embolisms along with deep vein thrombosis.

CASE PRESENTATION:

A 37-year-old previously medically healthy female presented to the hospital with new-onset left leg pain, swelling, and left flank pain. The patient had a left leg trauma two weeks prior and had a cast on for a week for an ankle sprain. She also had a history of using contraceptive patches.

Doppler ultrasound showed extensive deep venous thrombosis was seen involving the left lower limb extending from the left common femoral vein to the superficial and deep femoral vein to anterior and posterior tibial veins (Figure 1). Enlarged echogenic incompressible lumen of left common femoral vein, superficial and deep femoral vein, popliteal vein, anterior and posterior tibial veins with no flow on color Doppler. Enlarged echogenic lumen representing thrombosis involves greater and lesser saphenous veins. A CT pulmonary angiography (CTPA) showed no obvious pulmonary embolism (PE).

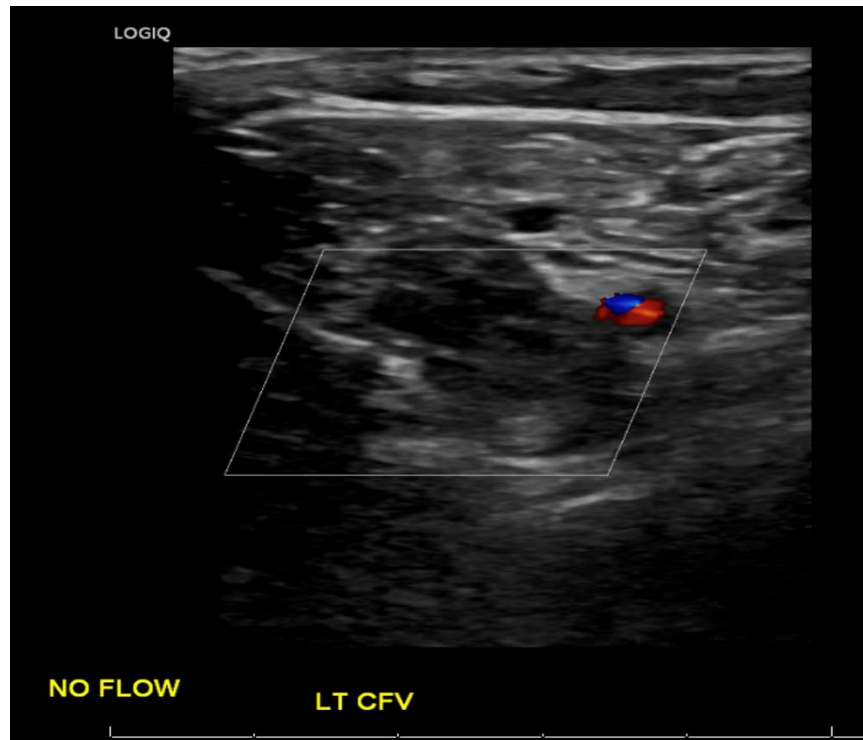


Figure 1: Extensive deep venous thrombosis left lower limb extending from common femoral vein

The patient was initially started on therapeutic enoxaparin, however, the patient remained in severe pain and the swelling is increasing. After that, the patient was started on heparin infusion with regular monitoring of aPTT as per the heparin infusion protocol. Unfortunately, the patient was not reaching the therapeutic range which raised the question of heparin resistance. Due to the unavailability of genetic tests for heparin resistance, we were not able to proceed with this idea. Due to the extension of the DVT, a decision was made for Catheter-directed thrombolytic and Inferior Vena Cava (IVC) Filter insertion.

A CT abdomen was requested before IVC filter insertion revealed compression of the left common iliac vein where it passes behind the left common iliac

artery, suggesting May-Thurner syndrome (Figure 2). Thrombosis was seen in the left common iliac vein extending from its upper end along its course into the left internal and external iliac veins, as well as the left common femoral, superficial femoral, and deep femoral veins. Collaterals were seen in the pelvic cavity mainly on the left side. The inferior vena cava had a relatively small diameter, but there was no obvious thrombosis at the level of the inferior vena cava or right common iliac, internal, external iliac, and visualized part of the right common femoral, superficial femoral, and deep femoral veins. A tiny hepatic cyst, a normal variant of the prominent right extrarenal pelvis with fullness in the collecting system of the right kidney without obvious urinary stones, and a tiny fatty umbilical hernia were also noted.

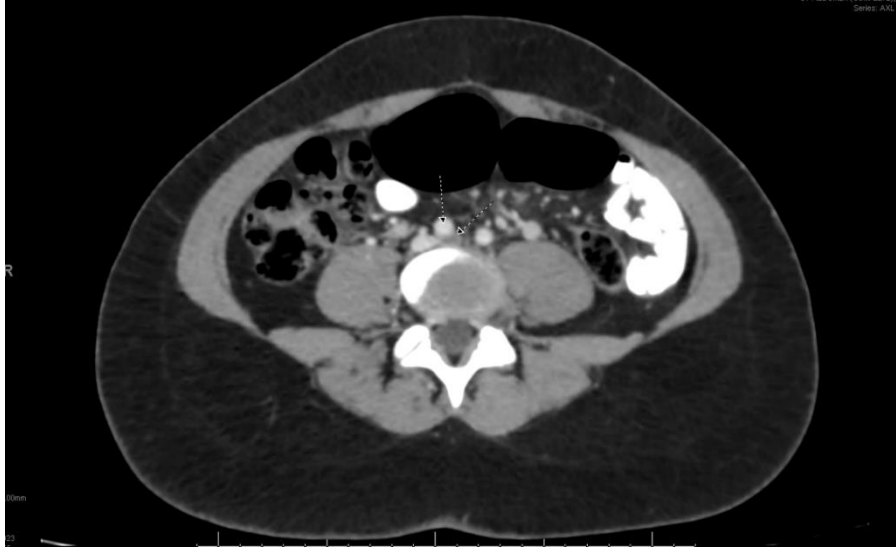

Figure 2: Compression of the left common iliac vein where it passes behind the left common iliac artery suggesting of May Thurner Syndrome

A few days later the patient underwent mechanical thrombectomy and lysis of a vascular clot. The procedure was successful, and there were no complications. A Venogram of the left femoral and iliac showed diffuse multiple filling defects representing clots occluding the superficial femoral vein and common femoral vein with total occlusion of the left iliac vein. Over guidewire mechanical thrombectomy using the AngioJet DVT kit complete suction of the thrombus was carried out. A Venogram of the iliac vein on the left side demonstrates severe stenosis at the common iliac artery distally and diffuse narrowing throughout the common iliac artery on the

left side (Figure 3). A venoplasty 12 mm balloon was used with a very good response and a follow-up venogram showed clear patency of the iliac. The final venogram showed clear patency and no residual clot throughout the superficial femoral vein, common femoral vein, and iliac vein with free flow into the inferior vena cava (Figure 4). No stenting is required for the left iliac vein. The patient also underwent an IVC filter insertion on the same day. The procedure was successful, and there were no complications. A retrievable IVC filter was deployed in the infrarenal portion of the inferior vena cava.

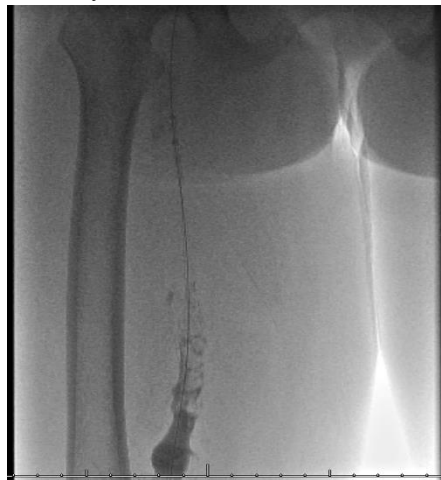

Figure 3: Venogram of the left femoral and iliac shows diffuse multiple filling defects representing clots occluding the superficial and common femoral veins with total occlusion of the left iliac vein.

As of the fourth-day post-procedure, the patient is vitally stable, ambulating, and has less swelling and lower limb pain. Her hemoglobin level is stable, and her creatinine level is normal. She was on heparin infusion for three days post-procedure and then she was shifted to Apixaban 5mg bid to prepare for the discharge.

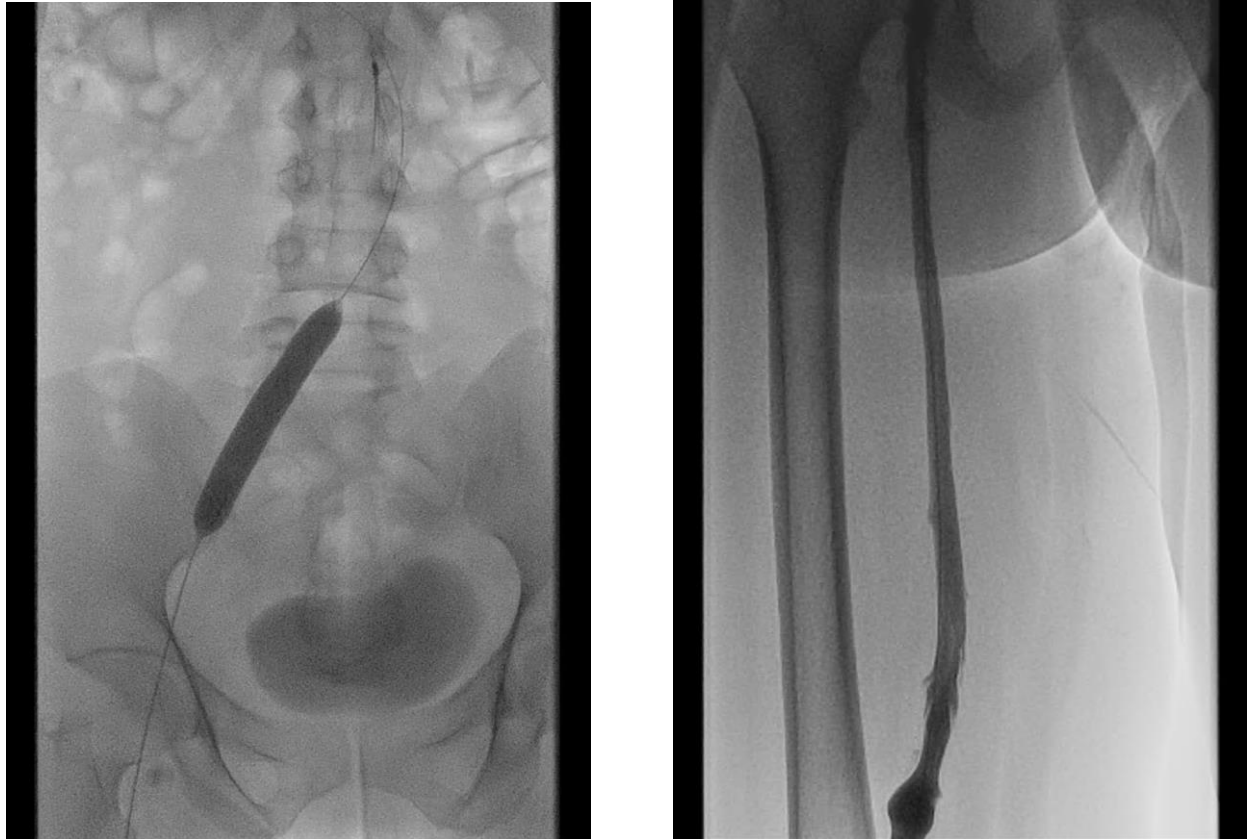


Figure 4: Venoplasty 12 mm balloon used with very good response and follow-up venogram showed clear patency of the iliac.

DISCUSSION:

May-Thurner Syndrome is a condition where the right common iliac artery presses on the left iliofemoral vein just after it leaves the abdominal aorta and before the iliofemoral junction. Veins against bony structures, typically the lower lumbar vertebrae, are compressed over time by the overriding artery, resulting in "venous spurs." Although the left iliofemoral veins thrombose most frequently because of MTS, 'right' sided MTS has also been documented on occasion.^[7] Initially, it was believed that venous spurs and stenosis owing to MTS had existed since birth. May and Thurner hypothesized that intraluminal "spurs" that encouraged clot formation are created when the endothelium is repeatedly irritated by the

pulsing of the artery underlying it.^[8] In 1968, Negus et al. demonstrated that there are fibrous bands between the anterior and posterior walls of the iliofemoral artery.^[10] As repositioning of the artery in their investigation did not result in the recanalization of the veins, Cockett et al. further hypothesized that the band development might be an irreversible process.^[11]

May-Thurner Syndrome (MTS) is a vascular condition which occurs from compression of the left iliac vein by the overlying right iliac artery. Although it almost always presents on the left side, there have been a handful of incidents where right sided MTS has been reported. This anatomical compression results in

various pathological changes. Most notably, MTS is a major risk factor for developing deep vein thrombosis (DVT) in the left lower extremity.

According to Virchow's triad, there are three major contributors to clot formation: hypercoagulability, stasis of blood flow (or any alteration of blood flow in the vessel lumen), and vessel (or endothelial) wall injury.^[12] MTS creates an environment where two of these three criteria are met. Due to the nature of MTS, there is significant anatomical compression of the left iliac vein resulting in disruption to the blood flow distal and around the point of compression. The left iliac vein runs between the spinal vertebrae and the right iliac artery. Some individuals have a larger or more rigid right iliac artery leading to even more compression of the left iliac vein between the two. This anatomical arrangement also leads to increased pressure on the left iliac vein during normal movement and activities.

This prolonged compression of the left iliac vein leads to endothelial injury. This results in damage to the inner lining of the blood vessel that gets worse with time. Endothelial injury can result from increased pressure, shear stress, and inflammation in the compressed area. The compression of the left iliac vein as well as the endothelial damage further exacerbates the disruption of blood flow in the lumen of the vessel resulting in venous stasis. This phenomenon refers to the pooling or slowing of blood in a vessel due to impaired blood flow. This now stagnant blood becomes a significant risk factor for clot or thrombus formation. Blood clots in these deep vessels in the body are termed DVTs. DVTs have the potential of migrating from their original location and entering the pulmonary circulation thus resulting in a pulmonary embolism (PE).

DVTs, if severe enough, can result in necrosis to the distal tissue and can require amputation if not addressed in a timely fashion. The diagnosing of MTS is critical and can prevent poor medical outcomes. Further, PEs are also a clinical emergency and can be life threatening. The mortality rate of untreated PEs can be as high as 30%. It is important to mention that not everyone with MTS will develop DVTs or even have any of its symptoms. Some individuals may have asymptomatic compression of the left iliac vein, while others may develop symptoms such as leg swelling,

pain, or skin changes due to chronic venous insufficiency.

As mentioned in our case, the majority of individuals with MTS will initially be asymptomatic, however, disease progression may occur resulting in symptoms related to venous hypertension. One of the common symptoms patients experience is lower extremity swelling. Most leg swelling with MTS presents on the left side, however, bilateral, and right sided leg swelling have also been reported.^[14] One major indication to MTS is ipsilateral leg swelling without evidence of DVT. This is highly sensitive for a diagnosis of MTS. Tenderness and swelling are usually at their peak at the end of the day when continuous venous compression results in venous hypertension. Another symptom of MTS is venous claudication which is experienced by almost 85% of patients. The venous outflow obstruction caused by MTS results in pain in the thigh and leg as well as tightness in the area, especially with exercise. These symptoms are usually alleviated with rest and elevation of the leg.^[15]

Patients with MTS will not infrequently also present with recurrent superficial vein thrombosis. This is due to the moderate-to-severe degree of venous insufficiency that is caused by MTS. Pts may also present with hyperpigmented skin, venous eczema, and venous ulcers. Finally, a rare symptom of MTS is a ruptured iliac vein and a resultant retroperitoneal hematoma.^[16] This can be life threatening if hemodynamic instability ensues and the bleeding is not addressed in a timely manner.

MTS can be diagnosed with a multitude of modalities. Of these include venous duplex ultrasound, computed tomographic (CT), as was performed in our patient, or magnetic resonance (MR) venography. Iliac vein stenosis can be found with duplex ultrasonography, which also enables dynamic assessment of the condition of the deep veins in the affected extremity. Although proximal DVT can be detected by venous ultrasound with high sensitivity and specificity using the compressibility criterion in B-mode, the deep location of the proximal iliac vein and other factors (such as obesity and overlying gas) may make it difficult for ultrasound alone to accurately diagnose MTS. Cross-sectional imaging is sensitive for determining the location and degree of stenosis in non-

thrombosed veins, identifying venous collaterals, and recognizing other anatomic abnormalities (e.g., CT scan with venous phase, or MR venography). The sensitivity and specificity of CT and MR venograms for the diagnosis of MTS are both greater than 95%, although these imaging modalities necessitate suitable technical protocols for image capture.

The advantage of finding more extrinsic venous compression sources with CT venography may make it better at detecting more severely stenotic lesions, but technical problems such as inadequate contrast opacification might make the test nondiagnostic. Better imaging of the pelvic and spinal structures, such as lumbar vertebral degeneration, protruding or bulging intervertebral discs, osteophytes, or spondylolisthesis, is possible using MR venography. The biggest downside to both CT and MR imaging modalities is their high cost

Treatment of MTS depends on the severity of symptoms as well as whether or not a thrombus is present. In non-thrombotic MTS with either minimal or no symptoms, treatment is mostly conservative. Compression stockings are the treatment of choice for this category and are usually sufficient to relieve any symptoms. For patients with non-thrombotic MTS but moderate-to-severe symptoms, treatment is targeted to improving the severity of the stenosed venous lesion via the use of angioplasty and stenting. Angioplasty alone, however, is not enough and is associated with a high rate of recurrences.^[17] The best method to alleviate the stenosis in this case is with the use of self-expanding stents and post-stenting balloon dilation to allow the stent to fully expand.

In patients with thrombosis and no contraindication to lytic therapy, the gold-standard treatment is full therapeutic anticoagulation. Pharmacomechanical thrombolysis or catheter-directed thrombolysis via intravascular ultrasound can also achieve appropriate anticoagulation and lysis of the clot. Afterwards, angioplasty and stenting of the affected ilioacaval segment is usually done. Anticoagulation alone without the use of angioplasty and stenting is insufficient in appropriately treating MTS and may result in post-thrombotic syndrome. Rates of post-thrombotic syndrome in an inadequately treated patient can be as high as 80-90%.

Finally, in patients with thrombosis and a contraindication to thrombolytic therapy more innovative approaches may be taken to remove the thrombus. This includes rheolytic thrombectomy, rotational thrombectomy, and suction thrombectomy.

CONCLUSION:

MTS is a rare anatomical condition that results from compression of the left iliac vein between the right iliac artery and the spinal vertebrae. The disruption of venous blood flow and endothelial injury caused by this compression makes individuals with MTS highly susceptible to blood clots and DVTs. MTS commonly presents with unilateral lower extremity swelling and pain. Treatment is highly dependent on the presence of a thrombus as well as severity of symptoms but almost always entails angioplasty and stenting of the affected area.

REFERENCES:

1. **Poyyamoli, S., Mehta, P., Cherian, M., Anand, R. R., Patil, S. B., Kalva, S., & Salazar, G. (2021).** May-Thurner syndrome. *Cardiovascular diagnosis and therapy*, 11(5), 1104–1111.
2. **Abboud G, Midulla M, Lions C, El Ngeoui Z, Gengler L, Martinelli T, Beregi JP. (2010).** "Right-sided" May-Thurner syndrome. *Cardiovasc Intervent Radiol.* 33(5):1056-9.
3. **Collum, A. (2021).** What is May-Thurner Syndrome. *RIA Endovascular Radiology Imaging Associates P.C*
4. **Harbin, M. M., & Lutsey, P. L. (2020).** May-Thurner syndrome: History of understanding and need for defining population prevalence. *Journal of thrombosis and haemostasis : JTH*, 18(3), 534–542.
5. **Moudgill N, Hager E, Gonsalves C, et al. (2009)** May-Thurner syndrome: case report and review of the literature involving modern endovascular therapy. *Vascular*; 17:330.
6. **Mangla, A., & Hamad, H. (2022).** May-Thurner Syndrome. In *StatPearls*. StatPearls Publishing.
7. **Burke RM, Rayan SS, Kasirajan K, Chaikof EL, Milner R. (2006)** Unusual case of right-sided May-Thurner syndrome and review of its management. *Vascular.*; 14(1):47-50.
8. **Abboud G, Midulla M, Lions C, El Ngeoui Z, Gengler L, Martinelli T, Beregi JP. (2010)**

- "Right-sided" May-Thurner syndrome. *Cardiovasc Intervent Radiology*.; 33(5):1056-9.
9. **Andrew R. Forauer, Joseph J. Gemmete, Narasimham L. Dasika, Kyung J. Cho, David M. Williams, (2002)** Intravascular Ultrasound in the Diagnosis and Treatment of Iliac Vein Compression (May-Thurner) Syndrome, *Journal of Vascular and Interventional Radiology*, Volume 13, Issue 5, Pages 523-527, ISSN 1051-0443
 10. **Negus D, Fletcher EW, Cockett FB, Thomas ML. (1968)** Compression and band formation at the mouth of the left common iliac vein. *Br J Surg*.; (5):369-74.
 11. **Cockett FB, Thomas ML. (1965)** The iliac compression syndrome. *Br J Surg*.; 52(10):816-21.
 12. **Kushner A, West WP, Khan Suheb MZ, et al. (2022).** Virchow Triad. *Stat Pearls*
 13. **BMJ Publishing Group. (2017)** Virchow's Triad of the Three Broad Categories. *Research Gate*.
 14. **Birn J, Vedantham S. (2015)** May-Thurner syndrome and other obstructive iliac vein lesions: meaning, myth, and mystery. *Vasc Med*; 20:74.
 15. **Bjorndal RI. (1970)** Intermittent venous claudication. A report of two cases. *Acta Chir Scand*; 136:641.
 16. **Hosn MA, Katragunta N, Kresowik T, Sharp WJ. (2016)** May-Thurner syndrome presenting as spontaneous left iliac vein rupture. *J Vasc Surg Venous Lymphat Disord*; 4:479.
 17. **Mickley V, Schwagierek R, Rilinger N, et al. (1998)** Left iliac venous thrombosis caused by venous spur: treatment with thrombectomy and stent implantation. *J Vasc Surg*; 28:492.