

DOI: 10.5281/zenodo.8215967

CASE REPORT

11

ANAESTHETIC MANAGEMENT OF THORACIC GANGLIONEUROMA IN PAEDIATRIC PATIENT – A CASE REPORT

Dr. Neelkumar H. Patel¹, Dr. Misha B. Agarwal², Dr. Jayshree M. Thakkar³, Dr. Rajan P. Saxena⁴, Dr. Kinjal M. Solanki⁵

¹Resident doctor, ²Assistant Professor, ³Professor and Head of Department, ⁴Resident doctor, ⁵Resident doctor,

Department of Anaesthesiology, Gujarat Cancer and Research Institute, Civil Hospital, Ahmedabad, Gujarat

Corresponding Author Name: Dr. Neelkumar Hitendrabhai Patel,

Email Id: neel6076@gmail.com, Contact Number: 7359315508

ABSTRACT

BACKGROUND: Ganglioneuroma is a rare neurogenic tumor, which commonly arises from sympathetic ganglion cells. These are most common tumor occupying posterior mediastinum. It can grow into a massive size and cause compression symptoms like difficulty in breathing, wheezing, cough, spinal deformity or spinal compression.

CASE SUMMARY: A 6-year old female patient presented with complain of shortness of breath for past 2 years which was increasing progressively. The chest radiograph suggested opaque right hemithorax. CECT revealed 11.8 × 10.5 × 13 cm sized lesion in right hemithorax. It compresses main right bronchus causing severe luminal narrowing. Parenchyma of right lung appears collapsed. Single lumen cuffed endotracheal tube inserted adjusting low tidal volume and high frequency of respiratory rate to avoid lung injury due to high airway pressure. At the end of procedure lung recruitment done by manual ventilation for 3 min. After nebulization with budesonide, patient was extubated and put on O₂ mask. Postoperative chest radiograph revealed expansion of most of the right lung.

CONCLUSION: Anaesthetic management of such patient, require meticulous consideration towards airway management, positioning, hemodynamic stability and goal directed fluid therapy. Strict post-operative respiratory and cardiac status monitoring; and post-operative analgesia are major lookouts.

KEYWORDS: Intrathoracic Ganglioneuroma, Paediatric, Two lung ventilation, Single lumen endotracheal tube

INTRODUCTION

Ganglioneuroma is a rare neurogenic tumor, which commonly arises from sympathetic ganglion cells. These are most common tumor occupying posterior mediastinum. It is usually asymptomatic and discovered incidentally in older paediatric patients or adults.

It can grow into a massive size and cause compression symptoms like difficulty in breathing, wheezing, cough, spinal deformity or spinal compression. Radiological examination is essential for diagnosis, and characteristics of the tumor.

In this report, we present a young 6-year-old child with a giant posterior mediastinal ganglioneuroma who presented with dyspnoea. radiological findings suggest large, well defined hypodense lesion in right hemithorax.

PATIENT INFORMATION

A 6-year old young female patient weighting 14 kg came to opd with complain of shortness of breath for past 2 years which was increasing progressively and got aggravated on exertion. Patient preferred sleeping in the right lateral position.

No h/o of any addiction or comorbidity, no chemotherapy or radiotherapy taken.

PHYSICAL EXAMINATION

Patient had MPG grade I. HR – 97/min, BP – 112/75 mmHg, SPO₂ – 96% on room air, respiratory rate – 18-20/min.

On auscultation air entry was decreased on upper, middle, and lower zone of right lung, CVS/CNS normal.

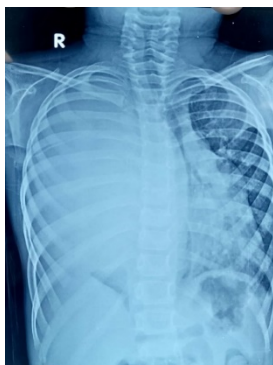DIAGNOSTIC ASSESSMENT

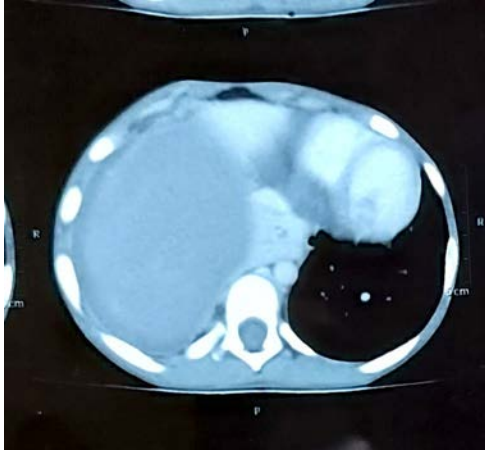
All routine Investigation were within normal limits.

On Chest X-Ray (PA View) presence of opaque right hemithorax noted with blunting of right cp angle and obliteration of right dome of diaphragm and shift of mediastinum towards opposite side , possibility of gross pleural effusion appears likely.

CECT SCAN OF THORAX revealed $11.8 \times 10.5 \times 13$ cm well defined mildly homogenously enhancing hypodense lesion is noted in right hemithorax, it extend into right intervertebral foramen of T4 vertebra, it compresses right main bronchus causing severe luminal narrowing, it causes shift of trachea and mediastinum to left side, visualized parenchyma of upper and lower lobes of lung appears collapsed, mild pleural effusion on right side. Tumor abuts right subclavian artery and superior vena cava.

Chest radiograph reveals an opacity of the whole right hemithorax.





Enhanced CT scan image of axial section showed the mass pushing mediastinal organs to the contralateral side.

INTERVENTION

Informed written consent was taken.

Patient was taken on operation table; all monitors were attached.

Well-functioning 22G IV line secured.

Pre-medication: Inj. Glycopyrrolate - 0.05 mg IV, Inj. Ondansetron - 1.5 mg IV, Inj. Ranitidine – 15 mg IV given

Pre-oxygenation for 3-5 min with 100% O₂ via JR circuit O₂ flow rate at 6-8 L/min.

IV induction done with inj. Ketamine – 15, Inj. Pentothal – 75 mg and Inj. Atracurium – 10 mg.

Direct laryngoscopy was done and 5 mm cuffed Portex ETT inserted orally. B/L air entry checked and tube fixed at 14 cm.

Single lumen endotracheal tube inserted to provide two lung ventilation adjusting low tidal volume and high frequency of respiratory rate to avoid lung injury due to high airway pressure.

Under USG guidance 5 Fr central venous catheter was inserted in right femoral vein.

Measures were taken to prevent hypothermia.

Constant monitoring of Blood pressure, Pulse rate, ECG, SPO₂, End tidal CO₂,

Patient ventilated by pressure control mode of mechanical ventilation. Pressure of 25 cmH₂O set for delivering 120 ml of tidal volume. After removal of tumor, required pressure to deliver 120 ml of tidal volume was reduced from 25 to 15 cmH₂O. Respiratory rate was 22/min.

Anaesthesia was maintained with O₂, sevoflurane with mac of 0.8-1.5, medical air and Inj. Atracurium – 2 mg IV maintenance dose.

For analgesia Inj. Paracetamol – 230 mg IV was given intraoperatively as a part of multimodal analgesia.

At the end of procedure lung recruitment done by manual ventilation for 3 min. Inj. Bupivacaine – 0.5% 3 CC and Inj. Xylocaine – 2% 3 CC given for intercostal nerve block.

Intraoperative period was uneventful. At the end of procedure patient reversed after spontaneous breathing effort with Inj. glycopyrrolate – 0.1 mg IV and Inj. Neostigmine – 1 mg IV. Patient nebulized with budesonide by T-piece. Patient successfully extubated and kept on O2 mask at O2 flow rate 3L/min for 2 hours and then patient shifted to room air and was hemodynamically stable.

Duration of surgery – 4 hours, Total iv fluid – 1000 ml, Blood loss – 120 ml, Urine output – 300 ml.

DISCUSSION

Surgical resection was recommended due to large size of the mass and the symptoms due to the mass compression. The patient was placed in the left lateral decubitus position and a right-sided posterolateral thoracotomy was performed under general anaesthesia.

A huge mass was found to be occupying almost the whole right hemithorax, pushing the lungs to the superior, and was extrapleural with no invasion to the adjacent structures.

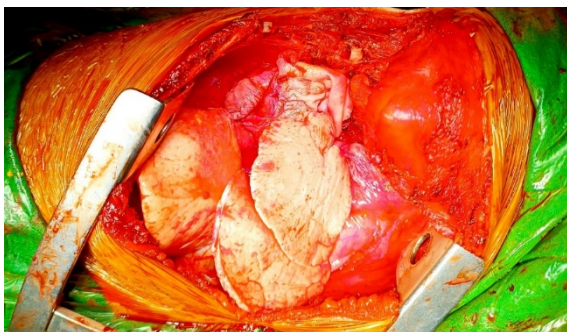
Double lumen tube was not inserted because lung isolation was not required it also avoid injury to vocal cord, post-operative laryngeal oedema and sore throat.

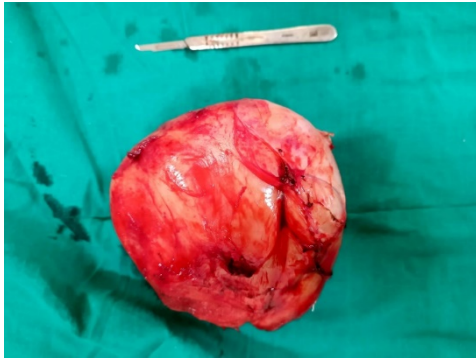
After removal of tumor required pressure to deliver 120 ml of tidal volume was reduced from 25 to 15 cmH₂O due to relieve of mass compression.

Patient was in stable condition and shifted to icu. Post-operative chest radiograph revealed expansion of most of the right lung. The patient was then discharged home with no complications.

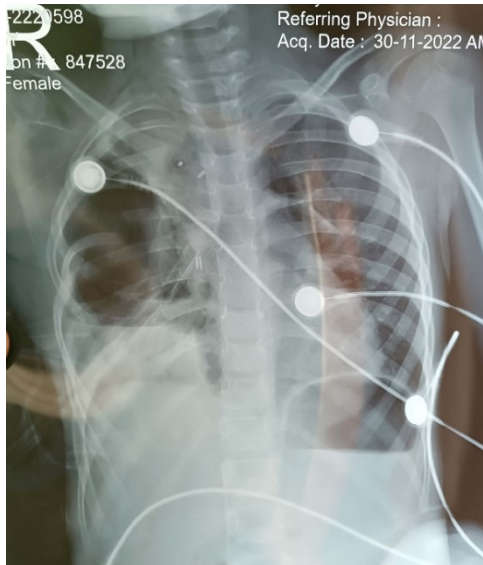Anaesthetic management of such patient require meticulous consideration towards airway management, positioning, temperature regulation, hemodynamic stability and goal directed fluid therapy. Strict post-operative respiratory and cardiac status monitoring and post-operative analgesia are major lookouts.

Posterolateral thoracotomy was performed on right side under general anaesthesia.





Whitish solid and capsulated tumor.



Chest radiograph reveals post-operative expansion of right lung.

CONCLUSION

Major concern for anaesthetic management in patient with large intrathoracic ganglioneuroma include one lung ventilation, ventilation of both lungs with low tidal volume, paediatric age group, massive blood loss, intraoperative hypothermia, prevention of pulmonary oedema, which require meticulous pre-operative planning. Detailed pre-operative evaluation, planning, intraoperative management and postoperative physiotherapy, multidisciplinary approach are the basis of successful management.

REFERENCES

1. Nugraha HG, Hernowo RPA. A Rare Case of Giant Mediastinal Ganglioneuroma in A 3-year-old. *Radiol Case Rep.* 2021 Nov 1;17(1):80-85. doi: 10.1016/j.radcr.2021.10.010. PMID: 34765066; PMCID: PMC8571537.
2. Lima AF, Moreira FC, Menezes A, Dias L. Cervical Ganglioneuroma in Pediatric Age: A Case Report. *Turk Arch Otorhinolaryngol.* 2018 Dec;56(4):237-240. doi: 10.5152/tao.2018.3690. Epub 2018 Dec 1. PMID: 30701121; PMCID: PMC6340319.
3. Sanal, Murat & Meister, Bernhard & Kreczy, A. & Unsinn, K. & Hager, Jennifer. (2005). Intrathoracic ganglioneuroma and ganglioneuroblastoma: Report of four cases. *European Surgery.* 37. 317-320. 10.1007/s10353-005-0178-8.

4. Kan, Chan Siang MD, MRCS (Edin)^a; Chang, Tze Sen MD, MRCS (Ire)^a; Cheong, Lu Jeat MD^a; Dzin, Manisah Binti Mohd. MB Bch BAO (Ire), Dr (Path)^b; Karupiah, Saravanan MMED (Surgery)^a; Jong, Yuan Hsun MBBS (Mal), FRCS (Ire), FRCS CTh (Malaysia)^a; Soon, Sing Yang MBCHB (Edin), MRCS (Edin), FRCS CTh, CCT (UK)^a. Uncommon presentation of a huge intrathoracic ganglioneuroma in an 8-year-old child: a rare case report. *International Journal of Surgery Oncology* 4(6):p e80, November 2019. | DOI: 10.1097/IJ9.0000000000000080
5. Kumar, Alok & Singh, Simrandeep & Tiwari, Nikhil & Joshi, Ankur. (2022). Airway management of a giant thoracic ganglioneuroma causing airway obstruction in a 3-year-old child. *Airway*. 5. 10.4103/arwy.arwy_7_22.

CONFLICT OF INTEREST: NIL

FUNDING: NIL

ACKNOWLEDGEMENTS: NIL