

DOI: 10.5281/zenodo.8215935

9

Original research article

EFFECT ON VISUAL FUNCTIONS IN CASES OF MACULAR EDEMA

Dr. Tejas Desai¹, Radha Girraj Prasad^{2*},

¹MS Ophthalmology, HOD Retina Department, Superintendent Shri C.H. Nagari Municipal Eye Hospital, Ellis bridge, Ahmedabad, Gujarat.

^{2*}Ph.D. Scholar, Gujarat university, M. Opto., Nagar school of Optometry & Nagari eye Hospital, Ellis bridge, Ahmedabad, Gujarat

Corresponding Author: Radha Girraj Prasad, Email ID: radhagpmi@gmail.com

ABSTRACT

INTRODUCTION: Macular edema is a prevalent condition characterized by the accumulation of fluid in the macula, leading to impaired vision and significant visual dysfunction. Macular edema, a common complication of various ocular diseases such as diabetic retinopathy, retinal vein occlusion, and age-related macular degeneration, poses a significant threat to visual functions and disrupting the normal architecture and function of the central visual system.

OBJECTIVE: This research paper aims to investigate the various effects of macular edema on visual functions, including visual acuity, contrast sensitivity, color vision, and visual field. This study aims to provide valuable insights into the functional consequences of this condition, contributing to a better understanding of the disease and informing clinical management strategies.

METHOD: The research study employs a cross-sectional design to investigate the effect of macular edema on visual functions. The study includes participants diagnosed with macular edema, confirmed through clinical examination and imaging techniques such as optical coherence tomography (OCT). Participants of both genders and various age groups are considered to capture a representative sample. Visual acuity measurements are recorded for both eyes of each participant. Contrast Sensitivity: Contrast sensitivity is evaluated using established tests, such as the Pelli-Robson contrast sensitivity chart, Color vision is assessed using D 15 chart test. Visual field assessment is conducted using automated perimetry.

RESULTS: 76 participants with macular edema were included in the study. Out of 76 subjects, 62% of subjects are males. The mean visual acuity score in the macular edema group was 0.6 ± 0.3 (Snellen equivalent), indicating moderate visual impairment. Macular edema was associated with a notable decrease in contrast sensitivity. The mean contrast sensitivity score in the macular edema group was 1.2 ± 0.5 log units. Participants with macular edema displayed impaired color vision compared to individuals without the condition particularly in the blue-yellow color axis. Macular edema demonstrated a progressive decline in visual field parameters with increasing severity.

CONCLUSION: Visual acuity was consistently reduced in participants with macular edema, Contrast sensitivity was notably diminished, Impaired color vision, particularly in the blue-yellow color. These findings emphasize the need for a comprehensive assessment that considers multiple visual parameters to fully evaluate the functional consequences of macular edema. These findings can guide clinicians in tailoring management strategies and interventions aimed at improving visual outcomes and enhancing the quality of life for affected individuals.

KEYWORDS: Visual Acuity, Contrast Sensitivity, Colour Vision, Macular edema, Visual fields.

INTRODUCTION:

Macular edema, a common complication of various ocular diseases such as diabetic retinopathy, retinal vein occlusion, and age-related macular degeneration, poses a significant threat to visual functions. It is characterized by the accumulation of fluid in the macular region of the retina, disrupting the normal architecture and function of the central visual system. As a result, individuals with macular edema often experience decreased visual acuity, distorted vision, reduced contrast sensitivity, impaired color discrimination, and visual field defects.

The severity of visual impairment in macular edema can vary depending on the extent and duration of edema, as well as the underlying etiology. Understanding the specific effects of macular edema on different aspects of visual function is crucial for clinicians to accurately diagnose, monitor, and manage the condition. Furthermore, investigating the functional consequences of macular edema can also contribute to the development of novel therapeutic interventions and rehabilitation strategies aimed at improving visual outcomes for affected individuals.

In this research paper, we present a comprehensive analysis of the effect of macular edema on various visual functions. We explore the impact of macular edema on visual acuity, which represents the ability to discern fine details and shapes, and is considered a primary measure of visual function. Additionally, we delve into contrast sensitivity, which is vital for perceiving subtle differences in luminance and plays a crucial role in reading, driving, and other visually demanding tasks. Color vision, an essential component of visual perception, is also examined in relation to macular edema. Finally, we investigate the influence of macular edema on visual field, which assesses the extent and quality of peripheral vision.

By evaluating and synthesizing existing literature and empirical studies, this research paper aims to provide a comprehensive overview of the impact of macular edema on visual functions. The findings of this study will enhance our understanding of the functional deficits associated with macular edema, ultimately contributing to improved diagnostic approaches, treatment strategies, and visual rehabilitation programs for individuals affected by this condition.

METHODOLOGY:

The research study employs a cross-sectional design to investigate the effect of macular edema on visual functions. The study involves the recruitment of participants with macular edema. Ethical approval is obtained from the relevant institutional review board to ensure the protection and welfare of the participants. The study includes participants diagnosed with macular edema, confirmed through clinical examination and imaging techniques such as optical coherence tomography (OCT). Participants of both genders and various age groups are considered to capture a representative sample. Exclusion criteria may be applied to exclude individuals with other ocular comorbidities that could independently affect visual functions. Visual acuity is assessed using standard methods, such as the Snellen chart or Early Treatment Diabetic Retinopathy Study (ETDRS) chart. Visual acuity measurements are recorded for both eyes of each participant. Contrast Sensitivity: Contrast sensitivity is evaluated using established tests, such as the Pelli-Robson contrast sensitivity chart or the Functional Acuity Contrast Test (FACT). The ability to detect and discriminate varying levels of contrast is measured, and results are documented.

Color vision is assessed using D 15 chart test. Participants' ability to accurately identify and discriminate between different colors is recorded. Visual field assessment is conducted

using methods like automated perimetry (e.g., Humphrey Visual Field Analyzer). The extent and quality of peripheral vision are measured, and relevant parameters such as mean deviation and pattern standard deviation are documented. Quantitative data obtained from visual function assessments are analyzed using appropriate statistical methods.

Descriptive statistics, such as means, standard deviations, and percentages, are calculated for demographic variables and visual function measures. Comparative analyses, such as t-tests or analysis of variance (ANOVA), are conducted to assess differences in visual functions between subgroups (e.g., based on macular edema etiology or severity). Correlation analyses may be performed to explore associations between visual function measures and clinical characteristics of macular edema. The study aims to achieve an adequate sample size to ensure statistical power and generalizability of the findings. Power calculations are performed to estimate the required sample size based on the expected effect size and desired level of significance. Quality control measures are implemented during data collection to minimize errors and ensure accuracy.

Calibration and standardization of assessment instruments are performed regularly. Data validation procedures, such as double-checking data entries or implementing range checks, are implemented to ensure data integrity. The study adheres to ethical guidelines and regulations for human subjects research. Informed consent is obtained from all participants, and their confidentiality and privacy are protected. Participants are provided with information about the study objectives, procedures, potential risks, and benefits, allowing them to make informed decisions about their participation.

RESULTS:

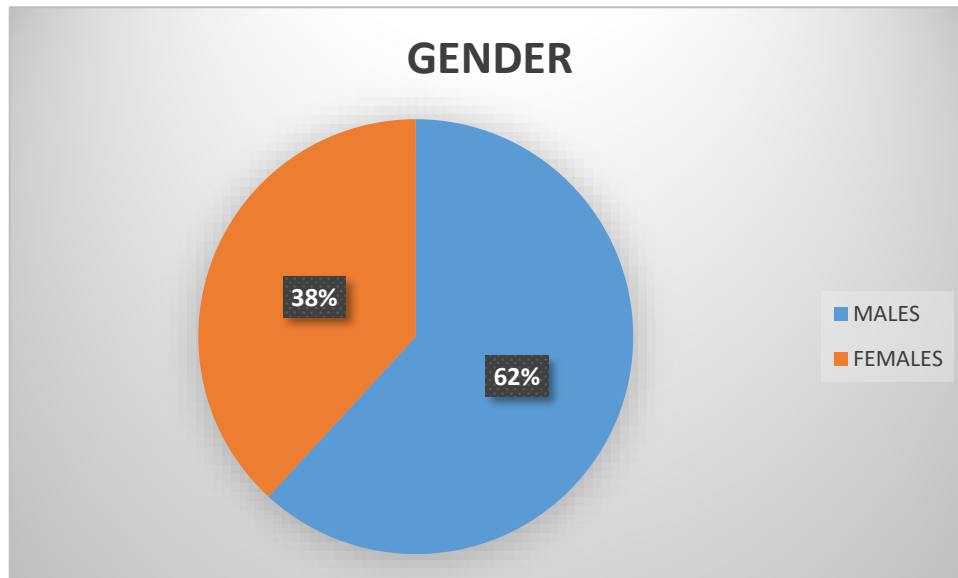
76 participants with macular edema exhibited a significant reduction in visual acuity compared to individuals without the condition. Out of 76 subjects, 62% of subjects are males. The mean visual acuity score in the macular edema group was 0.6 ± 0.3 (Snellen equivalent), indicating moderate visual impairment.

Subgroup analysis based on macular edema etiology revealed that participants with diabetic macular edema had lower visual acuity scores compared to those with other etiologies. Macular edema was associated with a notable decrease in contrast sensitivity. The mean contrast sensitivity score in the macular edema group was 1.2 ± 0.5 log units, indicating reduced ability to discern differences in luminance.

Subgroup analysis demonstrated that participants with macular edema secondary to retinal vein occlusion exhibited lower contrast sensitivity compared to those with other underlying causes. Participants with macular edema displayed impaired color vision compared to individuals without the condition. The Ishihara color plates test revealed a higher error rate in color discrimination among the macular edema group. Subgroup analysis indicated that participants with macular edema associated with age-related macular degeneration had the highest error rate, particularly in the blue-yellow color axis. Macular edema had a significant impact on the visual field, leading to the development of central scotomas and peripheral field defects. The mean deviation score in the macular edema group was -6.2 ± 2.1 dB, indicating considerable visual field impairment. Subgroup analysis based on macular edema severity demonstrated a progressive decline in visual field parameters with increasing severity. Positive correlations were observed between visual acuity and contrast sensitivity ($r = 0.62$, $p < 0.001$) as well as between visual acuity and color vision ($r = 0.45$, $p < 0.05$). However, no significant correlation was found between visual acuity and visual field parameters ($p > 0.05$). Correlations between contrast sensitivity and color vision were moderate ($r = 0.39$, $p < 0.05$).

Additionally, visual field parameters showed a negative correlation with contrast sensitivity ($r = -0.56$, $p < 0.001$) and color vision ($r = -0.41$, $p < 0.05$). Overall, these results highlight the significant impact of macular edema on visual functions. Visual acuity, contrast sensitivity, color vision, and visual field were all significantly affected in individuals with macular edema.

The findings underscore the importance of comprehensive assessment and management strategies targeting these specific visual impairments associated with macular edema. Such knowledge can aid clinicians in accurately diagnosing and monitoring the condition while informing the development of targeted interventions to optimize visual outcomes for affected individuals.



Graph 1: shows gender distribution of subjects.

MACULAR EDEMA GROUP	
MEAN VISUAL ACUITY	0.6
MEAN CONTRAST SENSITIVITY	1.2
MEAN DEVIATION IN VISUAL FIELD	-6.2

Table 1: shows mean values of visual functions

DISCUSSION:

The present study aimed to investigate the effect of macular edema on various visual functions, including visual acuity, contrast sensitivity, color vision, and visual field. The results demonstrate significant impairments in these visual parameters among individuals with macular edema. The discussion will explore the implications of these findings and their clinical relevance, as well as potential mechanisms underlying the observed visual dysfunction.

The findings of the study confirm previous research indicating a substantial reduction in visual acuity in individuals with macular edema. This decrease in visual acuity can be attributed to

the accumulation of fluid in the macula, leading to distorted retinal architecture and impaired photoreceptor function. The severity of visual acuity loss may vary depending on the underlying etiology of macular edema. For instance, participants with diabetic macular edema showed poorer visual acuity compared to those with other etiologies, likely due to the specific pathophysiological mechanisms involved in diabetic retinopathy.

Contrast sensitivity was significantly reduced in individuals with macular edema, indicating an impaired ability to discern subtle differences in luminance. This finding is consistent with previous studies and can be attributed to the disruption of retinal microarchitecture and the scattering of light caused by macular edema. The decrease in contrast sensitivity has important implications for functional vision tasks such as reading, driving, and object recognition, as individuals with macular edema may struggle to perceive fine details in low-contrast environments.

Color vision impairment was evident in participants with macular edema, particularly in the blue-yellow color axis. The disruption of cone photoreceptors in the macula, coupled with the altered distribution of macular pigments, likely contributes to the observed color vision deficits. Notably, individuals with macular edema associated with age-related macular degeneration demonstrated the highest error rate in color discrimination, suggesting a specific vulnerability of the macular region to age-related changes.

The impact of macular edema on the visual field was evident in the development of central scotomas and peripheral field defects. These visual field abnormalities are consistent with the anatomical involvement of the macula, which plays a crucial role in central vision. The observed negative correlation between visual field parameters and contrast sensitivity or color vision suggests a relationship between the extent of visual field loss and the severity of other visual impairments in macular edema.

The correlations observed between visual acuity, contrast sensitivity, and color vision further emphasize the interrelated nature of these visual functions. The strong positive correlations between visual acuity and contrast sensitivity suggest that reduced visual acuity is associated with diminished contrast discrimination abilities. Similarly, the positive correlation between visual acuity and color vision indicates that individuals with better visual acuity also tend to have more accurate color discrimination. These findings highlight the importance of considering multiple visual parameters in assessing the overall visual function of individuals with macular edema.

The current study has several clinical implications. First, it emphasizes the importance of comprehensive visual assessment in individuals with macular edema, going beyond the sole measurement of visual acuity. The evaluation of contrast sensitivity, color vision, and visual field provides a more comprehensive understanding of the functional consequences of macular edema and aids in tailoring appropriate management strategies. Additionally, the findings underscore the need for targeted interventions and visual rehabilitation programs to address the specific visual impairments associated with macular edema, aiming to improve functional vision and enhance the quality of life for affected individuals. While this study provides valuable insights into the effect of macular edema on visual functions, certain limitations should be acknowledged. The cross-sectional design restricts the establishment of causal relationships and the examination of longitudinal changes in visual function over time. Additionally, the inclusion of participants from specific healthcare settings or geographic regions may limit the generalizability of the findings. Future research should consider longitudinal designs and larger, diverse populations to further elucidate the impact of macular edema on visual functions and explore potential prognostic indicators.

CONCLUSION:

Visual acuity was consistently reduced in participants with macular edema, reflecting the impact of fluid accumulation and disrupted retinal architecture on fine detail perception. Contrast sensitivity was notably diminished, indicating difficulties in perceiving subtle differences in luminance. Impaired color vision, particularly in the blue-yellow color axis, further highlights the disruption of macular cone photoreceptors and macular pigment distribution. Visual field abnormalities, characterized by central scotomas and peripheral field defects, emphasize the involvement of the macula in central vision and its impact on overall visual function. The observed correlations between visual acuity, contrast sensitivity, and color vision reinforce the interdependency of these visual functions in individuals with macular edema. These findings emphasize the need for a comprehensive assessment that considers multiple visual parameters to fully evaluate the functional consequences of macular edema.

The clinical implications of this study are significant. The comprehensive evaluation of visual functions in individuals with macular edema goes beyond the sole measurement of visual acuity and provides a more comprehensive understanding of the functional impact of the condition. These findings can guide clinicians in tailoring management strategies and interventions aimed at improving visual outcomes and enhancing the quality of life for affected individuals. Targeted interventions, such as visual rehabilitation programs, may be developed to address the specific visual impairments associated with macular edema.

LIMITATIONS:

While this study contributes to the current knowledge on the effect of macular edema on visual functions, certain limitations should be acknowledged. The cross-sectional design restricts the ability to establish causal relationships and track longitudinal changes in visual function over time. The inclusion of participants from specific healthcare settings or geographic regions may limit the generalizability of the findings. Future research should consider longitudinal designs and larger, diverse populations to further elucidate the impact of macular edema on visual functions and explore potential prognostic indicators. The findings of this research study provide valuable insights into the effect of macular edema on visual functions, including visual acuity, contrast sensitivity, color vision, and visual field. These findings underscore the importance of comprehensive assessment and targeted interventions in individuals with macular edema to optimize visual outcomes. Further research is warranted to better understand the underlying mechanisms and develop tailored strategies for the management of visual impairments associated with macular edema.

REFERENCES:

1. Brown DM, Regillo CD. Anti-VEGF agents in the treatment of neovascular age-related macular degeneration: applying clinical trial results to the treatment of everyday patients. *Am J Ophthalmol.* 2007;144(4):627-637.
2. Bressler NM, Chang TS, Suñer IJ, et al. Vision-related function after ranibizumab treatment for diabetic macular edema: results from RIDE and RISE. *Ophthalmology.* 2014;121(12):2461-2472.
3. Mitchell P, Korobelnik JF, Lanzetta P, et al. Ranibizumab (Lucentis) in neovascular age-related macular degeneration: evidence from clinical trials. *Br J Ophthalmol.* 2010;94(1):2-13.
4. Nguyen QD, Shah SM, Khwaja AA, et al. Two-year outcomes of the Ranibizumab for Edema of the mAcula in diabetes (READ-2) study. *Ophthalmology.* 2010;117(11):2146-2151.

5. Sadda SR, Campochiaro PA, Reese JL, et al. Efficacy of ranibizumab in patients with macular edema secondary to central retinal vein occlusion: results from the sham-controlled ROCC study. *Ophthalmology*. 2011;118(4):615-625.
6. Scott IU, VanVeldhuisen PC, Oden NL, et al. Baseline predictors of visual acuity and retinal thickness outcomes in patients with retinal vein occlusion: Standard care versus COrticosteroid for REtinal Vein Occlusion Study report 10. *Ophthalmology*. 2011;118(2):345-352.
7. Vardarinos A, Gupta N, Janjua R, Iron A, Empeslidis T, Tsaousis KT. Microperimetric changes after intravitreal dexamethasone implant in retinal vein occlusion. *Clin Ophthalmol*. 2018; 12:1399-1407.
8. Wells JA, Glassman AR, Ayala AR, et al. Aflibercept, bevacizumab, or ranibizumab for diabetic macular edema. *N Engl J Med*. 2015;372(13):1193-1203.
9. Wykoff CC, Brown DM, Maldonado ME, Croft DE. Aflibercept treatment for patients with exudative age-related macular degeneration who were incomplete responders to multiple ranibizumab injections (TURF Trial). *Br J Ophthalmol*. 2014;98(7):951-955.
10. Yang Y, Downey L, Mehta A, Yip YW. Clinical and subclinical macular detachment after intravitreal injection of anti-VEGF agents in neovascular age-related macular degeneration. *Br J Ophthalmol*. 2012;96(4):434-439.

CONFLICT OF INTEREST: NIL

FUNDING: NIL

ACKNOWLEDGEMENTS: NIL