

**DOI: 10.5281/zenodo.8215820**

**Original research article**

**4**

## **Capture the unseen - smartphone with slit-lamp attachment brings a new perspective to digital ocular photography**

Optom Ashish Singh<sup>1</sup>, Dr Usman Memon<sup>2</sup>

<sup>1</sup> B. Optom, Pursuing M. Optometry, Nagar School of Optometry, Ahmedabad

<sup>2</sup> PhD, M. Optom, FIACLE (Aus.), Director, Vision Venture Eye Care Hospital, Ahmedabad

### **Abstract**

**AIM:** Applications of smartphone in ocular photography using slit lamp attachment to obtain high quality anterior segment images in routine OPD to shift paradigm as evidence based eye care practice and learning tool for budding eye care practitioners.

**METHOD:** Cost effective method which demonstrates how Eye care practitioner can use slit lamp attachment with any of the smartphone to click photographs for ease of clicking anterior segment photography in rush hours of OPD to cater need for evidence either for follow up visits, demonstration, research and evidence for practice management.

**RESULTS:** Series of nine anterior segment photographs were obtained with the use of slit lamp adapter and smartphone which portrays a wide range of pathology and complications of the eyelids, conjunctiva, cornea, iris, and crystalline lens and contact lens complications, different photographs were obtained by using slit lamp attachment and modification with different angle of illumination and magnification to obtain best quality of image.

**CONCLUSION:** Slit lamp attachment using with smartphone is a cost effective method as well helpful to provide better depth of photograph as we can change magnification and illumination of the system, for observing any particular part in detail to get better results in the anterior segment photograph of the eye. It's the best tool for budding eye care practitioner to shift paradigm towards evidence based practice.

**Keywords: slit-lamp, slit-lamp, digital ocular photography, smartphone**

### **INTRODUCTION**

We live in an age where technology is advancing fast and becoming more accessible. Smartphones are one of the areas where this rapid growth is very visible. The availability of cheaper, faster and more capable mobile computing devices has led to a lot of innovations in every field where it can be applied. In addition, with higher end smartphone devices.<sup>1</sup>

Using a smartphone nowadays is very common and allows us to capture images and videos in regular OPD'S for the ocular disease documentation, treatment, and monitoring patient's data and, for the education and research purpose to share and discussion done with the colleagues

Obtaining a secure, photographic record of clinical findings during patient encounters can serve as a powerful adjunct other than texting heavy documentation that dominates modern electronic health record system

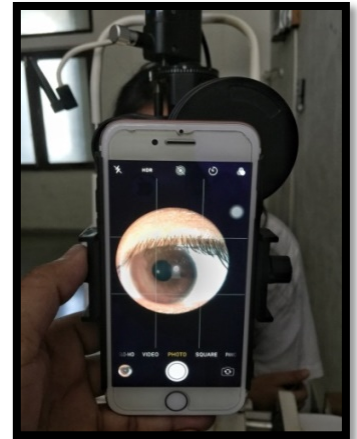
## MATERIALS



**SLIT-LAMP**



**SLIT-LAMP  
ATTACHMENT**



**SMARTPHONE**

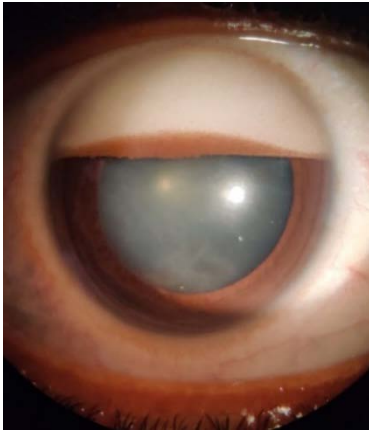
A high fibre plastic holder comes with screw fitting slit lamp attachment used to attach smartphone with the eye piece of the slit lamp, which gives support and good stability to the smartphone with the eye piece of slit lamp through which eye care Practitioner can click sharp, clear anterior segments photographs.

## METHODOLOGY

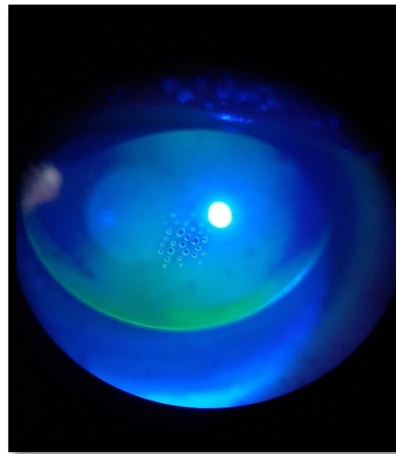
The methodology is simple. Loosen the screw of slit lamp attachment and the pad to attach smartphone onto it and tighten the screw. This will help hold the mobile steady at the correct distance with proper centration to the smartphone camera lens onto the eye piece of sit lamp. Focus slit lamp with required illumination, viewing angle onto the object of interest and as per requirement change exposure and ISO settings if needed prior to capture image. Depends upon the observer the slit lamp illumination and magnification can be changed to focus well.

## RESULTS

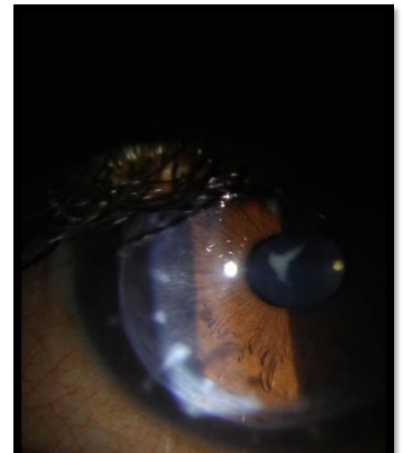
### PHOTOGRAPHS CAPTURED WITH SMARTPHONE ATTACHED WITH SLIT LAMP ATTACHMENT



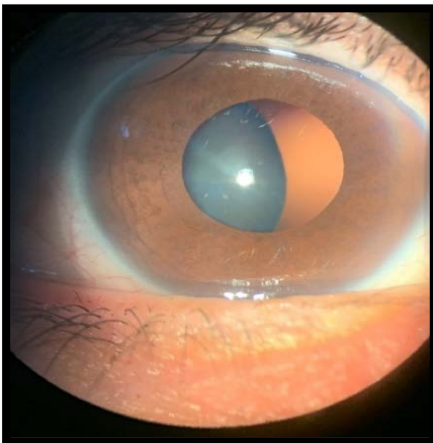
**Inverse hypopyon with emulsified silicon oil**



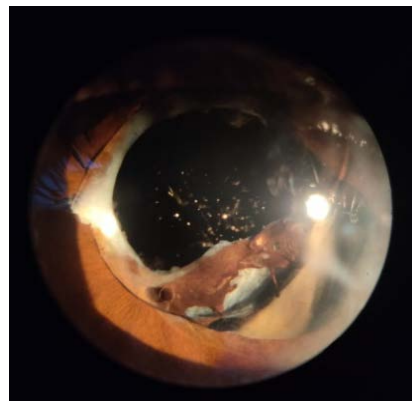
**Dimple veiling in rgp CL Fitting**



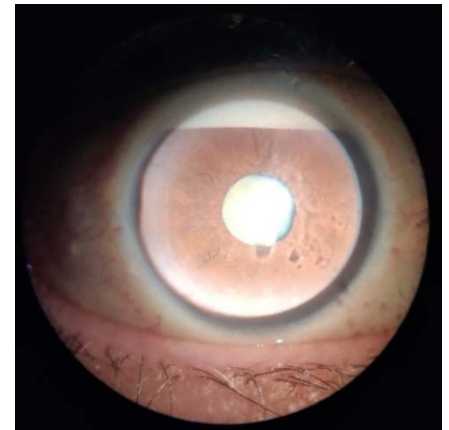
**Post OPK with sutural cataract**



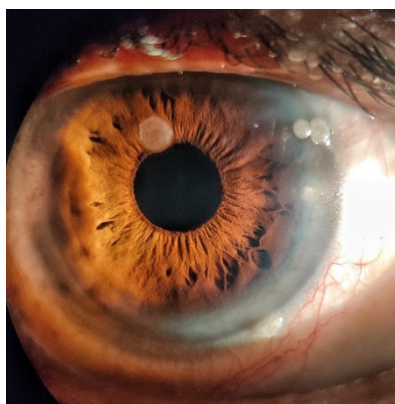**Subluxated crystalline lens**



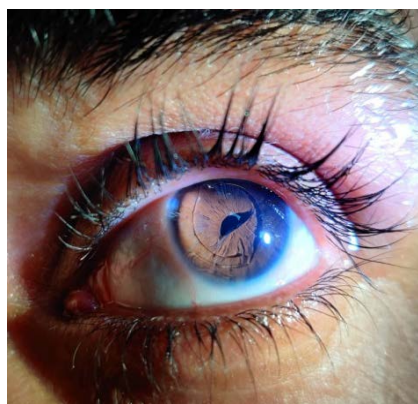**Traumatic iris with ac IOL showing aqueous flares**



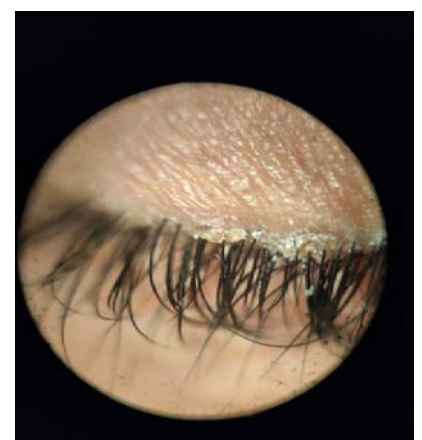**Inverse hypopyon with white pupil reflex**



**Lipid deposits on the surface of soft contact lens**



**AC IOL with peaked pupil**



**Blepharitis**

## **DISCUSSION**

In this era, most of the eye care practitioners are equipped with a smartphone which can be smartly used in collection of patient's data for clinical studies case discussions and also to correlate on follow-up's.

Study by *Cassie A Ludwig et al*; A novel smartphone ophthalmic imaging adapter: User feasibility done in Hyderabad, India, shows that how smartphone can be useful in ocular photography when equipped with attachments which can enhances the quality of images supports my study with same potential.<sup>2</sup>

This method allows for quick and efficient documentation of ocular conditions, as well as providing high-quality images that can be used for comparison over time. The use of smartphone photography in ocular examination can improve patient care and support evidence-based decision making.

## **CONCLUSION**

This study was designed to conclude that how a regular smart phone can be very useful for clicking sharp and clear ocular photographs, rather than using the conventional slit lamp and large expensive photography devices in eye care profession.

## **REFERENCES**

1. Application of mobile technology in ophthalmology to meet the demands of low-resource settings  
By *Dr. Rahul Chakrabarti*
2. A novel smartphone ophthalmic imaging adapter: User feasibility studies in Hyderabad, India  
By *Cassie A Ludwig, Somasheila I Murthy, et al*

**Acknowledgements:** none

**Conflicts of interest:** none

**Funding:** Nil