

Prolong Administration of Methanolic Whole Fruit Extract of *Lagenaria breviflora* (Benth.) Roberty Provoke Oxidative Stress and Kidney Dysfunction in Male Wistar Rats

Ajayi Ayodeji Folorunsho^{1*}, Olubukola Sinbad Olorunnisola², Adewale Adetutu² and Abiodun Olusoji Owoade²

¹Department of Physiology, Ladake Akintola University of Technology, Ogbomoso, Nigeria

²Department of Biochemistry, Ladake Akintola University of Technology, Ogbomoso Oyo State, Nigeria

Abstract

Kidney diseases contributed to the worldwide burden of human diseases, with approximately more than ¾ million deaths annually. The exact reason (s) for the high prevalence of kidney and urinary tract diseases are unknown. The effects of 1 mL of methanolic fruit extract of *L. breviflora* administered orally, at 0.5 and 1.0 g/kg/body weight once daily for fourteen and twenty-eight days respectively on serum and tissue antioxidants status, electrolytes and the activities of some 'marker' enzymes of kidney toxicity in Wistar rats was investigated. The control group received 0.9% physiology saline. Using established protocols, the results showed that the extract negatively altered ($p < 0.05$) the electrolyte balance, alkaline phosphatase, gamma glutamyl transferase, Lactate dehydrogenase, antioxidant enzymes activities, glutathione and malondialdehyde status in dose and duration dependent manners when compared with the untreated group. Histological evidence revealed mild tubular and glomerular damage. Although, no significant change was observed in the kidney body weight ratio in all the extract treated groups, our results, suggest that extract of *L. breviflora* may be nephrotoxic at high dosage over a prolonged period.

Keywords: *L. breviflora* fruit; Oxidative stress; Anti-oxidant enzymes; Lipid peroxidation; Kidney damage; Electrolytes

Introduction

Kidney diseases are the most leading causes of death in the world. According to Nandi et al. [1] Arrigo and Giuseppe, 12th and 17th cause of death and disability respectively, has been attributed to kidney and urinary tract diseases. They contributed to the world-wide burden of human diseases, with approximately more than ¾ million deaths annually and disability-adjusted life [2]. Its prevalence is estimated to be 8-16% worldwide [3]. Although, the exact reason(s) for the increase in the incidence of kidney and urinary tract diseases are unknown, diabetes mellitus has been reported as the most common cause of chronic kidney disease worldwide, while other causes include herbal and environmental toxins [3]. The use of medicinal plants in maintenance of good health is a common practice in most developing countries [4]. Their application in the management and treatment of human diseases is based solely on traditional folk usage that has been handed down through the generations [5], and recently, the world population is adopting the approach for the treatment of various ailments [6]. Bioactive compounds are believed to be responsible for the curative or therapeutic properties of medicinal plants [7]. However, most of the information on their safety has not been verified scientifically. *Lagenaria breviflora* (Benth.) Roberty, a family of Cucurbitaceae [8], is an example of one of the numerous plants commonly use in the management of inflammatory and other diseases in Nigeria. *Lagenaria breviflora* is a perennial climber ascending to the forest, growing canopy, occurring in tropical Africa and its leaves appear to be very scabrid and sand pappery [9]. All the three distinct parts of the fruit of *L. breviflora* are used for medicinal purposes. Its fruits are used in the treatment of cold, anti-fertility [9], as stimulating agent and erythropoiesis [10]. According to Tomori [11] the whole fruit extract of the plant demonstrate antibacterial activity while the crushed stem and its decoction are employed in the treatment of headache in Western part of Nigeria [9]. It was reported that the pharmacological functions of the fruit may be due to the presence of phytochemical constituents such as triterpenoid and saponins [12]. Other members

of Cucurbitaceae which has been reported to demonstrate similar pharmacological activities such as anti-inflammatory and analgesic properties [13,14] include Lantanatriflora and Cayaponiatatuya. In spite, of the wide application of the various parts of *L. breviflora* in the treatment of human diseases, information on the likely effect of the extract on the antioxidant system and markers of kidney toxicity is limited in the literature. Therefore, the present study was designed to evaluate the likely effect of the methanolic fruit extract of the plant on antioxidant status and kidney functions.

Materials and Methods

Plant material

Fresh fruits of *L. breviflora* were bought from a local market in Ogbomosho, Oyo State, Nigeria in the month of April, 2013 and were identified by Dr. A.T.J. Ogunkunle of the Department of Pure and Applied Biology, Ladake Akintola University of Technology Ogbomoso, Oyo State Nigeria. A voucher (DSO 014) sample of the plant was also deposited at the University herbarium.

Extraction of the fruit of *Lagenaria breviflora*

Sliced fresh fruits of *L. breviflora* (2 kg) were crushed with electric blender and soaked in 4 liters of methanol for 72 hours. The mixture was stirred frequently and later filtered with a meshing cloth. The residue was

*Corresponding author: Folorunsho AA, Department of Physiology, Ladake Akintola University of Technology, Ogbomoso, Nigeria, Tel: +2348033834495; E-mail: aajayi22@lautech.edu.ng

Received November 23, 2018; Accepted February 13, 2019; Published February 20, 2019

Citation: Folorunsho AA, Olorunnisola OS, Adetutu A, Owoade AO (2019) Prolong Administration of Methanolic Whole Fruit Extract of *Lagenaria breviflora* (Benth.) Roberty Provoke Oxidative Stress and Kidney Dysfunction in Male Wistar Rats. J Bioanal Biomed 11:142-148. doi:10.4172/1948-593X.1000225

Copyright: © 2019 Folorunsho AA, et al. This is an open-access article distributed under the terms of the Creative Commons Attribution License, which permits unrestricted use, distribution, and reproduction in any medium, provided the original author and source are credited.

re-soaked in 2L of methanol for 24 hours and then filtered. The filtrate obtained was concentrated in a rotary evaporator at 40°C. A greenish brown jell-like concentrate was obtained, weighing 69.6 g (3.48% of the fresh fruits). A stock solution was prepared by dissolving 100 mg of the extract in 100 mL of distilled water.

Experimental animals

Twenty-five adult male (n=5) rats (180-200 g) used for this study were housed at the Animal Housing Unit of the Department of Biochemistry, Ladoko Akintola University of Technology Ogbomoso, Oyo State, Nigeria and were maintained under standard laboratory conditions at ambient temperature of 25 ± 2°C and 50 ± 15% relative humidity with a 12-h light/12-h dark cycle for 2 weeks before commencement of the experiment. The rats were fed with pelletized rat ration (Guinea Feed, Nig. Ltd) and water ad libitum. After acclimatization the rats were divided into five groups (A, B, C, D and E).

- Group A were administered with 0.9% physiological saline.
- Groups B and C were administered with methanolic extract of *L. breviflora* at 500 and 1000 mg/kg/body weight respectively for 14 days.
- Group D and E were administered with 500 and 1000 mg/kg/body/weight of the extract respectively for 28 days.

The rats were administered, orally with their various designated dosages once daily using oral cannula.

Collection of tissue samples

After the experimental regimen, the animals were sacrificed under mild chloroform anesthesia. Blood was collected by cardiac puncture and serum was separated by centrifugation (for 20 min at 3500 rpm). The kidney was immediately dissected out, bloated, washed and 0.5 g of tissue was weighed and homogenized in 5 mL of 0.05 M of Tris-HCl buffer (pH-7.4) in 0.9% ice cold saline for various biochemical evaluations. The remaining portion of the tissue was put in 1% formalin for histopathological studies.

Estimation of biochemical parameters in serum and tissues

Assay kits for alkaline phosphatase, gamma glutamyl transferase and Lactate dehydrogenase were obtained from Randox Laboratories Ltd., United Kingdom while, reagents for glutathione peroxidase, superoxide dismutase, malondialdehyde and catalase were obtained from Merck Laboratories Ltd., India.

Estimation of lipid peroxidation (MDA)

The method described by Okhawa [15] was employed to determine the level of lipid peroxidation in the animal tissue. Briefly, the reaction mixture of 0.2 mL of 8.1% sodium dodecyl sulfate, 1.5 mL of 20% acetic acid solution adjusted to pH 3.5 with sodium hydroxide and 1.5 mL of 0.8% aqueous solution of thiobarbituric acid was added to 0.2 mL of 10% (w/v) of the homogenate. The mixture was brought up to 4.0 mL with distilled water and heated at 95°C for 60 min. cooling with tap water, 1.0 mL distilled water and 5.0 mL of the mixture of n-butanol and pyridine (15:1 v/v) was added and the mixture centrifuged at 2000 rpm for 10 min. The organic layer was removed and its absorbance measured at 532 nm and compared with those obtained from MDA standards.

Determination of Superoxide Dismutase Activity

The activity of superoxide dismutase was determined as described by Toshihiro and Irwin [16]. The assay mixture contained 0.5 mL of

hepatic PMS, 1 mL of 50 mM sodium carbonate, 0.4 mL 25 µM nitroblue tetrazolium and 0.2 mL of freshly prepared 0.1 mM hydroxylamine hydrochloride. The reaction mixture was mixed quickly by inversion followed by the addition of the clear supernatant of 0.1 mL of kidney homogenate (10% w/v). The change in absorbance was recorded at 560 nm. The percentage of inhibition was calculated using this Equation:

$$\% \text{ Superoxide dismutase inhibition} = \frac{[(\text{Normal activity} - \text{inhibited activity}) / (\text{normal activity})] \times 100\%}{}$$

Determination of Catalase Activity (CAT)

Catalase activity was measured as described by Pari and Latha [17]. Briefly, the tissue was homogenized in 0.01 M phosphate buffer (pH 7.0) and centrifuged at 5000 rpm. The reaction mixture consisted of 0.4 mL of hydrogen peroxide (0.2 M), 1 mL of 0.01 M phosphate buffer (pH 7.0) and 0.1 mL of kidney homogenate (10% w/v). The reaction of the mixture was stopped by adding 2 mL of dichromate-acetic acid reagent (5% K₂Cr₂O₇) prepared in glacial acetic acid). The changes in the absorbance were measured at 620 nm and recorded. The percentage of inhibition was calculated using the equation:

$$\% \text{ Catalase inhibition} = \frac{[(\text{normal activity} - \text{inhibited activity}) / (\text{normal activity})] \times 100\%}{}$$

Determination of glutathione peroxidase

Glutathione peroxidase (GPx) was measured by the method described by Chikezie [18]. Briefly, the reaction mixture contained 0.2 mL 0.4 M phosphate buffer (PH 7.0), 0.1 mL 10 mM sodium azide, 0.2 mL tissue homogenized in 0.4 M phosphate buffer PH-7.0. 0.2 mL tissue homogenized in 0.4 M, phosphate buffer, PH 7.0, 0.2 mL reduced glutathione, 0.1 mL 0.2 mM hydrogen peroxide. The contents were incubated for 10 min at 37°C, 0.4 mL 10% TCA was added to stop the reaction and centrifuged at 3200 × g for 20 min. The supernatant was assayed for glutathione content using Ellman's reagent 19.8 mg 5, 5'-dithiobisnitrobenzoic acid [DTNB] in 100 mL 0.1% sodium nitrate). The activities were expressed as µg of GSH consumed/ min/mg protein.

Estimation of reduced glutathione

The amount of reduced glutathione in the samples was estimated by the method of Ellman [19]. 1 mL of the sample extracts were treated with 4.0 mL of metaphosphoric acid precipitating solution (1.67 g of glacial metaphosphoric acid, 0.2 g EDTA and 30 g NaCl dissolved in 100 mL water). After centrifugation, 2.0 mL of the protein-free supernatant was mixed with 0.2 mL of 0.4 M Na₂HPO₄ and 1.0 mL of DTNB reagent (40 mg DTNB in 100 mL of aqueous 1% tri sodium citrate). Absorbance was read at 412 nm within 2 minutes. GSH concentration was expressed as nmol/mg protein.

Determination of GST Activity

The activity of GST was determined according to the method of Chikezie [18] Briefly, CDNB solution (0.1 mL) was pipetted into a conical flask before adding phosphate buffer (1 mL) and distilled water (1.7 mL). Next, the mixture was incubated at 37°C for 5 min. The serum sample (0.1 mL) and GSH solution (0.1 mL) were added (using an automatic micropipette) after the incubation. A blank devoid of the serum was prepared for background correction. Absorbance readings at 340nm were taken for 5 min at 60s interval using a UV-VIS Analyst spectrophotometer.

Histopathological analysis of the kidney

The kidney of the animals from each group was fixed in 10% formaldehyde, dehydrated, and paraffin blocks prepared for

histopathological examination. The block was sectioned at 5-7 μm and stained with hematoxylen.

Statistical analysis

Results are expressed as Mean \pm SD of six individual experiments and the statistical significance was evaluated by one way analysis of variance (ANOVA) using SPSS version (10.0) and the individual comparisons were obtained by the Duncan multiple range test (DMRT). A value of $p < 0.05$ was considered to indicate a significant difference between groups.

Results and Discussion

The assessment of serum electrolytes status in Wistar albino rats is a valuable tool for monitoring the effect of xenobiotics (plant extracts) on kidney functions and integrity [20]. Electrolytes such as calcium ions are important for many physiological functions such as cell muscle contraction, enzyme co-factor, second messenger, transfer of impulses along the nerve cells and blood clotting and bone formation [21,22]. In spite, of the important of calcium ion, its serum concentration must be maintained at equilibrium. In the present study, the mean concentration of potassium (K^+), bicarbonate (HCO_3^-), chloride ion (Cl^-), phosphate ion (PO_4^-) and calcium ion (Ca^{2+}) assessed in the control and rats treated with 500 mg/kg/body weight of methanolic extract of *L. breviflora* for fourteen and twenty eight days respectively remain within the normal physiology range (3.4 - 8.7 mEq/L (K^+), 80-107 mmol/L (Cl^-), 20 - 35 mmol/L (HCO_3^-) and 130-155 mEq/L (Na^+) respectively [23]. Although, a significant reduction ($p < 0.05$) in serum Ca^{2+} ion concentration was observed following twenty-eight days administration of extract at the dose of 1000 mg/kg/ b.wt (Table 1), the observed value is still within the normal physiology range. The result is consistence with previous report by Adebowale [24]. Recently, Ajani also reported that the ethanolic leaf extract of the plant at 1000 mg/kg/body/weight caused insignificant decrease in serum calcium ion concentration. Hypocalcaemia has been reported in terminal stages of chronic generalized renal failure [24], the histology report (Figures 1a-1c) in this study does not show renal failure. Therefore, the observed reduction in serum calcium ion in this study may be due to derangement in renal function resulting from interference with ions

Serum Electrolytes (mmol/L)	Groups and treatment duration				
	14 days Administration (mg/kg)			28 days Administration (mg/kg)	
	Control	500	1000	500	1000
Ca^{2+}	14.00 \pm 1.20 ^a	14.80 \pm 1.20 ^a	14.23 \pm 0.27 ^a	14.87 \pm 0.23 ^a	11.09 \pm 0.81 ^b
K^+	3.65 \pm 0.50 ^a	3.70 \pm 0.20 ^a	3.88 \pm 0.15 ^a	3.98 \pm 1.14 ^a	2.22 \pm 1.23 ^c
Na^+	132.07 \pm 2.23 ^a	134.10 \pm 1.23 ^a	135.01 \pm 0.22 ^a	134.30 \pm 0.34 ^a	150.04 \pm 1.11 ^b
Cl^-	26.5 \pm 2.50 ^a	23.5 \pm 2.10 ^a	26.22 \pm 0.19 ^a	27.01 \pm 1.12 ^a	18.2 \pm 1.30 ^b
HCO_3^-	22.0 \pm 2.50 ^a	24.5 \pm 1.50 ^a	23.0 \pm 0.24 ^a	22.23 \pm 0.45 ^a	18.15 \pm 1.05 ^b
PO_4^{3-}	11.13 \pm 0.20 ^a	10.92 \pm 0.50 ^a	10.89 \pm 0.15 ^a	10.78 \pm 0.55 ^a	13.99 \pm 1.22 ^b
Kidney body Weight Ratio (%)	0.59 \pm 0.05 ^a	0.58 \pm 0.03 ^a	0.61 \pm 0.01 ^a	0.52 \pm 0.12 ^a	0.56 \pm 0.05 ^a

Values are mean of 5 replicate \pm SD. Statistical analysis used was analysis of variance (ANOVA) and student's t-test. Values along the same row carrying different superscripts are significantly different ($p < 0.05$).

Table 1: Effect of 14 and 28 days administration of methanolic fruit extract of *L. breviflora* on electrolytes ion and kidney body weight ratio of male rats.

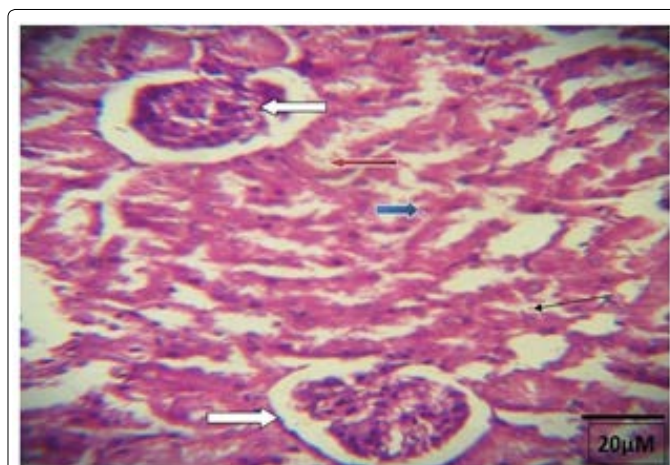


Figure 1a: Photomicrograph of a kidney section treated with 0.9 physiological saline showing normal kidney architecture, there are normal glomeruli with normal capsular space and mesangial cells (white arrow). The tubules appear normal, the proximal convoluted tubules (red arrow) and distal convoluted tubules (blue arrow) appear normal. The interstitial spaces are not infiltrated but appear normal (slender arrow*). No pathological lesion Seen. H&E Stain, 400x.

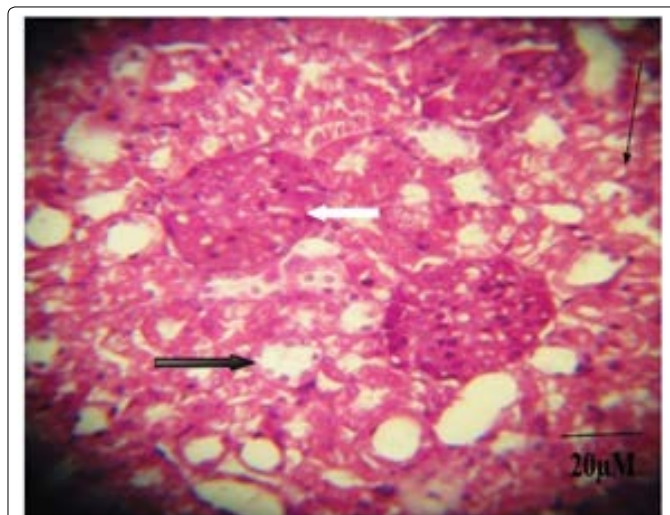


Figure 1b: Photomicrograph of a kidney section administered 500 mg/kg/B. Wt for twenty-eight days, showing abnormal glomeruli with proliferated mesangial cells and lack of capsular space (white arrow). The renal tubules show some attenuated tubules and proximal convoluted tubules with loss of brush border (black arrow). The interstitial spaces are not infiltrated but appear normal (slender arrow). (H&E strain 400x).

transport across the renal tubules [24]. It could also be associated to imbalance in its mobilization from calcium dependent system or the induction of calcium lowering hormones such as calcitonin from the thyroid gland [21]. The histological analysis of the kidney of both the treated and control group is shown. No visible lesion was observed in the kidney of the control and experimental groups (500 and 1000 mg/kg/b.wt) after administration for fourteen days. Figure 2 showed the kidney sections of control and rats administered with 500 and 1000 mg/kg/b.wt methanolic fruit extract of *L. breviflora* for twenty-eight days. There were several architectural defects such as abnormal glomeruli, renal tubular degeneration and necrosis (1b and c) in rats administered with 500 and 1000 mg/kg/b.wt of the fruit extract compared with the control (1a). The duration and dosage dependent kidney damage effect of the extract was also supported by histological evidence. The photomicrograph of animals treated with 500 and 1000 mg/kg/body

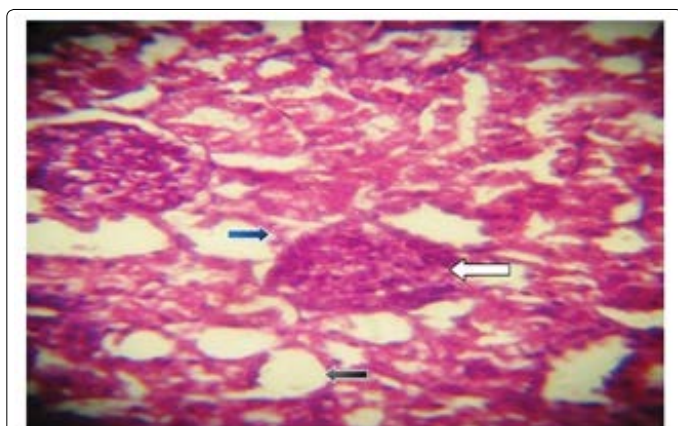


Figure 1c: Photomicrograph of a kidney section administered 1000, 500 mg/kg/B. Wt for twenty-eight days showing abnormal glomeruli with proliferated mesangial cells and lack of capsular space (white arrow). The renal tubules show some attenuated tubules (black arrow) and proximal convoluted tubules with loss of brush border (blue arrow). The interstitial spaces are not infiltrated but appear normal (slender arrow). (H&E stain 400x).

weight for 28 days (Figures 1b and 1c) revealed degenerative changes compared to the control animal (Figure 1a).

Potassium ion is a major cation of the intracellular fluid and about 10% of the total body potassium is found in the extracellular. Derangements in serum potassium concentration are known to portray serious health implications. For example, decreased serum potassium ion known as hypokalemia is associated with muscular weakness, hypotonia and cardiac arrhythmias (Crook) while, elevated serum potassium ion (hyperkalemia) is reported to predispose to cardiac arrest [25]. Sodium ion, a very important electrolyte in the body on the other hand has been implicated in diseases such as hypertension [26] and vessel walls contraction. According to Enemor and Okaka, [25], fluctuations in its concentration may contribute to high or lower blood pressure. Elevated sodium ion in the blood can cause cell hydration leading to hypernatremia which may result to coma or death [27]. In the present study, the significant decrease in the serum K^+ concentration of the group administered with 1000 mg/kg/body weight of the extract for 28 days (Table 1) suggested a possible adverse effect on the sodium pump that maintains the constancy of the extracellular concentration of potassium [21]. This finding is slightly different from Adebawale [24] who reported an insignificant decrease in the level of the ion when treated with the same extract concentration for fourteen days. The difference in the report might consequently be because of the prolonged days i.e., 28 of administration. Increase in the serum Na^+ ion level at 1000 mg/kg/body weight observed in the study is in line with the report by Adebawale [24], who reported that the mean serum Na^+ level for the test rats was higher than the control. Possible mechanism (s) for hypernatremia may be due to excessive loss of Na^+ from body fluids or due to increased production of aldosterone and other mineralocorticoids which will in turn increase the reabsorption of Na^+ [28]. Another possible mechanism is the inverse activity of sodium and potassium pump [29]. Chloride ion is important for muscle contractions. Sodium retention is associated and directly related with chloride ion, most sodium ion reabsorption is coupled with chloride ion reabsorption [30], while Chloride ion reabsorption is associated with excretion of bicarbonate ion. The decreased chloride and bicarbonate ion concentration observed in all doses especially at 1000 mg/kg/body weight when compared with the control suggest tubular and glomerular dysfunction [31]. Phosphate ion is another group of electrolytes that can

be used to assess renal function. It's *Mentha longifolia* L. subsp. *capensis* leaves in rats normally released during cell breakdown and *Mentha longifolia* L. subsp. *Capensis* leaves in rats is used in building the *Mentha longifolia* L. subsp. *capensis* leaves in rats acid of cells. The significant increase in PO_4^{2-} ion (Hyperphosphatemia) in the 1000 mg/kg/body weight dose group might have resulted from high phosphate content of the extract, decreased phosphate excretion, or a disorder that shifts intracellular phosphate to extracellular space. Since the movement of phosphate in and out of bones generally balanced and renal excretion of excess dietary phosphate intake ensures maintenance of phosphate homeostasis at a level of approximately 3-4 mg/dL, it is suggested that the significant high phosphate level obtained in this study may be due to tubular dysfunction of the nephron [32]. To further evaluate the effect of chronic administration of *L. breviflora* on kidney function, other biochemical makers such as urea, uric, creatinine, albumin, globulin and total protein were assayed (Table 2). A significant increase in serum urea concentration with a concomitant significant increase in creatinine levels when the extract was administered at 1000 mg/kg/body weight over a prolong period of 28 days was observed. The result suggest renal impairment in the rats or increased protein catabolism [21,32]. Creatinine clearance was measured to assess glomerular filtration rate. Increase in the serum creatinine content following the administration of methanolic fruit extract of *L. breviflora* at 1000 mg/kg/body weight over a prolong period of 28 days (Table 2) may be an indication of glomerular and tubular dysfunction. Decreased serum total protein content may be a useful index of severity of hepatocellular damage. Increased plasma total protein concentration observed in the current work at high doses of 500 and 1000 mg/kg and prolong days (28) of treatment (Table 2) may be due to dehydration and/or increased plasma immunoglobulin concentration due to infection. The fact that increase water intake was not observed in the animals in this group (data not included), suggest that, higher doses and prolonged administration of the extract might have predisposed the animals to infection resulting in increased serum globulin.

Oxidative stress has been reported to play a critical role in the pathophysiology of several kidney diseases. Reactive Oxygen species are extremely reactive, unstable and react with lipids, proteins, carbohydrates and nucleic acids in the body leading to generation of cascade reaction producing lipid peroxidation (LPO), a major mechanism of cell membrane distraction and cell damage [33]. However, biological systems are endowed with endogenous defense system against free radical induced cell damage. Primary antioxidant enzymes viz. GPx, CAT and SOD directly eliminate hydroxyl radical, superoxide radical, hydrogen peroxide whereas glutathione reductase, G6PDH and cytosolic GST are secondary enzymes that detoxify ROS by decreasing peroxide levels or maintaining a steady supply of metabolic intermediates like glutathione and NADPH necessary for optimum functioning of primary antioxidant enzymes [33]. The generation of ROS is a primary event under a variety of stress conditions and the consequence of ROS formation depends on the intensity of the stress. Stressful conditions are known to interfere with antioxidant system by interfering with production or inactivation of antioxidant enzymes [34]. The ROS scavenging activity of SOD is normally followed by the actions of CAT and GPx, which scavenge hydrogen peroxide generated by SOD [35]. It is therefore hypothesized that an imbalance in the SOD/CAT may results in oxidative alterations.

The significant ($p < 0.05$) increase in activities of tissue (kidney) antioxidant enzymes SOD, CAT, GST, GPx (Table 3) and marker of lipid peroxidation (MDA) in the rats administered with 500 and 1000 mg/kg/body weight extract of *L. breviflora* for 14 days compared

Treatment	Group mg/kg/b.wt	Renal indices (mmol/L)					
		Globulin	Albumin	Total protein	Urea	uric acid	creatinine
	Control	2.81 ± 0.16 ^a	4.35 ± 0.14 ^a	7.26 ± 0.54 ^a	3.48 ± 2.16 ^a	1.80 ± 2.13 ^a	14.00 ± 2.00 ^a
14 days administration of <i>L. breviflora</i>	500	2.52 ± 1.30 ^a	4.56 ± 2.11 ^a	7.08 ± 0.37 ^a	3.83 ± 0.38 ^a	1.83 ± 1.13 ^a	13.89 ± 1.89 ^a
	1000	3.90 ± 0.12 ^b	4.28 ± 1.02 ^a	7.18 ± 0.25 ^a	3.58 ± 0.17 ^a	1.79 ± 1.11 ^a	13.76 ± 2.11 ^a
28 days administration of <i>L. breviflora</i>	500	3.65 ± 0.30 ^c	4.62 ± 0.25 ^a	8.27 ± 1.02 ^b	3.69 ± 1.01 ^a	1.85 ± 0.56 ^a	14.67 ± 1.34 ^a
	1000	4.28 ± 0.11 ^d	4.38 ± 0.51 ^a	8.66 ± 0.23 ^c	5.35 ± 0.14 ^b	2.94 ± 1.20 ^b	16.16 ± 1.05 ^b

Values are mean of 5 replicate ± SD. Statistical analysis used was analysis of variance (ANOVA) and student's t-test. Values down the columns carrying different superscripts are significantly different (p<0.05).

Table 2: Effect of 14 and 28 days administration of methanolic fruit extract of *L. breviflora* on serum kidney function indices.

Treatment	Group mg/kg/bwt	Antioxidant tissue enzymes activity and MDA					
		SOD (Units/mg of protein)	CAT (μ moles of H ₂ O ₂ utilized /min/mg/ protein)	GPx (μg of GSH/mg of protein)	GSH (mg/100g tissue)	GST(μmoles of CDNB Conjugate formed/mg of protein)	MDA (nmol/mg tissue)
	Control	6.99 ± 1.10 ^a	79.23 ± 2.01 ^a	30.2 ± 0.14 ^a	40.15 ± 1.20 ^a	8.2 ± 2.13 ^a	18.35 ± 0.81 ^a
14 days administration of <i>L. breviflora</i>	500	8.52 ± 0.30 ^b	88.56 ± 1.11 ^b	47.08 ± 0.17 ^b	38.53 ± 0.48 ^b	11.83 ± 2.13 ^b	26.09 ± 1.29 ^b
	1000	9.70 ± 0.12 ^b	89.20 ± 1.02 ^b	49.24 ± 0.25 ^b	36.28 ± 0.27 ^b	12.79 ± 1.11 ^b	28.76 ± 2.11 ^b
28 days administration of <i>L. breviflora</i>	500	5.45 ± 1.31 ^c	74.62 ± 0.15 ^c	27.23 ± 1.02 ^c	33.60 ± 1.11 ^c	6.05 ± 0.56 ^a	24.67 ± 1.34 ^b
	1000	4.87 ± 2.21 ^c	70.12 ± 1.51 ^c	26.66 ± 1.23 ^c	31.30 ± 0.12 ^c	6.00 ± 1.20 ^b	25.16 ± 1.05 ^b

Values are mean of 5 replicate ± SD. Statistical analysis used was analysis of variance (ANOVA) and student's t-test. Values down the columns carrying different superscripts are significantly different (p<0.05). Superoxide dismutase (SOD), catalase (CAT) glutathione transferase (GST) and Malondialdehyde (MDA).

Table 3: Effect of 14 and 28 days administration of methanolic fruit extract of *L. breviflora* on tissue antioxidant enzyme activity.

with the control suggested that the extract caused generation of free radicals or directly activate synthesis of antioxidant enzymes. However, the significant decreased in antioxidant enzymes activities and GSH with a concomitant increased in MDA level after prolong (28 days) extract administration at similar doses confirmed that the extract increased free radicals generation. GSH is a thiol which plays a central role in coordinating the body's antioxidant defense processes [36]. The mechanism by which GSH protect against oxidative induced tissue damage involved binding of sulfhydryl groups in glutathione to a variety of electrophilic radicals and metabolites that may cause cell damage [31]. The concentration and duration dependent depletion of GSH could be due to saturation of detoxification pathways leading to accumulation of intermediate metabolites and kidney damage resulting from covalent binding to tissue molecules and proteins such as GSH or it could be that the *L. breviflora* fruit extract contains an oxidizing agent or causes suppression of GSH synthesis leading to increased production of reactive oxygen species and induction of oxidative stress. According to Al-Zubairi alkaloid content of the fruit extract of *L. breviflora* [37] might be responsible for the altered activities of the free radical metabolizing/scavenging enzyme system in this study.

The investigation and diagnosis of xenobiotics toxicity involved the measurement of activities of various enzymes such as alkaline phosphatase (ALP), gamma glutamyl transferase (γGT) and Lactate dehydrogenase in the tissue and body fluids [38]. Alkaline phosphatase (ALP), is used to access the integrity of the plasma membrane and lysosomal membrane damage respectively [38]. Increased activities of the enzyme in serum with corresponding decrease in tissue would indicate likely damage to the external boundary of the cells (plasma membrane) [38]. The dose dependent elevated activities of ALP (Figure 2) in the kidney of the rats administered 500 and 1000 mg/kg/body weight for 14 days and their corresponding decrease in its activities in the serum may suggest an induced effect occasioned by the extract or early response to oxidative induced damage as revealed in the increased antioxidant enzymes activities and MDA (Table 3). However, the significant

increase in serum ALP and its corresponding decrease in the kidney of rats administered with 500, 1000 mg/kg/body weight of the extract for 28 days suggested that the extract had a deleterious effect on the plasma membrane of the kidney resulting to leakage of the enzyme into the serum. This incidence could interfere with the normal transportation of ion or molecules across the membrane. It may also affect other metabolic processes that involved nuclear protein, nucleic acids and phospholipids synthesis as well as the cleavage of phosphate esters. The saponins content of the plant [39] may be responsible for leakages of the enzymes as it has been previously demonstrated that saponins can disrupt biological membranes resulting in escape of large quantities of metabolites including enzymes and generation of free radicals [40,41]. Gamma-glutamyl transferase (γGT) is membrane-localized enzyme responsible for (Figure 3) the extracellular catabolism of the antioxidant glutathione [42] and resorption of amino acids from the glomerular filtrate and intestinal lumen [43]. The significant increase in the kidney activity of the enzyme at 500 and 1000 mg/kg/body weight after 14 and 28 days of administration may be attributed to the induction of the enzyme synthesis in the tissue, while the significant decrease in kidney GGT activity at 1000 mg/kg/body weight after 28 days of extract administration (Figure 2) with the concurrent increase in its serum enzymes activity may indicate a dose duration induce toxicity characterized with disruption of membrane integrity and glutathione metabolism. Lactate dehydrogenase (LDH), is a cytosolic marker enzyme for kidney diseases including kidney transplantation, rejection, myocardial infarction, haemolytic anaemia, testicular tumour; lung disease such as pneumonia and congestive heart failure [44]. The observed increase in LDH activity of kidney of rats administered at the dose of 500 mg/kg body weight of the extract for 14 days (Figure 4) suggests an enhancement of the activities of the existing enzymes by the extract. The stress imposed on the tissue by the extract, supported by the increased activities of antioxidant enzymes and marker of lipid peroxidation (Table 2), might induced the tissue to increase the *de novo* synthesis of the enzyme in bid to offset the stress, thus accounting for the increase in LDH activities in the tissue [44]. On the contrary, the

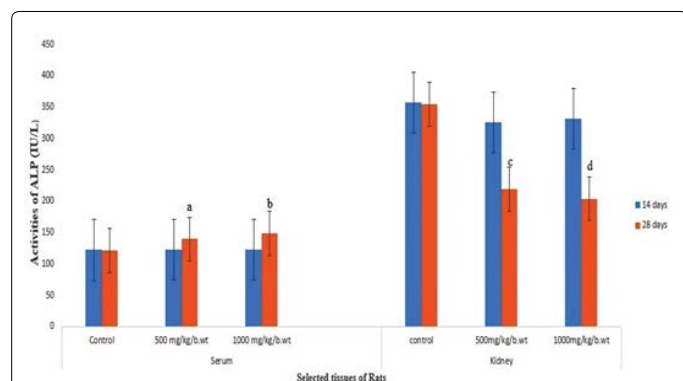


Figure 2: Enzyme activities of alkaline phosphatase (ALP) in serum and kidney of rat after administration of methanolic fruit extract of *L. breviflora* at 500 and 1000 mg/kg/b.wt.

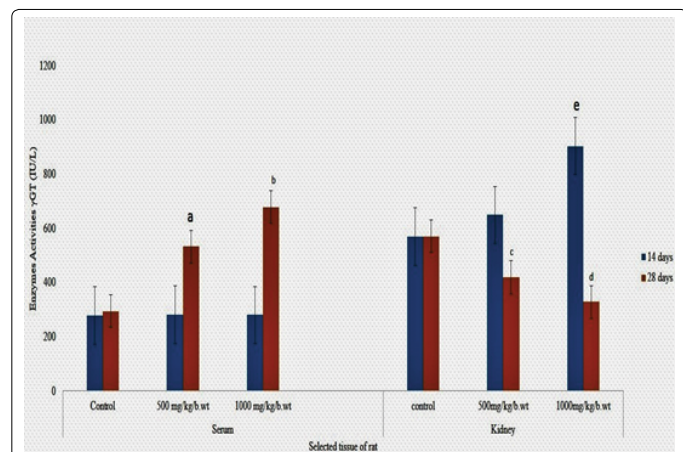


Figure 3: Enzyme activities of gamma glutamyltransferase (γGT) in serum and kidney of rat after administration of methanolic fruit extract of *L. breviflora* at 500 and 1000 mg/kg/b.wt.

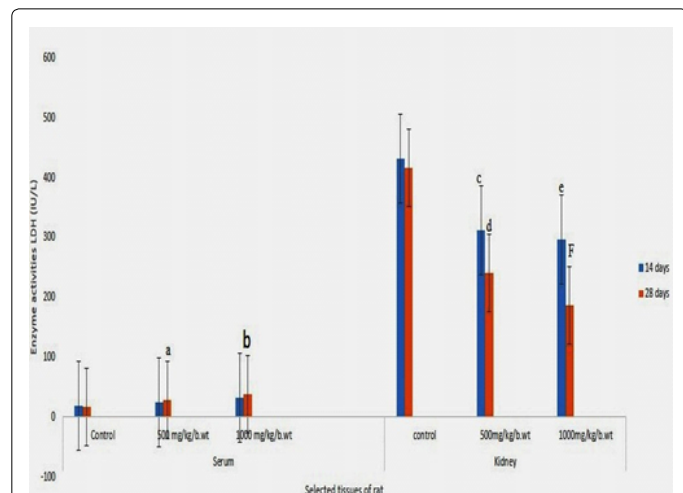


Figure 4: Enzyme activities of Lactate dehydrogenase (LDH) in serum and kidney of rat after administration of methanolic fruit extract of *L. breviflora* at 500 and 1000 mg/kg/b.wt. a, b, c, d and e represent significant difference (p<0.05).

reduction of the enzyme activity in the kidney and the corresponding increase in its serum activity after 28 days of the extract administration suggested a possible leakage of the cytosolic enzyme from the tissues

into serum.

Conclusion

The results of these study reveal that prolong consumption of whole fruit extract of *L. breviflora* especially at high concentrations resulted in diverse toxic effects on the kidney of treated rats as evidenced by alterations in biomarkers of oxidative stress and biochemical indices of kidney function with corresponding histological changes.

Conflicts Interest

The authors declare that they have no conflicts of interests concerning the medicinal plants reported in this paper.

Authors' Contributions

All authors contributed equally to the preparation of this research work and manuscript.

Acknowledgments

Many thanks to Dr. A.T.J. Ogunkunle of the Department of Pure and Applied Biology of Ladoke Akintola, University of Technology Ogbomosho, Oyo State, Nigeria for identification of whole fruit of *Lagenaria breviflora*.

References

1. Arrigo S, Giuseppe R (2005) Chronic renal diseases as a public health problem Epidemiology, social, and economic implications. *Kidney Int Suppl* 98: S7-S10.
2. World Health Organization (2004). Burden of disease project.
3. Jha V, Garcia-Garcia G, Iseki K, Li Z, Naicker S, et al. (2013) Chronic kidney disease: global dimension and perspectives. *Lancet* 382: 260-272.
4. Ali, S, Nasreen S, Safeer S, Andleeb S, Ejaz M, et al. (2016) Medicinal plants as therapeutic agents for cancer treatment. *Punjab univ J Zool* 31: 295-305.
5. Lopes LC, Albano F, Laranja GAT, Alves LM, Silva LFM, et al. (2000). Toxicological evaluation by in vitro and in vivo assays of an aqueous extract prepared from *Echinodorus macrophyllus* leaves. *Toxicol Lett* 116: 189-198.
6. Sofowora A (2001) Medicinal plants and traditional medicine in Africa. *J Phytochemistry* 34: 223-230.
7. Gulnaz AR, Savitha G (2013) Phytochemical evaluation of leaf and stem extracts of siddha medicinal plant: *Sida cordata*. *J Evol Med Dent Sci* 2: 2514-2521.
8. Morimoto Y, Maundu P, Fujimaki H, Morishima H (2005) Diversity of landraces of the white-flowered gourd (*Lagenaria siceraria*) and its wild relatives in Kenya: Fruit and seed morphology. *Genet Res Crop Evol* 52: 737-747.
9. Ajayi GO, Awujo NC, Abulu LE (2002) The miracidicidal and cercaricidal activity of the methanolic extracts of *Lagenaria breviflora* Robert Family Cucurbitaceae fruit on *Schistosoma mansoni*. *Niger Qt J Hosp Med* 12: 57-59.
10. Saba AB, Oridupa OA, Oyeyemi MO, Osanyigbe OD (2008). Spermatozoa morphology and characteristics of male wistar rats administered with ethanolic extract of *Lagenaria breviflora* Roberts. *Afri J Biotech* 8: 1170-1175.
11. Tomori OA, Saba AB, Dada-Adegbola HO (2007) Antibacterial activity of ethanolic extract of whole fruit of *Lagenaria breviflora* Robert. *J Animal Vet Advances* 6:752-757.
12. Adeyemi M, Ekunseitan D, Abiola S, Dipeolu M, Egbeyale L, et al. (2017) Phytochemical analysis and GC-MS determination of *Lagenaria breviflora* R. Fruit. *IJPPR* 9: 1045-1050.
13. Silva GN, Martins FR, Matheus ME, Leitão SG, Fernandes PD (2005) Investigation of anti-inflammatory and antinociceptive activities of *Lantana trifolia*. *J Ethnopharmacol* 100: 254-259.
14. Silvia A, Rosa MG, María CR, Etile D (2009) Spegazzini and José Luis Ríos. Anti-inflammatory activity of flavonoids from *Cayaponia tayuya* roots. *J Ethnopharmacol* 121: 333-337.
15. Ohkawa H, Ohishi N, Yagi K (1979) Assay for lipid peroxides in animal tissues by thiobarbituric acid reaction. *Anal Biochem* 95: 351-35.
16. Ishii T, Fridovich I (1999) Dual effects of superoxide dismutase on the autoxidation of 1,4-naphthoquinone. *Free Radic Biol Med* 8: 21-24.

17. Pari L, Latha M (2004) Protective role of Scopariadulcis plant extract on brain antioxidant status and lipid peroxidation in STZ diabetic male Wistar rats. BMC Complem Altern Med 4: 16-4-16.
18. Chikezie P, Chikezie C, Uwakwe A, Monago C (2009) Comparative study of glutathione s- transferase activity of three human erythrocytegenotypes infected with plasmodium falciparum. J Appl Sci Environ Manage 13: 13-18.
19. Ellman GL (1959) Tissue sulfhydryl groups. Arch Biochem Biophys 82: 70-77.
20. Ighodaro OM, Omole JO (2010) Effects of *Cajanus cajan* Aqueous leaf extract on serum amino transferase, alkaline phosphatase and electrolytes concentrations of normal Wistar rats. Animal Res Inter 7: 1304-1308.
21. Yakubu MT, Akanji MA, Oladij AT (2009) Effect of chronic administration of aqueous extract of *Fadogia agrestis* stem on male rat kidney function indices. Phytopharmacol Therapeut 1: 19.
22. Guyton AC, Hall JE (2000) Textbook of Medical Physiology (10th edn). Harcourt International Edition, W.B. Saunder Company, Philadelphia 279-281.
23. Abubakar SM, Sule MS (2010) Effect of oral administration of aqueous extract of *Cassia occidentalis* L. seeds on serum electrolytes concentration in rats. Bayero Journal of Pure and Applied Sciences 3: 183-187.
24. Adebowale BS, Olayinka AO, Sunday OO (2009) Evaluation of haematological and serum electrolyte changes in Wistar rats administered with ethanolic extract of whole fruit of *Lagenaria breviflora* Robert. J of Med Plants Res 3: 758-762.
25. Enemor VH, Okaka AN (2013) Sub-acute effects of ethanol extract of *Sarcocephalus latifolius* root on some physiologically important electrolytes in serum of normal Wistar albino rats. Pak J Bio Sci 10: 3923.
26. Vasudevan DM, Sreekumari S (2007) Textbook of Biochemistry for Medical Students. 5th Edition, New Delhi pp: 239-246
27. Kebe EO, Victoria NI, Eze LI (2013) The electrolytic effect of *Sida acuta* Leaf extract on the Kidney Electrolyte of Adult Wistar Rats. J Biol Agri Healthcare 3: 116-124.
28. Tietz NW, Pruden EL, Siggaard-Anderson O (1994) In: Burtis, CA, Ashwood ER. (Eds.), Tietz textbook of Clinical Chemistry. W. B. Saunders Company, London, UK. pp. 1354-1374.
29. Philip DM (2005) Clinical chemistry in diagnosis and treatment (6th ed.) Book Power.
30. Browse N (2005) Introduction to the symptoms and signs of surgical diseases (4th edn) Book Power, USA.
31. Chawla R (1999) Kidney Function Tests. In: Practical Clinical Biochemistry, Methods and Interpretation. (2nd edn), New Delhi, India pp: 90-92.
32. Onu A, Saidu Y, Ladan MJ, Bilbis LS, Aliero AA, et al. (2003) Effect of aqueous stem bark extract of *Khaya senegalensis* on some biochemical, haematological, and histopathological parameters of rats. J Toxicol 2013: 1-9.
33. Devaki M, Nirupama R, Yajurvedi HN (2011) Reduced antioxidant status for prolonged period due to repeated stress exposure in rat. JSPB 7: 139-147.
34. Krutz F, Sohn YH, Gloe T, Zahler S, Riexinger T, et al. (2002) NAD(P)H oxidase-dependent platelet superoxide anion release increases platelet recruitment. Blood 100: 917-924.
35. Halliwell B (2001) Role of free radicals in the neurodegenerative diseases: therapeutic implications for antioxidant treatment. Drugs Aging 18: 685-716.
36. Fahaid H, Al-Hashem, Bin-Jaliah I, Dallak AM, Nwoye LO, et al. (2011) Khat (*Catha edulis*) Extract increases oxidative stress parameters and impairs renal and hepatic functions in rats. BMB 33: 1-9.
37. Banjo TA, Kasim LS, Iwalokun BA, Mutiu WB, Olooto WE, et al. (2013) Effects of different extraction methods on in-vitro antimicrobial properties of *Lagenaria breviflora* whole fruits. New York Sci J 6: 60-65.
38. Yakubu MT, Bilbis LS, Lawal M, Akanji MA (2003) Biochemistry 15: 50-56.
39. Onasanwo SA, Singh N, Saba BA, Oyegbami AA, Oridupe OA, et al. (2011) Anti-ulcerogenic and *in vitro* antioxidant activities of *Lagenaria breviflora* (LB) whole fruit ethanolic extract in laboratory animals. Pharmacognosy Res 3: 2-8.
40. Francis G, Kerem Z, Makkar HPS, Becker K (2002) The biological action of saponins in animal systems: a review. Br J Nutr 88: 587-605.
41. Nandi B, Roy S, Bhattacharya S, Babu SPS (2004) Free radicals mediated membrane damage by the saponin sacaciaside A and acaciaside B. Phytother Res 18: 191-194.
42. Ayorinde BT, Akanji MA, Yakubu MT (2008) Alterations in some marker enzymes of liver and kidney damage following chronic administration of aqueous extract of *Tapinanthus globiferus* leaves to rats. Phcog Mag 4: S9-S14.
43. Kaplan MM. Alkaline phosphatase (1972) N Engl J Med 286: 220-223.
44. Olatunde A, Oladiji AT, Oloyede HOB (2014) Toxicological evaluation of aqueous extract of *Mangifera Indica* Linn (Mango) stems bark on the activities of some enzymes in Albino rats. N Y Sci J 7: 40-45.