



Fracture zygoma and its management our experience

*Balasubramanian Thiagarajan *Seethalakshmi Narashiman * Karthikeyan Arjunan

*Stanley Medical College

Abstract:

Zygoma is a very crucial component which maintains facial contour. Fractures involving zygoma is very common, in fact it is the second most common facial bone to be fractured following facial trauma (next only to nasal bones). Fractures involving maxilla not only creates cosmetic deformities, it also causes disruption of ocular and mandibular functions too. This article attempts to discuss in detail the etiopathogenesis and the various management options available. It also includes our 3 years experience in treating these patients at Stanley Medical College Chennai. During the period of 3 years between 2010 - 2012 about 82 patients got treated in our institution for faciomaxillary trauma.

Introduction:

Zygoma plays a vital role in maintaining facial contour. This is because the facial contour is directly influenced by underlying bony architecture¹. Fracture and dislocation of this bone not only causes cosmetic defects but also disrupts ocular and mandibular functions too. The zygomatic region is a prominent portion of the face next only to the dorsum of the nose. This predisposes this bone to various trauma². The bony architecture of this bone is rather unique, it enables it to withstand blows with significant impact without being fractured. At the most it gets disarticulated along its suture lines. Fractures can involve any of the four articulations of zygoma which include zygomatico-maxillary complex, zygomatic complex proper, orbitozygomatic complex. Fractures involving zygoma should be repaired at the earliest because it can cause both functional and cosmetic defects.

Important functional defects involving this bone is restriction of mouth opening due to impingement on the coronoid process³. It is hence mandatory to diagnose and treat this condition properly. It is also important to reduce this fracture and fix it accurately, because skeletal healing after inadequate reduction can cause reduced projection of malar region of the face leading on to cosmetic deformities. Accurate assessment of position of the fractured bone should be performed in relation to skull base posteriorly and midface anteriorly. This assessment is very important before reduction is attempted to ensure accurate reduction of the fractured fragments.

Importance of facial buttresses in fracture of middle third of face⁴:

The buttress system of midface is formed by strong frontal, maxillary, zygomatic and sphenoid bones and their attachments to one another. The central midface contains many fragile bones that

could easily crumble when subjected to strong forces. These fragile bones are surrounded by thicker bones of the facial buttress system lending it some strength and stability.

Components of Buttress system:

For better understanding the components of the facial buttress system have been divided into:

1. Vertical buttresses
2. Horizontal buttresses

Vertical buttress:

These buttresses are very well developed.

They include:

1. Nasomaxillary
2. Zygomaticomaxillary
3. Pterygomaxillary
4. Vertical mandible

Majority of the forces absorbed by midface are masticatory in nature. Hence the vertical buttresses are well developed in humans.

Horizontal buttresses:

These buttresses interconnect and provide support for the vertical buttresses. They include:

1. Frontal bar
2. Infraorbital rim & nasal bones
3. Hard palate & maxillary alveolus

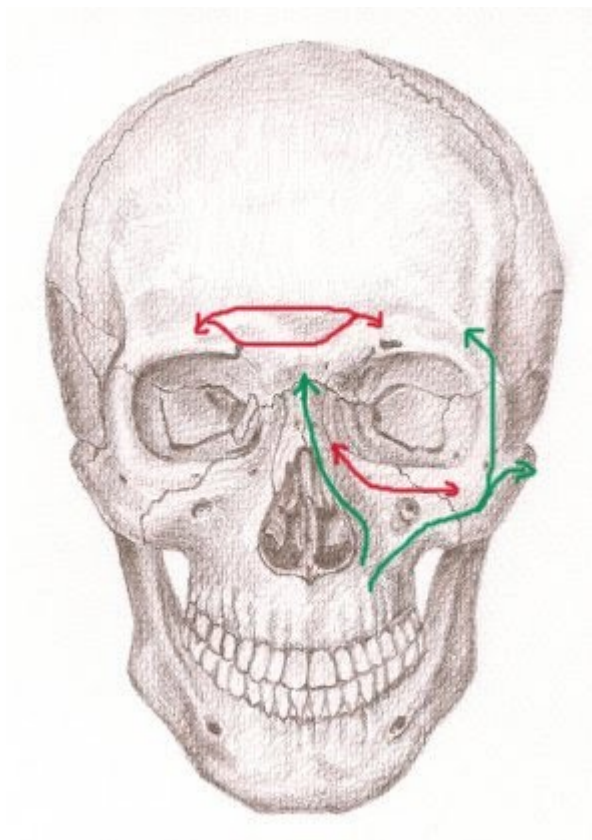


Diagram illustrating the Buttress system of the facial skeleton

Incidence:

Among the 280 trauma patients admitted for treatment at Stanley Medical College 82 had sustained faciomaxillary injuries.

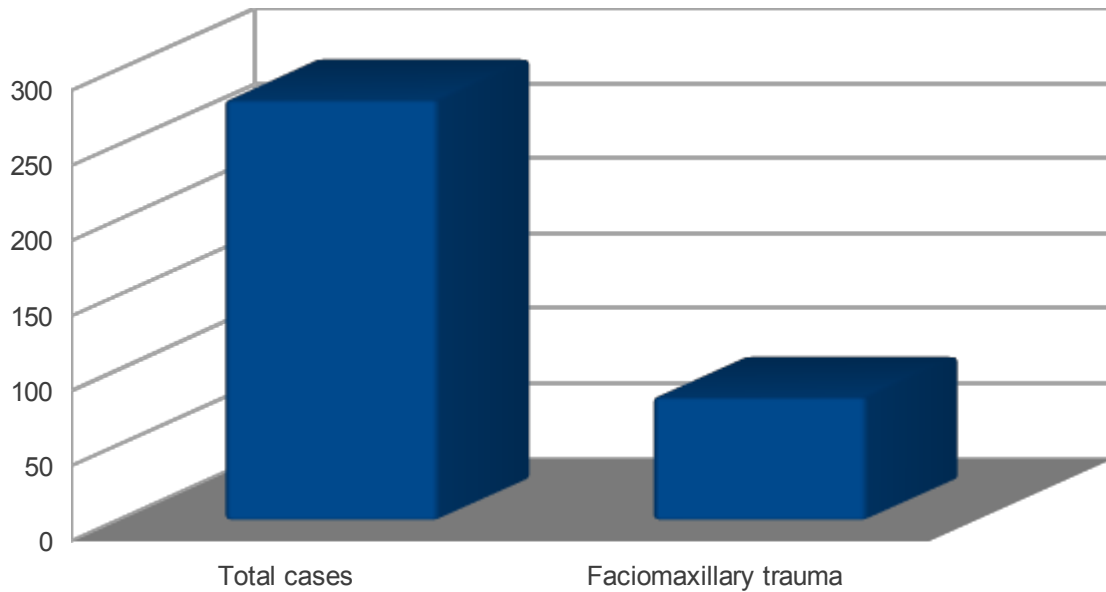


Chart showing the incidence of faciomaxillary trauma in comparison with other trauma cases

Among the cases studied 70 of them were males and the rest were females.

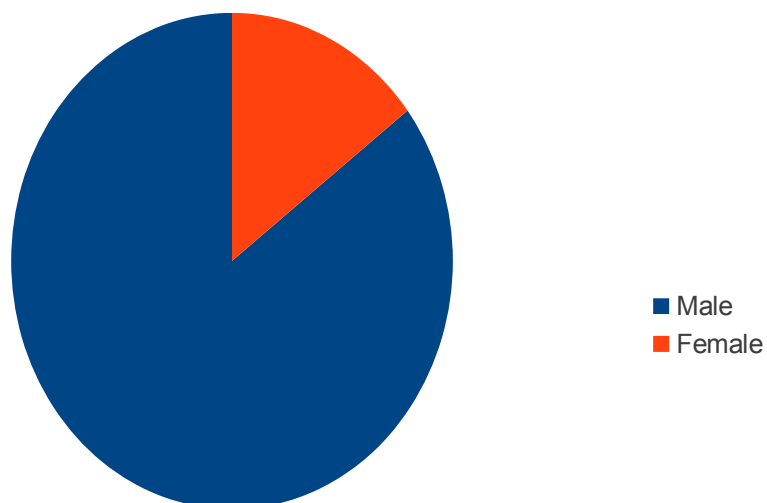


Chart showing the number of male and female patients who presented with fracture of zygoma

Classification of zygoma fracture:

Leefort classification:

1. Non displaced – Symptomatic treatment. No reduction necessary
2. Displaced – Closed reduction is necessary
3. Comminuted – Open reduction is necessary
4. Orbital wall fracture – If ocular symptoms predominate it should be attended first. After oedema subsides then open reduction can be attempted.
5. Zygomatic arch fracture – Open reduction with stabilization using micro plates / wiring.

Knight & North classification ⁵:

This classification suggested by Knight et al in 1961 helped to determine prognosis and optimal treatment modality for these individuals.

Group I fractures:

In these patients fracture lines in zygoma could be seen only in imaging. There is absolutely no displacement. These patients could ideally be managed conservatively by observation and by asking the patient to eat soft diet.

Group II fractures:

This group includes isolated fractures of the arch of zygoma. These patients present with trismus and cosmetic deformities.

Group III fractures:

This include unrotated fractures involving body of zygoma.

Group IV fractures:

This involves medially rotated fractures of body of zygoma.

Group V fractures:

This involves laterally rotated fractures of body of zygoma. This type of fracture is very unstable and cannot be managed by closed reduction. Open reduction will have to be resorted to.

Group VI fractures:

This is complex fracture. It has multiple fracture lines over the body of zygoma. This condition is difficult to manage by closed reduction. Open reduction and microplate fixation is indicated in these patients. This type of fracture should not be managed by closed reduction alone because the presence of oedema / haematoma would mask the cosmetic deformity giving an impression that reduction has occurred. After reduction of oedema and followed by the action of masseter the fractured fragment may distract making the cosmetic deformity well noticeable.

In our Institution patients with zygomatic bone fractures presented under various categories of Knight classification. Majority of them belonged to Group I and II fractures.

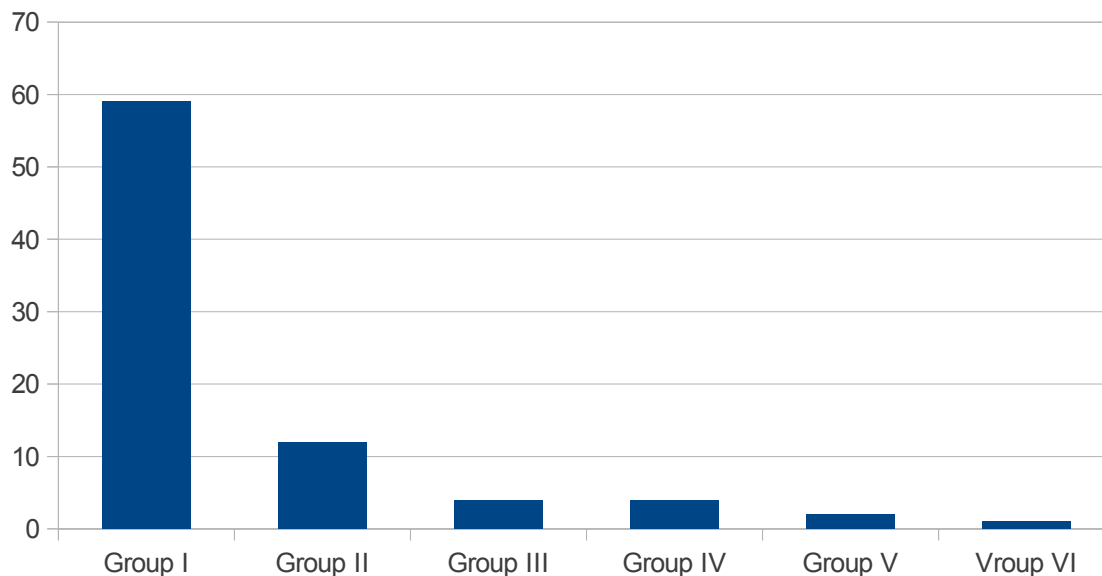


Table showing the number of patients in various groups of Knight's classification

Mason's classification of fracture zygoma:

Mason⁶ et al used CT imaging to classify various forms of fracture zygoma. CT imaging provides the most accurate information about facial skeleton. Fractures involving facial bones, their positions, whether it is displaced or not can be clearly seen in CT scan images. Mason classified fractures involving zygoma into:

1. Low energy injury
2. Medium energy injury
3. High energy injury

Low energy injury:

Low energy fractures involving zygoma involves minimal or no displacement of fractured fragments. In this group of patients fractures are commonly seen in the frontozygomatic suture line. This area is very stable and hence fractures involving this area can be treated conservatively.

Middle energy injury:

Fracture zygoma due to middle energy injury causes fractures of all its supporting buttresses. There may be mild to moderate displacement and comminution. These patients invariably need eyelid / intraoral approach for adequate reduction and fixation of fracture.

High energy injury:

This injury frequently causes Lefort fractures. These patients have difficulty in opening their mouth. Repair of fractures involving this area should be carried out through multiple approaches which include:

Bicoronal approach

Intraoral approach

Eye lid approach

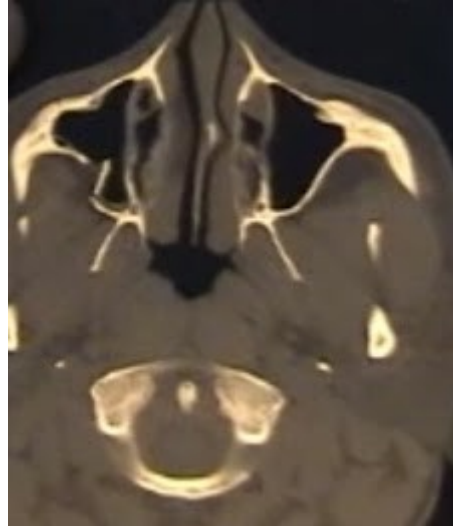
Studies reveal that primary bone healing allows quicker and stronger bone formation than callous healing⁷. Rigid fixation of fractured fragments promote primary healing in preference to callous formation.

While performing open reduction it should be borne in mind that Titanium plates⁸ are preferred to biodegradable ones when the process of reduction leaves small gaps between fractured fragments.

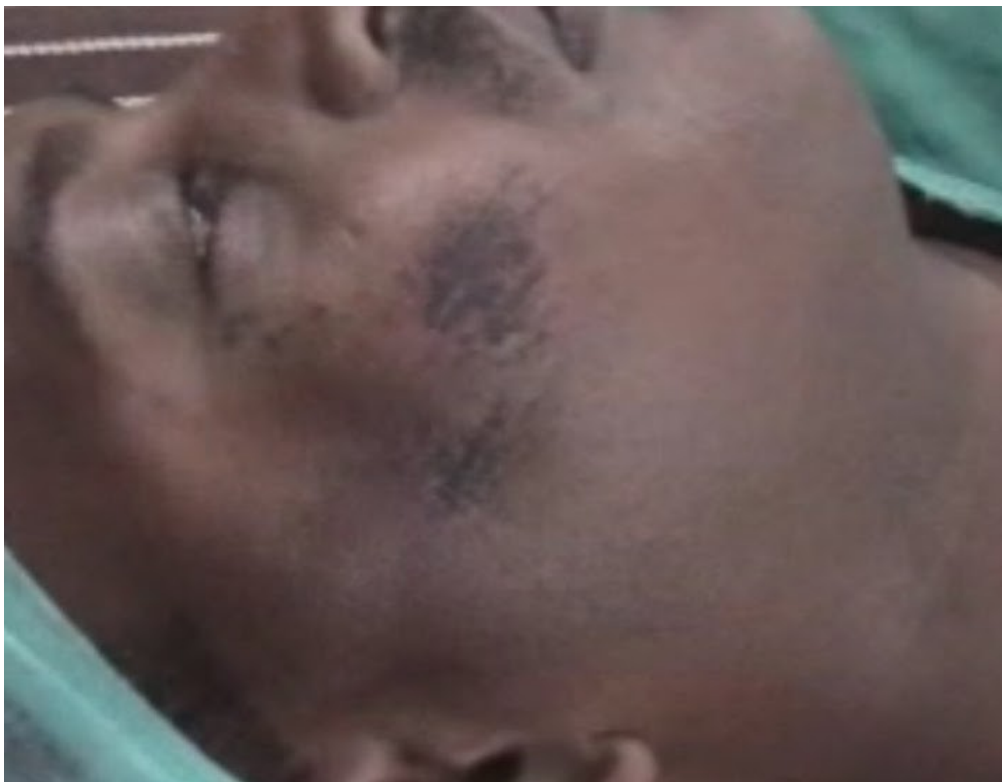Clinical features:

1. Anaesthesia / Paraesthesia of that side of the face
2. Inability to open the mouth
3. Flattening of zygomatic area
4. Diplopia
5. Subconjunctival haemorrhage
6. Eye lid oedema
7. Periorbital haemorrhage
8. Lateral canthal dystopia
9. Ipsilateral epistaxis
10. Buccal sulcus haematomas
11. Enophthalmos in orbital floor fractures

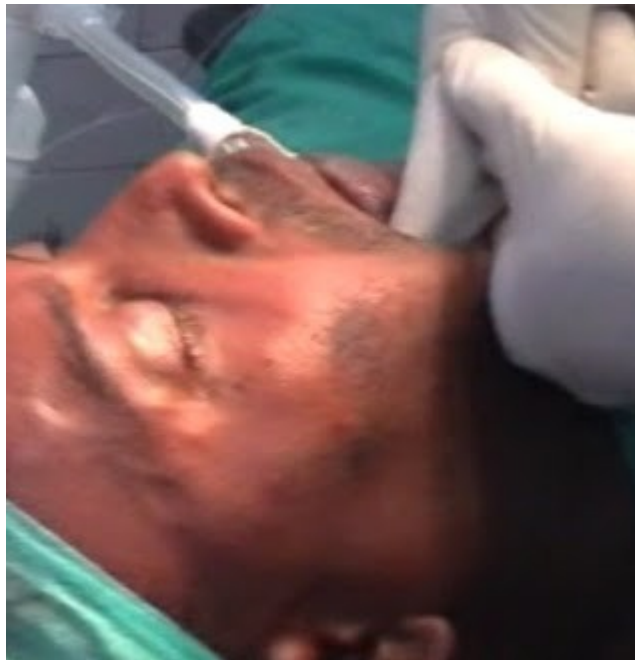Ophthalmic examination is a must if any of the ophthalmic manifestations of fracture of zygoma is seen. In the presence of ruptured globe, retinal detachment and traumatic optic nerve atrophy management of ophthalmic manifestations take precedence over fracture reduction procedure.



Axial CT image of nose and sinuses showing fracture of zygoma with medial displacement (stable)



Picture showing depressed fracture of zygoma (medial displacement)



Picture showing reduction being performed via intraoral route

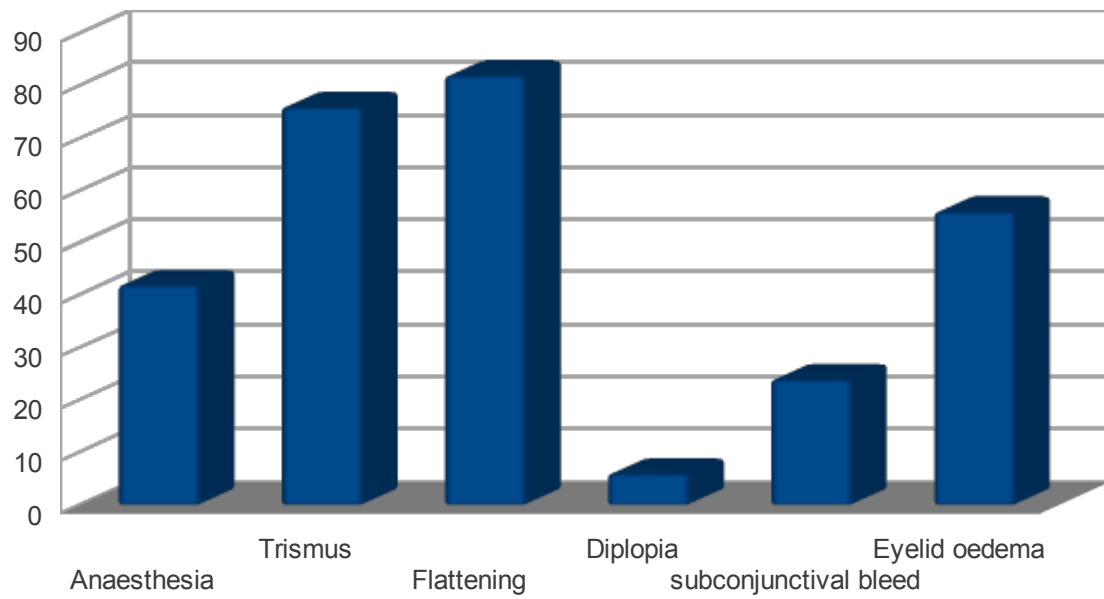


Chart showing the common clinical features our patients presented with

Orbital exploration is indicated in the following circumstances:

1. Severe comminution
2. Displacement of orbital rim
3. Displacement of greater than 50% of the orbital floor with prolapse of orbital contents into the maxillary sinus
4. Orbital floor fracture of greater than 2 cm²
5. Combination of inferior and medial orbital wall fractures
6. Suspected involvement of orbital apex

Our patients commonly presented with cosmetic defect of the malar area, followed by trismus.

Isolated zygomatic arch fracture:

This fracture can be managed easily without the necessity of internal fixation / splinting if reduction is performed within the span of 72 hours following injury. Fractures involving zygomatic arch can cause inability of movement of mandible. These fractures can be reduced using Gillie's temporal approach or Dingman's⁹ supraorbital approach. Other approaches include Buccal sulcus approach. Studies reveal that temporal or supraorbital approaches provided the best results¹⁰.

Ruler test:

This is a rather useful clinical test to identify patients with fracture of zygoma.

Two rulers are used as shown in the figure below to perform this test. These rulers are placed in front of the ears. Ruler is found to deviate on the side of fracture.

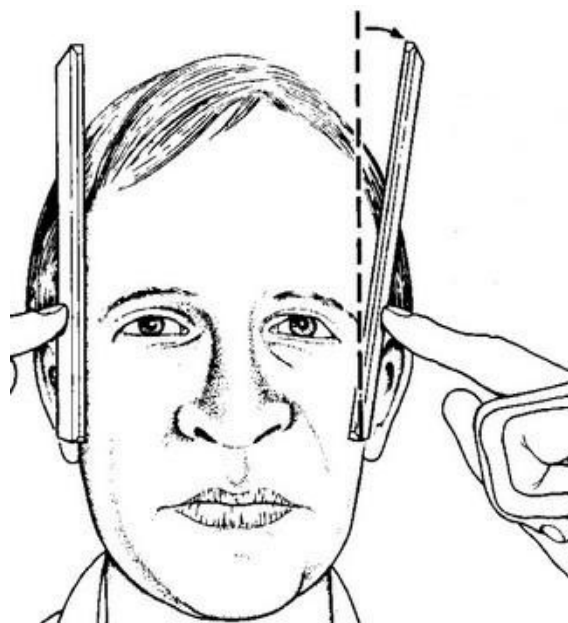


Figure showing ruler test being performed

Gillie's technique of reducing fracture zygoma:

Small incision is made over temporal area superficial temporal artery is avoided.

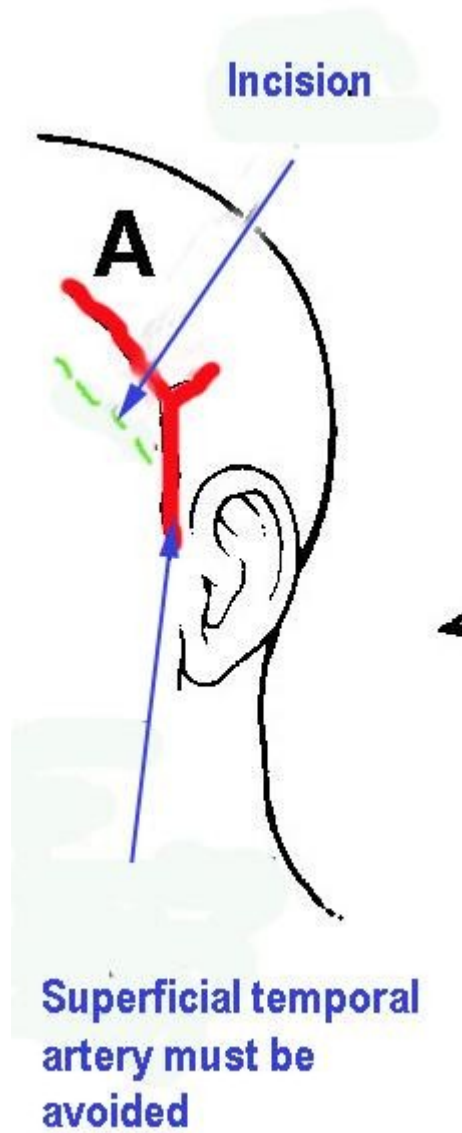
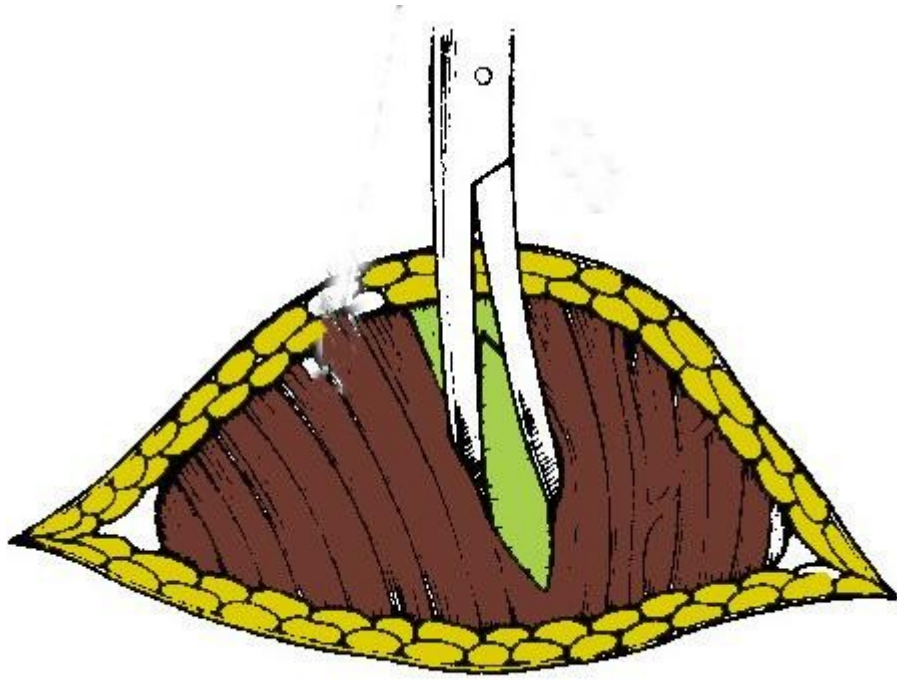
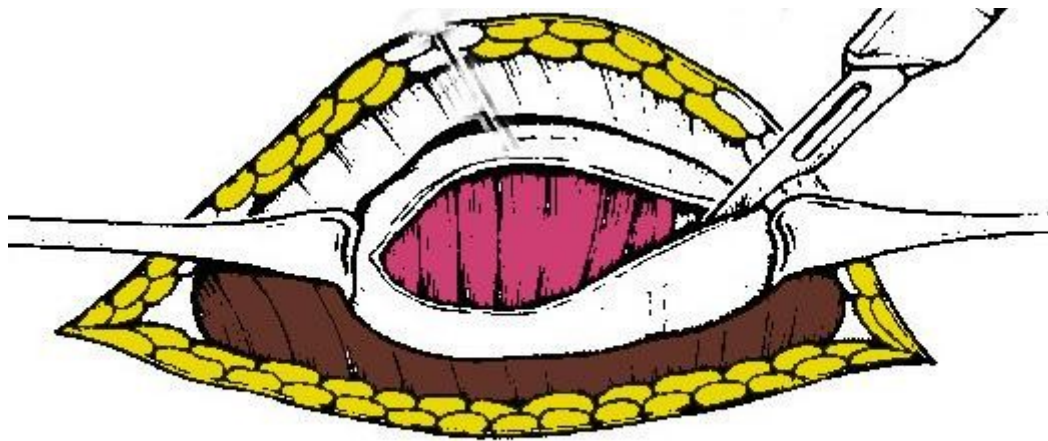


Figure showing incision for Gillies procedure



Auricularis superior muscle is cut along the line of its muscle fibers



Temporalis fascia is cut with a knife



Periosteal elevator is inserted through the incision and the fractured fragment is elevated. A gauze piece is used as a leverage

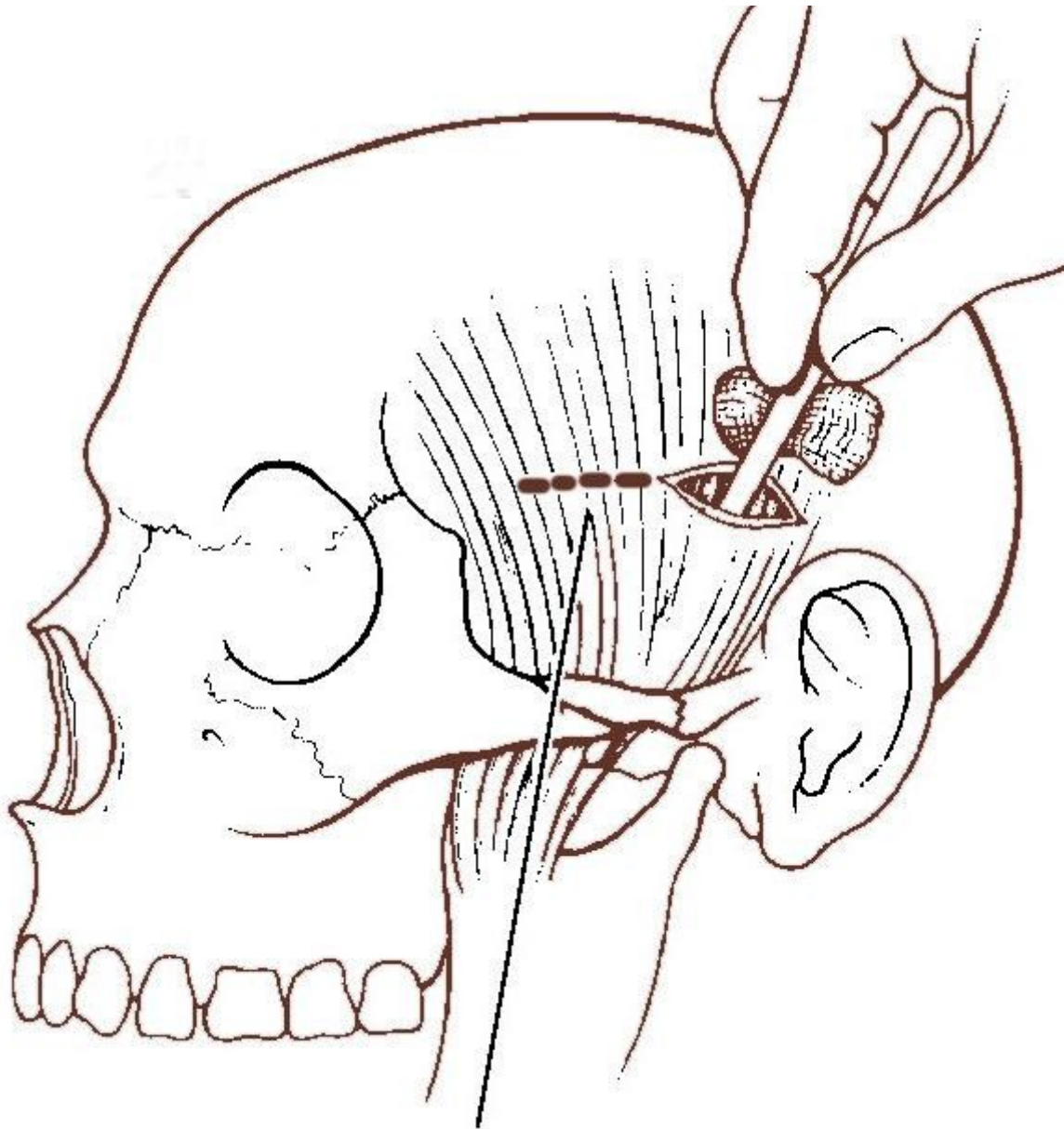


Figure showing fracture arch of zygoma being reduced.

Zygomatic complex fractures:

These fractures are invariably managed by open reduction with two point / three point fixation. Surgical procedure is performed usually after 4- 6 weeks following injury. If fractures are more than 3 months old then osteotomy will have to be performed. Bone grafts need to be used to perform accurate repair. Usually two point fixation is sufficient in majority of patients. Two point fixation involves microplate fixation at zygomatico-frontal and zygomatic arch areas. When using microplates for zygomatico-frontal area care should be taken to position it slightly posteriorly so

that untoward subcutaneous projection of the plate can be avoided.

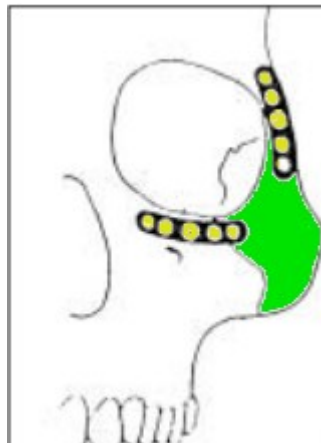


Figure showing two point fixation points

Two point fixation is sufficient in a majority of patients. Rarely when fracture is extensive and associated with lateral displacement of fractured fragments three point fixation need to be resorted to.

Bicoronal approach may be used to approach this area for open reduction purposes. Eye brow incision / transconjunctival incisions can also be used to access this area.

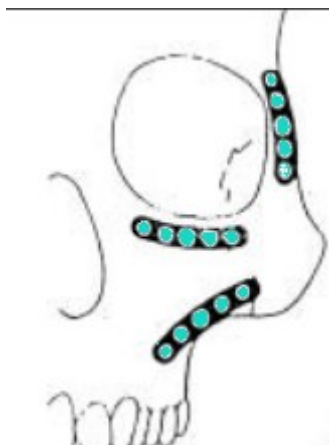

Figure showing three point fixation areas

As shown in the figure three point fixation includes fixing:

1. Frontozygomatic suture
2. Infraorbital rim
3. Zygomatico maxillary buttress

In our analysis only 2 of the 82 patients studied needed two point fixation. All the other patients were managed either conservatively or by closed reduction.

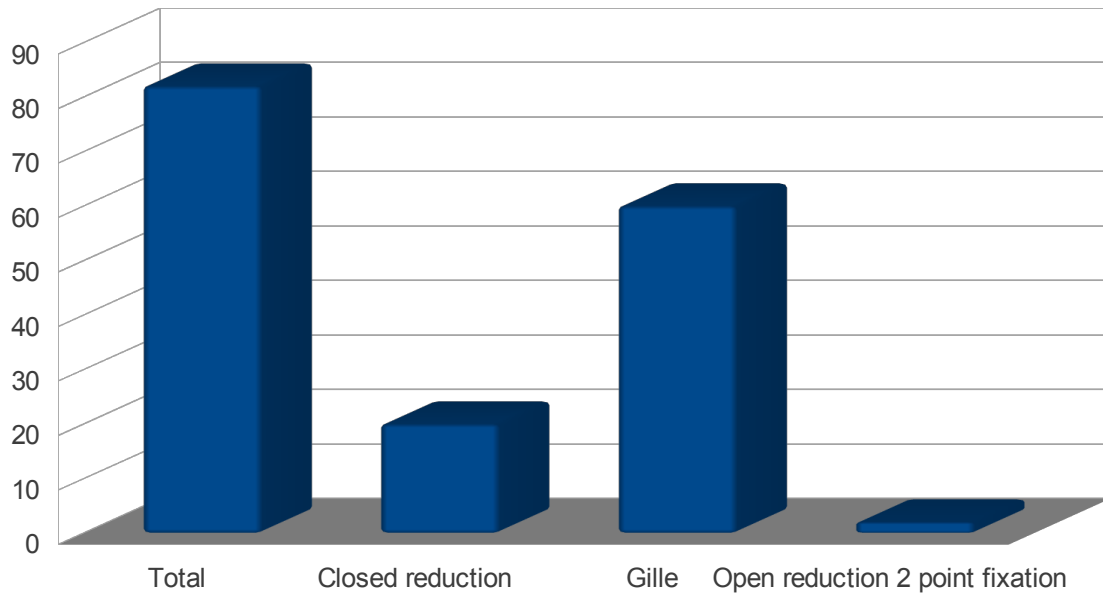


Chart showing the number of patients who underwent various procedures for the management of zygomatic fracture

Classification of zygomatico-maxillary complex fractures:

Zingg's classification ¹¹:

Zingg in 1992 had separated zygomatico-maxillary complex into three types:

1. Type A
2. Type B
3. Type C

Type A :

This type is associated with one component of the tetrapod structure.

This type is subdivided into three subgroups:

Type A1 zygomatic arch alone is fractured.

Type A2 fracture of lateral orbital wall

Type A3 fracture of inferior orbital rim

Type B fracture:

This type of fracture involves all 3 buttresses. Also known as Tripod fracture. This fracture will have to be treated by two point fixation / three point fixation techniques.

Type C fracture:

These are comminuted fractures involving zygoma.

Orbital floor is the weakest component of the zygomatic-maxillary complex. Type A3, B and C are associated with fracture of the floor of orbit with risk of injury to orbital contents.

Conclusion:

This study reveals:

1. Majority of our patients with fracture zygoma presented with flattened malar region. Next common symptom of presentation was trismus.
2. All of our patients except for one with fracture zygoma had stable medial displacement
3. Majority of our patients were managed conservatively / Gillie's procedure.
4. Only two patients needed open reduction with three point fixation

References:

1. Edward E, Winai K (1996) Analysis of treatment of the isolated zygomaticomaxillary complex fractures. *J Oral Maxillofac Surg* 54(4):386–400
2. Chowdhury SKR, Menon PS: Etiology and management of zygomatico maxillary complex fractures in the armed forces. *MJAFI* 2005, 61:238-240.
3. Nayyar MS: Management of zygomatic complex fracture. *J Coll Physicians Surg Pak* 2002, 12:700-705.
4. Manson PN, Hoopes JE, Su CT. Structural pillars of the facial skeleton: An approach to the management of Le Fort fractures. *Plast Reconstr Surg* 1980; 66:54–7.
5. Knight JS, North JF. The classification of malar fractures: An analysis of displacement as a guide to treatment. *Br J Plast Surg*. 1961;13:325.
6. Manson PN, Markowitz B, Mirvis S, et al. Toward CTbased facial fracture treatment. *Plast Reconstr Surg*. Feb 1990;85(2):20212; discussion 2134
7. Lin KY, Bartlett SP, Yaremchuk MJ, et al. The effect of rigid fixation on the survival of onlay bone grafts: an experimental study. *Plast Reconstr Surg*. Sep 1990;86(3):44956.
8. Gosain AK, Song L, Corrao MA, et al. Biomechanical evaluation of titanium, biodegradable plate and screw, and cyanoacrylate glue fixation systems in craniofacial surgery. *Plast Reconstr Surg*. Mar 1998;101(3):58291
9. Dingman RO, Natvig P. *Surgery of Facial Fractures*. Philadelphia: WB Saunders Co; 1964.
10. Kobienia BJ, Sultz JR, Migliori MR, et al. Portable fluoroscopy in the management of zygomatic arch fractures. *Ann Plast Surg*. Mar 1998;40(3):2604.
11. Zingg M, Laedrach K, Chen J, et al. Classification and treatment of zygomatic fractures: a review of 1,025 cases. *J Oral Maxillofac Surg*. Aug 1992;50(8):77890.