

Clinical and immunological features of cataract surgery in uveitis

Sabina Majidova

National Center of Ophthalmology named after Academician Zarifa Aliyeva, 32/15 Javadkhan Str., AZ1114, Baku, Azerbaijan

For correspondence: sabinamedjidova@gmail.com

Received: March 23, 2023; Received in revised form: April 4, 2023; Accepted: April 18, 2023

There is much information about successful cataract surgery for different uveitis in the literature. However, the frequency of postoperative inflammation in uveitic cataract surgery even at the present stage of microsurgery remains quite high. The aim of this study was to evaluate the clinical and immunological features of the surgical treatment of uveitic cataracts. The study group of 52 patients (74 eyes) with uveitic cataracts (male - 29, female - 23) has been chosen on the basis of the clinical material of the National Centre of Ophthalmology named after Academician Zarifa Aliyeva. The examination complex was presented by ophthalmologic and immunological methods before and after the surgery. In all patients, phacoemulsification with intraocular lens implantation was used in order to remove cataracts against the background of the disease remission and no recurrence within 3 months prior to surgery. Despite the high professional level of surgeons and careful preoperative preparation, there were minor intraoperative and postoperative complications the structure of which depended on the initial severity of the operated eyes. Shortly after the surgery inflammation of varying severity was reported in 32 eyes (43.3%) and in the late period - in 28 eyes (37.8%). In patients with developed postoperative inflammation prior to the surgery there was observed a significant increase in the average immunoregulatory index (CD4+/CD8+), complement component C3 ($1753 \pm 10.01 \text{ mg/L}$), immunoglobulin A ($563.8 \pm 4.7 \text{ mg/dl}$), immunoglobulin G ($2028 \pm 7.4 \text{ mg/dl}$) and antinuclear antibody (1.8 ± 0.11) in serum relative to the control index ($p < 0.05$). Careful preoperative and postoperative control of the activity of the inflammatory process, early detection of postoperative complications, complete clinical examination of the posterior segment of the eye are the key to the successful treatment of uveitic cataracts. An immunological survey before surgery may serve as an additional method of assessment to predict the risk of postoperative exudative inflammatory reaction.

Keywords: *Uveitis, cataract, inflammation, survey, immune response*

ABBREVIATIONS

UC - uveitic cataract	CRP - C-reactive protein
OCT - optical coherence tomography	ANA – antinuclear antibody
IOL- intraocular lens	IgA – immunoglobulin A
BCVA - best corrected visual acuity	IgM – immunoglobulin M
IOP - intraocular pressure	IgA – immunoglobulin A
CME - cystoid macular edema	IgG – immunoglobulin G
CMT - central macular thickness	IgE – immunoglobulin E
	IRI - immunoregulatory index
	LLC - limited liability company

INTRODUCTION

Cataracts in uveitis can develop as a result of a direct inflammatory process of the uvea as well as long-term use of corticosteroids (Aliyeva and Shulpina, 2011; Gasimov et al., 2023; Agayeva et al., 2020). Pathological changes in UC are characterized not only by local anatomical and morphological processes, but also by systemic disorders, which determine the features of clinical and surgical management of such patients (Choi et al., 2022; Curnow et al., 2004). The incidence of cataracts in uveitis varies from 8% to 78% depending on the type of uveitis (Sen et al., 2016). Opacification often develops in the posterior layers of the lens with gradual progression but may also be diffuse. There are a lot of data in the literature on the successful surgical treatment of cataracts in various uveitis (Shilovskikh, Safonova, 2015; Llop and Papaliadis, 2018). But the frequency of postoperative inflammation in UC surgery even at the current level of development of microsurgery is relatively high (Chiu et al., 2017). The main postulates of success in UC surgery are careful preoperative and postoperative control of the activity of the inflammatory process, impeccable surgical technique, compliance with the requirements for biocompatibility and design of IOL, effective and early detection and treatment of postoperative complications, and a complete clinical examination of the posterior segment of the eye. The etiological diagnosis of uveitis is of paramount importance in planning a surgical strategy and further management of such patients. The complexity of diagnosis and choice of treatment tactics in many cases are complicated by the polyetiological nature of uveitis, the complexity of their pathogenesis, and the frequent combination of infectious and non-infectious factors (Balta et al., 2018).

The main importance in the pathogenesis of uveitis is given to violations of the immunological response. Uveitis refers to immune-mediated inflammatory diseases characterized by impaired regulation of immunity, chronic inflammation, and tissue damage (Minkus et al., 2021). Therefore, the formation of an immune response in the postoperative period of UC surgery occurs with the participation of all components of immune-active cellular structures.

The purpose of this research was to evaluate the clinical and immunological features of the surgical treatment of UC.

MATERIALS AND METHODS

The study group consisted of 52 patients (74 eyes) with UC (men - 29, women - 23); it was selected by blind sampling based on the clinical material of the National Center of Ophthalmology named after Academician Zarifa Aliyeva. The examination complex was presented by methods of ophthalmological and laboratory examination.

Ophthalmological examination: anamnesis survey, determination of visual acuity (using Huvitz Chart Projector CCP-3100 (HUVITZ Co, LTD, South Korea), refractometry (automatic keratorefractometer RC-5000, TOMEY, Japan), biomicroscopy of the anterior segment of the eye (slit lamp TOMEY TSL-5000, TOMEY, Japan and portable slit lamp Reichert, Japan), tonometry (applanation tonometer FT-1000, TOMEY, Japan), ophthalmoscopy of the fundus (slit lamp TOMEY TSL-5000, TOMEY, Japan) using lenses (Ocular High Mag 78D, Ocular Instruments Inc., USA), ultrasound examination of the eye (ophthalmic ultrasound scanner E-Z Scan AB5500, SONOMED, USA), specular microscopy (specular microscope EM-3000, TOMEY, Japan), OCT (Cirrus optic coherence tomography HD-OCT 5000, Carl Zeiss Meditec AG, Germany).

Laboratory methods: general blood analysis, determination of blood glucose, CRP, rheumatoid factor, antistreptolysin, fibrinogen, coagulogram, serological reactions to various infections and viruses, assessment of immune status. When assessing the immune system (factors of cellular and humoral immunity) the level of serum IgA, IgM, IgG, IgE, ANA, complement component C3 and the presence of ANA were calculated. Cellular immunity included the determination of the relative content in the blood of lymphocyte subpopulations expressing surface markers CD4+, CD8+ by staining cells in an immunofluorescent test using a set of monoclonal antibodies (LLC "Sorbent", Russia, No. 9398-331-13180653-02). Monoclonal antibodies manufactured by LLC "Sorbent" were tested within the framework of the 5th (USA, 1993), 6th (Japan, 1996) and 7th

(Great Britain, 2000) International Human Leukocyte Differentiation Antigens workshops. Phenotyping of stained cells was performed using an AXIO Scope A1 Carl Zeiss fluorescent microscope (Germany). The factors of humoral immunity were determined by the Mancini immunodiffusion method. Benchmarks were determined by examining 50 voluntarily apparently healthy representatives of the appropriate age.

All subjects were warned about the ongoing scientific study and gave informed consent to participate in it (protocol No. 25 of the Ethics Committee of the Azerbaijan Medical University). A comprehensive laboratory examination was carried out for several purposes: to determine the etiology of the disease, to study the presence of allergic sensitization and associated viral infection, to assess the state of the immune status during treatment and the risk of postoperative inflammation, and to determine the timing of the next examination.

In all 52 patients with UC (74 eyes), the clouded lens was removed by phacoemulsification with IOL implantation against the background of disease remission and no recurrence of uveitis within 3 months before surgery. Patients were observed in dynamics before and after surgery (1-3 days, 1 month, 6 months, 1 year after surgery). Depending on the etiology of uveitis patients received specific general and local treatment (anti-inflammatory, desensitizing, anti-infective, etc.) before and after surgery. The duration of the uveitis in all patients ranged from 6 months to 5 years. If necessary, patients were consulted by narrow specialists (rheumatologist, phthysiatrician, endocrinologist, cardiologist, dentist, neuropathologist, etc.).

The results obtained were processed by the method of variation statistics with the calculation of arithmetic means (M), minimum (min) and maximum (max) values of the sample. The reliability of the obtained results was assessed using Student's t-test.

RESULTS AND DISCUSSION

Age of the examined patients ranged from 20 to 60 years: 20-30 years old - 7 patients (13.5%);

31-40 years old - 14 (26.9%); 41-50 years old - 12 (23.1%); 51 - 60 years - 19 (36.5%).

Fig. 1 presents the results of the etiological diagnosis of uveitis, against which a cataract developed in the examined patients. Most often, UC was observed in reactive arthritis (23%), ankylosing spondyloarthritis (16.2%), rheumatoid arthritis (14.9%), in general - 54.1%. The most frequent spread of UC among these patients is explained by the mutual influence of both the inflammatory process itself and the use of steroids in the complex systemic therapy of the underlying disease which is the etiological cause of uveitis.

As a result of the analysis of the incidence of cataract development depending on the duration and frequency of relapses of uveitis, predominant clouding of the lens was recorded in the first five years of the disease in the vast majority of patients with a history of 5-8 exacerbations of the inflammatory process of the choroid (38 patients, 73.1%). The development of UC in both eyes was diagnosed in 22 patients (42.3%).

According to the international classification of uveitis by localization (Standardization of Uveitis Nomenclature (SUN)), the development of UC was registered against the background of 4 types of uveitis: anterior - in 31 (59.6%), intermediate- in 2 (3.8%), posterior - in 8 (15.4%) and panuveitis - in 14 (26.9%) (Fig. 2). As it can be seen, the most common clouding of the lens developed in anterior uveitis (59.6%).

The mean value of BCVA before surgery was 0.1 ± 0.09 (pr.l.certae to 0.4). The average value of IOP is 17 mm Hg (9 to 24.5 mm Hg). Given the preoperative clinical features of operated eyes with UC (Table 1), ophthalmic surgeons had to resort to additional surgical procedures (Table 2). The main condition for this is the desire to minimize surgical trauma to reduce postoperative inflammation risk. Table 1 shows biomicroscopic signs of changes associated with UC in the examined group. As can be seen from the biomicroscopic examination results, ophthalmic surgeons had to face the following local status features most often during the operation: iris dystrophy of varying severity (71.6%), posterior synechiae (66.2%) and pupil rigidity (41.9%). It should be noted that in the majority of patients (45 patients - 86.5%) more than two of the above signs were observed

simultaneously in one eye which was one of the main reasons for the need for a thorough approach

to the upcoming cataract surgery and the development of postoperative inflammation.

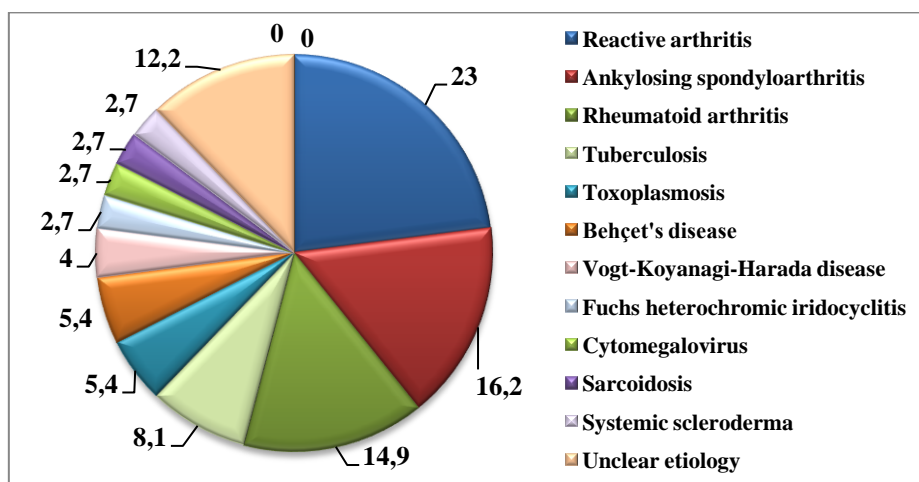


Fig. 1. Distribution of patients with UC by etiological feature (in %).

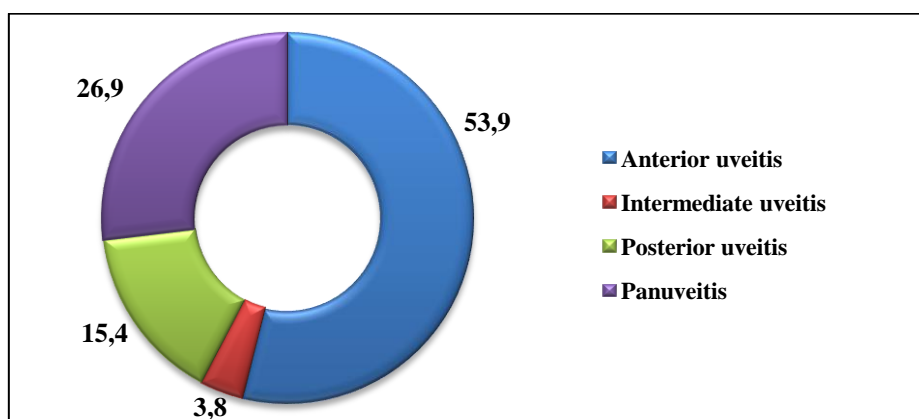


Fig. 2. Distribution of patients with UC by the anatomical feature of uveitis (in %).

Considering that the density of cataracts is the leading factor determining the energy parameters of phacoemulsification and the time of ultrasound exposure which in turn also has a certain effect on the degree of postoperative inflammatory reaction. Table 3 shows the distribution of operated 74 eyes with UC in the examined group according to the degree of density of the nucleus of the clouded lens according to L. Buratto.

Despite the high professional level of operating surgeons and the necessary preoperative preparation of patients with UC, there were also minor intraoperative complications the structure of which depended on the initial severity of the

operated eyes: hemorrhage in the anterior chamber - 4 eyes (5.4%), damage to the pupillary edge of the iris - 1 eye (1.4%), rupture of the posterior capsule and prolapse vitreous body - 2 eyes (2.7%).

An increase in visual results was noted in all 52 patients. The dynamics of postoperative BCVA are presented in Table 4. BCVA below 0.2 in 16 eyes (21.6%) in the early postoperative period was due to the initial presence of the consequences of uveitis affecting functional parameters: ribbon-like corneal degeneration (6 eyes); secondary glaucoma (5 eyes) and CME (5 eyes). BCVA in the range of 0.2 – 0.5 after a year (40 eyes – 54.1%) was caused by secondary

cataract (10 eyes); recurrence of uveitis with proliferative changes in the vitreous (22 eyes); CME (8 eyes). BCVA above 0.5 was registered in

22.9% of cases of operations performed (17 eyes) after a year.

Table 1. Features of the local status of patients with UC before surgery

Clinical features	Absolute number of eyes	Relative amount (%)
Ribbon-like corneal degeneration	8	10.8
Anterior synechiae	7	13
Posterior synechiae	49	66.2
Pupil rigidity	31	41.9
Shallow anterior chamber	24	32.4
Iris dystrophy	53	71.6
Secondary glaucoma	10	13.5
Degree I-II lens subluxation	14	18.9
Destruction of the vitreous body	18	24.3
Epiretinal membrane	8	10.8

Table 2. The frequency of additional surgical procedures in UC surgery

Surgical manipulation	Absolute number of eyes	Relative amount (%)
Staining of the anterior capsule	65	87.8
Pupil dilation	29	39.2
Separation of synechiae	56	75.7
Application of iris retractors	17	22.9
Iridoplasty	7	9.5
Basal iridectomy	5	6.7

Table 3. Distribution of patients with UC according to the degree of density of the lens nucleus (according to L.Buratto)

The degree of density of the lens nucleus	Absolute number of eyes	Relative amount (%)
2	21	28.4
3	44	59.4
4	9	12.2
Total	74	100

Table 4. Dynamics of BCVA after uveal cataract surgery (absolute number of eyes, %)

BCVA	1-3 days after surgery	A month later	In a year
<0.2	16 (21.6%)	10 (13.5%)	17 (22.9%)
0.2 – 0.5	39 (52.7%)	37 (50%)	40 (54.2%)
>0.5	19 (25.7%)	27 (36.5%)	17 (22.9%)
Total	74 (100%)		

Table 5. Results of evaluation of the frequency of postoperative complications after UC surgery

Postoperative complication	Absolute number of eyes	Relative amount (%)
Early postoperative complications		
Degree 1 Tyndall effect	14	18.9
Degree 2 Tyndall effect	3	4.1
Precipitates on the IOL	8	10.8
Posterior synechiae, vitreous effusion	7	9.5
Increase in IOP	5	6.8

Late postoperative complications		
Recurrence of uveitis	28	37.8
CME	8	10.8
Secondary cataract	10	13.5
Secondary glaucoma	2	2.7

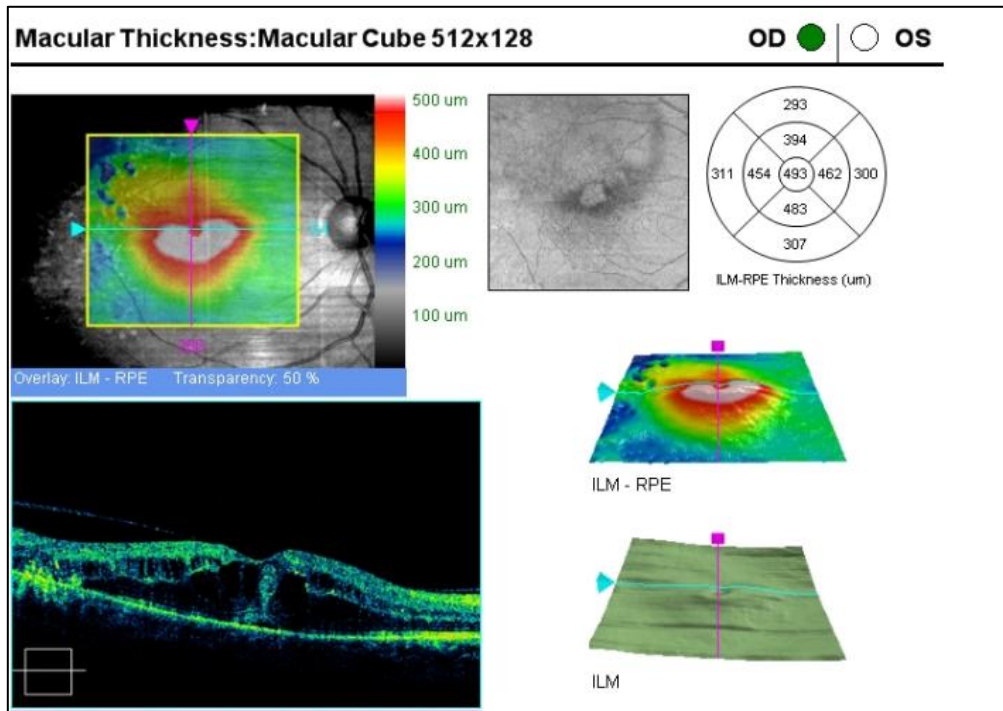


Image 1. CME before treatment in a patient B.M. with UC, CMT =493 um (OCT, Cirrus optic coherence tomography HD-OCT 5000, Carl Zeiss Meditec AG).

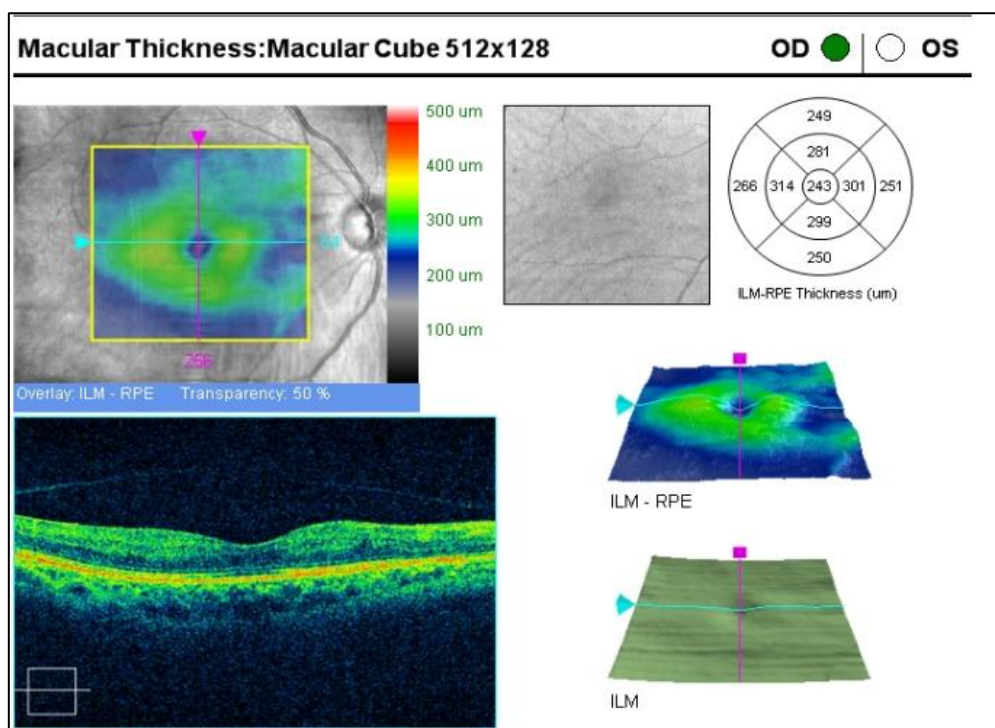


Image 2. CME after treatment in a patient B.M. with UC, CMT =243 um (OCT, Cirrus optic coherence tomography HD-OCT 5000, Carl Zeiss Meditec AG).

Results of the analysis of the frequency of early and late postoperative complications are presented in Table 5. As can be seen from Table 5, postoperative complications were caused by the inflammatory reaction of the operated eye to surgery and were all stopped by the appointment of appropriate anti-inflammatory therapy. In the early postoperative period, complications of inflammatory etiology of varying severity were registered in 37 eyes in 16 patients (30.8%). The most common of these was an inflammatory reaction with the degree 1 Tyndall effect in 14 eyes out of 74 operated (18.9%). The most common late postoperative complication was a recurrence of uveitis in 28 eyes (37.8%). Recurrence of uveitis, which developed within a year after surgery, was stopped by the appointment of specific immunosuppressive therapy in 6 patients (12 eyes) with ankylosing spondyloarthritis; 3 patients (6 eyes) with Behcet's disease; 3 patients (6 eyes) with rheumatoid arthritis; 2 patients (4 eyes) with Vogt-Koyanagi-Harada disease. Even before surgery, all patients with pathological changes in the macula (epiretinal membrane with traction

component in 8 eyes) in the late postoperative period had the development of CME (8 eyes - 10.8%) (Image 1). Restoration of visual functions and the thickness of the macula in 6 cases were noted after conservative anti-inflammatory therapy; in 2 cases were noted after intravitreal steroid injection (Image 2).

Secondary cataract in 10 eyes was resolved by YAG-laser capsulotomy on the background of anti-inflammatory therapy. In secondary glaucoma, 2 patients (2 eyes) were prescribed topical hypotensive therapy followed by laser iridectomy. One of them due to the absence of a persistent hypotensive effect of the treatment underwent surgery with implantation of glaucoma drainage.

The clinical examination was carried out along with the analysis of the results of the laboratory immunological examination. It was interesting for us to present comparatively the results of an immunological study conducted in dynamics in 32 patients without postoperative complications (Table 6) and in 20 patients with postoperative inflammation of varying severity (Table 7). In patients without the development of inflammation in the postoperative period, there

were no significant changes in the average values of immunological parameters of the immune response. Some factors of humoral immunity (IRI=CD4+/CD8+, IgM, IgG, IgA, complement

component C3) were higher than the control indicators but this difference had no special significance ($p>0.05$).

Table 6. Results of a comparative immunological survey of patients without postoperative complications (n=32)

Immunology factor	Control	Unit	Before surgery, M±m	3 days after surgery, M±m
CD4+/CD8+	1.2 - 2.5	-	2.37±0.11	2.45±0.09
Complement component C3	1032 - 1495	mg/l	1234±14.2	1376±17.7
IgM	60 - 280	mg/dl	221.8±9.7	234.9±10.4
IgA	90 - 450	mg/dl	464±11.3	469±10.9
IgG	800 - 1800	mg/dl	1981±12.8	2017±12.7
IgE	0-100	IU/ml	34±7.8	45±9.9
ANA (IgG)	≤1,0 - negative; >1,0 - positive	-	0.8±0.02	0.9±0.07
CRP	0-6	mg/l	6 ±0.02	6 ±0.01

Table 7. Results of a comparative immunological survey of patients with postoperative complications (n=20)

Immunology factor	Control	Unit	Before surgery, M±m	3 days after surgery, M±m
CD4+/CD8+	1.2 - 2.5	-	2.89±0.23	3.17±0.01*
Complement component C3	1032 - 1495	mg/l	1753±10.01*	2069±9.31*
IgM	60 - 280	mg/dl	219.4±8.2	263.7±7.1
IgA	90 - 450	mg/dl	563.8±10.7*	589.8±11.4*
IgG	800 - 1800	mg/dl	2028±13.4*	2154±12.8*
IgE	0-100	IU/ml	43±6.8	45±10.9
ANA (IgG)	≤1.0 - negative; >1.0 - positive	-	1.8±0.11*	2.1±0.09*
CRP	0-6	mg/l	6 ±0.01	6 ±0.03

Note: statistical significance of differences with control indicators: * - $p < 0.05$

IRI is the ratio of the number of CD4+ T-helpers and CD8+ T-suppressors in peripheral blood (CD4+/CD8+). According to the results of a comparative immunological examination in patients with postoperative inflammation, there was a statistically significant increase in the mean values of the IRI, the complement component C3, IgA, IgG, and ANA in blood serum relative to the control parameters ($p<0.05$) even before surgery. After surgery on days 1-3, these indicators still remain elevated. An increase in IRI is noted against the background of a decrease in CD8+T-killers and an increase in CD4+ T-helpers which can contribute to the strengthening of autoimmune processes in turn. The complement component C3 is also a protein of the acute phase of inflammation and participates in the activation of the complement system both in the classical (acquired immunity) and in an alternative way (innate immunity). IgA are glycoproteins that are synthesized mainly by plasma cells of the mucous membranes in response to local exposure to antigens and are an important factor in the local

protection of the mucous membranes. They enhance the phagocytosis of antigens by activating complement via an alternative pathway. IgG is the main type of blood and intercellular fluid antibodies; therefore, it participates in the control of infection throughout the body by binding to a variety of pathogens. The level of IgG in the blood is considered an indicator of the activation of an individual's immune system against a certain pathogen. IgM is normally first secreted during the humoral response of the immune system to the primary contact of the body with the antigen and are indicators of an acute infectious process. ANA is a family of autoantibodies that bind to nucleic acids and their associated proteins. ANA is detected in more than 90% of patients with diffuse connective tissue diseases, therefore this immunological test was of great diagnostic importance in the etiological diagnosis of uveitic pathology. CRP is a protein in the acute phase of inflammation. Neither before, nor after the operation average values of IgM and CRP were elevated in these patients which was an

immuno-biochemical confirmation of the absence of an acute process and clinical activity of systemic inflammation in the operated patients. The results obtained indicate that even against the background of clinical well-being in patients with UC, deviations of some systemic immunological parameters (CD4+, CD8+, IgG, IgA, complement component C3, ANA) are possible. These disorders are mainly indicators of unfavorable autoimmune sensitization, and as the studies show they can serve as harbingers of the development of undesirable immune responses and an indication for strengthening preoperative preventive anti-inflammatory training with an emphasis on immunosuppressive treatment.

Many sources of modern ophthalmological literature agree with our results of a more frequent spread of cataracts in anterior uveitis (59.6%) (Choi et al., 2022; Balta et al., 2018). Also in the literature, many authors point to the multifactorial etiological structure of the pathogenesis of cataracts in uveitis: the effect of autoimmune inflammation increased permeability of the hemato-ophthalmic barrier, the role of free radical oxidation as well as corticosteroids used for a long time in the treatment of uveitis (Chiu et al., 2017; Macarie and Macarie, 2018). In our study, the incidence of uveitis in autoimmune diseases was higher in patients taking systemic steroids (54.1%) (Drozdova, 2012). Many leading ophthalmic surgeons of the world agree with the conjugation of uveitic cataract surgery with certain technical difficulties. Thus, in this study during the phacoemulsification of cataracts, additional surgical measures were applied to achieve a highly functional result: the elimination of synechiae (75.7%), the use of iris retractors (22.9%), iridoplasty (9.5%). But additional manipulations during surgery, along with anatomical and physiological features of the UC are a risk of postoperative inflammation with the development of early and late postoperative complications such as pupil overgrowth, iris bombage, glaucoma, vitreous fibrosis, retinal detachment and eye subatropy (Sen et al., 2016; Llop and Papaliadis, 2018).

In this study, the most frequent complication in the early and late postoperative period was postoperative inflammation of varying severity (37.8%). Also, UC is often combined with the

pathology of the posterior segment of the eye: vitreous opacity, proliferative vitreoretinopathy with the formation of traction retinal detachment, CME, detachment of the ciliary body and hypotension of the eye in connection with which vitreoretinal interventions are often required. In this study, CME that occurred in 10,8% of surgical cases was successfully cured by anti-inflammatory therapy (Juthani et al., 2017).

But it is necessary to note a certain aspect of this study, the novelty of which is the main purpose of its conduct. In all patients with UC, the operation was performed in the remission stage of uveitis. At the same time in patients with the development of inflammation in the postoperative period even before surgery statistically significant deviations of the average values of some immunological parameters (CD4+, CD8+, IgG, IgA, complement component C3, ANA) were noted with normal indicators of the activity of the inflammatory process (CRP, IgM).

Thus, cataract surgery for uveitis requires careful monitoring of the activity of the inflammatory process before and after surgery. Despite the stage of uveitis remission, depending on the indicators of the immunological survey of a patient with UC before surgery, it is possible to outline a certain algorithm of preoperative immunosuppressive treatment to minimize postoperative inflammation risk.

CONCLUSIONS

1. Cataract development was most often noted in anterior uveitis (59.6%).
2. The mutual influence of the inflammatory process and the systemic use of steroids in the complex therapy of uveitis contributed to a more frequent spread of uveitic cataracts in autoimmune diseases (54.1%).
3. Patients with uveitic cataracts are at high risk of developing postoperative inflammation in the early and late postoperative periods. Immunological surveys in the preoperative period during cataract surgery in patients with uveitis can serve as an additional method for predicting postoperative inflammation risk.

STATEMENTS

The author declares no conflict of interest. This article and the research underlying it would not have been possible without the exceptional support of the staff of the National Center of Ophthalmology named after Academician Zarifa Aliyeva. I accept the terms of the publication.

REFERENCES

- Agayeva R.B., Gasimov E.M., Rustamova H.M.** (2020) Epidemiological features of the incidence of cataract in Azerbaijan among the adult population. *Azerbaijan Ophthalmology Journal*, **3(34)**: 46-53 (in Russian).
- Aliyeva Z.A., Shulpina N.B.** (2011) Vision organ tuberculosis. Baku: Sharg-Garb, 224 p. (in Russian).
- Balta O., Sungur G., Acar M.A., Kosker M., Yakin M., Ornek F.** (2018) Long-term results of cataract surgery in patients with anterior uveitis. *Int J Ophthalmol.*, **38(4)**:1399-1407; doi: 10.1007/s10792-017-0598-z.
- Buratto L.** (1998) Phacoemulsification. SLACK Inc., 544 pp.
- Chiu H., Dang H., Cheung C., Khosla D., Arjmand P. et al.** (2017) Ten-year retrospective review of outcomes following phacoemulsification with intraocular lens implantation in patients with pre-existing uveitis. *Can. J. Ophthalmol.*, **52(2)**:175-180; doi: 10.1016/j.jcjo.2016.10.007.
- Choi J.A., Ju H.H., Lee J., Kim J.E., Paik S.Y., Skiba N.P., Rao P.V.** (2022) Increased complement-associated inflammation in cytomegalovirus-positive hypertensive anterior uveitis patients based on the aqueous humor proteomics analysis. *J. Clin. Med.*, **11(9)**:2337; doi: 10.3390/jcm11092337.
- Curnow S.J., Scheel-Toellner D., Jenkinson W., Raza K., Durrani O.M. et al.** (2004) Inhibition of T cell apoptosis in the aqueous humor of patients with uveitis by IL-6/soluble IL-6 receptor trans-signaling. *J. Immunol.*, **173(8)**:5290-5297; doi: 10.4049/jimmunol.173.8.5290.
- Drozdova E.A.** (2012) Immunosuppressive therapy of non-infectious uveitis and retinovasculitis. *Ophthalmology*, **9(2)**: 58-61 (in Russian).
- Gasimov E.M., Slepova O.S., Majidova S.R.** (2023) The role of detection of antinuclear antibodies in the diagnosis of autoimmune uveitis. Materials of the International Scientific Conference on Current Problems of Ophthalmology Dedicated to the Anniversary of Academician Zarifa Aliyeva: 115-117 (in Russian).
- Juthani V.V., Clearfield E., Chuck R.S.** (2017) Non-steroidal anti-inflammatory drugs versus corticosteroids for controlling inflammation after uncomplicated cataract surgery. *Cochrane Database Syst. Rev.*, **7(7)**: CD010516; doi: 10.1002/14651858.
- Llop S.M., Papaliodis G.N.** (2018) Cataract surgery complications in uveitis patients: A review article. *Semin Ophthalmol.*, **33(1)**: 64-69; doi: 10.1080/08820538.2017.1353815.
- Macarie S.S., Macarie D.M.** (2018) Phacoemulsification in adult patients with post-uveitis complicated cataract. *Rom. J. Ophthalmol.*, **62(2)**:135-137.
- Minkus C.L., Pistilli M., Dreger K.A., Fitzgerald T.D., Payal A.R. et al.** (2021) Systemic immunosuppressive therapy for eye diseases (SITE) cohort study research group. Risk of cataract in intermediate uveitis. *Am. J. Ophthalmol.*, **229**:200-209; doi: 10.1016/j.ajo.2021.02.032.
- Sen H.N., Abreu F.M., Louis T.A., Sugar E.A., Altaweel M.M. et al.** (2016) Multicenter uveitis steroid treatment (MUST) trial and follow-up study research group. Cataract surgery outcomes in uveitis: The multicenter uveitis steroid treatment trial. *Ophthalmology*, **123(1)**: 183-190; doi: 10.1016/j.ophtha.2015.09.022
- Shilovskikh O.V., Safonova O.V.** (2015) Uveitic cataract phacoemulsification with synechiotomy, posterior capsulorhexis, partial vitrectomy and original IOL implantation: long-term results. Bulletin of the Orenburg State University, **12 (187)**: 313-317 (in Russian).

***Citation:** Majidova Sabina (2023) Clinical and immunological features of cataract surgery in uveitis. *Journ. Life Sci. & Biomed.*, **78(1)**: 93-102

S.R.Majidova

S. Majidova: <https://orcid.org/0009-0001-5829-5759>