

Hypoxia-induced apoptosis of eyeball cells

Pasha Musayev-Galbinur¹, Yuliya Markitantova², Khanagha Babayev³, Sevinj Akberova^{4*}

¹Department of Ophthalmology, Azerbaijan Medical University, 2 M.Mirgasimov Str., AZ1022, Baku, Azerbaijan

²Institute of Developmental Biology named after N.K.Koltsshva, Russian Academy of Sciences, 26 Vavilova Str., 119334, Moscow, Russia

³Academician Abdulla Garayev Institute of Physiology, Ministry of Science and Education of the Republic of Azerbaijan, 2 Sharifzade Str., AZ1100, Baku, Azerbaijan

⁴Medical Clinic "MedKvadrat", 74 korp., 1 Kashirskoe Shosse, 115409, Moscow, Russia

*For correspondence: seving_@mail.ru

Received: February 15, 2023; Received in revised form: March 13, 2023; Accepted: March 30, 2023

We aimed to study the effect of acute hypoxic hypoxia and acute hypobaric hypoxia on eye tissue cells in adult rats. In each experiment with acute hypoxic hypoxia and acute hypobaric hypoxia, 12 (4 animals in each group, 24 rats in total) male Wistar rats (24 eyes in each experiment, 48 eyes in total) were used, divided into 3 groups: Group I - intact control, group II - 1 hour after hypoxia, group III - 3 hours after hypoxia. Identification of apoptotic cells in the tissues of the eye was performed by the TUNEL method on frozen eye sections with additional staining with nuclear fluorescent dye Hoechst 33342. The localization and intensity of fluorescent emission in damaged cells were analyzed under a fluorescent microscope using Image J software. When exposed to acute hypobaric hypoxia, selective primary apoptotic damage to the cells of the conjunctiva and the anterior epithelium of the cornea was found. But under conditions of simulated acute hypoxic hypoxia, apoptotic damage to the conjunctiva, corneal epithelium, choroid and photoreceptor layer of the retina was observed. Cells of different parts of the eye of adult rats are characterized by different sensitivity to apoptotic damage in acute hypoxia modeled in this study.

Keywords: Acute hypoxia, eye, conjunctiva, apoptosis

INTRODUCTION

Hypoxia plays an important role in the pathogenesis of dry eye syndrome, hereditary, dystrophic, ischemic, inflammatory, infectious and other diseases of the eyeball (Blasiak et al., 2014; Chao et al., 2013). During hypoxia, the conditions for maintaining normal metabolism and functioning of cells are violated, which can lead to their death. In many diseases of the human eye: glaucoma, cataract, diabetic retinopathy, retinal dystrophy, cell death is observed by the apoptosis mechanism (Ermilov and Maxonin, 2011; Slepova et al., 2012; Servellati et al., 2014; Ishibashi, 2012; Kaur et al., 2008; Ozaki et al., 2012; Saccà and Izzotti, 2008).

Experimental studies of the effect of hypoxia on apoptotic cell death were carried out on individual tissues of the eye, under in vitro conditions. Thus, in cultures of purified rat retinal ganglion cells, as well as corneal keratocytes, it has been shown that hypoxia induces apoptosis in these cells (Unterlauff et al., 2014; Yang et al., 2013).

We aimed to study the effect of acute hypoxic hypoxia and acute hypobaric hypoxia on the tissues of the eye of adult rats in various experimental models of hypoxia *in vivo*.

MATERIALS AND METHODS

The work was performed on 24 mature male

Wistar rats, aged 3-4 months. In each experiment, 12 rats (24 eyes) were used: group I - intact control (4 rats); Group II - after hypoxia in 1 hour (4 rats); Group III (4 rats) - after hypoxia after 3 hours. Control animals (4 rats) were not exposed to hypoxia. In the experimental groups, the eyes of the animals were examined 1 and 3 hours after hypoxia.

Experimental modeling of acute hypoxia. In the experimental group, the animals were subjected to a single exposure to acute hypoxic hypoxia. Hypoxia was achieved by replacing the air with nitrogen from a hermetic chamber with a volume of 0.12 m³, where experimental animals were placed, for 7-10 minutes, until convulsions occurred. The eyes of animals from the experimental group were analyzed three hours after hypoxic exposure. The control group of animals not subjected to hypoxia was kept at room temperature. Animals from both groups were taken out of the experiment by anesthesia in ether, after which the eyes of rats from both groups were enucleated, their histological examination was carried out, and the distribution of apoptotic cells in the tissues of the eye was also analyzed.

Experimental modeling of acute hypobaric hypoxia. In the experimental group, the animals were subjected to a single action of acute hypoxia, which was achieved by pumping out air for 1 min until the pressure chamber reached a pressure of 180 mm Hg. Under these conditions, the rats were kept for 3 min before the onset of convulsions. The results of the experiments were recorded 3 hours after hypoxia. Animals were withdrawn from the experiment by intraperitoneal injection of chloral hydrate (Riedel-de-Haen, Germany) followed by euthanasia with ether vapor until the animals recovered from anesthesia. The eyes of experimental and control rats were enucleated.

The experiments were carried out in accordance with the Rules for the Keeping and Use of Laboratory Animals and the provisions of the European Convention for the Protection of Animals Used for Experimental and Other Scientific Purposes. To detect apoptosis in eye tissues, the traditional TUNEL method (Terminal deoxynucleotidyl transferase – mediated deoxyuridine triphosphate (UTP) – nick end – labeling) was used using the Dead End

Fluorometric TUNEL System reagent kit (Promega Corporation, USA).

Histological examination. The material for light microscopy was processed by conventional histological methods. For histological analysis, the eyes of rats were fixed in Bouin's fluid, embedded in paraffin, and used for sectioning according to the standard protocol (Sennlaub et al., 2002). Sections 7 µm thick were glued onto adhesive-coated slides (Silane-Prep Slides, Sigma) and after deparaffinization, the sections were stained with hematoxylin and eosin. The preparations were examined under a Leica light microscope (Germany).

Material preparation and DNA labeling reaction according to the TUNEL method. The eyes were fixed in 4% neutral formalin prepared in 0.1 M phosphate buffer (pH 7.4) for 4 h. Then the samples were washed in phosphate buffer, three changes of phosphate buffer with 5% sucrose, three changes of phosphate buffer with 10% sucrose, then 20% sucrose (in each solution for 15 minutes) and left overnight in phosphate buffer with 20% sucrose at 4°C. After freezing the eyes in a special medium (Tissue-Tec OST, Leica, Germany), using a cryostat (Leica M1900, Germany), transverse sections of the eyeball were obtained and selected for analysis. The slice thickness was 12 µm.

Fragmented DNA was labeled by the TUNEL method according to the manufacturer's protocol. Before carrying out the enzymatic reaction, the sections were washed in 0.1 M PBS, fixed in 4% paraformaldehyde for 5 minutes, then washed from the fixative in 0.1 M PBS three times for 5 minutes. The reaction was carried out for an hour at a temperature of 37°C, then the reaction was stopped by washing the sections in a 2x SSC solution. To confirm the specificity of the reaction, a standard control reaction was also performed in the absence of the rTdT enzyme. Cell nuclei were stained with Hoechst 33342 diluted in 0.1 M PBS (1:1000, Leica, Germany) for two minutes. After staining, the sections were washed in several shifts with 0.1 M PBS, for 15 minutes in each solution, and placed in a special medium for preparations with a fluorescent label - Vectashield (Vector, USA).

Microscopy and computer image analysis. The localization of the fluorescent glow and its

intensity in the cells of the eye tissues were analyzed using a Leica DM RXA2 fluorescent microscope (Germany), with the image transferred to a computer console equipped with the Leica for Windows program. No fluorescent emission was observed in the control preparations. The images were processed using the Image J computer program.

RESULTS AND DISCUSSION

Viewing the selected transverse sections to identify apoptotic cells in the tissues of the eye clearly showed that under conditions of acute hypoxic hypoxia, the primary lesion occurs in all layers of the conjunctiva, in the anterior corneal epithelium, in the own choroid, and also in the photoreceptor layer of the retina (Fig. e, f; g, h; i, j). In dynamics, there is an increase in cell damage by apoptosis, i.e. 3 hours after hypoxia, a more intense glow of damaged cells is noted (Fig. i, j) than after 1 hour (Fig. e, f.)

It has been shown that the simulated conditions of hypoxia cause a pronounced reaction of the cells of the conjunctiva, in the anterior epithelium of the cornea and in the photoreceptor layer of the retina, which leads to apoptotic death of a significant part of them. Staining with DNA dye Hoechst 33342 confirms the localization of apoptosis in the cell nuclei. In other tissues of the eye - the lens, iris, ciliary body - apoptotic cells were absent in this type of lesion. The same picture was observed in all studied eyes.

In the studied tissues of the eye of animals from the control group (without exposure to hypoxia), only single apoptotic cells were found in the conjunctiva and in the anterior epithelium of the cornea. In the control group of animals, there were no apoptotic cells in the lens, iris, ciliary body, and retina (Fig. c, d). In the control preparations, which served as a negative control to confirm the specificity of the reaction in the experiment, no labeled cells were observed (Fig. a,b).

Thus, during acute hypoxic hypoxia under the conditions modeled in this work, causes an intense process of DNA fragmentation and apoptosis in the cells of the tissues of the anterior surface of the eye, the own choroid, and the photoreceptor layer of the retina.

In acute hypobaric hypoxia, we found the same type, selective localization of cells with damaged DNA in the anterior corneal epithelium and in the conjunctiva. These cells were subjected to apoptosis, which was confirmed by staining eye sections with the fluorescent DNA-binding dye Hoechst 33342. In dynamics, there is an increase in cell damage by apoptosis, i.e., 3 hours after hypoxia, a more intense glow of damaged cells is noted than after 1 hour.

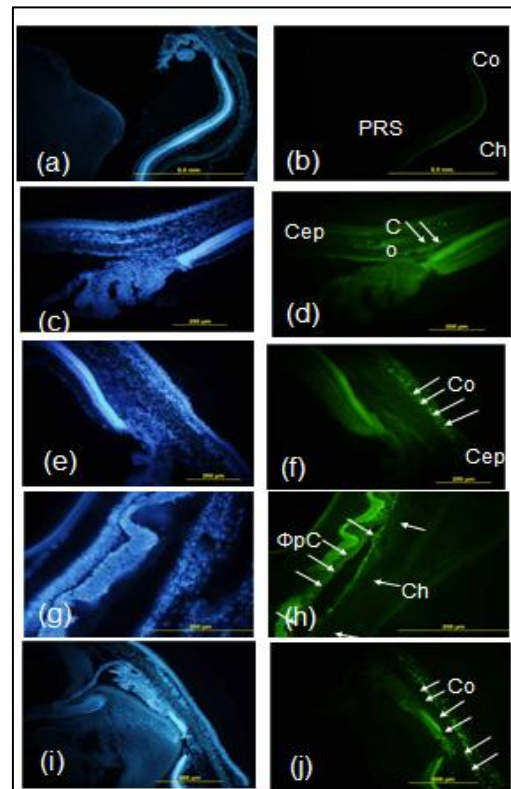


Fig. Apoptotic cells in rat eye tissues in normal conditions and after experimental hypoxia. Arrows show TUNEL-positive cells in the conjunctiva and corneal epithelium. Nuclei were stained with Hoechst 33342. Intact negative control: (a, b); intact control conjunctiva (c, d); fixation after a single hypoxia: after 1 hour the conjunctiva (e, f), fixation after a single hypoxia after 1 hour the retina (g, h); fixation after 3 hours, conjunctiva (i, j). Cep – corneal epithelium; Co – conjunctiva; PRS, photoreceptor layer of the retina; Co – choroid (choroid). Scale: 200 (a–f), 500 μ m (g–h).

In the studied tissues of the eye of animals from the control group (without exposure to hypoxia), only single apoptotic cells were found. In the lens, iris, ciliary body, choroid and retina,

apoptotic cells were absent, both in the experimental and control groups. In the control preparations, which served as a negative control to confirm the specificity of the reaction in the experiment, no labeled cells were observed.

Acute hypoxia under the conditions modeled in this work causes an intense process of DNA fragmentation and apoptosis in the cells of the tissues of the anterior surface of the eye - the conjunctiva and the anterior corneal epithelium. Unlike acute hypobaric hypoxia, hypoxic hypoxia also causes apoptosis of the own choroid and retina. Acute hypoxia in the conditions of these experiments in the lens, iris, ciliary body does not occur apoptotic changes in cells, i.e. they remain undamaged. Thus, the cells of different parts of the eye of adult rats are characterized by different sensitivity to hypoxia modeled in this study.

The results obtained by us open up further prospects for experimental studies of the mechanisms of eye tissue pathology under conditions of hypoxia of various genesis. Given the role of apoptosis in the pathogenesis of pathologies of the surface of the eye and retina, it is possible to study the fundamental mechanisms of the effectiveness of certain drugs in the treatment of eye diseases using these experimental models.

CONCLUSIONS

1. Acute hypobaric hypoxia causes an intense process of DNA fragmentation and apoptosis only in the cells of the tissues of the anterior surface of the eye - the conjunctiva and the anterior epithelium of the cornea.
2. Acute hypoxic hypoxia causes an intense process of DNA fragmentation and apoptosis in the cells of the tissues of the anterior surface of the eye - the conjunctiva and the anterior epithelium of the cornea, choroid and retina.

REFERENCES

Blasiak J., Petrovski G., Veréb Z., Facskó A., Kaarniranta K. (2014) Oxidative stress, hypoxia and autophagy in the neovascular processes of age-related macular degeneration.

- Biomed. Res. Int.*, **2014**: Article ID 768026.
- Cervellati F., Cervellati C., Romani A., Cremonini E., Sticozzi C., Belmonte G., Pessina F., Valacchi G.** (2014) Hypoxia induces cell damage via oxidative stress in retinal epithelial cells. *Free Radic. Res.*, **48(3)**: 303-312.
- Chao H.M., Chuang M.J., Liu J.H., Liu X.Q., Ho L.K., Pan W.H., Zhang X.M., Liu C.M., Tsai S.K., Kong C.W., Lee S.D., Chen M.M., Chao F.P.** (2013) Baicalein protects against retinal ischemia by antioxidation, antiapoptosis, downregulation of HIF-1 α , VEGF, and MMP-9 and upregulation of HO-1. *J. Ocul. Pharmacol. Ther.*, **29(6)**: 539-549.
- Ermilov V.V., Makhonina O.V.** (2011) Correlation of metabolic disorders in eye structures with aging, apoptosis and age-dependent diseases. *Vestnik VolgGMU*, **37**: 67-69 (in Russian).
- Ishibashi T.** (2012) Comprehensive strategy for retinal neuroprotection. Challenging the clinical application. *Nihon Ganka Gakkai Zasshi*, **116(3)**: 165-198.
- Kaur C., Foulds W.S., Ling E.A.** (2008) Hypoxia-ischemia and retinal ganglion cell damage. *Clinic. Ophthalmol.*, **2(4)**: 879-889.
- Ozaki T., Nakazawa M., Yamashita T., Sorimachi H., Hata S., Tomita H., Isago H., Baba A., Ishiguro S.I.** (2012) Intravitreal injection or topical eye-drop application of a μ -calpain C2L domain peptide protects against photoreceptor cell death in Royal College of Surgeons' rats, a model of retinitis pigmentosa. *Biochem. Biophys. Acta.*, **1822(11)**: 1783-1795.
- Saccà S.C., Izzotti A.** (2008) Oxidative stress and glaucoma: injury in the anterior segment of the eye. *Prog. Brain Res.*, **173**: 385-407.
- Sennlaub F., Courtois Y., Goureau O.** (2002) Inducible nitric oxide synthase mediates retinal apoptosis in ischemic proliferative retinopathy. *The J. of Neuroscience*, **22(10)**: 3987-3993.
- Slepova O.S., Frolov M.A., Morozova N.S., Lovpache J.N.** (2012) Markers of Fas-mediated apoptosis in primary open-angle glaucoma and the possibility of their pharmacological correction. *Vestn. Ophthalmol.*, **128(4)**: 27-31 (in Russian).
- Unterlauff J.D., Claudepierre T.M., Müller K., Yafai Y., Wiedemann P., Reichenbach A.**

Eichler W. (2014) Enhanced survival of retinal ganglion cells is mediated by Müller glial cell-derived PEDF. *Exp. Eye. Res.*, **127**: 206-214.
Yang X., Wei A., Liu Y., He G., Zhou Z., Yu Z.

(2013) IGF-1 protects retinal ganglion cells from hypoxia-induced apoptosis by activating the Erk-1/2 and Act pathways. *Mol. Vis.*, **19**: 1901-1912.

Citation:* Musaev-Galbinur Pasha, Markitantova Yulia, Babayev Khanagha, Akberova Sevinj (2023) Hypoxia-induced apoptosis of eyeball cells. *Journ. Life Sci. & Biomed.*, **78(1): 38-41

P.Galbinur-Musayev ORCHID: <https://orcid.org/0000-0003-7799>

Yu. Markitantova ORCHID: <https://orcid.org/0000-0003-2518-0610>

Kh. Babayev ORCHID: <https://orcid.org/0000-0003-3919-6277>

S. Akberova ORCHID: <https://orcid.org/0009-0008-0264-3292>