

# Oral Myofibromatosis: Report of an Unusual Case and Literature Review

Dominic Innes-Taylor<sup>1\*</sup>, Safa Helmy<sup>1</sup> and Elizabeth Gruber<sup>1</sup>

<sup>1</sup>Northampton General Hospital. Northampton. NN1 5BD. United Kingdom.

**\*Corresponding Author:** Dr. Dominic Innes-Taylor BDS MFDS RCS(Ed) (DCT), Northampton General Hospital. Northampton. NN1 5BD. United Kingdom.

DOI: <https://doi.org/10.58624/SVOADE.2023.04.0131>

**Received:** April 09, 2023 **Published:** May 02, 2023

## Abstract

Myofibromatosis is a rare condition involving multiple soft tissue tumours. It is believed to be a disease of infancy, presenting only in older individuals as solitary lesions (myofibromas). We present a case of oral myofibromatosis in an adolescent with sudden facial swelling, demonstrating the misleading nomenclature of the condition. Whilst the family history was unremarkable, extensive investigation had failed to diagnose the patient's congenital genetic syndrome but had proposed a mutation in the PTEN gene as a cause for his ongoing myofibromatosis. Greater distinction is needed between myofibromatosis and myofibromas to draw reliable conclusions from the literature. Only one case clearly detailed myofibromatosis in an adult. Further information is also needed on medical and family histories to gain a better understanding of the disease's aetiology. Only one case reported an autosomal dominant pattern of inheritance.

**Keywords:** Myofibromatosis; myofibroma; genetic syndrome.

## Introduction

Being less familiar with rare conditions such as myofibromatosis can lead to confusion and delays, whether for our maxillofacial colleagues in emergency departments or practice. Early identification of an active oral fibroma can prevent panic or overtreatment. A lack of clarity in the literature regarding its presentation would suggest further case reports are required. We present such a case of a 15-year-old male with an unknown syndrome presenting to A&E with a one-week history of sudden upper lip and gingivae swelling.

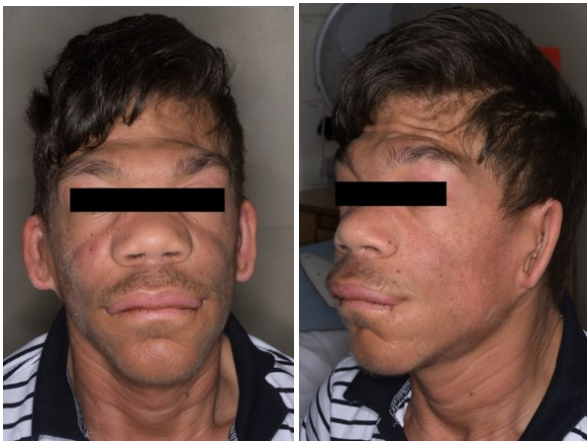## Case Report

On presentation, no trauma, insect bite, new food/medication or change in behaviour was reported and the patient had not experienced a situation like this before. The patient was born with various subcutaneous lesions at 34+6 week and further myofibromas had developed throughout his body ever since. Several cycles of chemotherapy had attempted to stabilize their growth. Extensive genetic investigation had failed to diagnose the patient's syndrome, other than identify a mutation in the PTEN gene, which was proposed as a cause for his adolescent myofibromatosis. No family history of congenital or metabolic disorders was reported. No allergies nor regular medications were noted.

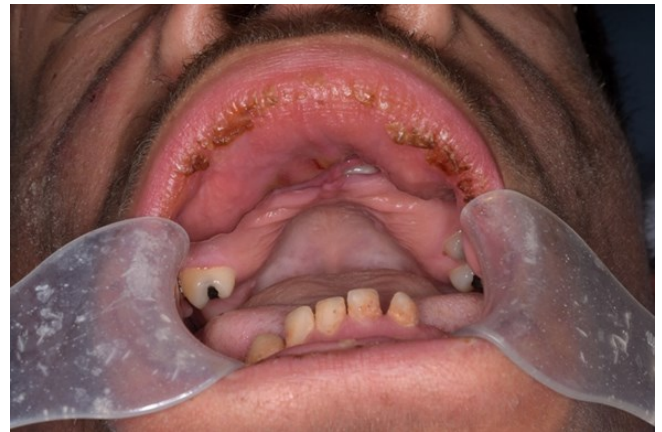On examination, thickening of the bridge of the nose, frontal bossing and bilateral ptosis were visible. The upper lip was clearly enlarged and of a beefy texture (figure 1). There was no lymphadenopathy and no paraesthesia. Intraorally, the few teeth present were sound and non-mobile. His upper incisors appeared nearly completely embedded due to the swelling (figure 2). Further findings included fragile and telangiectatic skin, reduced joint mobility and clawing and overgrowth of the hands and feet (figure 3). Historic diagnoses included astigmatism, bilateral conductive hearing loss, factor XII deficiency, pansynostosis and infantile myofibromatosis.

Possible causes attributed to the swelling included allergic reaction, oral facial granulomatosis, and resurgence of the patient's myofibromatosis. A dental abscess was ruled out. An OPG (figure 3) revealed multiple unerupted, ectopic teeth with several large maxillary and mandibular radiolucencies. Facial bones views were also taken, depicting the 'copper beaten' appearance of the patient's skull (figure 5). No fractures were noted. An updated MRI showed no conclusive evidence of new myofibromas, however. Bloods were in normal range except for an elevated CRP of 36mg/L a total bilirubin of 23umol/L and a low creatine of 46umol/L.

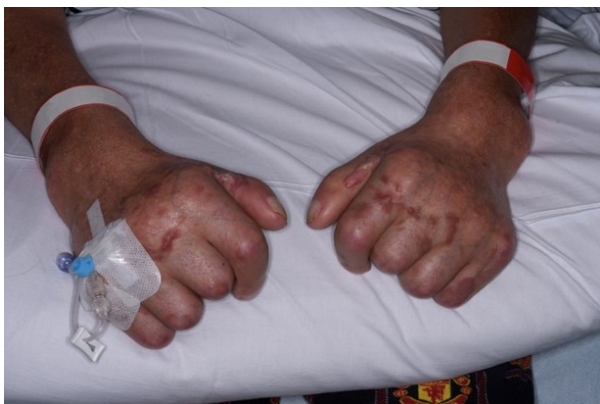The patient's painkillers were optimised to an adult dose and a trial of antihistamines was initiated. The patient was admitted for two nights of observation and started on IV metronidazole and ceftriaxone. Following some reduction in the swelling and pain, the patient was discharged with oral antibiotics. A marked improvement was noted at the 3-month review and no further appointments required.



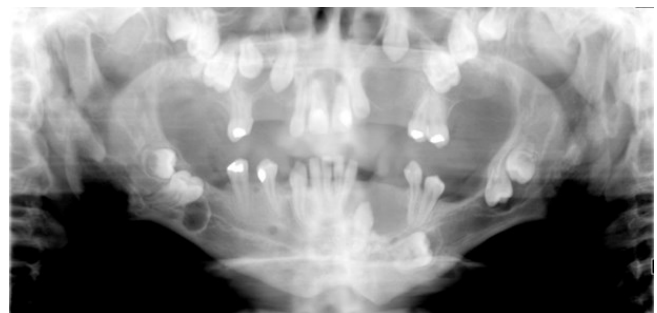
**Figure 1:** Frontal and oblique profiles of patient.



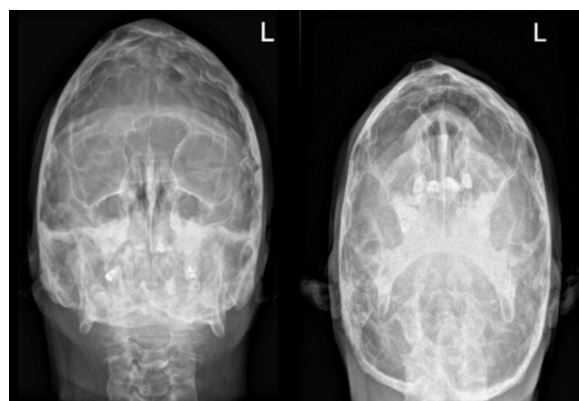
**Figure 2:** Intraoral view with embedded upper incisor.



**Figure 3:** Clawing and overgrowth of the patient's hands.



**Figure 4:** OPG demonstrating abnormal dentition.



**Figure 5:** Copper beaten appearance on OM views.

## Literature Review

A search of the English literature using the keywords 'myofibromatosis', 'oral', 'jaw' and 'mouth' returned 63 results. The inclusion criteria specified papers available through the Healthcare Library of Northern Ireland search engine. Those not involving the oral cavity or only detailing myofibromas were excluded, leaving five publications. Two presented 24 and 79 new cases but neither specified which were myofibromas and which were myofibromatosis.<sup>1,2</sup> Medical/family histories were also not made clear. The three remaining cases from 2002-2012 affected the gingiva, mandible and palate with one patient being of 14 years.<sup>3-5</sup> All were surgically excised with unremarkable medical histories. Only one case mentioned genetic disposition where an autosomal dominant pattern of myofibromas across three generations was noted.

## Discussion

One third of myofibromas arise within the head and neck, occurring anywhere within the oral cavity.<sup>6</sup> There is little consensus on clinical presentation, but most affect the mandible.<sup>1</sup> They are benign, can regress spontaneously but also display aggressive behaviour. Ulceration and tooth displacement is not uncommon. Dependent on the location of the tumour, facial paraesthesia, muscle entrapment and obstruction of the airway are possible developments.<sup>2,7</sup> Diagnosis is determined histologically but differentiation of myofibromatosis from malignant tumours can be difficult.<sup>2,6,8</sup> Dependant on the size and extent of the disease, surgical excision is often the chosen treatment. Recurrence is uncommon, at approximately 18% in the oral cavity.<sup>2</sup> Chemotherapy or observation till growth completion are also commonly opted for.

## Conclusion

When more than one lesion is present, the condition is commonly referred to as infantile myofibromatosis. This presentation of myofibromatosis could be linked to the patient's undiagnosed genetic condition but could equally be part of an unappreciated adult manifestation of the disease. Raising awareness of the misleading nomenclature can only be achieved by adding further case reports to the literature. Review of the literature produced only one reliable case of non-infantile myofibromatosis. More are needed for future systematic reviews, with particular attention to pattern-recognition in the medical and familial histories of such cases. Greater detail is needed in case reports, especially in the distinction between myofibromas and myofibromatosis. Clinicians should be wary of the potential of the latter to present and cause sudden swellings in older demographics too.

## Conflict of Interest

The authors declare no conflict of interest.

## Patient Consent

Obtained.

## Funding

None.

## References

1. Smith MH, Reith JD, Cohen DM, Islam NM, Sibille KT, Bhattacharyya I. An update on myofibromas and myofibromatosis affecting the oral regions with report of 24 new cases. *Oral Surg Oral Med Oral Pathol Oral Radiol*. 2017 Jul;124(1):62-75
2. Foss RD, Ellis GL. Myofibromas and myofibromatosis of the oral region: A clinicopathologic analysis of 79 cases. *Oral Surg Oral Med Oral Pathol Oral Radiol Endod*. 2000 Jan;89(1):57-65
3. Corson MA, Reed M, Soames JV, Seymour RA. Oral myofibromatosis: an unusual cause of gingival overgrowth. *J Clin Periodontol*. 2002 Nov;29(11):1048-50
4. Hazarey J, Hazare S, Moghe G. Unusually aggressive myofibromatosis in a neonate. *Journal of Neonatal Surgery*. 2012 Apr;1(2).
5. Flaitz, C., Dishop, M., Metry, D., Friedman, E., Chintagumpala, M. and Hicks, J., 2005. Autosomal Dominant Multicentric Myofibromatosis Presenting as a Palatal Mass. *Oral Surgery, Oral Medicine, Oral Pathology, Oral Radiology and Endodontology*, 2(100), p.187.
6. Beck JC, Devaney KO, Weatherly RA, Koopmann CF, Lesperance MM. Pediatric Myofibromatosis of the Head and Neck. *Arch Otolaryngol Head Neck Surg*. 1999;125(1):39-44

7. Scheper MA, Difabio VE, Sauk JJ, Nikitakis NG. Myofibromatosis: a case report with a unique clinical presentation. *Oral Surg Oral Med Oral Pathol Oral Radiol Endod.* 2005 Mar;99(3):325-30
8. Robinson M, Hunter K, Pemberton M, Sloan P. *Soames' and Southam's oral pathology.* 5th ed. p22. Oxford University Press. 2018.

**Citation:** Innes-Taylor D, Helmy S, Gruber E. Oral Myofibromatosis: Report of an Unusual Case and Literature Review. *SVOA Dentistry* 2023, 4:3, 84-87.

**Copyright:** © 2023 All rights reserved by Innes-Taylor D., et al. This is an open access article distributed under the Creative Commons Attribution License, which permits unrestricted use, distribution, and reproduction in any medium, provided the original work is properly cited.