

Rare Case of Metastatic Nodular Adrenal Ganglioneuroblastoma to Bone in a Young Female at Ibn Rochd University Hospital of Casablanca in Morocco

Ismael Coulibaly¹,
Hanane Rida¹,
Xavier Sia¹,
Tarik Chékrine¹,
Hassan Jouhadi¹,
Nezha Tawfiq¹,
Souha Sahraoui¹,
Abdelatif Bénider¹,
Nadia Benchakroun¹,
Zineb Bouchbika¹

¹Mohamed VI Center for the Treatment of Cancers, CHU Ibn Rochd, hospital districts, 20360 Casablanca, Morocco

Sara Moukhlis²,
Farida Marnissi²,

²Central Laboratory of Pathological Anatomy, CHU Ibn Rochd, 20503 Casablanca, Morocco

Mohammed Dakir³,

³Urology Department, CHU Ibn Rochd, Casablanca, Morocco

Abstract:- Ganglioneuroblastoma is a tumor belonging to the family of neuroblastic tumours. Those are tumors of the sympathetic nervous system. Ganglioneuroblastoma is very rare in adults. We report here a case of nodular ganglioneuroblastoma metastatic to the bone in a 31-year-old woman who consulted for pain in the right flank with, on the CT scan, a voluminous and heterogeneous tissue formation of lobulated contours. She underwent an adrenalectomy. A postoperative radiological assessment showed osteolytic lesions of the neck, left femoral metaphysis and bilateral iliac wings. The patient was put on palliative chemotherapy. She is currently under surveillance at 16 months of survival without new events. Ganglioneuroblastomas are considered to have intermediate metastatic potential.

Keywords: Ganglioneuroblastoma, Nodular, Metastatic, Bone, Female.

I. INTRODUCTION

Ganglioneuroblastoma is a tumor belonging to the large family of neuroblastic tumors with two other entities including neuroblastoma and ganglioneuroma [1]. These are tumors of the sympathetic nervous system, common in children and rare in adults. The most benign tumor is the ganglioneuroma, which is composed of gangliocytes and mature stroma. Ganglioneuroblastoma is composed of both mature gangliocytes and immature neuroblasts and has an

intermediate malignant potential. Neuroblastoma is the most immature, undifferentiated and malignant tumor of the three [2]. Ganglioneuroblastoma is very rare in adults. It occurs preferentially on 03 sites: the retro-peritoneal, the adrenal gland and the posterior mediastinum. The therapeutic indications for ganglioneuroblastoma are not well codified due to the rarity of this pathology. We report here a case of metastatic nodular ganglioneuroblastoma to bone in a 31-year-old woman.

II. CLINICAL CASE

Our case is that of a young patient aged 31, married and mother of 3 children. She has no particular personal history or notion of cancer in the family. She consulted in September 2019 for an exaggeration of right flank pain evolving for 2 months. The admission examination found a patient in good general condition with a WHO Performans Status of 1 and a painful mass on palpation of the right flank with no other associated signs. We performed an abdominopelvic CT scan without and with injection of contrast product which objectified a voluminous formation of tissue density and heterogeneous lobulated contours, visible in the right inter hepatorenal evoking an adrenal origin (Fig 1 and 2). It measured 6.6 cm in height by 12.8 cm in anteroposterior diameter and 10 cm in transverse diameter. The urinary dosages of acid derivatives of catecholamines (homovanillic acid, vanylmandelic acid) and methoxylated derivatives (metanephrine, normetanephrine) returned high to 12 times normal. She then underwent an adrenalectomy.

The pathological examination found an adrenal gland measuring 13 cm x 8 cm x 6 cm, entirely occupied by a neoplasm of multi-nodular appearance made up of nodules 0.5 to 2 cm in diameter, often containing significant hemorrhagic changes and sometimes a fibro-myxoid aspect. The multinodular tumor proliferation is made of neuroblast cells at different stages of maturation (Fig 3 to 6), ranging from small neuroblast to ganglion cell. We noted areas of necrosis, the presence of vascular emboli, the presence of calcification. The resection was complete R0, no normal adrenal parenchyma is seen, but the adrenal capsule and the periaxillary fat are preserved. The immunohistochemistry study showed expression of chromogranin (Fig 7), synaptophysin (Fig 8), neurofilaments (Fig 9) with absence of expression of PS 100 (Fig 10) and a Ki 67 at 37% (Fig 11). A postoperative thoraco-abdomino-pelvic CT scan was performed showing osteolytic lesions of the cervix, left femoral metaphysis and bilateral iliac wings (Fig 13 and 14), with no residual tumor, no secondary hepatic or pulmonary visceral lesions. We completed the assessment with an abdomino-pelvic MRI which objectified nodular lesions of the right iliac wing, the right sacral fin and the L5 lumbar vertebra enhanced after injection of gadolinium.

We concluded that there was a 13 cm multinodular ganglioneuroblastoma metastatic to the bone.

The patient was put on palliative Etoposide-Cisplatin type chemotherapy every 21 days, which took place without toxicity greater than or equal to grade 2 according to CTCAE V5. After 6 cures, an abdominopelvic MRI and a bone scintigraphy were performed, reporting stability of the bone lesions described above (Fig 16 and 17). We opted for a therapeutic window with close clinical and radiological monitoring. She had 3 years of progression-free survival. Currently she is in bone progression. Analgesic radiotherapy on bone lesions and palliative chemotherapy are planned.

III. DISCUSSION

Neuroblastic tumors are apudomes of the neural crest [3]. They are classified into three histological groups: neuroblastoma, ganglioneuroblastoma and ganglioneuroma. The three histological types constitute the different stages of the development of the same pathology and can be observed in the same tumour. Neuroblastoma is the least differentiated form with a high risk of metastasis, ganglioneuroblastoma is an intermediate form, with more neuronal ganglion cells than neuroblasts, and ganglioneuroma is the most differentiated form with a lower risk of metastasis [3, 1]

We found 50 cases of ganglioneuroblastoma described in the literature with 19 cases located in the adrenal gland (Table 1). Males were predominantly represented. In these 19 cases, the mean age at the time of diagnosis was 38 years with extremes of 20 and 63 years. The average size of the tumor was 10.4 cm with extremes of 4.5 cm and 18 cm. No typical symptoms are present in ganglioneuroblastoma. In some cases, the disease is manifested by symptoms related to local mass effect due to tumor expansion [7], as in our present case. Some cases can be found incidentally [4, 8, 9,

10]. Some are discovered with symptoms of distant metastases to other organs [11]. There are also no radiological signs specific to ganglioneuroblastoma and it is difficult to make a preoperative diagnosis, although a biopsy can be performed in some cases before surgery. The ideal imaging for the diagnosis of ganglioneuroblastoma and metastases in adults is magnetic resonance imaging (MRI) and meta-iodo-benzylguanidine (MIBG) scintigraphy. PET-FDG and technetium bone scintigraphy are additional means that can help in the diagnosis of distant metastasis [12]. Bone is the second most common site of metastasis after lymph nodes [5, 6, 11, 12, 13]. Ganglioneuroblastoma cells can activate both osteoclasts and osteoblasts and produce mixed lytic/sclerotic bone metastases [11]. Of the 19 cases found in the literature, 9 were metastatic, including 3 to lymph nodes, 2 to bone, 2 to bone marrow and 2 others metastatic to the liver (Table 1). In adults the initial extension of the tumor is a fundamental criterion for the prognosis, the International Neuroblastoma Staging System (INSS) has defined 6 evolutionary stages summarized in table 2.

The final diagnosis should always be confirmed by pathological examination and immunohistochemistry for chromogranin-A, neurofilament, synaptophysin and neuron-specific enolase [14, 15]. The usefulness of urinary catecholamines in the diagnosis of ganglioneuroblastoma is limited. They cannot be used to differentiate between ganglioneuroblastoma and pheochromocytoma [16]. Urinary catecholamine derivatives were negative or not searched for in some cases in the literature, but they were high in other cases. In our case they were high at 12 times normal. The International Neuroblastic Pathology Committee (INPC) has grouped ganglioneuroblastoma into 2 subtypes: nodular ganglioneuroblastoma which is our present case and mixed ganglioneuroblastoma [1]

The nodular ganglioneuroblastoma has a poor prognosis while the mixed one has a good prognosis. The age, the initial location and the stage of extension at the time of diagnosis are important prognostic factors.

Treatments for ganglioneuroblastoma include surgery, chemotherapy, and radiation therapy. There is no consensus on a better treatment. The chemotherapy molecules used are the combination of etoposide + cisplatin (as in neuroendocrine carcinomas) and the combination (adriamycin, cyclophosphamide and ifosfamide) [23], [26]. Due to the rarity of ganglioneuroblastomas, a prospective study seems impossible. Survival data are limited. The longest follow-up is only 5 years in the localized form against 2.5 years in the metastatic form. The combination of these 03 therapeutic modalities is beneficial for patients as revealed by Schipper et al [5]. Frequent imaging (every 3 months) should also be part of careful follow-up.

IV. CONCLUSION

Ganglioneuroblastomas are considered to have intermediate metastatic potential between neuroblastoma, which is malignant and therefore highly metastatic, and ganglioneuroma, which is benign and therefore potentially

not very metastatic. The treatment will depend on the stage of diagnosis and the general condition of the patient at the time of diagnosis.

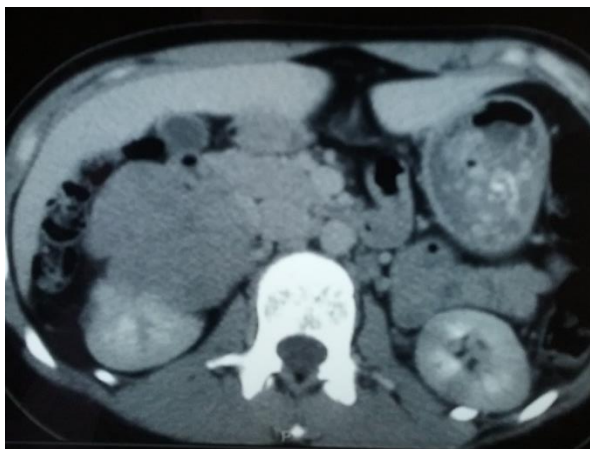

Fig 1 CT Showing Right Adrenal Mass

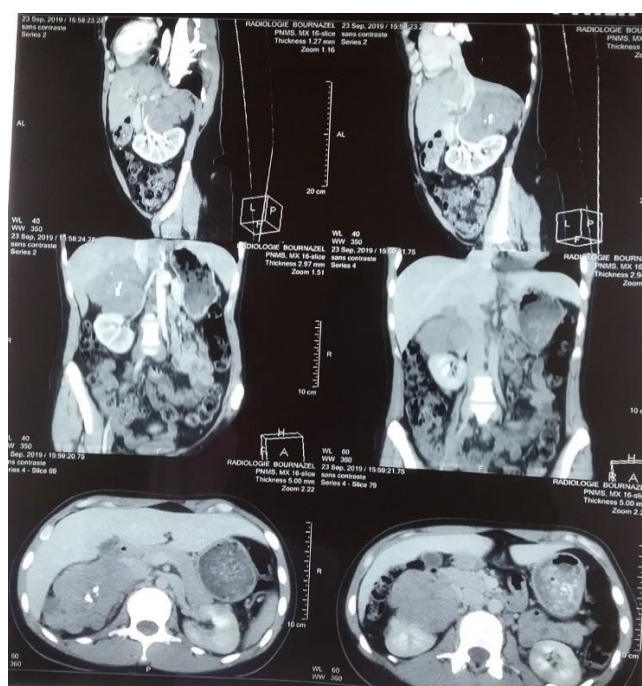


Fig 2 CT Showing Right Adrenal Mass

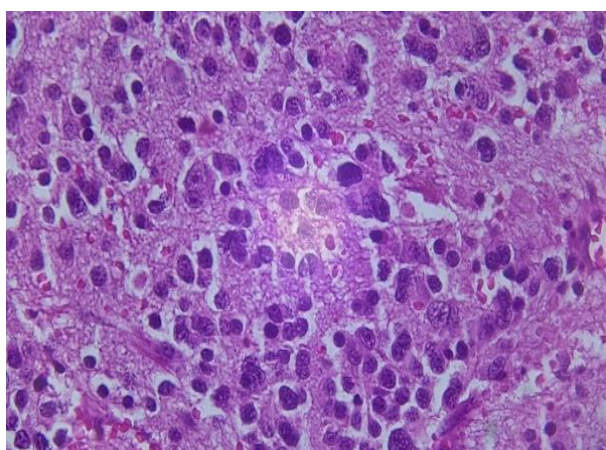


Fig 3 Mature Component at High Magnification

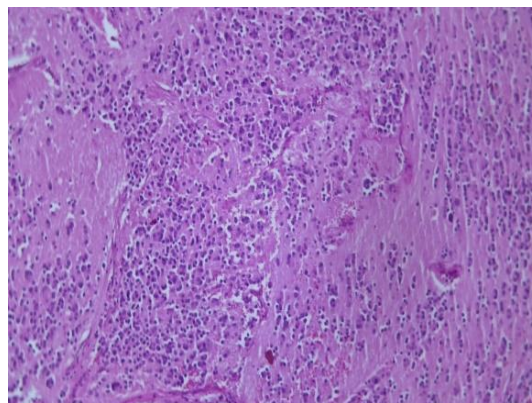


Fig 4 Mature Component in Low Magnification

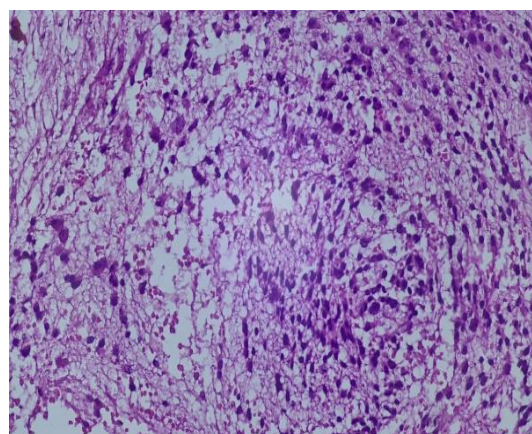


Fig 5 Immature Component at High Magnification

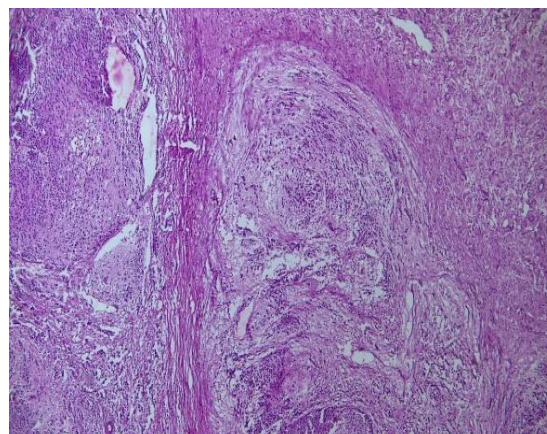


Fig 6 Immature Component at Low Magnification

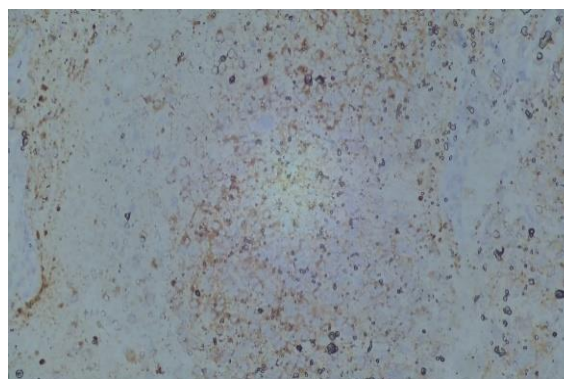


Fig 7 Chromogranin Expression

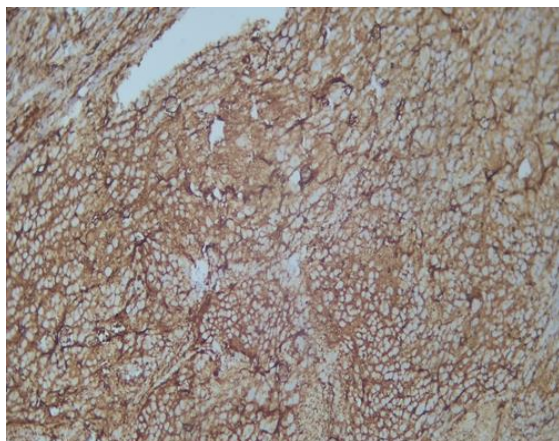


Fig 8 Synaptophysin Expression

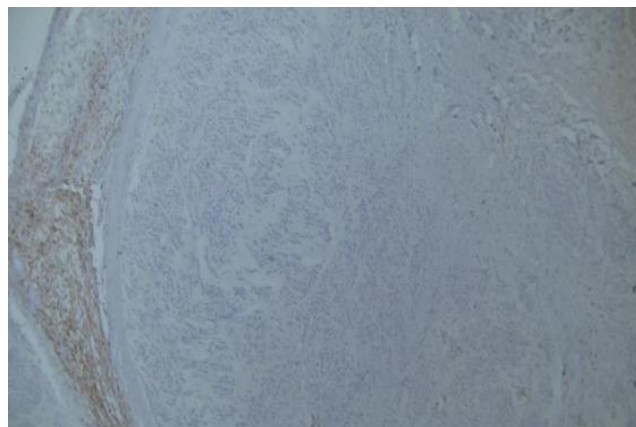


Fig 12 No Expression PS 100

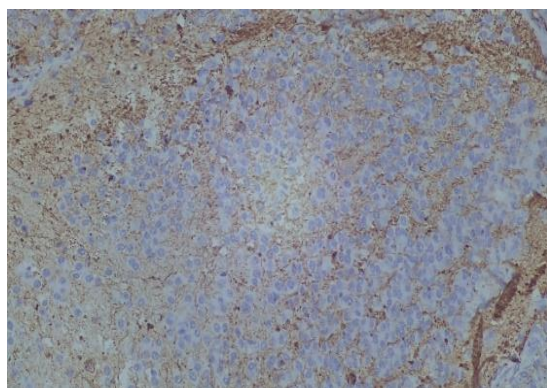


Fig 9 Neurofilament Expression

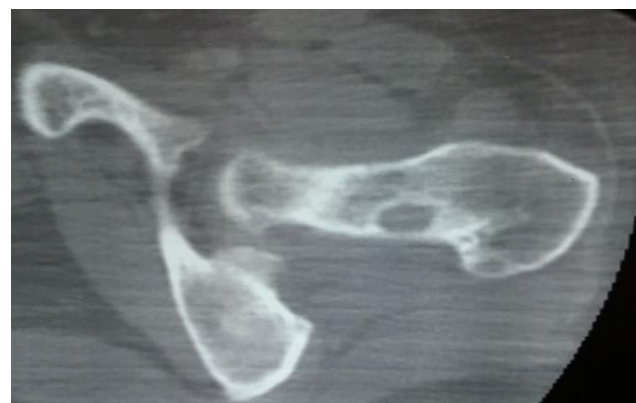

Fig 13 Postoperative CT Scan Showing the Left Bone Lesion

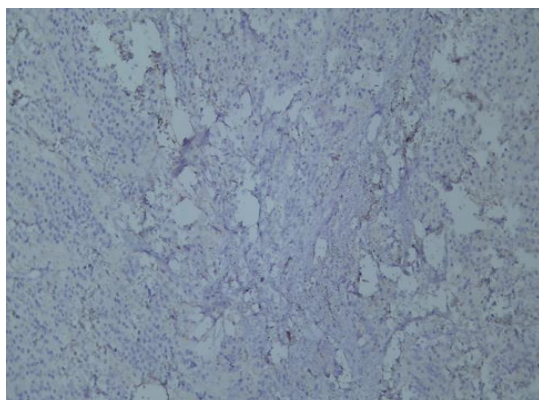


Fig 10 GFAT

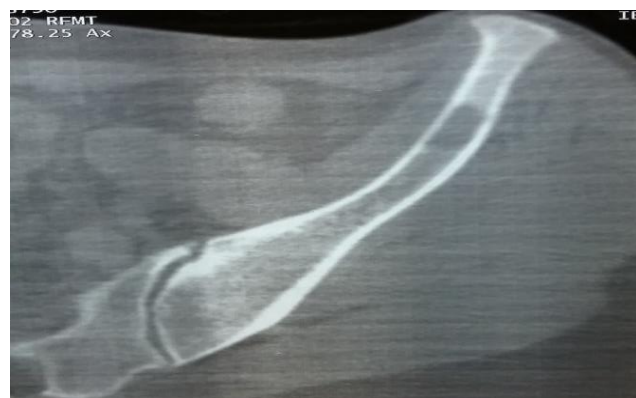

Fig 14 Postoperative CT Scan Showing Iliac Lytic Bone Lesion

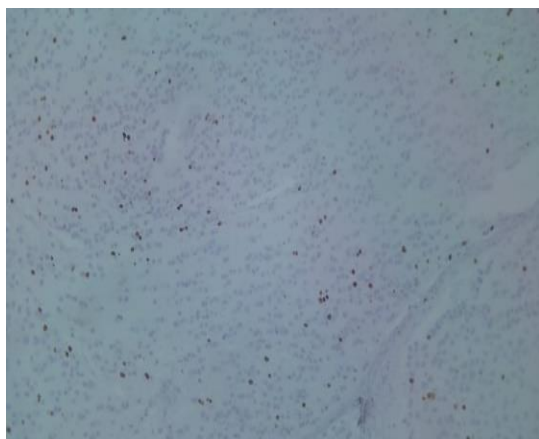


Fig 11 Expression KI 67

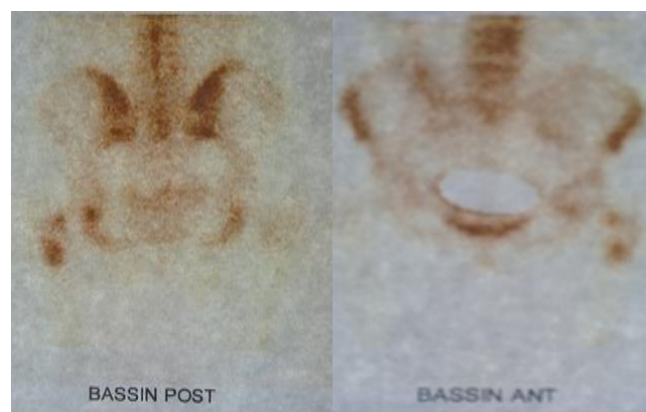

Fig 15 Postoperative Bone Scan

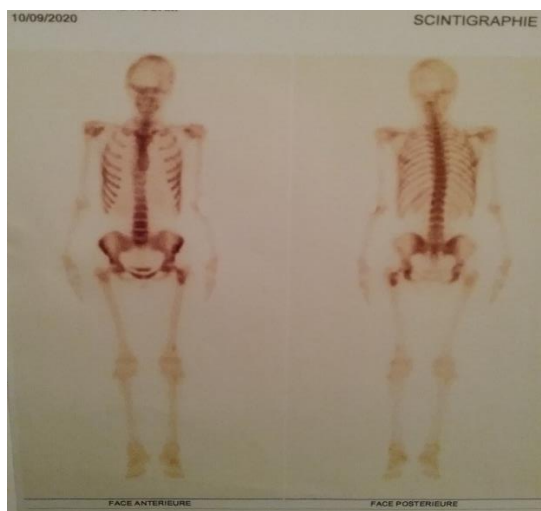


Fig 16 Bone Scan after Chemotherapy

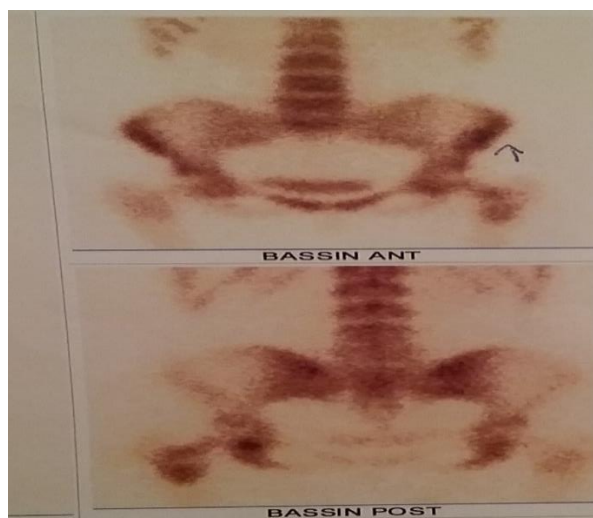


Fig 17 Bone Scan after Chemotherapy

Table 1 Case of Adrenal Ganglioneuroblastoma

Patient	Auteur	Age	Sex	Taille (cm)	Localisation	Activité sécrétoire	Métastases	Traitement	Survie
1	Butz (1940) [21]	25	M	NR	NR	NR	Foie	NR	NR
2	Cameron (1967) [22]	58	F	NR	Droite	VMA, HVA	Aucun	Chirurgie	3,5 ans sans récurrence
3	Takahashi (1988) [23]	21	M	8,8	Gauche	VMA, HVA	Ganglion	Chirurgie + RTH + CTH	8 mois sans récurrence
4	Kishikawa (1992)	29	M	11	NR	VMA, HVA	Os	Chirurgie + CTH	NR
5	Kiozumi (1992) [24]	47	F	9	Droite	VMA, HVA	Moelle osseuse	Aucun	3 mois décédé
6	Higuchi (1993) [25]	29	M	11	NR	Catécholamines urinaires	Moelle osseuse	Chirurgie	10 mois sans récurrence
7	Hiroshige (1995) [9]	35	M	10	Gauche	Aucune	Aucune	Chirurgie	2 ans sans récurrence
8	Mehta (1997) [18]	22	M	9	Bilatéral	NR	NR	Chirurgie	NR
9	Rousseau (1998) [26]	NR	F	NR	Gauche	NR	Foie	Chirurgie + RTH + CTH	NR
10	Fujiwara (2000) [27]	25	M	9	Gauche	Aucune	Aucune	Chirurgie	5 ans sans récurrence
11	Slapa (2002) [19]	20	F	18	NR	Aucune	Aucune	Chirurgie	1 an sans récurrence
12	Koike (2003) [8]	50	M	4,5	Droite	Aucune	NR	Chirurgie	2,5 an sans récurrence
13	Gunlusoy (2004) [20]	59	M	12	Droite	Aucune	Ganglion	Chirurgie	NR
14	Mizuno (2010) [13]	53	M	11	Droite	Aucune	Os (Vertèbres lombaire)	Chirurgie + RTH	2,5 ans avec récurrence
15	Bolzacchini (2015) [17]	63	M	5	Gauche	Aucune	Aucune	Chirurgie	6 mois sans récurrence
16	Qiu (2015) [10]	27	F	11	Gauche	Aucune	Aucune	Chirurgie	5 mois sans récurrence
18	Xiaobo (2015) [4]	27	F	11,5	Gauche	NSE	Aucune	Chirurgie	NR
17	Stefano (2017) [6]	21	F	11	Gauche	Aucune	Ganglion	Chirurgie	21 mois sans récurrence
18	Zahra (2018) [16]	38	M	4,7	Droite	Aucune	Aucune	Chirurgie	

HVA= Homovanillic acid, VMA = Vanilylmandelic acid, RTH = Radiotherapy, CTH = Chemotherapy, NR = Not specified

Table 2 Stage of Extension of Peripheral Neuroblastic Tumors According to the INSS

STADIUM	DESCRIPTION
Stage 1	Localized tumour, no local lymph node metastasis, complete surgical excision
Stage 2A	Localized tumour, no local lymph node metastasis, incomplete surgical excision
Stage 2B	Localized tumour, ipsilateral lymph node metastasis, complete surgical excision
Stage 3	Localized PTN, non-operable And crossing the midline or midline tumor with bilateral extension or localized tumor with contralateral lymph node metastasis
Stage 4	Metastatic tumor (remote lymph nodes, bone, medullary, etc.)
4S stage	Tumors occurring before 1 year, associating a localized primitive site with extensions to the liver, to the skin and/or bone marrow, excluding bone damage

REFERENCES

- Peuchmaur, M. (2004). Peripheral neuroblastic tumours, anatomo-pathological classification. *Annals of Pathology*, 24(6), 556–567. doi:10.1016/s0242-6498(04)94018-7
- Lonergan GJ, Schwab CM, Suarez ES, Carlson CL. Neuroblastoma, ganglioneuroblastoma and ganglioneuroma: radiological-pathological correlation. *X-ray*. 2002; 22 (4): 911–34. doi:10.1148/radiographics.22.4.g02j115911
- F. Mourtada, A. Oujilal, A. Benhamou, S. Sefiani, M. Kzadri. Cervical ganglioneuroblastoma: report of a case. *The Letter of ENT and cervico-facial surgery - Morocco - n° 312 - January-March 2008*
- Ding, X., Hou, Y., Ma, X., Zhang, H., Wang, C. & Wang, Y. (2015). Adult adrenal ganglioneuroblastoma: a rare case report. *Journal of the Canadian Urological Association*, 9(1-2), 75. doi:10.5489/cuaj.2410
- Schipper MH, van Duinen SG, Taphoorn MJ, et al. Adult-onset cerebral ganglioneuroblastoma: two patients and a review of the literature. *Clin Neurol Neurosurg*. 2012; 114: 529–34. doi:10.1016/j.clineuro.2012.03.015
- Benedini, S., Grassi, G., Aresta, C., Tufano, A., Carmignani, LF, Rubino, B., ... Corbetta, S. (2017). Adrenal Ganglioneuroblastoma in Adults: A Case Report and Review of the Literature. *Case Reports in Endocrinology*, 2017, 1–7.
- Yamanaka M, Saitoh F, Saitoh H, Nisimura S, Sawada Y, Tsukui A, et al. Primary retroperitoneal ganglioneuroblastoma in an adult. *Int J Urol* 2001;8:130–132.
- Koike K, Iihara M, Kanbe M, Omi Y, Aiba M, Obara T. Adult-type ganglioneuroblastoma in the adrenal gland treated by a laparoscopic resection: report of a case. *Surg Today* 2003;33:785–790.
- Hiroshige K, Sonoda S, Fujita M, Takasugi M, Kuroiwa A, Inatomi H. Primary adrenal ganglioneuroblastoma in an adult. *InternMed* 1995;34:1168–1173.
- Qiu, W., Li, T., Sun, XD and Lv, GY (2015). Appearance of an adrenal ganglioneuroblastoma in an adult after childbirth. *Annals of Surgical Treatment and Research*, 89(4), 220. doi:10.4174/astr.2015.89.4.220
- Bhadada, S., Bhansali, A., Bhattacharya, A. and Sridhar, S. (2012). Lytic and sclerotic (mixed) vertebral metastases in ganglioneuroblastoma. *Indian Journal of Nuclear Medicine*, 27(2), 127. doi:10.4103/0972-3919.110721
- Mousa, AM, Shokouh-Amiri, MH, Shah, LM, Garzon, S., and Xie, KL (2020). Adult ganglioneuroblastoma of the posterior mediastinum with bone metastases. *Radiology Case Reports*, 15(9), 1676–1682. doi:10.1016/j.radcr.2020.06.048
- Mizuno, S., Iida, T., & Fujita, S. (2010). Adult-onset adrenal ganglioneuroblastoma - Bone metastasis two years after surgery: Report of a case. *Surgery Today*, 40(5), 482–486. doi:10.1007/s00595-008-4084-0
- Jrebi, NY, Iqbal, CW, Joliat, G.-R., Sebo, TJ, & Farley, DR (2014). Review of Our Experience With Neuroblastoma and Ganglioneuroblastoma in Adults. *World Journal of Surgery*, 38(11), 2871–2874. doi:10.1007/s00268-014-2682-0
- Agrawal, A., Rangarajan, V., Shah, S., Puranik, A., & Purandare, N. (2018). MIBG (metaiodobenzylguanidine) theranostics in pediatric and adult malignancies. *The British Journal of Radiology*, 20180103.
- Heidari Z, Kaykhaei MA, Jahantigh M, Sheikhi V. Adrenal ganglioneuroblastoma in an adult: a rare case report, *Int J Endocrinol Metab*. 2018; 16 (1): e63055. doi:10.5812/ijem.63055.
- Bolzacchini E, Martinelli B, Pinotti G. Adult onset of ganglioneuroblastoma of the adrenal gland: case report and review of the literature. *Surg Case Rep*. 2015;1:79. Published 2015 Sep 11. doi:10.1186/s40792-015-0062-0
- Mehta N, Tripathi RP, Popli MB, Nijhawan VS. Bilateral intraabdominal ganglioneuroblastoma in an adult. *Br J Radiol* 1997; 70: 96–98.
- Slapa RZ, Jakubowski W, Kasperlik-Zaluska AA, Szopiński K, Debski R, Samsel M, et al. Adrenal ganglioneuroblastoma in pregnant women: diagnosis by three-dimensional ultrasound. *Eur Radiol* 2002;12:S121–S126.
- Gunlusoy, B., Arslan, M., Selek, E., Sural, S., & Ayder, AR (2004). A case report: Adrenal ganglioneuroblastoma in a 59-year old man. *International Urology and Nephrology*, 36(4), 481–483. doi:10.1007/s11255-004-0851-z
- Butz, H. About sympathocoblastoma of the adrenal medulla. *Virchows Arch. Path Anat.* 306, 360-371 (1940). <https://doi.org/10.1007/BF02595101>
- Cameron DG, Warner HA, Szabo AJ. Chronic diarrhea in an adult with hypokalemic nephropathy and osteomalacia due to a functioning ganglioneuroblastoma. *Trans Am Clin Climatol Assoc*. 1967;78:205-17. PMID: 4961457; PMC ID: PMC2441153.
- Takahashi Y, Kuriyama M, Kawada Y et al. [Multimodal treatment of adrenal ganglioneuroblastoma: a case report] *Hinyokika kyo*. *Acta Urologica Japonica*. 1988 December; 34 (12): 2149-2154.

- [24]. Koizumi, T., Kanbayashi, T., Ichiyoshi, T., nakamura, M., & moriyama, S. (1992). Ganglioneuroblastoma with Disseminated Bone Marrow Infiltration in an Adult. *Internal Medicine*, 31(11), 1322–1324. doi:10.2169/internalmedicine.31.1322
- [25]. Higuchi M, Teshima T, Okada K. Autologous blood stem cell transplantation in an adult with ganglioneuroblastoma. *Nippon Gan Chiryo Gakkai ShiJ.* 1993; 28:1135.
- [26]. Rousseau P, Bernard A, Favre JP, Arnould L, Cheynel N, Manuelian M. Ganglioneuroblastoma de l'adulte [Ganglioneuroblastoma in the adult]. *Med Press.* 1998 Oct 31;27(33):1677-9. English. PMID: 9834780.
- [27]. Fujiwara T, Kawamura M, Sasou S, Hiramori K. Results of surgery for a compound adrenal tumor consisting of pheochromocytoma and ganglioneuroblastoma in an adult: 5-year follow-up. *InternMed.* 2000 Jan;39(1):58-62. doi: 10.2169/internalmedicine.39.58. PMID: 10674851.