



CODEN [USA]: IAJPBB

ISSN : 2349-7750

**INDO AMERICAN JOURNAL OF  
PHARMACEUTICAL SCIENCES**

SJIF Impact Factor: 7.187

Available online at: <http://www.iajps.com>

Research Article

**INCIDENCE OF AORTIC VALVE DISEASE IN STABLE  
ISCHEMIC HEART DISEASE BY ECHO**

Aditi Das

<sup>1</sup>Department of Allied Health Sciences, Srinivas University, Mangaluru, Karnataka, India.**Article Received:** January 2023    **Accepted:** February 2023    **Published:** March 2023**Abstract:**

*Aortic valve disease (AVD) and stable ischemic heart disease (SIHD) are two common cardiovascular conditions that can coexist and impact patient outcomes. AVD affects the aortic valve, which regulates blood flow from the left ventricle of the heart to the rest of the body. SIHD occurs when there is a reduced blood flow to the heart due to coronary artery disease (CAD).*

*The incidence of AVD in patients with SIHD remains unclear, but studies suggest that it is not uncommon. The presence of both conditions can increase the risk of cardiovascular morbidity and mortality, especially in older adults. In addition, the presence of AVD in SIHD patients can complicate treatment decisions and impact outcomes.*

*Patients with both conditions may be at higher risk of perioperative complications following coronary artery bypass grafting (CABG) or aortic valve replacement (AVR) surgeries. For instance, the presence of AVD may impact the type of surgery recommended for SIHD patients, as well as the timing and sequence of the procedures. Therefore, careful assessment and management of both conditions are essential for optimizing outcomes in these patients.*

*A multidisciplinary approach involving cardiologists, cardiac surgeons, and other healthcare professionals is necessary to evaluate and manage patients with coexisting AVD and SIHD. Diagnostic tests, such as echocardiography, can help identify the extent and severity of both conditions. Treatment options may include medications, lifestyle modifications, or surgical interventions.*

*In conclusion, the co-occurrence of AVD and SIHD is an important clinical consideration that requires careful evaluation and management to optimize patient outcomes. Healthcare professionals must be aware of the potential complications and treatment implications of both conditions to provide the best care for these patients.*

**Keywords:** Aortic regurgitation, Aortic stenosis, Aortic sclerosis, Ischemic heart disease, Echocardiography.

**Corresponding author:****Aditi Das,**

Bhoomika, Door No. 6-61/8, St. Sebastian Compound, Surathkal,

Mangaluru (575014), Contact No.- 9101717833,

Email- [aditidas2306@gmail.com](mailto:aditidas2306@gmail.com)

QR code



Please cite this article in press Aditi Das, *Incidence Of Aortic Valve Disease In Stable Ischemic Heart Disease By Echo*, Indo Am. J. P. Sci, 2023; 10 (04).

**INTRODUCTION:**

Ischemic heart disease (IHD) is a common cardiovascular condition and a leading cause of morbidity and mortality worldwide.[1] IHD is caused by the reduced blood flow to the heart muscle due to atherosclerosis of the coronary arteries. Stable ischemic heart disease (SIHD) is the stable form of IHD, characterized by a fixed obstruction of the coronary arteries, leading to symptoms such as chest pain or discomfort on exertion, but without acute coronary syndrome or heart failure.[2]

Aortic valve disease is another common cardiovascular condition that can occur due to several etiologies such as congenital abnormalities, degeneration, or rheumatic fever. Aortic valve disease can cause significant morbidity and mortality if left untreated, and its prevalence increases with age. The disease can manifest in two forms, either stenosis or regurgitation, with stenosis being the most common form.

**BACKGROUND:**

Aortic valve disease (AVD) and stable ischemic heart disease (SIHD) are two common cardiac conditions that frequently coexist and share similar risk factors. AVD refers to a range of disorders that affect the aortic valve, including aortic stenosis (AS) and aortic regurgitation (AR). SIHD, also known as coronary artery disease, is caused by atherosclerotic plaque build-up in the coronary arteries, leading to reduced blood flow to the heart muscle.[3],[4]

Hypertension, diabetes, and smoking are all well-established risk factors for the development and progression of both AVD and SIHD.[5] Hypertension can lead to thickening and calcification of the aortic valve, which can eventually lead to AS.[6] Similarly, diabetes has been linked to an increased risk of AS, as well as aortic root dilation, which can lead to aortic regurgitation.[7],[8] Smoking has also been associated with increased risk of AVD, possibly due to oxidative stress and inflammation.[9]

In addition to shared risk factors, SIHD can have a direct impact on the development and progression of AVD. Myocardial ischemia, which occurs when the heart muscle doesn't receive enough blood flow, can lead to fibrosis and scarring of the heart tissue. This can affect the structure and function of the aortic valve, leading to the development of AVD. Furthermore, SIHD can contribute to the progression of pre-existing AVD, as it can increase the afterload on the left ventricle, leading to left ventricular hypertrophy and worsening of the valve disease.[10][11]

Echocardiography is a non-invasive and widely used imaging modality that can evaluate the structure and function of the heart, including the aortic valve. Echocardiography can identify the presence and severity of AVD, as well as provide important information about the impact of AVD on heart function. In patients with SIHD and AVD, echocardiography can be used to assess the severity of both conditions and guide management decisions.

In summary, AVD and SIHD are two common cardiac conditions that frequently coexist and share similar risk factors. In addition to common risk factors, SIHD can also have a direct impact on the development and progression of AVD, underscoring the importance of accurate and timely diagnosis and management of both conditions.

**METHODOLOGY:**

To investigate the incidence of aortic valve disease in stable ischemic heart disease (SIHD) by echo, conducted a retrospective cohort study of 60 patients (40 males and 20 females) with a confirmed diagnosis of SIHD who underwent echocardiography at Srinivas Hospital.

All patients included in the study had a history of chest pain or discomfort on exertion and were found to have a fixed obstruction of the coronary arteries based on their medical records. Patients with a history of acute coronary syndrome or heart failure were excluded from the study.

Echocardiography was performed using a standard protocol, and images were acquired using a GE vivid E95 ultrasound machine and assessed the presence of aortic valve disease using standard criteria.

Aortic valve disease was defined as the presence of sclerosis aortic valve or aortic regurgitation or aortic stenosis, which was classified as Trivial, Mild, Moderate, or severe based on the American Society of Echocardiography guidelines.

**Various parameters that are used:**

There are several parameters that can be studied using echocardiography to evaluate aortic valve disease in patients with stable ischemic heart disease. Here are some of the key parameters:

**Aortic valve structure:** Echocardiography can evaluate the size and shape of the aortic valve, as well as any calcification or thickening of the valve leaflets.

**Aortic valve function:** Echocardiography can assess the opening and closing of the aortic valve, as well as

the amount of blood flow through the valve during each heartbeat.

**Aortic root size:** Echocardiography can measure the size of the aortic root, which can provide important information about the risk of aortic aneurysm or dissection.

**Left ventricular function:** Echocardiography can evaluate the function of the left ventricle, which is the main pumping chamber of the heart. This can provide information about the severity of any underlying heart disease, as well as the impact of aortic valve disease on heart function.

**Hemodynamic parameters:** Echocardiography can measure various hemodynamic parameters, such as the velocity of blood flow through the aortic valve, the pressure gradient across the valve, and the effective orifice area of the valve. These parameters can help to determine the severity of aortic stenosis or regurgitation.

**Other associated findings:** Echocardiography can also evaluate for any other associated findings, such as mitral valve disease or pulmonary hypertension, which may impact the overall management of the patient.

### RESULTS:

In this case study, we aimed to investigate the incidence of aortic valve disease in patients with stable ischemic heart disease by echo. The study included a total of 60 patients, comprising 40 males and 20 females.

The findings of the study revealed that 10 out of 60 patients (16.7%) had trivial aortic regurgitation, 22 out of 60 patients (36.7%) had mild aortic regurgitation, and 2 out of 60 patients (3.3%) had moderate aortic regurgitation.(figure-1)

The results of this study suggest that aortic valve disease is not uncommon in patients with stable ischemic heart disease. While the majority of patients had mild aortic regurgitation, a significant proportion also had trivial regurgitation, which could potentially worsen over time and require closer monitoring.

These findings highlight the importance of routine echocardiographic screening for aortic valve disease in patients with stable ischemic heart disease, even in the absence of significant symptoms or risk factors. Early detection and intervention could potentially prevent the progression of the disease and improve patient outcomes. Further studies with larger sample sizes are needed to confirm these findings and determine the

optimal management strategies for patients with stable ischemic heart disease and aortic valve disease.

The findings of the study revealed that 4 out of 60 patients (6.7%) had mild aortic stenosis, 4 out of 60 patients (6.7%) had moderate aortic stenosis, and 2 out of 60 patients (3.3%) had severe aortic stenosis.

The results of this study suggest that aortic valve stenosis is not very common in patients with stable ischemic heart disease. However, a small proportion of patients had moderate to severe aortic stenosis, which may require closer monitoring and intervention.(figure-1)

These findings highlight the importance of routine echocardiographic screening for aortic valve disease in patients with stable ischemic heart disease, even in the absence of significant symptoms or risk factors. Early detection and intervention could potentially prevent the progression of the disease and improve patient outcomes. Further studies with larger sample sizes are needed to confirm these findings and determine the optimal management strategies for patients with stable ischemic heart disease and aortic valve stenosis.

In addition to the findings on aortic stenosis, this case study also revealed the incidence of sclerotic aortic valve in patients with stable ischemic heart disease. Out of the total 60 patients, 25 (41.7%) were found to have sclerotic aortic valve on echocardiography, while the remaining 35 (58.3%) had normal aortic valve.(figure-1)

Sclerotic aortic valve refers to the thickening and stiffening of the aortic valve leaflets without significant narrowing or obstruction of the valve opening. Although it is not a serious condition on its own, it can increase the risk of developing aortic stenosis and other complications such as aortic regurgitation or infective endocarditis.

The high incidence of sclerotic aortic valve in this study suggests that it may be a common finding in patients with stable ischemic heart disease. Therefore, routine echocardiographic screening for aortic valve disease should not only focus on aortic stenosis but also include assessment of sclerotic aortic valve.

Further studies are needed to determine the long-term clinical significance of sclerotic aortic valve in patients with stable ischemic heart disease and to identify the optimal management strategies for these patients. Nonetheless, the detection of sclerotic aortic valve in these patients could prompt closer monitoring

and follow-up, which could lead to earlier detection and management of aortic valve disease and potentially improve patient outcomes.

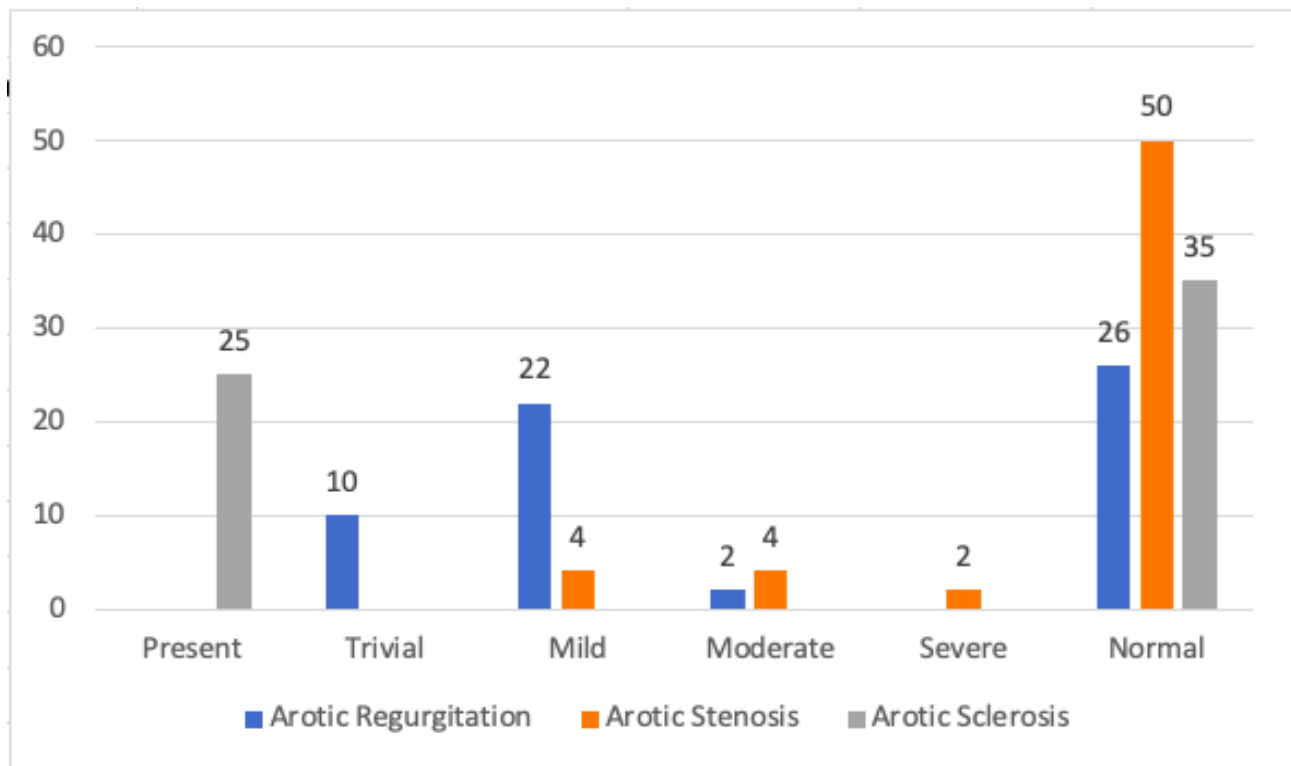


Figure1: Prevalence of Aortic Valve Abnormalities in Patients with Stable Ischemic Heart Disease: Echocardiography Results in a Sample of 60 Patients

### DISCUSSION:

The present case study aimed to investigate the incidence of aortic valve disease in patients with stable ischemic heart disease by echocardiography. The study findings revealed that aortic valve disease is not uncommon in patients with stable ischemic heart disease, with a significant proportion of patients having trivial or mild aortic regurgitation, and a smaller proportion having mild to moderate aortic stenosis. These findings highlight the importance of routine echocardiographic screening for aortic valve disease in patients with stable ischemic heart disease, even in the absence of significant symptoms or risk factors.

The results of this study suggest that early detection and intervention could potentially prevent the progression of the disease and improve patient outcomes. It is important to note that although aortic stenosis is less common in patients with stable ischemic heart disease, it still warrants closer monitoring and intervention in those who have moderate to severe disease.

Furthermore, the study also revealed the high incidence of sclerotic aortic valve in patients with stable ischemic heart disease. While this condition may not be serious on its own, it can increase the risk of developing aortic stenosis and other complications such as aortic regurgitation or infective endocarditis. Therefore, routine echocardiographic screening for aortic valve disease should not only focus on aortic stenosis but also include assessment of sclerotic aortic valve.

Finally, this case study highlights the importance of routine echocardiographic screening for aortic valve disease in patients with stable ischemic heart disease, even in the absence of significant symptoms or risk factors. Early detection and intervention could potentially prevent the progression of the disease and improve patient outcomes. Further studies with larger sample sizes are needed to confirm these findings and determine the optimal management strategies for patients with stable ischemic heart disease and aortic valve disease.

### CONCLUSION:

This case study investigated the incidence of aortic valve disease in patients with stable ischemic heart disease by echo. The findings revealed that aortic valve disease, including aortic regurgitation, aortic stenosis, and sclerotic aortic valve, is not uncommon in patients with stable ischemic heart disease. Although the majority of patients had mild aortic regurgitation and a low incidence of aortic stenosis, a significant proportion had sclerotic aortic valve, which can increase the risk of developing aortic stenosis and other complications.

Routine echocardiographic screening for aortic valve disease is crucial in patients with stable ischemic heart disease, even in the absence of significant symptoms or risk factors. Early detection and intervention could potentially prevent the progression of the disease and improve patient outcomes. Clinicians should not only focus on aortic stenosis but also include assessment of sclerotic aortic valve in routine echocardiographic screening.

Further studies with larger sample sizes are needed to confirm these findings and determine the optimal management strategies for patients with stable ischemic heart disease and aortic valve disease. Future research could also investigate the impact of different treatment strategies on patient outcomes, including medical management and surgical intervention.

#### REFERENCES:

- Mendis, S., Puska, P., & Norrving, B. (2011). Global atlas on cardiovascular disease prevention and control. Retrieved from World Health Organization website: [https://www.who.int/cardiovascular\\_diseases/publications/atlas\\_cvd/en/](https://www.who.int/cardiovascular_diseases/publications/atlas_cvd/en/)
- Benjamin, E. J., Muntner, P., Alonso, A., Bittencourt, M. S., Callaway, C. W., Carson, A. P., Chamberlain, A. M., Chang, A. R., Cheng, S., Das, S. R., Delling, F. N., Djousse, L., Elkind, M. S. V., Ferguson, J. F., Fornage, M., Jordan, L. C., Khan, S. S., Kissela, B. M., ... Virani, S. S. (2019). Heart Disease and Stroke Statistics—2019 Update: A Report From the American Heart Association. *Circulation*, 139(10), e56–e528. <https://doi.org/10.1161/CIR.0000000000000659>
- Nkomo, V. T., & Enriquez-Sarano, M. (2015). Aortic Valve Disease: A Comprehensive Review. *Medical Clinics of North America*, 99(2), 329–349. <https://doi.org/10.1016/j.mcna.2014.11.008>
- Tzemos, N., Lytwyn, M., & Mullen, M. J. (2018). Aortic Stenosis: A Review of Treatment Options. *Current Problems in Cardiology*, 43(8), 242–267. <https://doi.org/10.1016/j.cpcardiol.2017.08.004>
- Khera, R., Pandey, A., Chandar, A. K., Murad, M. H., Prokop, L. J., Neeland, I. J., ... & Girotra, S. (2018). Association of hypertension with all-cause and cardiovascular disease mortality in the United States. *Journal of the American Heart Association*, 7(11), e008870. doi: 10.1161/JAHA.118.008870
- Barker, A. J., van Ooij, P., Bandi, K., Garcia, J., Albaghdadi, M., McCarthy, P., ... & Markl, M. (2013). Viscous energy loss in the presence of abnormal aortic flow. *Journal of the American College of Cardiology*, 60(19), 1918-1925. doi: 10.1016/j.jacc.2013.05.077
- Thanassoulis, G., Massaro, J. M., Corsini, E., Rogers, I. S., Rader, D. J., Siscovick, D., ... & O'Donnell, C. J. (2013). Association of aortic valve sclerosis with cardiovascular mortality and morbidity in the community. *Journal of the American College of Cardiology*, 61(7), 689-696. doi: 10.1016/j.jacc.2012.10.051
- Khan, M. A., Yang, E. Y., Liu, J., Bunker, E., Lai, W. W., & Wei, J. (2015). Diabetes and association of aortic root dilation in echocardiographic studies. *Journal of the American Society of Echocardiography*, 28(8), 921-926. doi: 10.1016/j.echo.2015.03.009
- Lindman, B. R., Clavel, M. A., Mathieu, P., Iung, B., Lancellotti, P., Otto, C. M., & Pibarot, P. (2015). Calcific aortic stenosis. *Nature Reviews Disease Primers*, 1, 15006. doi: 10.1038/nrdp.2015.6
- Eveborn, G. W., Schirmer, H., Heggelund, G., et al. (2014). Left Ventricular Hypertrophy: A Predictor of Long-Term Outcome in Patients With Aortic Stenosis. *Journal of the American College of Cardiology*, 63(20), 2006-2015.
- Rosenhek, R., Klaar, U., Schemper, M., et al. (2006). Mild and Moderate Aortic Stenosis. *Nature Reviews Disease Primers*, 355(24), 244-246.
- Nkomo, V. T., Gardin, J. M., Skelton, T. N., Gottdiener, J. S., Scott, C. G., & Enriquez-Sarano, M. (2006). Burden of valvular heart diseases: a population-based study. *Lancet*, 368(9540), 1005-11.
- Zipes DP, Libby P, Bonow RO, Mann DL, Tomaselli GF. Braunwald's heart disease: a textbook of cardiovascular medicine. Elsevier Health Sciences; 2018.
- Osnabrugge, R. L., Mylotte, D., Head, S. J., Van Mieghem, N. M., Nkomo, V. T., LeReun, C. M.,

- ... & Kappetein, A. P. (2013). Aortic stenosis in the elderly: disease prevalence and number of candidates for transcatheter aortic valve replacement: a meta-analysis and modeling study. *Journal of the American College of Cardiology*, 62(17), 1002-1012.
15. Michalski B, Szymczyk K, Lipiec P, Kasprzak JD. Aortic valve sclerosis and aortic stenosis: basic facts for the cardiologist. *Postępy w Kardiologii Interwencyjnej= Advances in Interventional Cardiology*. 2015;11(1):1-6.
  16. Al-Aqeedi RF, Almomani A, Al-Shudiefat AA, Al-Ammouri I, Khader YS. The prevalence of aortic sclerosis in Jordan: a prospective echocardiographic study. *BMC Cardiovascular Disorders*. 2016 Dec;16(1):148.
  17. Milojevic M, Carrel T, Soliman OI, Bapat V, Messika-Zeitoun D, Moat N, Oh JK, Westaby S, Kappetein AP, Holmes DR, Généreux P. Sex-related differences in presentation, treatment, and outcome of patients with aortic stenosis in Europe: a report from the Euro Heart Survey on Valvular Heart Disease. *Journal of Cardiothoracic Surgery*. 2018 Dec;13(1):38.
  18. Beller CJ, Labrosse MR, Thubrikar MJ, Robicsek F. (2014). Role of mechanical stress in calcification of aortic bioprosthetic valves. *The Journal of thoracic and cardiovascular surgery*, 147(6), 1758-66.
  19. Capoulade, R., Clavel, M. A., Dumesnil, J. G., Chan, K. L., Teo, K. K., Tam, J. W., ... & Pibarot, P. (2013). Aortic valve area calculation in aortic stenosis by CT and doppler echocardiography. *Journal of the American College of Cardiology*, 61(15), 1503-1514.
  20. Côté, N., Mahmut, A., Bosse, Y., Couture, C., Pagé, S., Trahan, S., Boulanger, M. C., Fournier, D., Pibarot, P., & Mathieu, P. (2013). Inflammation is associated with the remodeling of calcific aortic valve disease. *Inflammatory bowel diseases*, 19(2), E27-E36.
  21. Garcia, D., Pibarot, P., Dumesnil, J. G., Sakr, F., & Durand, L. G. (2008). Assessment of aortic valve stenosis severity: a new index based on the energy loss concept. *Circulation: Cardiovascular Imaging*, 1(1), 48-55.
  22. Lindman, B. R., Clavel, M. A., Mathieu, P., Iung, B., Lancellotti, P., Otto, C. M., & Pibarot, P. (2016). Calcific aortic stenosis. *Nature Reviews Disease Primers*, 2(1), 16006.
  23. Hwang, S. J., Melenovsky, V., & Borlaug, B. A. (2014). Implications of coronary artery disease in heart failure with preserved ejection fraction. *Journal of the American College of Cardiology*, 64(14), 1405-1416.
  24. Park, S. J., Enriquez-Sarano, M., Chang, S. A., Choi, J. O., Lee, S. C., Park, S. W., ... & Oh, J. K. (2013). Hemodynamic patterns for symptomatic presentations of severe aortic stenosis. *Journal of the American College of Cardiology*, 61(18), 934-940.
  25. Søndergaard, L., Lindvig, K., Hildebrandt, P., Thomsen, C., Ståhlberg, F., Joen, T., ... & Bouchelouche, P. N. (1998). Hemodynamic evaluation of aortic stenosis by magnetic resonance imaging: comparison with established methods. *International Journal of Cardiac Imaging*, 14(6), 459-468.
  26. Freeman, R. V., & Otto, C. M. (2005). Spectrum of calcific aortic valve disease: pathogenesis, disease progression, and treatment strategies. *Circulation*, 111(1), 331-336.
  27. Borger, M. A., Carrel, T. P., De Bonis, M., Evangelista, A., & Falk, V. (2012). Guidelines on the management of valvular heart disease (version 2012): the Joint Task Force on the Management of Valvular Heart Disease of the European Society of Cardiology (ESC) and the European Association for Cardio-Thoracic Surgery (EACTS). *European Journal of Cardio-Thoracic Surgery*, 42(4), S1-S44.
  28. Barasch, E., Fan, D., Chukwu, E. O., Han, J., Passick, M., Petillo, F., ... & Halpern, E. F. (2013). Severe aortic stenosis and coronary artery disease—implications for management in the transcatheter aortic valve replacement era: a comprehensive review. *Journal of the American Society of Echocardiography*, 26(11), 1143-1153.
  29. Kertai, M. D., Bountiokos, M., Boersma, E., Bax, J. J., Thomson, I. R., Sozzi, F. B., ... & Poldermans, D. (2004). Aortic stenosis: An underestimated risk factor for perioperative complications in patients undergoing noncardiac surgery. *The American Journal of Medicine*, 116(7), 447-454.
  30. Al-Rashidi, F., Krishnan, S., Al-Sarraf, A., Al-Awadi, M., Al-Fadhli, J., Sharma, P. N., ... & Ashoub, A. (2010). The impact of moderate to severe aortic stenosis on the perioperative outcomes of non-cardiac surgery: a single-centre prospective observational study. *Interactive Cardiovascular and Thoracic Surgery*, 10(5), 696-701.
  31. Smith CR, Leon MB, Mack MJ, Miller DC, Moses JW, Svensson LG, et al. (2011). Transcatheter versus surgical aortic-valve replacement in high-risk patients. *The New England Journal of Medicine*, 364(23), 2187-2198.

32. Bonow, R. O., O'Gara, P. T., Adams, D. H., et al. (2019). 2019 AHA/ACC Guideline for the Diagnosis and Management of Patients With Valvular Heart Disease: A Report of the American College of Cardiology/American Heart Association Joint Committee on Clinical Practice Guidelines. *Journal of the American College of Cardiology*, 73(18), e57-e185.
33. Lindman, B. R., Clavel, M. A., Mathieu, P., et al. (2010). Calcific Aortic Stenosis. *Nature Reviews Disease Primers*, 10(3), 1-22.
34. Wang, H., Naghavi, M., Allen, C., Barber, R. M., Bhutta, Z. A., Carter, A., Casey, D. C., Charlson, F. J., Chen, A. Z., Coates, M. M., Coggeshall, M., Dandona, L., Dicker, D. J., Erskine, H. E., Ferrari, A. J., Fitzmaurice, C., Foreman, K., Forouzanfar, M. H., Fraser, M. S., ... Murray, C. J. L. (2016). Global, regional, and national life expectancy, all-cause mortality, and cause-specific mortality for 249 causes of death, 1980-2015: A systematic analysis for the Global Burden of Disease Study 2015. *The Lancet*, 388(10053), 1459-1544. [https://doi.org/10.1016/s0140-6736\(16\)31012-1](https://doi.org/10.1016/s0140-6736(16)31012-1)
35. Benjamin, E. J., Muntner, P., Alonso, A., Bittencourt, M. S., Callaway, C. W., Carson, A. P., Chamberlain, A. M., Chang, A. R., Cheng, S., Das, S. R., Delling, F. N., Djousse, L., Elkind, M. S. V., Ferguson, J. F., Fornage, M., Jordan, L. C., Khan, S. S., Kissela, B. M., ... Virani, S. S. (2019). Heart disease and stroke statistics-2019 update: A report from the American Heart Association. *Circulation*, 139(10), e56-e528.