



Journal Homepage: -[www.journalijar.com](http://www.journalijar.com)

## INTERNATIONAL JOURNAL OF ADVANCED RESEARCH (IJAR)

Article DOI:10.21474/IJAR01/16322  
DOI URL: <http://dx.doi.org/10.21474/IJAR01/16322>



### RESEARCH ARTICLE

#### SIMULTANEOUS DIAGNOSIS OF ERYTHRODERMIC POIKILODERMATOUS MYCOSIS FUNGOIDES AND MUCOEPIDERMOID CARCINOMA OF THE RIGHT MAXILLARY SINUS

F. Amakha<sup>1</sup>, M. Aboudourib<sup>1</sup>, A. Lahrougui<sup>1</sup>, M. Rami<sup>2</sup>, Y. Rochdi<sup>2</sup>, A. Raji<sup>2</sup>, L. El Hamri<sup>3</sup>, A. Fakhri<sup>3</sup>, H. Rais<sup>3</sup>, O. Hocar<sup>1</sup> and S. Amal<sup>1</sup>

1. Department of Dermatology and Venereology, Mohammed VI University Hospital Center, Bioscience and Health Laboratory. Cadi Ayyad University, FMPM. Marrakech. Morocco.
2. Department of Otorhinolaryngology, Mohammed VI University Hospital Center, Bioscience and Health Laboratory. Cadi Ayyad University, FMPM. Marrakech. Morocco.
3. Department of Anatomopathology, Mohammed VI University Hospital Center, Bioscience and Health Laboratory. Cadi Ayyad University, FMPM. Marrakech. Morocco.

#### Manuscript Info

##### Manuscript History

Received: 20 December 2022

Final Accepted: 24 January 2023

Published: February 2023

##### Key words:

Erythroderma, Mucoepidermoid  
Carcinoma of the Maxillary Sinus,  
Mycosis Fungoides, Poikiloderma,  
Prognosis

#### Abstract

**Background:** Poikilodermatous mycosis fungoides (pMF) is a very rare variant of cutaneous T lymphoma. We describe a rare case of erythrodermic poikilodermatous MF associated with mucoepidermoid carcinoma of the right maxillary sinus.

**Case report:** A 66-year-old patient was admitted to the dermatology department for a dry pruritic and poikilodermic erythroderma that had been evolving for two years. He also reported a right unilateral nasal obstruction evolving for one and a half years. Histological examination showed an orthokeratotic epidermis and an edematous superficial and middle dermis, with a thick band of lymphocytic infiltrate in the subepidermis. This infiltrate was made of atypical lymphoid elements of mixed CD3+, CD4+, and CD8+ T phenotype with epidermotropism, allowing for diagnosis of poikilodermic MF to be made. A Deep biopsy of the right maxillary sinus had concluded a high-grade mucoepidermoid carcinoma.

**Conclusion:** Although it is impossible to demonstrate a causal relationship between erythrodermic poikilodermatous MF and our patient's mucoepidermoid carcinoma, this observation illustrates that in case of dissociated evolution under treatment of a poikilodermatous erythrodermic MF, the search for a second cancer is desirable. The association between poikilodermatous erythrodermic MF and Hematologic or Solid malignancies, requires long-term follow-up and conditions the prognosis of patients.

Copy Right, IJAR, 2023,. All rights reserved.

#### Introduction:-

Mycosis fungoides (MF) is the most common primary cutaneous lymphoma. It accounts for nearly 50% of all primary cutaneous lymphomas. Many mainly clinical variants of classical MF have been described, including poikilodermatous MF. Poikilodermatous mycosis fungoides has been individualized as a rare form and is considered to be even more indolent than classical MF(Kazakov DV et al, 2004). It can be difficult to differentiate from

**Corresponding Author:- Fatima Ezzahra Amakha**

Address:- Department of Dermatology and Venereology, Mohammed VI University Hospital Center, Bioscience and Health Laboratory. Cadi Ayyad University, FMPM. Marrakech. Morocco.

poikilodermatous parapsoriasis. The diagnosis is based on clinical and histological findings, combining a clinical appearance of poikilodermal lesions with a histological and immunohistochemical profile of mycosis fungoides. Mycosis fungoides may be associated with a hemopathy; particularly Hodgkin's disease, acute leukemia, or solid tumors; notably lung cancers (Huang K et al., 2007). The prognosis is mainly determined by the presence of a second malignancy. We describe a case of erythrodermic poikilodermatous MF associated with mucoepidermoid carcinoma of the right maxillary sinus.

### Case Report:

A 66-year-old man was hospitalized in the dermatology department for a pruritic erythroderma evolving for two years, in the context of apyrexia and conservation of the general state. He also reported a right unilateral nasal obstruction evolving for one year and a half. Physical examination revealed dry erythroderma with diffuse poikiloderma, accentuated on the neck, trunk and lower limbs, the entire surface of the skin was very thin and crinkled and had a characteristic wrinkled "cigarette-paper" appearance with palmoplantar keratoderma characterized by fissures, diffuse alopecia of the scalp and eyebrows (**Figures 1 A, B**), the fingernails and toenails were hyperkeratotic, and presence of right cervical lymphadenopathy. Histological examination of the skin showed an ortho-keratotic epidermis and an edematous superficial and middle dermis, with a thick band of lymphocytic infiltrate in the subepidermis. This infiltrate was made of atypical lymphoid elements of mixed CD3+, CD4+, and CD8+ T phenotype with epidermotropism, allowing to conclude to a diagnosis of poikilodermatous MF. The CD4/CD8 ratio was less than 10. Blood Sezary cells on the blood smear were 741.3 cells/mm<sup>3</sup>. The lymph node biopsy was in favor of a lymph node location of a poorly differentiated carcinomatous proliferation. As part of the etiological assessment of the nasal obstruction, a facial computed tomography was performed, showing an aggressive infiltrating process of the right maxillary sinus with endo-orbital and endocranial extension (**Figures 2, A, B**). Facial magnetic resonance imaging showing a mass of the right maxillary sinus; with isosignal intensity on T1-weighted imaging, and heterogeneous high signal intensity on T2-weighted imaging, intensely enhancing after injection of Gadolinium, with destruction of the right maxillary sinus walls (**Figures 3, A,B**). A deep biopsy of the right maxillary sinus had concluded a high-grade mucoepidermoid carcinoma. Following the multidisciplinary consultation meeting, the patient received four subcutaneous injections of methotrexate 25mg, one injection per week in combination with oral folic acid, forty-eight hours before the injection of methotrexate, and three sessions of palliative radiotherapy (given the non-operability of the patient and the contraindications to chemotherapy). The evolution was marked by the death of the patient.

### Discussion:-

Mycosis fungoides (MF) is the most common cutaneous T-cell lymphoma, belonging to the group of indolent primary cutaneous T-cell lymphomas according to the WHO/EORTC classification (World Health Organization/European Organization for Research and Treatment of Cancer). Poikilodermatous MF has been individualized as a rare and reputedly even more indolent form than classical MF (Huang K et al., 2007), posing the problem of differential diagnosis with benign dermatoses. It can be difficult to distinguish from poikilodermatous parapsoriasis and prelymphomatous states. Poikiloderma is a syndrome that can be found in many dermatoses, acquired or congenital. In particular in mycosis fungoides. Poikilodermatous MF is usually characterized by the development of large plaques or generalized skin involvement.

Poikilodermatous MF as an entity in its own right has been little studied, mostly in the form of clinical cases and in the context of two large Anglo-Saxon series (Abbott RA et al., 2011; Samman PD. 1976). The first series was published by Samman in 1976 and involved 122 patients with MF described as "lichenoid", the term used by the author for these chronic poikilodermal lesions (Samman PD. (1976). The second was a descriptive series of 49 patients from St John's Institute of Dermatology in London in 2011 (Abbott RA et al., 2011). This series included patients with poikilodermatous MF defined by the presence of at least 50% clinically poikilodermal lesions. The diagnosis of poikilodermatous mycosis fungoides is clinical and histo-immunohistochemical. Clinically, poikilodermatous MF is characterized by a poikilodermal lesion appearance. Histologically, there are histological signs of classic MF, represented by a superficial dermal atypical lymphocytic infiltrate in a subepidermal band, with epidermotropism, and an inconstant poikilodermal histological pattern with no clear correspondence with the clinical poikilodermal character; made of epidermal atrophy, telangiectasias, and pigmentary incontinence. The most commonly used treatments in poikilodermatous MF were: local corticosteroid therapy, narrow-band UVB phototherapy, oral retinoids (acitretin and isotretinoin) and topical chlormethine. Also, methotrexate with doses ranging from 12.5 to 25 mg/week, and PUVA therapy were recommended as a treatment for poikilodermatous MF. Therapeutic abstention if failure of one or more of the above-mentioned treatments.

Mucoepidermoid carcinoma (MEC) is a rare malignant tumor of the maxilla that accounts for 1-3% of cancers of the upper aerodigestive tract and 15-30% of malignant tumors of the salivary glands (Lakouichmi M et al., 2013; Meleti M et al., 2009). Mostly discovered between the ages of 40 and 60. Occurrence in young children and adolescents remains rare (Belghiti H et al., 2011). Its etiopathogenesis is not elucidated and the clinical signs are generally not very suggestive, especially in the initial stages. Currently, the Armed Forces Institute of Pathology (AFIP) and Brandwein classifications are used to describe this tumor (Ellis GL, Auclair PL, 1996; Goode RK et al., 1998; Brandwein MS et al., 2001); thus, MEC is defined as a low-grade, intermediate-grade, or high-grade tumor. To classify the tumor, the pathologist assigns points according to unfavorable histological parameters. As the score increases, the tumor is classified as a high grade. High-grade mucoepidermoid carcinoma usually affects older people and more often men. It is more likely to spread to other parts of the body and is often diagnosed at an advanced stage. This type of mucoepidermoid carcinoma has a serious prognosis.

The management of MEC depends on the pathological diagnosis. Surgical treatment of MEC remains the treatment of choice. It consists of removal of the tumor with a mucosal and bone margin (Baj A et al., 2002; Aro K et al., 2008). Lymph node dissection is indicated in high-grade tumors where the risk of lymph node metastases is greater than 50% (Da Cruz Perez DE et al., 2006). Radiation therapy complements surgery in high-grade MEC stages II, III, and IV and in low-grade tumors stages III and IV (C. VanHerpen et al., 2022). Chemotherapy is not recommended for this type of cancer (C. VanHerpen et al., 2022; Skálová A et al., 2022).

Several studies have reported a significantly increased risk of developing a second lymphoma or other cancer in patients with primary cutaneous T-cell lymphoma. The treatments used in this pathology, a genetic predisposition, or an environmental factor could explain it. Some authors have also suggested a role for dysfunctional T-cell immunity (Huang K et al., 2007). Mycosis fungoides can be associated with or reveal hematological diseases, in particular, Hodgkin's lymphoma and acute leukemia, or solid tumors, particularly of the lung, thyroid gland, colon, and urinary tract (**Table 1**). A case of granulomatous slack skin associated with metastatic testicular seminoma was reported in 2017 (D. Carton de Tournai, 2017). The association of poikilodermatous erythrodermic MF with cancer of the ORL sphere and particularly with mucoepidermoid carcinoma of the right maxillary sinus has not yet been reported in the literature.

### Conclusion:-

Although it is difficult to demonstrate a causal link between poikilodermatous MF and the mucoepidermoid carcinoma of our patient, this observation illustrates that in case of dissociated evolution under treatment of a poikilodermatous MF, the search for a second cancer is desirable. The association between poikilodermatous erythrodermic MF and malignant pathology, lymphoproliferative or other, imposes a long-term follow-up and conditions the prognosis of the patients.

### Table:

**Table1:-** Clinical features of mycosis fungoides patients with secondary malignancies in the literature.

| References               | Number of patients | Age (year) | Gender (% or number) | Hematologic and Solid malignancies   | Diagnosis before or after or simultaneous with Mycosis fungoides | Evolution |
|--------------------------|--------------------|------------|----------------------|--|--|-----------|
| Kyle T. Amber et al 2016 | 183                | -          | Male and Female      | Penile cancer<br>Predominance of Hodgkin's lymphoma in male<br>Non Hodgkin's lymphoma<br>Predominance of bronchopulmonary malignancy in female | After<br>Cutaneous Cell Lymphoma                                 | -         |
| Cengiz FP et al          | 13                 | Mean age   | Male (n=7)           | Predominance   | After  | -         |

|                               |     |                            |   |  |   |                          |
|-------------------------------|-----|----------------------------|---|--|---|--------------------------|
| 2017                          |     | = 47.23                    | Female (n= 6)                                   | hodgkin's lymphoma<br>Lung cancer<br>Non hodgkin's lymphoma<br>Others cancer                                 | mycosis fungoides                         |                          |
| Amrita Goyal et al 2020       | 511 | Median age =63             | Male (n=310, 60.67%)<br>Female (n= 201, 39.33%) | Hematologic malignancies (36%)<br>Tumor malignancies (64%)   | After Mycosis fungoides                   | Higher mortality (47.6%) |
| Amrita Goyal et al 2021       | 962 | Mean age =58.4             | Male-to-female ratios =1.2/1 to 2.9/1           | Predominance non hodgkin's lymphoma and Hodgkin's lymphoma<br>Lung cancer                                    | After Mycosis fungoides                   | -                        |
| Izabela B Lazewirz et al 2021 | 32  | Female= 59.7<br>Male= 66.8 | Male (n=18)<br>Female (n=14)                    | Basal Cell carcinoma and lymphomatoide papulosis (15.63%)<br>Lung cancer (12.50%)<br>B-Cell lymphoma (9.38%) | After mycosis fungoide or Sezary syndrome | -                        |

**Figures:**

**Figure 1 (A, B):** Clinical presentations of poikilodermatous mycosis fungoides (pMF); Generalized poikiloderma with wrinkled skin, cigarette-paper appearance and alopecia of the scalp in our patient, frontal view (A), posterior view(B) photography.

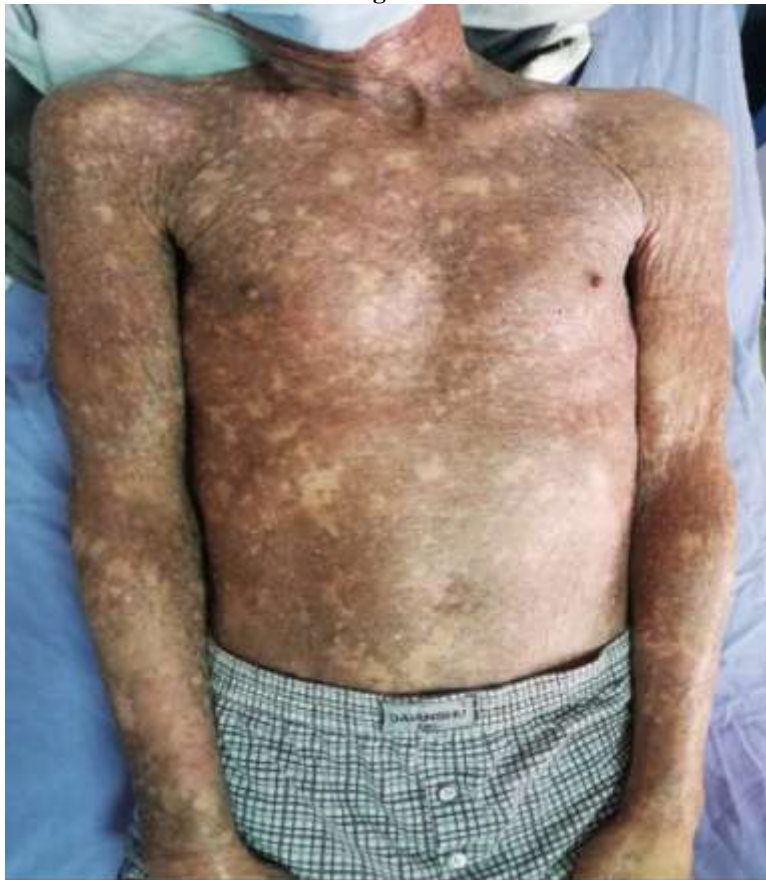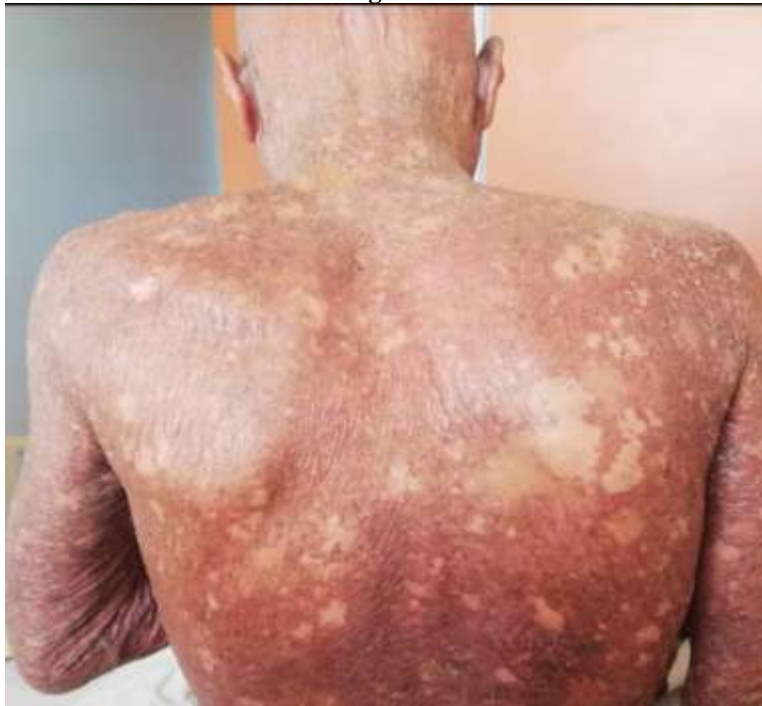**Fig1A:**

Fig 1B:



**Figure 2 (A, B):** Axial facial computed tomography (CT) images, show an aggressive infiltrating process of the right maxillary sinus with endo-orbital and endocranial extension. Unenhanced CT image reveals a spontaneously isodense tumor in the right maxillary sinus (A). Contrast- enhanced CT image shows a lesion with heterogeneous enhancement, with areas of necrosis (B).

Fig 2A:

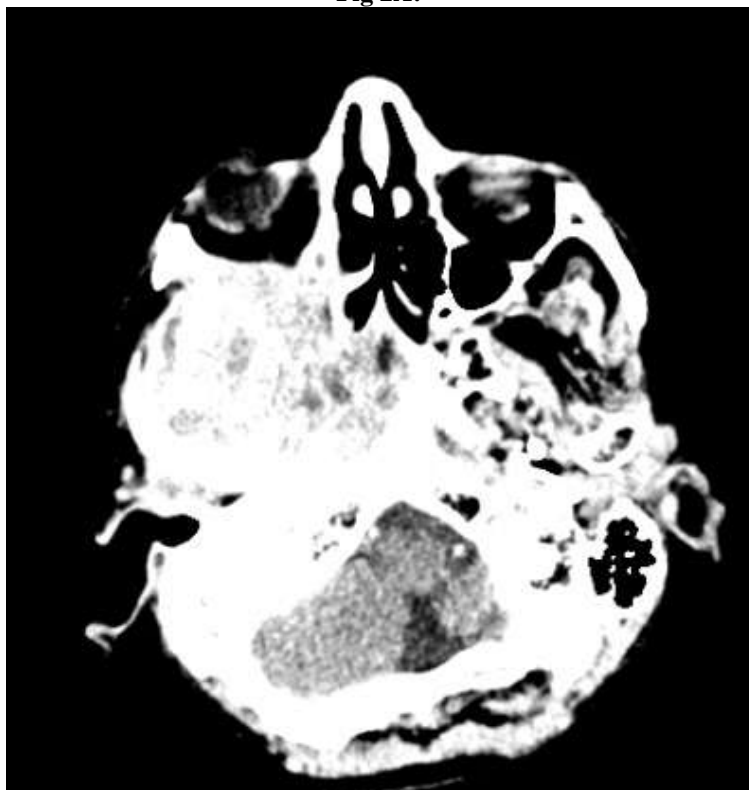
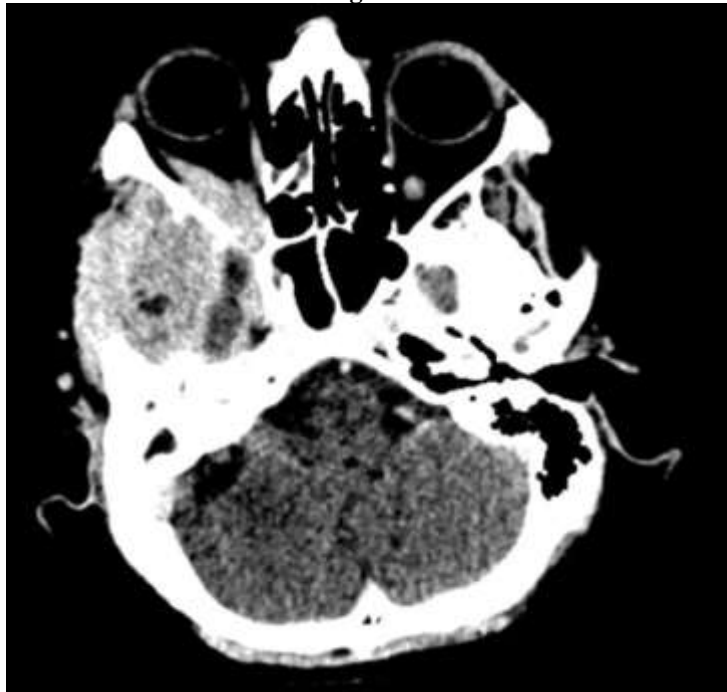


Fig 2B:



**Figure 3 (A, B):** Axial Magnetic resonance imaging indicated a soft tissue mass in the right maxillary sinus, which showed isosignal intensity on T1-weighted imaging (A), and heterogeneous high signal intensity on T2-weighted imaging (B), the tumor is enhanced by Gadolinium and responsible for lysis of the walls of the right maxillary sinus.

Fig 3A:

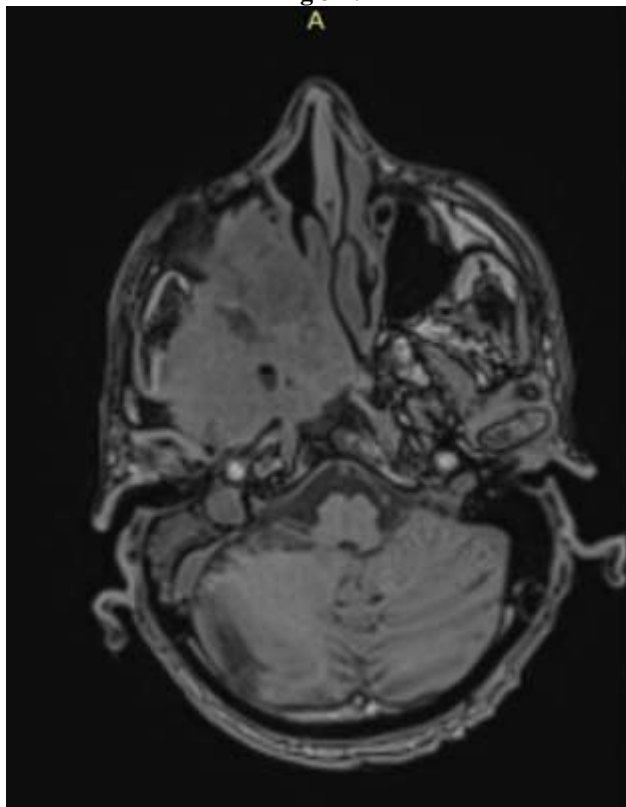
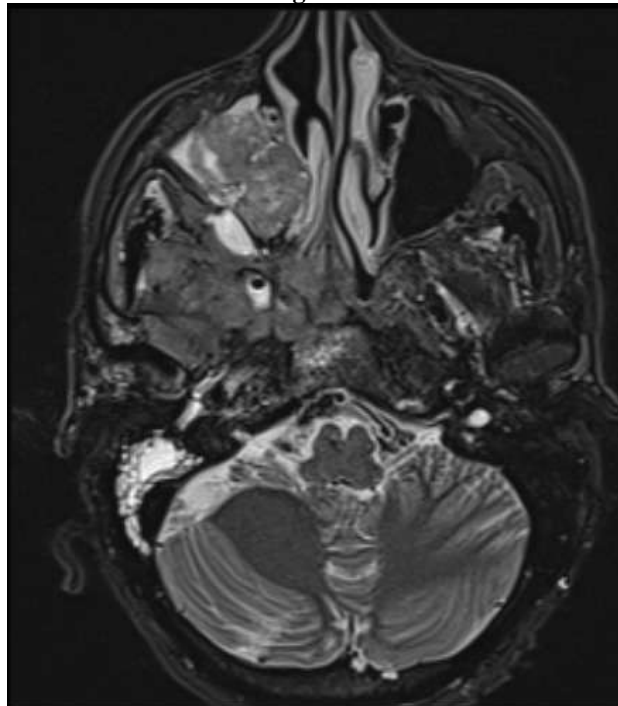




Fig 3 B:

**Conflicts of interest:**

None declared.

**References:-**

1. Abbott RA, Sahni D, Robson A, Agar N, Whittaker S, Scarisbrick JJ. (2011): Poikilodermatous mycosis fungoides: a study of its clinicopathological, immunophenotypic, and prognostic features. *J Am Acad Dermatol*; 65(2):313-319.
2. Amrita Goyal, MD, Daniel O’Leary, MD, Kavita Goyal, MD, Nathan Rubin, MS, Kimberly Bohjanen, MD, Maria Hordinsky, MD et al. (2020): Increased risk of second primary hematologic and solid malignancies in patients with mycosis fungoides: A surveillance Epidemiology, and Results analysis. *Journal of American Academy of Dermatology*; 83(2): 404–411.
3. Amrita Goyal, MD, Daniel O’Leary, MD, Kavita Goyal, MD, Krishnan Patel, MD, David Pearson, MD, Murali Janakiram, MD. (2021): Cutaneous T-Cell Lymphoma is associated with increases risk of lymphoma, melanoma, lung cancer, a,d bladder cancer: A systematic review and meta-analysis. *Journal of the American Academy of Dermatology*;85(6):1418-1428.
4. Aro K, Leivo I, Mäkitie AA. (2008): Management and outcome of patients with mucoepidermoid carcinoma of major salivary gland origin: a single institution’s 30-year experience. *Laryngoscope*; 118(2):258–262.
5. Baj A, Bertolini F, Ferrari S, Sesenna E. (2002): Central mucoepidermoid carcinoma of the jaw in a teenager: a case report. *J Oral Maxillofac Surg*;60(2):207–211.
6. Belghiti H, Znati K, Harmouch T, Amarti A, Zaki Z, El Alami MN. (2011): Mucoepidermoid carcinoma of the parotid gland in young children. *Rev StomatolChir Maxillofac*;112(2):110–112.
7. Brandwein MS, Ivanov K, Wallace DI, Hille JJ, Wang B, Fahmy A, et al.(2001): Mucoepidermoid carcinoma: a clinicopathologic study of 80 patients with special reference to histological grading. *Am J Surg Pathol*;25(7):835–845.
8. Cengiz FP, Emiroglu N, Onsun N. (2017): Frequency and Risk Factors for Secondary Malignancies in Patients with Mycosis Fungoides. *Tur Kish J Hematol*; 34(4):378-379.
9. C.VanHerpen, V.VanderPoorten, A. Skalova, C. Even, JP. Machiels. (2022): Salivary gland cancer: ESMO-European Reference Network on Rare Adult Solid Cancers (EURACAN) Clinical Practice Guideline for diagnosis, treatment and follow-up. November 02, 2022.100602. <https://doi.org/10.1016/j.esmoop.2022.100602>
10. D.Carton de tournai. (2017) : Mycosis fongoi e chalazodermique associ e   un s minome testiculaire m tastatique. *Annales de dermatologie et de v n r ologie* volume 144, Issues 6-7. June- July, P. 446-449.

11. Da Cruz Perez DE, Pires FR, Lopes MA, de Almeida OP, Kowalski LP.(2006):Adenoid cystic carcinoma and mucoepidermoid carcinoma of the maxillary sinus: report of a 44-year experience of 25 cases from a single institution. *J Oral Maxillofac Surg*;64(11): 1592–1597.
12. Ellis GL, Auclair PL. (1996): *Atlas of Tumor Pathology, Tumors of the salivary Glands, series 3, fascicle 17.* Washington DC; Armed Forces Institute of Pathology;155-75,353-355.
13. Goode RK, Auclair PL, Ellis GL. (1998): Mucoepidermoid carcinoma of the major salivary glands: clinical and histopathologic analysis of 234 cases with evaluation of grading criteria. *Cancer*;82(7):1217–1224.
14. HUANG K, WEINSTOCK M, CLARKE C, MCMILLAN A, HOPPE R, KIM Y. (2007): SECOND LYMPHOMAS AND OTHER MALIGNANT NEOPLASMS IN PATIENTS WITH MYCOSIS FUNGOIDES AND SÉZARY SYNDROME. *ARCH DERMATOL*;143(1):45-50.
15. Izabela Błażewicz, Berenika Olszewska, Marta StawczykMacieja, Maciej Jaśkiewicz, Roman J Nowicki, MałgorzataSokołowska-Wojdyło. (2021): The incidences of other primary cancers in patients with mycosis fungoides and Sézary syndrome. *Adv DermatolAlergol*;38(2):289-294.
16. Kazakov DV, Burg G, Kempf W. (2004): Clinicopathological spectrum of mycosis fungoides. *J EurAcad Dermatol Venereol*,18(4):397-415.
17. kyle T. Amber. Romi Bloom. Keyvan Nouri. (2016): Second Primary Malignancies in CTLC Patients from 1992 to 2011: A SEER-Based, Population-Based Study Evaluating Time from CTLC Diagnoses, Age, Sex, Stage, and CD30+ sub type. *Am J Clin Dermatol*;17(1):71-7.
18. Lakouichmi M, MlihaTouati M, Zrara I, Zoubeir Y, El Bouihi M, Mansouri Hattab N. (2013): Primary intraosseous mucoepidermoid carcinoma of the jaws. *Rev StomatolChirMaxillofacChir Orale*;114(5):334–337.
19. Meleti M, Ferrari S, Toma L, Vescovi P, Sesenna E. (2009): Mucoepidermoid carcinoma of palatal salivary glands: Clinicopathological experience with 10 patients. *Oral Oncology Supplement*;3(1):131.
20. Samman PD. (1976): Mycosis fungoides and other cutaneous reticuloses. *Clin Exp Dermatol*;1(3):197-214.
21. Skálová A, Hyrcza MD, Leivo I. (2022): Update from the 5th Edition of the World Health Organization Classification of Head and Neck Tumors: Salivary Glands. *Head Neck Pathol* ;16(1):40– 53.