



## The Effect of Dexpanthenol Treatment on Renal Parenchymal Injury in Rats with Induced Renovascular Occlusion

### Dekspantenol Tedavisinin Renovasküler Oklüzyon Oluşturulan Ratlarda Renal Parankim Hasarına Etkisi

Erkan ARSLAN<sup>1</sup> [ID], Hakan TÜRK<sup>1</sup> [ID], Murat ÇAĞLAYAN<sup>2</sup> [ID], Ataman GÖNEL<sup>3</sup> [ID],  
Cüneyt TAYMAN<sup>4</sup> [ID], Tuğba TAŞKIN TÜRKMENOĞLU<sup>5</sup> [ID]

<sup>1</sup>Department of Urology, Uşak University Faculty of Medicine, Uşak, Türkiye.

<sup>2</sup>Department of Medical Biochemistry, Dışkapı Yıldırım Beyazıt Training and Research Hospital, University of Health Sciences, Ankara, Türkiye.

<sup>3</sup>Department of Nutrition and Dietetics, Faculty of Health Science, Hasan Kalyoncu University, Gaziantep, Türkiye.

<sup>4</sup>Department of Neonatology, Ankara City Hospital, University of Health Sciences, Ankara, Türkiye.

<sup>5</sup>Department of Pathology, Dışkapı Yıldırım Beyazıt Training and Research Hospital, University of Health Sciences, Ankara, Türkiye.

**Article Info:** Received; 26.12.2022. Accepted; 25.01.2023. Published; 30.01.2023.

**Correspondence:** Erkan Arslan; MD., Department of Urology, Uşak University Faculty of Medicine, Uşak, Türkiye. E-mail: [erkanarslan@hotmail.com](mailto:erkanarslan@hotmail.com)

#### Abstract

Kidney damage due to ischemia-reperfusion injury (IRI) is a serious cause of morbidity and mortality. We induced an experimental kidney ischemia-reperfusion model in rats where intraperitoneal dexpanthenol were given and compared to controls in terms of oxidative stress, tubular damage, apoptosis, and its effect on renal inflammation. Twelve-week-old male albino Wistar rats were used for creating the experimental model and the study sample were divided into three groups (n=16); control group (intraperitoneal 2cc/kg saline was injected), IRI group and IRI+dexpanthenol group via intraperitoneal injection. Blood samples were obtained from rats 24 hours after perfusion and their left kidneys were removed. In order to determine the percentage of apoptotic cells, a total of 100 cells were counted in each region and the number of cells with caspase-3 positivity was recorded for each region. Mortality was lower, although not statistically significant in the IRI+dexpanthenol group (n=3; 18.8%) compared to the IRI group (n=6; 37.5%) (p=0.216). In addition, kidney parenchyma and tubular damages were significantly lower in the dexpanthenol group compared to the IRI group (p<0.05). Dexpanthenol significantly decreased oxidative stress and inflammation. Caspase-3 positive stained cell numbers were lower in the dexpanthenol group and also apoptosis rates were significantly lower (p<0.05). Dexpanthenol treatment in kidney ischemia-reperfusion models showed significant recovery in kidney tubular cell and parenchyma damages, apoptosis, oxidative stress, and inflammation. These results show us that dexpanthenol treatment can be a promising alternative in improving the prognosis of adults with kidney IRI.

**Keywords:** Ischemia-reperfusion injury, Kidney, Dexpanthenol, Oxidative stress, Inflammation.

#### Özet

İskemi-reperfüzyon injürisine (IRI) bağlı böbrek hasarı ciddi bir morbidite ve mortalite nedenidir. İntraperitoneal dekspantenol verilen ratlarda deneysel bir böbrek iskemi-reperfüzyon modeli oluşturduk ve

oksidatif stres, tübüler hasar, apoptoz ve renal inflamasyon üzerindeki etkisi açısından kontrollerle karşılaştırdık. Deneysel modelin oluşturulmasında 12 haftalık erkek albino Wistar ratlar kullanıldı ve çalışma örnekleme 3 gruba ayrıldı (n=16); kontrol grubu (intraperitoneal 2cc/kg salin enjekte edildi), IRI grubu ve intraperitoneal enjeksiyon uygulaması ile oluşturulan IRI+dekspantenol grubu. Perfüzyondan 24 saat sonra ratlardan kan örnekleri toplandı ve sol böbrekleri alındı. Apoptotik hücre yüzdesini belirlemek için her bölgede toplam 100 hücre sayıldı ve her bölge için kaspaz-3 pozitifliği olan hücre sayısı kaydedildi. Mortalite IRI+dekspantenol grubunda (n=3; 18.8), IRI grubuna (n=6; %37.5) göre istatistiksel olarak anlamlı düzeyde olmamakla beraber daha düşüktü (p=0.216). Ayrıca böbrek parankimi ve tübüler hasarlar dekspantenol grubunda IRI grubuna göre anlamlı olarak daha düşüktü (p<0.05). Dekspantenol, oksidatif stresi ve enflamasyonu önemli ölçüde azaltmıştı. Dekspantenol grubunda kaspaz-3 pozitif boyanan hücre sayıları ve apoptoz oranları anlamlı olarak düşüktü (p<0.05). Böbrek iskemi-reperfüzyon modellerinde dekspantenol tedavisi, böbrek tübüler hücre ve parankim hasarlarında, apoptozda, oksidatif streste ve inflamasyonda önemli iyileşme gösterdi. Bu sonuçlar bize dekspantenol tedavisinin böbrek IRI'si olan yetişkinlerin prognozunu iyileştirmede umut verici bir alternatif olabileceğini göstermektedir.

**Anahtar Kelimeler:** İskemi-reperfüzyon hasarı, Böbrek, Dekspantenol, Oksidatif stres, İnflamasyon.

## Introduction

Ischemia of an organ or a system usually results in varying degrees of tissue damage, depending on the volume and the period of obstructed arterial blood flow [1]. Reestablishing the blood flow following ischemia is named ischemia-reperfusion injury (IRI) [1]. Reperfusion mostly causes an issue which damages the tissues more than ischemic damage [2]. IRI is usually related with the disturbed microvascular perfusion following low oxygenation of the tissue [3]. Renal insufficiency caused by renal parenchymal damage due to renovascular obstruction might vary with obstruction degree and period. Kidney failure may also occur following renovascular occlusion.

Dexpanthenol (Dxp) is an alcohol analog and the biologically active form of pantothenic acid (vitamin B5) [4]. Dxp can be introduced via oral or parenteral route in mammals to benefit from its active form [5,6]. Dxp changes into D-pantothenic acid through oral or parenteral route in rats and mammals. Pantothenic acid treatment causes an increase in reduced glutathione (GSH), co-enzyme A (CoA) and intracellular adenosine triphosphate (ATP) synthesis [7,8]. Those GSH and glutathione-dependent peroxidases are the most important protective systems against oxidative stress and lipid peroxidation seen in ischemia-reperfusion injuries [8,9].

Kidney IRI is a severe morbidity and mortality cause. In this study, we aimed to investigate the effect of intraperitoneal Dxp in rats with an

experimental kidney IRI model on oxidative stress, tubular damage, apoptosis and renal inflammation, by comparing with the control group.

## Material and Method

All procedures were carried out in accordance with national guidelines and laws for using and caring of laboratory animals and the Guideline of National Health Institutes for the Care and Use of Laboratory Animals. The study and procedures were approved by the Animal Ethics Committee of Ankara Training and Research Hospital (11.06.2020-60/622).

### Animal model

Twelve-week-old, male albino Wistar rats weighing between 250-300 grams were divided into 3 groups with 16 rats in each group. Groups were labeled as controls, kidney IRI damage model group and IRI+ Dxp treatment group. The rats were put under anesthesia using intramuscular 15 mg/kg xylazine (Rompun, Bayer, Türkiye) and 50 mg/kg ketamine (Ketalar, Eczacıbaşı, Türkiye) and placed on a homeothermic pad to keep the 37°C body temperature. Anterior abdominal wall was opened using a midline section. Right kidney was removed, and the left kidney vessels were separated by blunt dissection. Renal artery was clamped using atraumatic vascular clamps and another atraumatic vascular clamp (FST, Essen, Germany) was applied to left kidney pedicle. Clamp was removed following 45 minutes of

ischemia and blood flow was reintroduced into the kidney. Then, the other vascular clamp was removed for kidney reperfusion. Occlusion was visually confirmed after confirming the color change in the kidneys with atropurpureus shade and reperfusion was visually confirmed by observing the change in color (blushing) of kidneys. Abdominal cavity was closed.

In the control group, rats' right kidneys were excised without blocking left kidney pedicles. Anterior abdominal wall incision was closed and disinfected using 10% povidone-iodine solution. Death incidents and life periods were recorded for all groups. In controls, intraperitoneal 2cc/kg saline was injected and samples from the left kidney were collected after 24 hours. In other rats with induced kidney IRI, dexpanthenol (Bepanthen ampoule, 500 mg, Bayer Corp., Istanbul, Türkiye) was introduced via intraperitoneal route in the treatment group 15 minutes following surgical intervention. In IRI and IRI+Dxp groups, blood samples were taken from rats and their left kidneys were removed under anesthesia 24 hours after reperfusion. After removing the renal capsule using a surgical blade, the kidney was separated into two parts. A part was preserved in 10 % formaldehyde solution for histopathological and immunohistochemical analysis. The other part was preserved for biochemical analysis.

#### *Histopathological assessment*

The kidney tissues obtained were fixed in 10% formaldehyde solution for 48 hours and then embedded in paraffin. The paraffin blocks were cut into 4-5 mm sections, then mounted onto poly-L-lysine-coated slides (Paul Marienfeld GmbH & Co., Lauda-Königshofen, Germany). Hematoxylin-eosin staining was carried out for histopathological evaluation. The sections were examined under 200× magnification using a light microscope (Figure 1). As for grading, histopathological changes were evaluated by tubular injury, according to tubular epithelial cell swelling, interstitial expansion, intratubular hemorrhaging, brush border loss, vacuolar degeneration, necrotic tubules, cast formation and desquamation. Histological sections were evaluated by two pathologists blinded to the groups, and photos were taken.

#### *Immunohistochemical analysis*

For immunohistochemical evaluation, the cross sections were stained with properly diluted primary antibodies specific for Caspase-3 [1:100; (CPP32) Ab-4 (rabbit PAP), 1 ml, Labvision (Thermo), RB-1197-P]. Each and every section was examined for apoptosis. All counting procedures and measurements were performed blind to the study groups. In order to determine the percentage of apoptotic cells, 10 fields of view were randomly selected for each subject, and 100 cells were counted in each field and the number of caspase-3 positive cells were recorded. As a result, 1000 cells were counted for each subject and the number of apoptotic cells was given as a percentage (Figure 2).

#### *Biochemical analysis*

The levels of serum creatinine (SCr) and blood urea nitrogen (BUN) were determined using an automated Biochemical Analyzer (Beckman Coulter, Inc., CA, USA). Obtained renal tissue samples were homogenized in normal saline (1 g in 5 ml) by using a homogenizer (IKA T18 Basic Ultra-Turrax, Germany). Subsequently, the homogenates were centrifuged at 4000 × g (NF 800 R, Nüve, Türkiye) for 20 min to remove supernatants for the analysis. A spectrophotometer (UV-1700, Shimadzu, Japan) was used for all measurements. Tissue protein concentrations were calculated by the Lowry method [10]. Superoxide dismutase (SOD) activity was determined by using a method described by Sun et al. [11] and GSH level was measured as described by Koyuncu et al. [12]. Tissue total antioxidant status (TAS) and total oxidant status (TOS) were measured with an autoanalyzer (Cobas Integra 800, Roche) using commercially available kits (Rel Assay Diagnostics kit; Mega Medical, Gaziantep, Türkiye) by means of a method developed by Erel et al. [13]. Oxidative stress index (OSI) was calculated using the formula  $OSI = TOS/TAS$ . Tissue lipid hydroperoxide (LPO) levels were measured by using commercially available kits (LPO Assay Kit, Item No. 705003, Cayman Chemical Company, Ann Arbor, USA). Levels of 8-Hydroxydeoxyguanosine (8-OHdG), an indicator of oxidative-dependent DNA damage, were

measured by using OXISELECT Oxidative DNA damage ELISA Kit (Cell Biolabs, San Diego, CA). Spectrophotometric measurement of advanced oxidation protein products (AOPP) was carried out by using a method described by Witko et al. [14]. Tissue caspase-3 levels were measured with a Caspase-3 ELISA kit designed for rats (BioSource Europe S.A., Nivelles, Belgium). TNF- $\alpha$  and IL-6 levels were measured in duplicate using ELISA kits (BioSource Europe S.A., Nivelles, Belgium) in accordance with the manufacturer's instructions. Myeloperoxidase (MPO) activity was determined by using a method described by Krawisz et al. [15]. Total thiol levels were measured with Total Thiol Assay Kit.

#### Statistical analysis

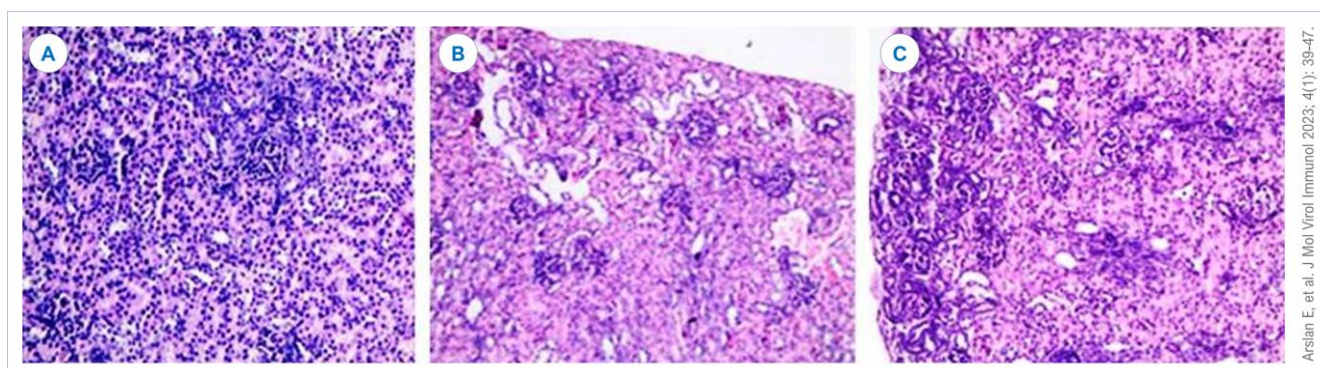
SPSS statistical program (v20.0, IL, USA) was used for statistical analysis. Data was expressed as mean  $\pm$  standard deviation (SD) and median-interquartile range (IQR). Biochemical and pathological parameters were analyzed by appropriate post hoc tests involving Analysis of Variance (ANOVA) and multiple comparison test [Fisher's Least Significant Difference (LSD)]. Statistical analyses for pathological scores of renal

IRI and IRI+Dxp groups were performed in ranks, by using Kruskal Wallis or one-way ANOVA. Mann-Whitney non-parametric test was used for independent samples in the comparisons between two groups.

Differences were considered statistically significant for p value <0.05. Power analysis was performed, and 16 animals were found to be sufficient in each group to obtain a test power of 80% with the effect size=0.80,  $\alpha$ =0.05,  $\beta$ =0.20 values.

#### Results

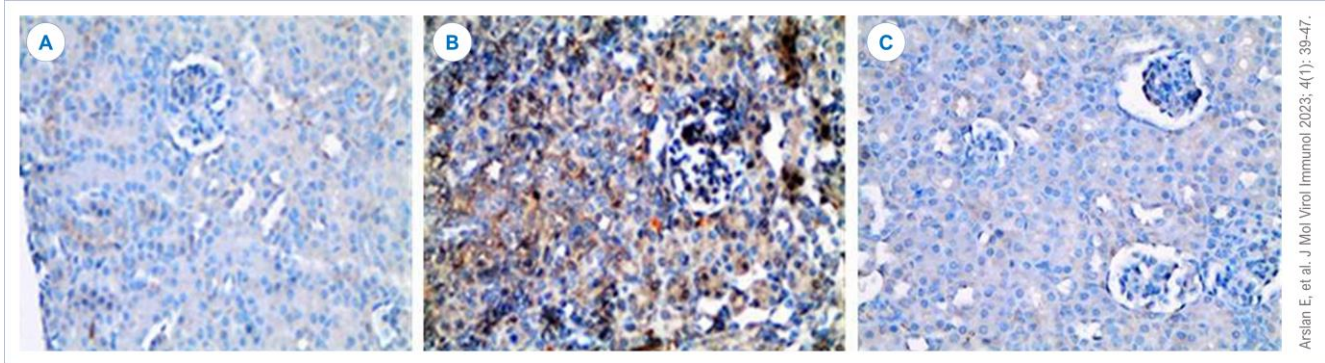
Mortality was lower, although not statistically significant in the IRI+Dxp group (n=3; 18.8%) compared to the IRI group (n=6; 37.5%) (p=0.216). Kidney parenchyma and tubular damage was significantly lower in IRI+Dxp group when compared to the IRI group (p<0.05) (Table 1, Figure 1). Dxp application was also found to significantly decrease oxidative stress and inflammation in IRI following biochemical marker analysis (Table 2). Immunohistochemical analysis showed decreased Caspase-3 positive cell numbers as well as apoptosis (p<0.05) (Table 1, Figure 2).



**Figure 1.** (A) Controls: Normal histology. (B) Renal Ischemia Reperfusion Injury (IRI): IRI- increased renal tubular damage in kidney, swelling in tubule epithelium, brush-border loss, interstitial widening, vacuole degeneration, necrotic tubules, cast formation and desquamation. (C) Renal ischemia reperfusion with dexpanthenol treatment: Renal tubular damage decreased following the treatment with dexpanthenol. All figures hematoxylin-eosin stained, 200 $\times$ .

Variables	Control (n=16)	IRI (n=16)	IRI+dexpanthenol (n=16)	P
Death (n / %)	0	6 / 37.5	3 / 18.8	0.216*
Histopathologic score; median (IQR)	1(0)	3(2)	2(1)	0.023
Caspase-3-positive cell (%)	0.5	17.3	8.2	0.001

IRI; Ischemia Reperfusion Injury. IQR; Interquartile range. \*IRI and IRI+dexpanthenol (Fisher's exact test 2 $\times$ 2)



**Figure 2.** (A) Controls: Minimal staining in control group. (B) Renal Ischemia Reperfusion Injury (IRI): IRI - caspase-3 positive cell density increased in the kidney, renal tubules and parenchyma. (C) Renal Ischemia Reperfusion with dexpanthenol treatment: Caspase-3 positive cell density decreased following treatment with dexpanthenol. All figures caspase-3 stained, 200 $\times$ .

**Table 2.** Biochemical results on kidney tissues and serum samples.

Variables	Controls (n=16)	IRI (n=10)	Dexpanthenol (n=13)	p
TAS (mmol Trolox equivalent/g protein)	9.23 $\pm$ 0.91	3.13 $\pm$ 0.51	6.34 $\pm$ 0.82	<0.001
TOS ( $\mu$ mol H <sub>2</sub> O <sub>2</sub> equivalent/g protein)	5.77 $\pm$ 1.95	53.67 $\pm$ 16.67	29.32 $\pm$ 5.33	<0.001
OSI (Arbitrary Units)	0.65 $\pm$ 0.21	18.36 $\pm$ 6.48	4.76 $\pm$ 1.65	<0.001
GSH (nmol/g)	13.78 $\pm$ 3.89	4.34 $\pm$ 1.94	8.98 $\pm$ 1.57	<0.001
AOPP (ng/mg protein)	4.87 $\pm$ 1.76	21.44 $\pm$ 6.83	13.45 $\pm$ 5.56	<0.001
Lipid hydroperoxide (nmol/L)	0.376 $\pm$ 0.0651	1.57 $\pm$ 0.622	0.86 $\pm$ 0.32	<0.001
8-OHdG (ng/ml)	1.67 $\pm$ 0.51	9.47 $\pm$ 1.87	4.57 $\pm$ 1.89	<0.001
Total thiol ( $\mu$ mol/L)	0.984 $\pm$ 0.265	0.186 $\pm$ 0.132	0.657 $\pm$ 0.064	<0.001
MPO (ng/mg protein)	23.49 $\pm$ 10.76	183.54 $\pm$ 40.51	87.56 $\pm$ 18.37	<0.001
TNF- $\alpha$ (pg/mg protein)	32.31 $\pm$ 6.2	189.5 $\pm$ 29.7	79.34 $\pm$ 15.5	<0.001
IL-6 (pg/mg protein)	16.8 $\pm$ 4.9	97.8 $\pm$ 18.1	35.9 $\pm$ 8.4	<0.001
Caspase-3 (ng/g protein)	9.2 $\pm$ 3.5	79.4 $\pm$ 12.6	30.6 $\pm$ 6.9	<0.001
NFR2 (pg/mg protein)	128.32 $\pm$ 33.56	269.65 $\pm$ 17.56	495.26 $\pm$ 64.28	<0.001
Hsp70 (ng/mg protein)	136.65. $\pm$ 39.37	534.57 $\pm$ 55.34	296.71 $\pm$ 42.21	0.002
Serum creatinine ( $\mu$ mol/L)	48.89 $\pm$ 7.02	158.45 $\pm$ 41.26	69.35 $\pm$ 5.34	<0.001
Serum BUN (mmol/L)	12.56 $\pm$ 3.45	49.6 $\pm$ 5.78	24.3 $\pm$ 6.3	0.001

TAS; Tissue total antioxidant status. TOS; Total oxidant status. OSI; Oxidative stress index. GSH; Glutathione. AOPP; Advanced oxidation protein products. 8-OHdG; 8-Hydroxydeoxyguanosine. MPO; Myeloperoxidase. NFR2; nuclear factor erythroid 2-related factor 2. Hsp70; Heat shock protein 70. IRI; Ischemia reperfusion injury. BUN; Blood urea nitrogen. TNF; Tumor necrosis factor.

## Discussion

Acute renovascular obstruction is a challenging clinical condition posing difficulties in diagnosis, which can be identified following a thorough examination based on clinical suspicion [16,17]. Treatment options for revascularization following renovascular occlusion include medical treatment, angioplasty, and open surgery. However, renal parenchymal damage continues to develop until the treatment begins. Moreover, reperfusion injuries after the removal of occlusion can cause increased tissue damage. The main culprit of these injuries are free oxygen radicals.

All tissues continuously produce an amount of free oxygen radicals. However, as they are low in volume, they can be removed by enzymatic antioxidant systems within tissues such as SOD, CAT, and GSH-Px [18]. During IRI, activated neutrophils migrate towards the inflamed region and increase tissue damage by producing and expressing reactive oxygen products, as well as secreting some toxic enzymes such as myeloperoxidase (MPO) [19]. Lipid peroxidation is a chemical process, which is initiated by free radicals, causing oxidation of polyunsaturated fatty acids on membrane phospholipids and

damaging cellular structure and functions by changing membrane lipid structures [20].

Dxp is the alcohol analogue of pantothenic acid, which is a member of B-complex vitamins [21]. Protective properties of pantothenic acid and its derivatives against cellular damage caused by reactive oxygen radicals were shown in a number of studies previously [6,7,9]. Pantothenic acid causes an increase in cellular CoA content and also intracellular ATP and GSH synthesis [7,9]. Recent studies also showed its anti-inflammatory effects and lipid peroxidation decreasing properties as well [21–24]. There are a number of studies which show the protective effect of Dxp for ischemia and reperfusion injury. One of those studies was conducted by Etensel et al. [24], in which they reported decreased testicular injury and lipid peroxidation in experimental testicular ischemia reperfusion injuries. Another study by Slyshenkov et al. reported that Dxp protected rats against some of the harmful effects of gamma radiation [6]. Authors also reported that Dxp protected jurkat cells against ultraviolet rays [6]. As opposed to those studies, Etensel et al. [24], studying the effects of Dxp on renal ischemia reperfusion reported that, even though biochemical parameters showed that there was a protective effect on antioxidant mechanisms within the tissue, it was not statistically significant and therefore, Dxp had no protective effect in renal ischemia reperfusion injuries.

In our experimental study, we assessed biochemical and pathological parameters of controls, renal IRI and renal IRI+Dxp groups. In pathological assessment, control group showed normal histology whereas IRI group showed increased renal tubular damage within kidney, swelling in tubule epithelium, loss of brush-border, interstitial expansion, vacuolar degeneration, necrotic tubules, cast formation and desquamation. Renal tubular damage was decreased in IRI+Dxp treatment group. When Caspase-3 activity was assessed, the control group showed minimal staining. The IRI group showed an increased concentration of caspase-3 positive cells within renal tubules and parenchyma cells within the kidney. However, a significant decrease in caspase-3 positive cell concentration was seen in IRI+Dxp group. TOS and OSI, which

shows increased oxidative stress, was significantly lower in IRI+Dxp group when compared to IRI, yet still high when compared to the control group. This shows us that although Dxp was able to decrease renal damage by lowering oxidative stress, it was not able to turn it back to its original state completely. In our study, we found an increase in total oxidant capacity and lipid hydroperoxides, while a decrease in total thiol and antioxidant capacity as well as in GSH, Nfr2 in renal parenchymal tissue. There was also a decrease in AOPP, 8-OHdG, MPO, and Hsp70 levels. There was an increase in the levels of TNF-alpha and IL-6, inflammatory system indicators, and caspase-3, apoptosis indicator. Antioxidant defense systems such as reduced GSH and thiol were significantly decreased in renal parenchymal tissue, whereas OSI index and oxidative stress as well as indicators of oxidative stress (Lipid hydroperoxide, 8-OHdG, AOPP, Nfr2, MPO, Hsp70) were found to be statistically significantly higher. Oxidative stress parameters and antioxidant capacity improved in the Dxp treatment group. In the meantime, caspase-3, apoptosis indicator, regressed by treatment. It was shown that Dxp treatment reduced oxidative stress and displayed anti-inflammatory and anti-apoptotic effects. In addition to all these, a decrease in mortality was also shown.

Dxp, which is used as an epithelizing and cicatrizing agent, was also shown to have anti-inflammatory and lipid peroxidase-decreasing properties in recent studies [21–24]. TNF- $\alpha$  and IL-6 are pro-inflammatory cytokines. In renal tissues, MPO, IL-6, TNF- $\alpha$  levels and other parameters indicating neutrophil infiltration and inflammation displayed a significant increase compared to other groups in the IRI group.

Tissue MPO, IL-6, TNF- $\alpha$  levels were significantly lower in IRI+Dxp group and those results showed us that Dxp treatment caused decreased neutrophil infiltration/inflammation. In the IRI group, IL-6 and TNF- $\alpha$  levels were significantly higher compared to controls and IRI+Dxp group, yet the rates treated with Dxp showed significantly decreased tissue IL-6 and TNF- $\alpha$  levels compared to the IRI group. All those parameters indicate that the inflammatory

processes which cause renal damage due to renovascular occlusion can be minimized using Dxp. This effect may also be related to the nuclear factor erythroid 2-related factor 2 (Nrf2)-antioxidant response element (ARE) pathway. The Nrf2-ARE pathway regulates oxidative stress by modulating the expression of hundreds of antioxidants and detoxifying genes [25,26]. This, as a result, can decrease the risk for renal insufficiency. In physiological conditions, there is an equilibrium between ROS formation and their elimination by the antioxidant system, especially by the SOD, glutathione peroxidase, catalase, and thiol group antioxidant system [27-29]. GSH plays a role in the final removal of detoxified oxidation products from the cell [9,28,29]. In addition to their function as a reactive oxygen species (ROS) scavenger, thiol and GSH are involved in various metabolic functions such as DNA repair, activation of transcription factors, cell cycle regulation, modulation of calcium homeostasis, and regulation of enzyme activities [9,28-31]. In the literature, pantothenic acid (PA) and its derivatives were reported to have a protective effect against the cell damage induced by ROS [9,30]. Pantothenic acid also prevents impairment of mitochondrial membrane potential and regulates ATP synthesis [7]. Dxp, a derivative of PA, stabilizes the endogenous antioxidant level by adjusting thiol and GSH activity [7-9,18]. In a study [32], the effects of Dxp treatment were investigated in adult rats with cerebral ischemia-reperfusion. Dxp treatment was noted to produce an antioxidant effect by increasing the reduced glutathione in cells, which might be associated with intracellular CoA increase. In our study too, thiol and GSH activities significantly decreased in

the IRI+Dxp group. And antioxidant capacity improved with Dxp treatment. 8-hydroxydeoxyguanosine (8-OHdG) is a sensitive biomarker of oxidative stress, as one of the most abundant among the oxidative products of DNA [33,34]. It can manifest oxidative DNA damage, even at extremely low levels [33]. Advanced oxidation protein products (AOPP) include dityrosine and cross-linking protein products [34]. And AOPPs are recognized as oxidative stress biomarkers in some neuroinflammatory diseases seen in adults [34]. Likewise, Heat Shock Protein (Hsp) is found in all organisms and in all cell types. Hsp is expressed by cells in response to various stress factors including hypoxia-ischemia as well as high temperature, free radicals, stress, toxins [35]. 8-hydroxydeoxyguanosine (8-OHdG) and Advanced Oxidation Protein Products (AOPP), as the markers of oxidative stress, were also evaluated in this study. In our study, 8-OHdG and AOPP levels were found to be decreased in the IRI+Dxp group with respect to the IRI group. Similarly, in our study, Dxp treatment decreased hsp levels with respect to the IRI group.

### Conclusion

In conclusion, when we assessed all the data in our study, we were able to show that Dxp had antioxidant, anti-inflammatory, anti-apoptosis and cytoprotective properties protecting the kidney following renal damage caused by renovascular occlusion. Dxp can be a treatment option to provide more time for other treatment models, in addition to alleviating functional impairment in kidneys, by decreasing post-IRI renal damages. However, further studies are required to clarify the renal protecting effect of Dxp.

**Conflict of interest:** The authors declare that there is no conflict of interest. The authors alone are responsible for the content and writing of the paper. **Financial disclosure:** There is no financial support to this study.

### References

1. Aktan ÖA, Yalçın SA. Ischemia-reperfusion injury, reactive oxygen metabolites and the surgeon. *Turk J Med Sci* 1998; 1-5.
2. Guneli E, Cavdar Z, Islekel H, Sarioglu S, Erbayraktar S, Kiray M, et al. Erythropoietin protects the intestine against ischemia / reperfusion injury in rats. *Mol Med* 2007; 13(9-10): 509-17. [[Crossref](#)] [[PubMed](#)]
3. Mallick IH, Yang WX, Winslet MC, Seifalian AM. Pyrrolidine dithiocarbamate reduces ischemia-reperfusion injury of the small intestine. *World J Gastroenterol* 2005; 11(46): 7308-13. [[Crossref](#)] [[PubMed](#)]
4. Loftus EV Jr, Tremaine WJ, Nelson RA, Shoemaker JD, Sandborn WJ, Phillips SF, et al. Dexpantenol

enemas in ulcerative colitis: a pilot study. *Mayo Clin Proc* 1997; 72(7): 616-20. [[Crossref](#)] [[PubMed](#)]

**5.** Abiko Y, Tomikawa M, Shimizu M. Enzymatic conversion of pantothenylalcohol to pantothenic acid. *J Vitaminol (Kyoto)* 1969; 15(1): 59-69. [[Crossref](#)] [[PubMed](#)]

**6.** Slyshenkov VS, Piwocka K, Sikora E, Wojtczak L. Pantothenic acid protects jurkat cells against ultraviolet light-induced apoptosis. *Free Radic Biol Med* 2001; 30(11): 1303-10. [[Crossref](#)] [[PubMed](#)]

**7.** Slyshenkov VS, Dymkowska D, Wojtczak L. Pantothenic acid and pantothenol increase biosynthesis of glutathione by boosting cell energetics. *FEBS Lett* 2004; 569(1-3): 169-72. [[Crossref](#)] [[PubMed](#)]

**8.** Jessop CE, Bulleid NJ. Glutathione directly reduces an oxidoreductase in the endoplasmic reticulum of mammalian cells. *J Biol Chem* 2004; 279(53): 55341-7. [[Crossref](#)] [[PubMed](#)]

**9.** Wojtczak L, Slyshenkov VS. Protection by pantothenic acid against apoptosis and cell damage by oxygen free radicals--the role of glutathione. *Biofactors* 2003; 17(1-4): 61-73. [[Crossref](#)] [[PubMed](#)]

**10.** Lowry OH, Rosebrough NJ, Farr AL, Randall RJ. Protein measurement with the Folin phenol reagent. *J Biol Chem* 1951; 193(1): 265-75. [[PubMed](#)]

**11.** Sun Y, Oberley LW, Li Y. A simple method for clinical assay of superoxide dismutase. *Clin Chem* 1988; 34(3): 497-500. [[PubMed](#)]

**12.** Koyuncu I, Kocyigit A, Gonel A, Arslan E, Durgun M. The Protective Effect of Naringenin-Oxime on Cisplatin-Induced Toxicity in Rats. *Biochem Res Int* 2017; 2017: 9478958. [[Crossref](#)] [[PubMed](#)]

**13.** Erel O. A new automated colorimetric method for measuring total oxidant status. *Clin Biochem* 2005; 38(12): 1103-11. [[Crossref](#)] [[PubMed](#)]

**14.** Witko-Sarsat V, Gausson V, Nguyen AT, Touam M, Drüeke T, Santangelo F, et al. AOPP-induced activation of human neutrophil and monocyte oxidative metabolism: a potential target for N-acetylcysteine treatment in dialysis patients. *Kidney Int* 2003; 64(1): 82-91. [[Crossref](#)] [[PubMed](#)]

**15.** Krawisz JE, Sharon P, Stenson WF. Quantitative assay for acute intestinal inflammation based on myeloperoxidase activity. Assessment of inflammation in rat and hamster models. *Gastroenterology* 1984; 87(6): 1344-50. [[PubMed](#)]

**16.** Thomas DP, Roberts HR. Hypercoagulability in venous and arterial thrombosis. *Ann Intern Med* 1997; 126(8): 638-44. [[Crossref](#)] [[PubMed](#)]

**17.** Rosendaal FR. Risk factors for venous thrombotic disease. *Thromb Haemost* 1999; 82(2): 610-9. [[PubMed](#)]

**18.** Aguilar A, Alvarez-Vijande R, Capdevila S, Alcobarro J, Alcaraz A. Antioxidant patterns (superoxide dismutase, glutathione reductase, and glutathione peroxidase) in kidneys from non-heart-beating-donors:

experimental study. *Transplant Proc* 2007; 39(1): 249-52. [[Crossref](#)] [[PubMed](#)]

**19.** Mallick IH, Yang W, Winslet MC, Seifalian AM. Ischemia-reperfusion injury of the intestine and protective strategies against injury. *Dig Dis Sci* 2004; 49(9): 1359-77. [[Crossref](#)] [[PubMed](#)]

**20.** Ayala A, Muñoz MF, Argüelles S. Lipid peroxidation: production, metabolism, and signaling mechanisms of malondialdehyde and 4-hydroxy-2-nonenal. *Oxid Med Cell Longev* 2014; 2014: 360438. [[Crossref](#)] [[PubMed](#)]

**21.** Ebner F, Heller A, Rippke F, Tausch I. Topical use of dexpanthenol in skin disorders. *Am J Clin Dermatol* 2002; 3(6): 427-33. [[Crossref](#)] [[PubMed](#)]

**22.** Biro K, Thaçi D, Ochsendorf FR, Kaufmann R, Boehncke WH. Efficacy of dexpanthenol in skin protection against irritation: a double-blind, placebo-controlled study. *Contact Dermatitis* 2003; 49(2): 80-4. [[Crossref](#)] [[PubMed](#)]

**23.** Romiti R, Romiti N. Dexpanthenol cream significantly improves mucocutaneous side effects associated with isotretinoin therapy. *Pediatr Dermatol* 2002; 19(4): 368. [[Crossref](#)] [[PubMed](#)]

**24.** Etensel B, Ozkısacık S, Ozkara E, Karul A, Oztan O, Yazıcı M, et al. Dexpanthenol attenuates lipid peroxidation and testicular damage at experimental ischemia and reperfusion injury. *Pediatr Surg Int* 2007; 23(2): 177-81. [[Crossref](#)] [[PubMed](#)]

**25.** Ahmed SM, Luo L, Namani A, Wang XJ, Tang X. Nrf2 signaling pathway: Pivotal roles in inflammation. *Biochim Biophys Acta Mol Basis Dis* 2017; 1863(2): 585-97. [[Crossref](#)] [[PubMed](#)]

**26.** Fu C, Zheng Y, Zhu J, Chen B, Lin W, Lin K, et al. Lycopene Exerts Neuroprotective Effects After Hypoxic-Ischemic Brain Injury in Neonatal Rats via the Nuclear Factor Erythroid-2 Related Factor 2/Nuclear Factor-κ- Gene Binding Pathway. *Front Pharmacol* 2020; 11: 585898. [[Crossref](#)] [[PubMed](#)]

**27.** Zhao M, Zhu P, Fujino M, Zhuang J, Guo H, Sheikh I, et al. Oxidative Stress in Hypoxic-Ischemic Encephalopathy: Molecular Mechanisms and Therapeutic Strategies. *Int J Mol Sci* 2016; 17(12): 2078. [[Crossref](#)] [[PubMed](#)]

**28.** Coimbra-Costa D, Alva N, Duran M, Carbonell T, Rama R. Oxidative stress and apoptosis after acute respiratory hypoxia and reoxygenation in rat brain. *Redox Biol* 2017; 12: 216-25. [[Crossref](#)] [[PubMed](#)]

**29.** Ulrich K, Jakob U. The role of thiols in antioxidant systems. *Free Radic Biol Med* 2019; 140: 14-27. [[Crossref](#)] [[PubMed](#)]

**30.** Tang J, Zhang B, Liang S, Wu Y, Feng Y, Guo Z, et al. Effects of pantothenic acid on growth performance and antioxidant status of growing male white Pekin ducks. *Poult Sci* 2020; 99(9): 4436-41. [[Crossref](#)] [[PubMed](#)]

**31.** Singhi S, Johnston M. Recent advances in perinatal neuroprotection. *F1000Res* 2019; 8: F1000 Faculty Rev-2031. [[Crossref](#)] [[PubMed](#)]



- 32.** Zakaria MM, Hajipour B, Khodadadi A, Afshari F. Ameliorating effects of dexpanthenol in cerebral ischaemia reperfusion induced injury in rat brain. *J Pak Med Assoc* 2011; 61(9): 889-92. [[PubMed](#)]
- 33.** Helbock HJ, Beckman KB, Ames BN. 8-Hydroxydeoxyguanosine and 8-hydroxyguanine as biomarkers of oxidative DNA damage. *Methods Enzymol* 1999; 300: 156-66. [[Crossref](#)] [[PubMed](#)]
- 34.** Liu Z, Yao X, Jiang W, Li W, Zhu S, Liao C, et al. Advanced oxidation protein products induce microglia-mediated neuroinflammation via MAPKs-NF- $\kappa$ B signaling pathway and pyroptosis after secondary spinal cord injury. *J Neuroinflammation* 2020; 17(1): 90. [[Crossref](#)] [[PubMed](#)]
- 35.** Lee BS, Jung E, Lee Y, Chung SH. Hypothermia decreased the expression of heat shock proteins in neonatal rat model of hypoxic ischemic encephalopathy. *Cell Stress Chaperones* 2017; 22(3): 409-15. [[Crossref](#)] [[PubMed](#)]