



# Familial Post-Axial Polydactyly of all Limbs in a Neonate

Enebeli Victor, Abhulimen Victor \*

Department of Surgery, University of Port Harcourt Teaching Hospital, Port Harcourt.

Corresponding author: Abhulimen Victor; [victorabhulimen80@gmail.com](mailto:victorabhulimen80@gmail.com)

Received 20 January 2023;

Accepted 08 February 2023;

Published 11 February 2023

## Abstract

**Background:** Polydactyly is a common congenital abnormality of the hands and feet characterized by more than five fingers and toes. Polydactyly is amongst the commonest inherited skeletal conditions. Polydactyly can be familial or sporadic. **Methods:** This article presents a case of familial postaxial polydactyly in a male neonate involving all four limbs seen in our hospital. The mother has history of postaxial polydactyly in both upper limbs consisting only of soft tissue unlike the index patient who has well developed bone on the extra digit. **Conclusion:** Polydactyly is easily diagnosed at birth however earlier diagnosis during the early antenatal period provides an opportunity for counselling, investigation for syndromic associations or familial gene transmission and planning treatment.

**Keywords:** Polydactyly, postaxial, familial, sporadic, congenital, skeletal.

## Introduction

Polydactyly is a common congenital abnormality of the hands and feet characterized by more than five fingers and toes [1-7]. It was first described by Theodor Kerchring in the 17<sup>th</sup> century [3]. Polydactyly is amongst the commonest inherited skeletal conditions seen at birth [1,2,6] occurring in 1 in 500 live birth [7,8]. Polydactyly may be an isolated congenital abnormality or syndromic associated with other congenital anomalies [2,3,5,7,9]. Polydactyly may also be described as familial when there is a family history or sporadic when there is no family history [10]. Several gene mutation has been associated with polydactyly such as GLI3 and SHH (ZRS/SHH enhancer) causing overlapping polydactyly phenotypes [11].

Polydactyly is described as preaxial when the extra digit is on the radial or tibial side, postaxial when the extra digit is on the ulnar or fibular side, and mesoaxial or central that is extra digit involves either the second, third or fourth digit [2-4,8]. Postaxial Polydactyly is the most common form [2] accounting for 75% of cases while central (mesoaxial) polydactyly is very rare [8]. Postaxial Polydactyly is commoner in blacks (Africans and African-Americans) than Caucasians being 10 times higher [6,7]. Other factors associated with polydactyly include African ethnicity, male sex, twinning, parental consanguinity and first-degree relatives [6]

Presence of postaxial polydactyly in Caucasians is usually syndromic [2,6,7] such as Ellis-Van Creveld syndrome and chondroectodermal dysplasia [6]. Postaxial polydactyly in Africans and African Americans is inherited as autosomal dominant while in Caucasians it is inherited as autosomal recessive [7].

Polydactyly can be classified as soft tissue, bone without a joint and complete functioning digit [12]. Polydactyly can be diagnosed during the antenatal period using ultrasonography done between 14 - 16 weeks of gestation [3,13]. Polydactyly can occur in just one limb or all four limbs, presence of polydactyly in all four limbs describe as Hexadactyly, Tetrapolydactyly or Polydactyly 24 is very rare [4,8]. We are unaware of any reported case of Hexadactyly in Port Harcourt. We present a rare case of familial Postaxial Polydactyly in all four limbs with the mother having Postaxial Polydactyly in both upper limbs.

## Clinical History

A 3-week-old Male child presented to our hospital with an extra digit on both hands and feet, this was noticed at birth. Pregnancy was unbooked in any hospital or Clinic. He was delivered in a maternity run by a Nurse. Labour and delivery were uneventful with a birth weight of 4.2kg.

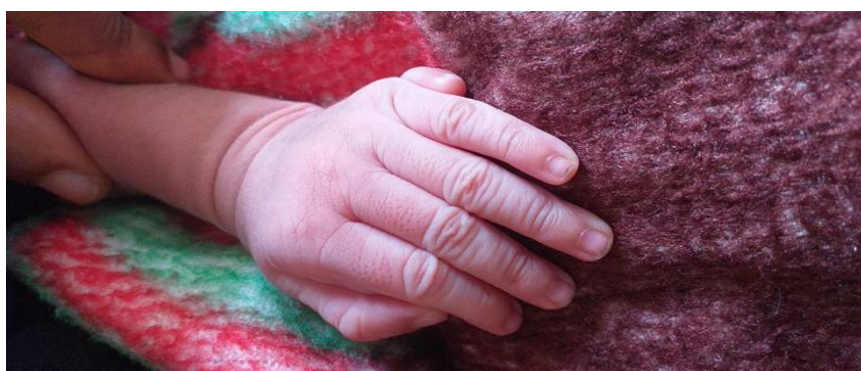
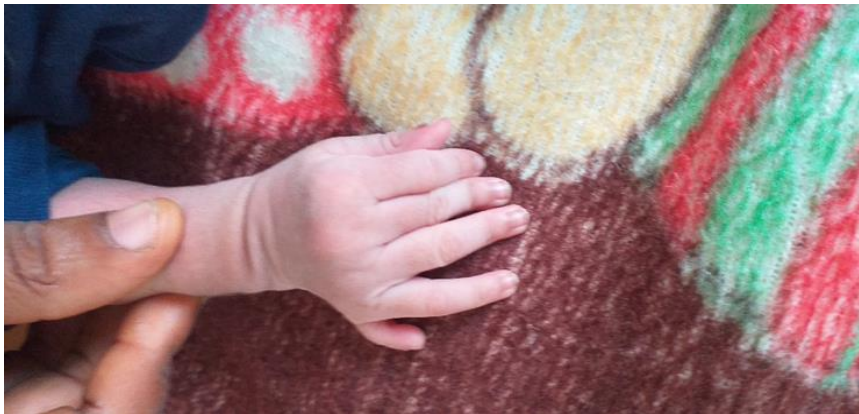
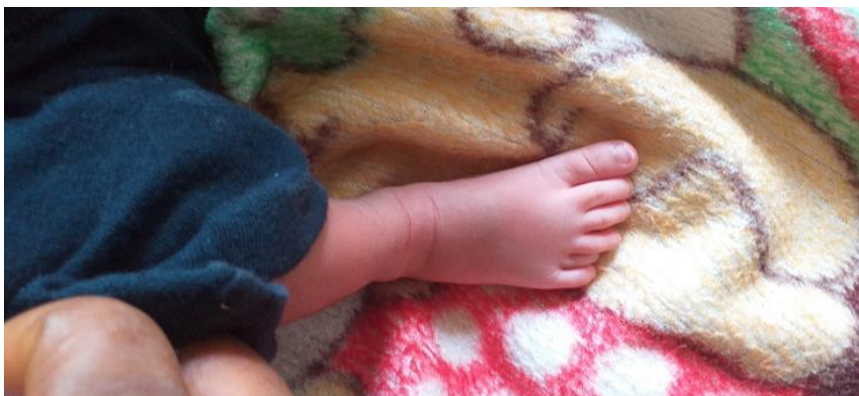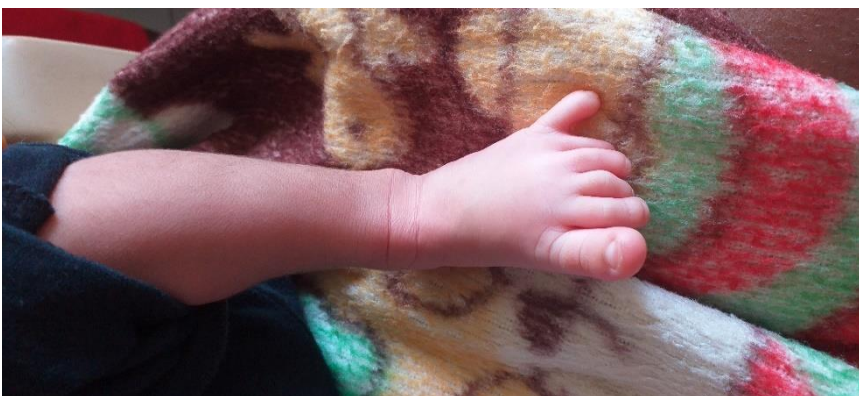Fig. 1 Showing left hand of neonate with six digit



**Fig. 2 Showing right hand of neonate with six digit**



**Fig. 3 Showing right foot of neonate with six digit**

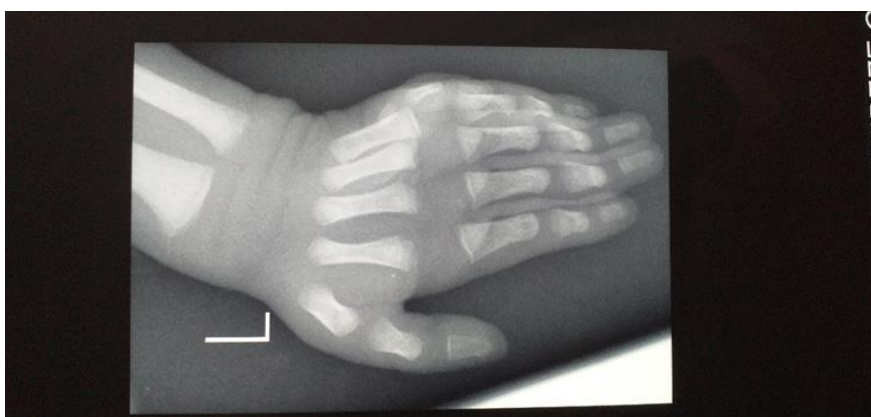


**Fig. 4 Showing left foot of neonate with six digit**

There is a family history of extra digits in the mother. She is a 26-year-old trader who was born with extra digits on both hands which were ligated at the base with sutures until they fell off after some days because there was no bony structure. The mother has two other

children (7 and 5 years). There is no history of an extra digit in her these children or her siblings.

Clinically the child has six digits on both hands and feet with the underlying bone. There were no other congenital abnormalities. Radiographs ordered showed bones and joints on the extra digits.



**Fig. 5 Showing xray of left with fully developed bone on six digit**

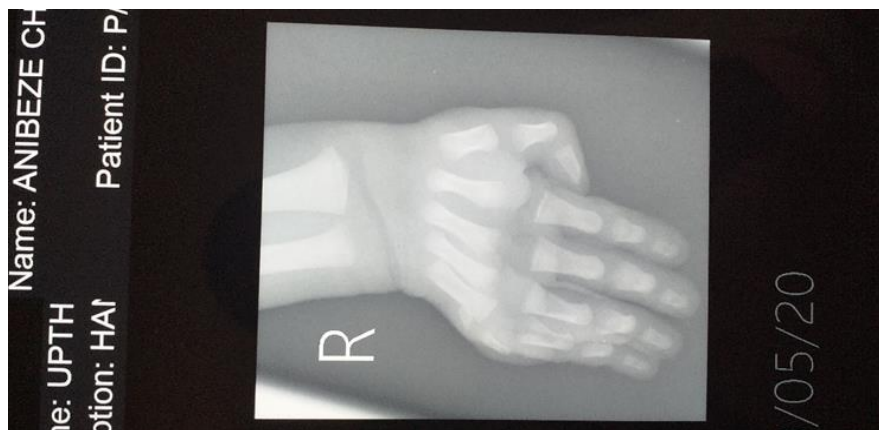

Fig. 6 Showing xray of right hand with fully developed bone on six digit

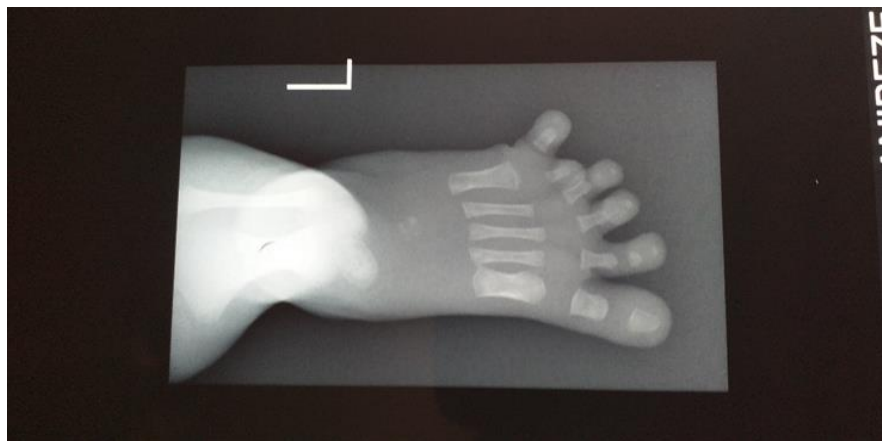


Fig. 7 Showing left foot with fully developed bone on six digit

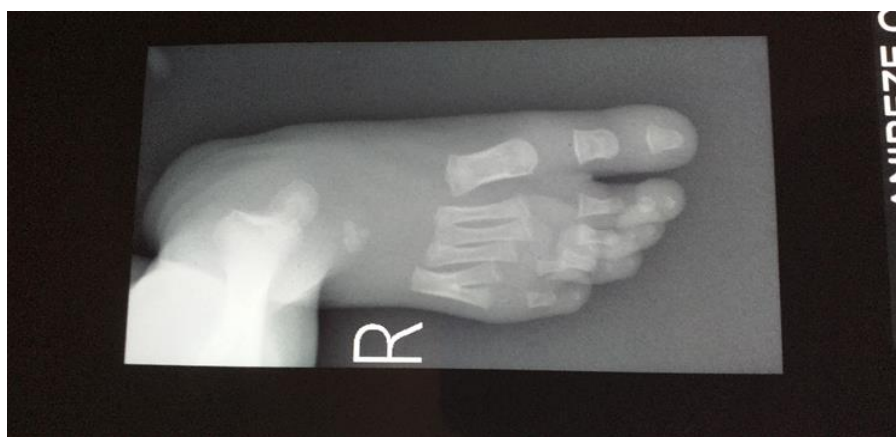

Fig. 8 Showing right foot with fully developed bone on six digit and bifid five metatarsal

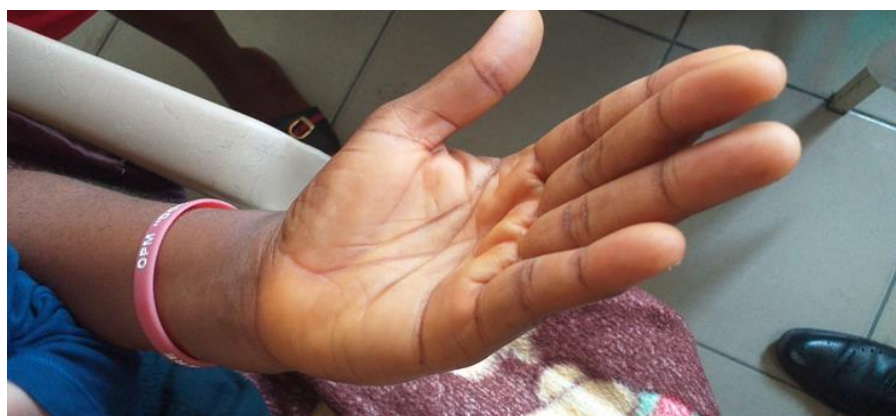
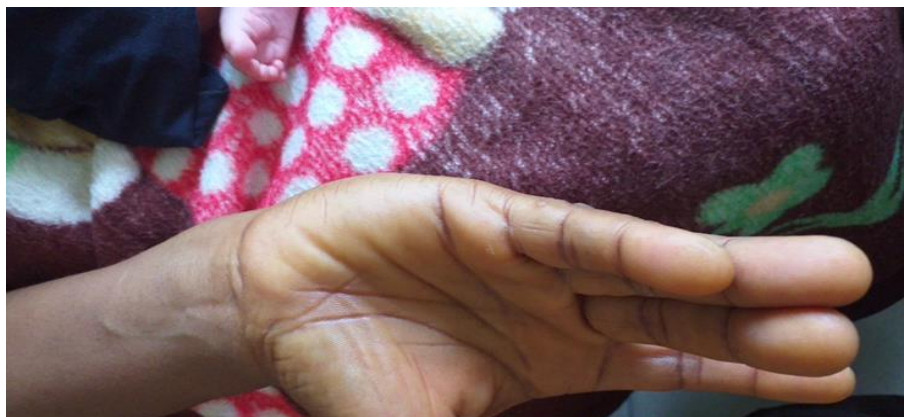
Fig. 9 Mother's left hand with remnant of extradigit on ulnar border of little finger



**Fig. 10** Mother's right hand with remnant of extradigit on ulnar border of little finger

## Discussion

Polydactyly can be diagnosed prenatally [13] and easily at birth however, they occasionally don't affect function in a growing child but the major complaint is cosmetic and finding fitting shoes. There is a psychological impact on the child [10] with the possibility that the child might be bullied at school. Some parents also hold self-guilt that they are responsible for the child's physical deformity as seen in the index case. Attendance at antenatal care provides an opportunity for diagnosis, counselling of parents and also planning treatment for the patient later [1].

Treatment of Polydactyly is corrective surgery by amputation of the duplicated digit when the child is over six months to 2 years at which period general anaesthesia is safer, while the procedure will have minimal effect on development and walking [7].

Most communities in Nigeria treat Polydactyly by application of ligatures around the base of the duplicated digit of the infant until the digit becomes gangrenous and falls off, as was done for the index patient's mother. However, this can only be done for soft tissue Polydactyly hence the index patient with bony structures was brought to the hospital for surgery.

## Conclusion

Polydactyly can be familial. Diagnosis can be done during antenatal care visits and this provides an opportunity for counselling and allays anxiety or self-guilt. Hence efforts should be made to encourage women to attend antenatal care early during pregnancy. Early diagnosis provides an opportunity also for screening for syndromic associations and investigation for inherited gene malformations.

## Conflict of Interest

The authors declare no conflict of interest

## Source of Funding

This was self-funded by the authors

## References

- [1] Mangalgi AS, Sherke AR. Polydactyly 24 - A Case report International Journal of Anatomical variations. 2: 146-149, 2009.
- [2] Oluseyi OA, Atanda, Kola M Owonikoko, Adewale S Adeyemi and Olanrewaju Bajowa. Case Report. Polydactyly 24 in a Female Neonate. Case Reports in Obstetrics and Gynecology. 1-3, 2013.
- [3] Pit Baran Chakraborty, Bani Marjit, Sikha Dutta, Alpna De. Polydactyly: A Case Study. J Anat Soc. India 56(1); 35-38, 2007.

- [4] Uwe Wollina, Shyam B Verma. Sporadic Familial Ulnar Hexadactyly of all four limbs. J Dermatol. 1: 06-10, 2010.
- [5] Muhammad Umair, Farooq Ahmad, Muhammad Bilal, Wasim Ahmad and Majid Alfadhel. Clinical Genetics of Polydactyly: An updated Review. Frontiers in Genetics 9(447): 1-9, 2018.
- [6] Rossi E, Barbieri A, Tamasi S, Pignatiello M, Smaldone MC, Castelli L, Cappabianca and Zeccolini M. Hexadactyly: A Rare Case. Biomed J Sci & Tech Res. 1(4) 1153-1155, 2017.
- [7] Banerjee M, Majumdar SK. Hexadactyly in all four limbs in a neonate – A case report. J Dhaka Med Coll. 22(2): 219-222, 2013.
- [8] Soura Mukherjee, Rudrajit Paul, Manimay Bandyopadhyay and Piyali Das. Post axial Polydactyly in Four limbs with different bony Configurations. Inter J Ana Variation 4: 77-79, 2011.
- [9] Abhulimen V, Gbobo I. Prune Belly Syndrome: A ten-year single tertiary centre experience in South-South, Nigeria. Open Journal of Urology. Vol. 13 No. 1. Jan 2023.
- [10] Chong A. Common Congenital Hand Conditions. Singapore Med J. 51(12): 965-970, 2010.
- [11] Malik S. Polydactyly: Phenotype, genetics and classification. Clin Genet 85: 203-212, 2013.
- [12] Blauth W, Olason AT. Classification of Polydactyly of the hands and feet. Arch Orthop Trauma Surg. 107(6): 334-344, 1988.
- [13] Benjamin I, Johns R, Oseji O, Anderson T, Mercardo F, Arruana V, Yancey J, Bogojevic A, Bainbridge R, Toner L, Gaither K. Polydactyly of the fetal foot: A case report and review of the literature. Journal of the National Medical Association. 114(4):406-411, 2022.



**Open Access** This article is licensed under a Creative Commons Attribution 4.0 International License, which permits use, sharing, adaptation, distribution and reproduction in any medium or format, as long as you give appropriate credit to the original author(s) and the source, provide a link to the Creative Commons license, and indicate if changes were made. The images or other third-party material in this article are included in the article's Creative Commons license, unless indicated otherwise in a credit line to the material. If material is not included in the article's Creative Commons license and your intended use is not permitted by statutory regulation or exceeds the permitted use, you will need to obtain permission directly from the copyright holder. To view a copy of this license, visit <https://creativecommons.org/licenses/by/4.0/>.

© The Author(s) 2023