

Sialolithiasis in The Sublingual Gland: Surgical Treatment

Geovana Aline Batista Cabrera Xavier¹, Erika Regina Stocco Di Francesco², Lidiane Fumiko Takeda³, Cristiano Gaujac⁴, Jones Salustiano Cerqueira⁵ and Irineu Gregnanin Pedron^{6*}

¹Undergraduate Student, Universidade Brasil, São Paulo, Brazil

²Independent Researcher and Private practice, São Paulo, Brazil

³Post-graduation Student, University of California, Los Angeles, USA

⁴Professor, Department of Dentistry, Universidade Federal de Sergipe, Aracaju, Brazil

⁵Professor, Department of Oral Surgery, Universidade Brasil, São Paulo, Brazil

⁶Professor, Department of Periodontology, Implantology, Stomatology and Therapeutics, Universidade Brasil, São Paulo, Brazil

***Corresponding Author:** Irineu Gregnanin Pedron, Professor, Department of Periodontology, Implantology, Stomatology, Integrated Clinic and Therapeutics, School of Dentistry, Universidade Brasil, São Paulo, Brazil.

DOI: <https://doi.org/10.58624/SVOADE.2023.04.0120>

Received: February 08, 2023 **Published:** February 23, 2023

Abstract

Sialolithiasis is relatively common in dental practice. It most commonly affects the major salivary glands, particularly the submandibular glands. Young adults between the third and fourth decades of life are the most affected. The swelling of the oral floor region, caused by salivary retention due to the sialolith within the salivary duct, as well as the observation of its presence by transparency can clinically characterize it. Additionally, radiopaque imaging can determine the final diagnosis. Most of the time, the treatment is surgical. The purpose of this article is to present the case of a patient with painful symptoms caused by a sialolithiasis in the sublingual duct. Surgical removal was performed. The patient has been followed with no signs of recurrence.

Keywords: Salivary Duct Calculi; Salivary Gland Calculi; Oral Surgery; Oral Pathology; Salivary Gland Diseases.

Introduction

Sialolithiasis is relatively common in dental practice, characterized by the presence of salivary calculus or sialolith within the salivary ducts causing obstruction of salivary flow and its retention. The calcified concretions may be present in the glandular parenchyma or ductal system of the major or minor salivary glands. The submandibular salivary glands are most commonly affected¹⁻⁷.

Clinically, sialolithiasis presents swelling of the oral floor, caused by enlargement of the gland, by salivary retention; and reduced salivary flow. Sometimes, purulent discharge may occur when associated with infection, observed near the ductal orifice. These clinical characteristics can cause painful symptoms, especially during meals¹⁻⁹.

The sialoliths are formed by rigid calcified masses; with varied appearance (fusiform, cylindrical or spherical); with yellowish color. It can affect major and minor salivary glands, inside the ducts or in the glandular parenchyma. They are usually solitary, but can be found in the glandular parenchyma in multiple calculi, or bilaterally in Warthon's ducts. They may be symptomatic or not, depending on the other clinical characteristics. The size is variable and may reach 30mm¹⁻⁹.

In the chemical composition of the calculi, organic and inorganic components are observed. Mucopolysaccharides, glycoproteins, lipids, and cellular debris compose the organic portion. The inorganic portion is composed of calcium salts and phosphates (zinc, iron, magnesium and copper) and carbonated apatite^{2,4-9}.

The etiopathogenesis is uncertain. However, predisposing factors such as salivary nature (saliva with a higher rate of mucin), ionic and pH imbalance, anatomical characteristics of the gland and location are known [1,2,4-9]. It is not usually associated with systemic diseases¹⁻⁷.

The purpose of this article is to present the case of a patient with painful symptoms caused by a sialolithiasis in the sublingual duct. Surgical removal was performed. The patient has been followed with no signs of recurrence.

Case Report

An African-descendent male patient, 15-years-old came to the dental clinic with a complaint of oral floor symptoms.

Clinically, a yellowish nodule was observed, underlying the mucosa, hardened and resistant to palpation, with a diagnostic hypothesis of sialolith in the duct of the sublingual gland (Figure 1).

An occlusal radiograph was taken, showing a radiopaque image in the oral floor region, defining the diagnosis of sialolithos (Figure 2).

Surgical removal of the sialolith was recommended. Under local infiltrative anesthesia, a mucosal incision was made over the sialolith, exposing it (Figure 3). A single calculus was easily removed, favoring the retained salivary flow (Figure 4). The mucosa was sutured (Figure 5). The removed fragment (Figure 6) was sent to anatomopathological examination, which confirmed the diagnosis of sialolith.

The suture was removed after 15 days. No post-surgical complaints or complications were reported. Satisfactory healing and normal salivary flow were observed. The patient has been followed with no signs of recurrence.

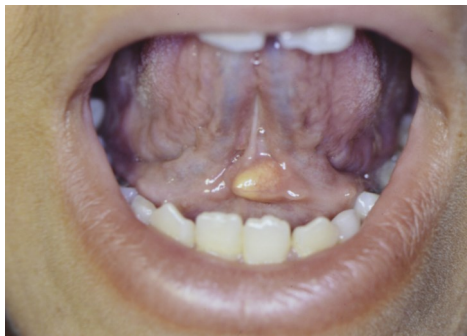

Figure 1: Sialolith located in the duct of the sublingual gland.

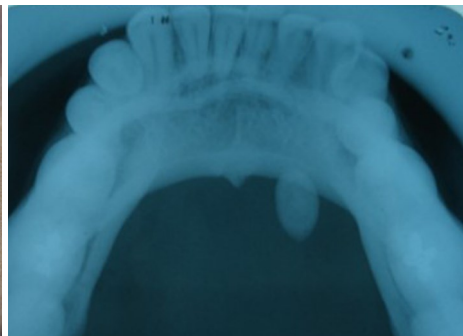


Figure 2: Radiopaque image located in the oral floor.

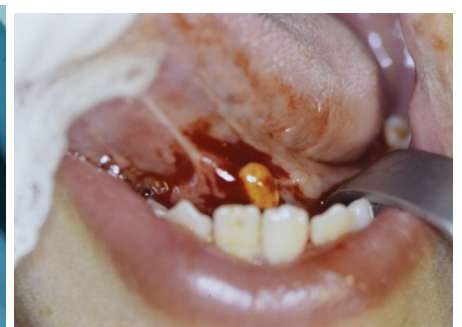

Figure 3: Incision of the mucosa over the sialolith.

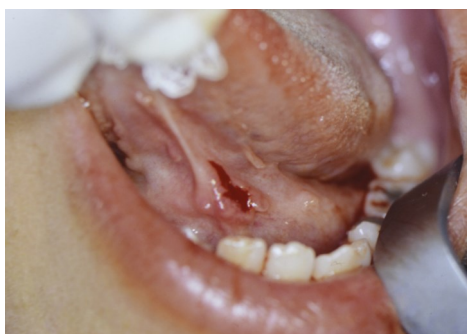

Figure 4: Removal of the sialolith and subsequent salivary flow.

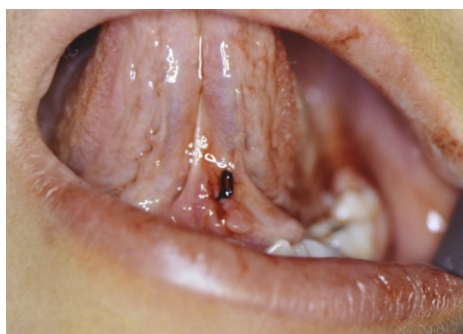

Figure 5: Suture of the surgical wound.

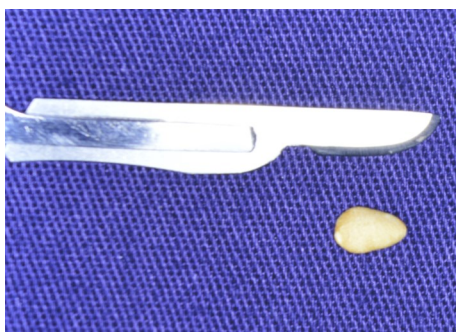


Figure 6: Removed sialolith.

Discussion

The diagnosis of sialolithiasis depends on some tests, but it seems simple. Inspection, palpation and milking of the ductal portion can help in the diagnostic process. The milking has a purpose to evaluate the possible ejection of the calculus from the interior of the duct. Imaging exams such as occlusal radiography and teloradiography (lateral view) can help visualize the sialolith. The occlusal radiograph was used in the present report, elucidating the diagnosis. The image is radiopaque, with defined contours and circumscribed, regardless of where it is located (ductal or parenchymal path of the salivary gland). Panoramic and periapical radiographs are not indicated, because there may be simulation of intraosseous lesions by the superimposition of images, making it difficult to diagnose sialolithiasis. Other imaging tests can be used, such as computed tomography, sialoendoscopy, ultrasound, sialography and scintigraphy. However, their use is discouraged by the high cost^{1-7,9,10}.

The clinical differential diagnosis of sialolithiasis included salivary gland tumors; obstructive sialadenitis; endemic parotitis; calcified lymph node, phleboliths; lymph node tuberculosis with vascular calcifications; mandibular torus; ossifying myositis; and osteoma¹.

The major salivary glands are usually the most affected, ranging from 83 to 90%, followed by the parotid glands (4 to 10%). The sublingual and minor salivary glands are rarely affected (1% to 2%). In the present report, the involvement of the excretory duct of the sublingual gland is observed. Sialolithiasis is usually seen in adults between the ages of 30 and 40 years. In the present report, the patient was in the second decade of life^{1,4-6,11}.

Treatment is most often surgical. However, when the sialolith is in the distal and end portion of the duct, manual milking or stimulation with lemon juice or sialogogues can be employed, which induce increased salivary secretion and favor the expulsion of the sialolith from inside the ductal lumen. When the sialolith is located inside the glandular parenchyma, exeresis of the gland should be considered. Other therapeutic modalities have been employed such as CO₂ laser surgery, shock wave lithotripsy and marsupialization of the duct with placement of catheters inside, with satisfactory post-surgical results. Marsupialization does not promote ductal stenosis or total obstruction of its lumen by fibrous scar tissue [1-3,5,7,9,11]. When the surgical procedure cannot be performed, the application of botulinum toxin has been indicated, reducing saliva production and excretion^{11,12}.

The recurrence rate depends on the type of therapeutic approach employed, ranging from 1 to 10% of cases^{2,7,10}.

Conclusion

Sialolithiasis often affects the submandibular glands. In the present report, we present a case of involvement of the sublingual gland. The age of the patient was also different from that found in the literature. The diagnosis was based on clinical and radiographic features. The surgical approach is the most used, by removing the sialolith. The prognosis is satisfactory and the recurrence rate is low.

Conflict of Interest

The authors declare no conflict of interest.

References

1. Arifa SP, Christopher PJ, Kumar S, Kengasubbiah S, Shenoy V. Sialolithiasis of the Submandibular Gland: Report of Cases. *Cureus* 2019;6;11(3):e4180.
2. Galli P, Ceva A, Foletti JM, Iline N, Giorgi R, Chossegras C, Graillon N. Salivary Gland Lithiasis Recurrence After Minimally-Invasive Surgery: Incidence, Risk Factors and Prevention. *Laryngoscope* 2021;131(4):794-799.
3. Holden AM, C-B Man, M Samani, AJ Hills, M McGurk. Audit of minimally-invasive surgery for submandibular sialolithiasis. *Br J Oral Maxillofac Surg* 2019;57(6):582-586.
4. Kumar ND, Sherubin JE, Bagavathy K. Sialolithiasis: An Unusually Large Salivary Stone. *J Maxillofac Oral Surg* 2021;20(2):227-229.
5. Pachisia S, Mandal G, Sahu S, Ghosh S. Submandibular sialolithiasis: A series of three case reports with review of literature. *Clin Pract* 2019;9(1):1119.
6. Thong HK, Hafiz Mahbob M, Athar PPSH, Kamalden TMIT. Recurrent Submandibular Sialolithiasis in a Child. *Cureus* 2020;12(12):e12163.

7. Ungari C, Cicconetti A, Cerbelli E, Sulpasso A, Filiaci F. Giant submandibular sialolith: a case report. *Clin Ter.* 2022;173(3):217-221.
8. Krishnapura SG, Tomblinson CM, Topf MC. Rate of Submandibular Gland Atrophy Secondary to Chronic Sialolithiasis. *Ear Nose Throat J* 2021;1455613211021178.
9. Thong HK, Othman IA, Ramli R, Athar SH. Painless Giant Submandibular Gland Sialolith: A Case Report. *Cureus.* 2021;13(11):e19429.
10. Koch M, Mantsopoulos K, Müller S, Sievert M, Iro H. Treatment of Sialolithiasis: What Has Changed? An Update of the Treatment Algorithms and a Review of the Literature. *J Clin Med* 2021;11(1):231.
11. Pedron IG. *Toxina botulínica - Aplicações em Odontologia.* Florianópolis: Ed. Ponto, 2016, 195 pages.
12. Douglas JE, W Thomas WW, Wen CZ, Loevner LA, Thaler ER, Chalian AA, Rassekh CH. Sialendoscopy for sialodocholithiasis following submandibular gland excision: six variations on a theme. *World J Otorhinolaryngol Head Neck Surg* 2021;7(4):291-295.

Citation: Xavier GABC, Di Francesco ERS, Takeda LF, Gaujac C, Cerqueira JS, Pedron IG. Sialolithiasis in The Sublingual Gland: Surgical Treatment. *SVOA Dentistry* 2023, 4:1, 16-19.

Copyright: © 2022 All rights reserved by Pedron IG., et al. This is an open access article distributed under the Creative Commons Attribution License, which permits unrestricted use, distribution, and reproduction in any medium, provided the original work is properly cited.