

# MEDICAL SCIENCES

## MUCOCUTANEOUS MANIFESTATIONS IN HIV/AIDS INFECTION

**Badarau Ana Maria,**

*Student, Faculty of General Medicine,  
State University of Medicine and Pharmacy*

*“Nicolae Testemitanu”*

*Republic of Moldova, Chisinau*

**Russu Irina**

*scientific supervisor, doctor of medical sciences, associate professor*

*State University of Medicine and Pharmacy*

*“Nicolae Testemitanu”*

*Republic of Moldova, Chisinau*

### Abstract

**Introduction:** HIV/AIDS infection is continuously progression in the Republic of Moldova, increasing by 51% from 2015 to 2021, thus burdening the health system and other public areas. Considering that most of patients diagnosed with HIV/AIDS develop mucocutaneous manifestations, we aimed to evaluate the frequency of dermatological lesions, their correlation with the clinical stage, respectively the level of CD4+ cells.

**Materials and methods:** the statistical retrospective research included 40 medical records of patients hospitalized in the Dermatological and Communicable Diseases Hospital from 2018 to 2021. The criteria took into consideration was: HIV/AIDS patients confirmed by PCR and 2 rapid tests, age>18 years, presence of mucocutaneous manifestations.

**Results:** From 40 selected patients, 81 dermatological lesions were diagnosed. Of the patients with non-infectious mucocutaneous lesions, there were 22.5%, and the infectious ones were 77.5%. Of the mucosal manifestations, 100% of cases were of oropharyngeal candidiasis, and of the skin, the most relevant was Herpes Zoster infection, diagnosed in 10% of patients. 64% of the lesions had a CD4+ value <200 cells/mm<sup>3</sup>, present in 23 patients (57%).

**Conclusion:** The correlation between CD4+ cell values <200 cells/mm<sup>3</sup> and indicative AIDS infections (cutaneous cryptococcosis, esophageal candidiasis) suggests that fungal infection is an important marker of immunosuppression in HIV/AIDS infected patients.

**Keywords:** HIV/AIDS infection, CD4+ cell, mucocutaneous manifestations

### Introduction

Human immunodeficiency virus is part of Lentivirus genus, Retroviridae family, and causes the acquired Human immunodeficiency syndrome. The targeted receptors for HIV are CD4 cells, in which the virus multiplies, damaging the lymphocytes and subsequently causing immunodeficiency.

In the Republic of Moldova, during 2021 were registered 15428 cases of HIV infected patients, from which 797 were new cases. In comparison, in 2015 were registered 10213 cases, therefore this signifies a 51% increase in incidence that notably affects the health system in Moldova[1].

Dermatological manifestations serve as markers to establish the patient immune status and prevent HIV progression. Subsequently, it is relevant to know the pathophysiology of dermatological lesions occurrence. In epidermis structure there are two distinct cell lines-keratinocytes and melanocytes, and the second line is represented by dendritic cells-melanocytes, Langerhans cells and sensitive Merkel cells [4]. Skin possesses its own immune system, which includes two types of antigen presenting cells- Langerhans cells and dendritic cells. At encounter with an antigen, APCs process and present the antigen to T lymphocytes, and lead to cytokines and chemokines secretion. The CD4+ receptors

are found on Th lymphocytes cellular membrane, as well as on Langerhans epidermal cells [3].

But once the person is infected with HIV virus, there is a decrease in the number and function of Langerhans cells, CD4+ , NK macrophages , monocytes. The contact between CD4+ lymphocytes with HIV 1 pulsatile dendritic cells is followed by a massive replication, which leads to cytolysis of both type of cells. Therefore, compromising the skin immune protective mechanisms leads to an increase in vulnerability to opportunistic infection and neoplasm.

### Aim of the study

Taking into consideration that the majority of HIV positive patients develop mucocutaneous manifestations, the study aims to evaluate the incidence of dermatological lesions, their correlation with clinical stage, CD4+ status [2]. Recognizing these symptoms as presumptive manifestations for HIV/AIDS infection may serve as crucial marker for early diagnosis and treatment of infected patients [3].

### Materials and methods

The study included 40 patients diagnosed with HIV/AIDS infection, registered at the Dermatological and Communicable Diseases Hospital from 2018 to 2021. A retrospective method of statistical research was used, based on the patients medical records. They were

selected based on the predetermined criteria. The criteria took into consideration was: HIV/AIDS patients confirmed by PCR and 2 rapid tests, age >18 years, presence of mucocutaneous manifestations. Patients who did not have laboratory confirmation of HIV/AIDS infection, age <18 years, absence of dermatological lesions were excluded.

The descriptive statistical analysis obtained from the observation forms of patients has been described in

Microsoft Office Excel diagrams and charts. The patients' personal data remains confidential.

#### Rezultate

The age of patients included in the study ranged from 21 to 61 years. The mean age of the patients was 39.77 years.

The distribution of patients by age groups is shown in figure 1. Most patients were aged 31-40 (42%), followed by 41-50 (23%), and those aged 51-61 (20%), and 20-30 had 15% (figure 1).

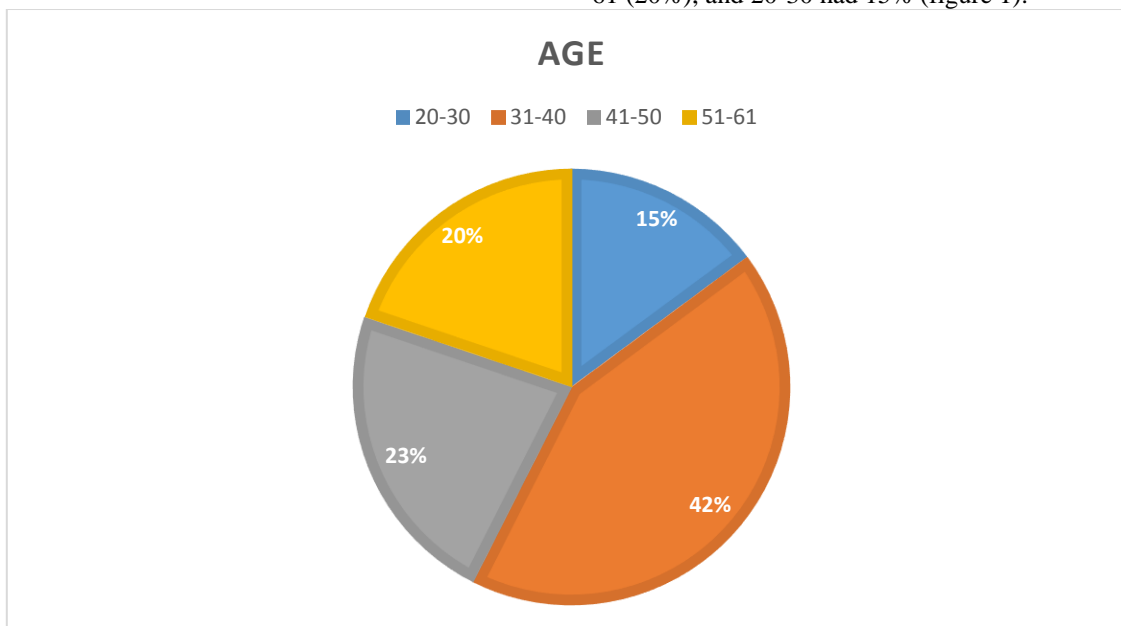


Figure 1. Distribution of patients according to age

In the examined patients, several dermatological manifestations were established which can be classified according to etiology into: viral, mycotic, bacterial and parasitic.

Muco-cutaneous manifestations of viral etiology represented 8.64% of the total number of 81 lesions. Thus, from the viral infections, the Herpes simplex virus was involved, causing a herpetic vesicular dermatitis in 1 patient (3%), the Varicello-Zosterian virus diagnosed in 4 patients (10%) with Zoster, a case of infection with the Molluscum Contagiosum Virus and one patient was diagnosed with villous leukoplakia of the tongue, caused by the Epstein Barr virus.

Mycotic infection caused 59 lesions out of 81 (72.83%). The most frequent mycotic manifestation of the mucous membranes was oropharyngeal candidiasis, present in all patients (100%), followed by vaginal candidiasis - in 11 patients (28%) and esophageal candidiasis - in 4 patients (10%) (figure 2). From the mycotic skin lesions, the following were diagnosed: cutaneous cryptococcosis (3%), pityriasis versicolor

(3%), demodecosis (3%), plant mycosis (5%) (figure 3). 27% of patients had a single mycotic condition - oropharyngeal candidiasis, and 73% of patients were diagnosed with 2 or more mycotic lesions.

Bacterial infections were responsible for 3 lesions (3.7%): pyoderma (3%), erysipelas (3%) caused by group A beta-hemolytic streptococcus (figure 3), and Lyme disease (3%) (figure 3).

Parasitic infections were caused by Sarcoptes scabiei ticks in 2 cases (5%), which corresponds to 2.4% of 81 lesions.

Non-infectious mucocutaneous manifestations have also been reported. Thus, the inflammatory damage to the mucosa was established - acute perirectitis in 3% of cases (figure 2), seborrheic dermatitis - in 8%, thrombocytopenic purpura - in 5% of cases as a reaction to drugs, disseminated psoriasis - in 5% of cases and rosacea acne - in 3% of cases (figure 3). So, inflammatory lesions of non-infectious origin constituted 22.5% of the total number of lesions.

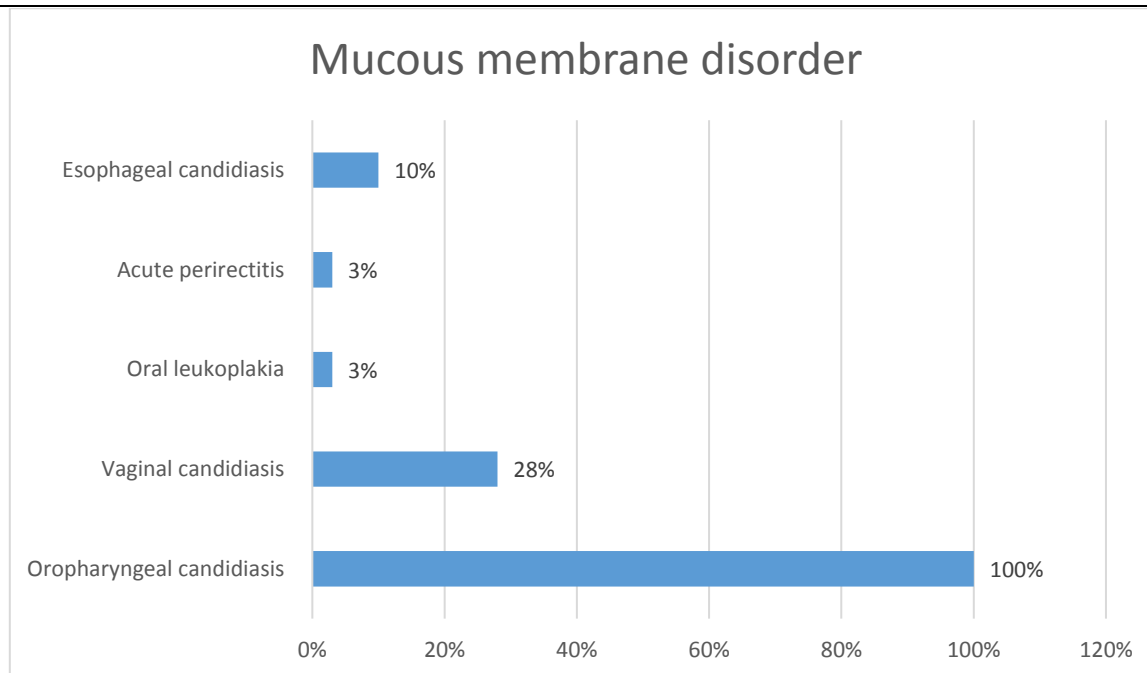


Figure 2. Mucosal manifestations in HIV/AIDS infected patients

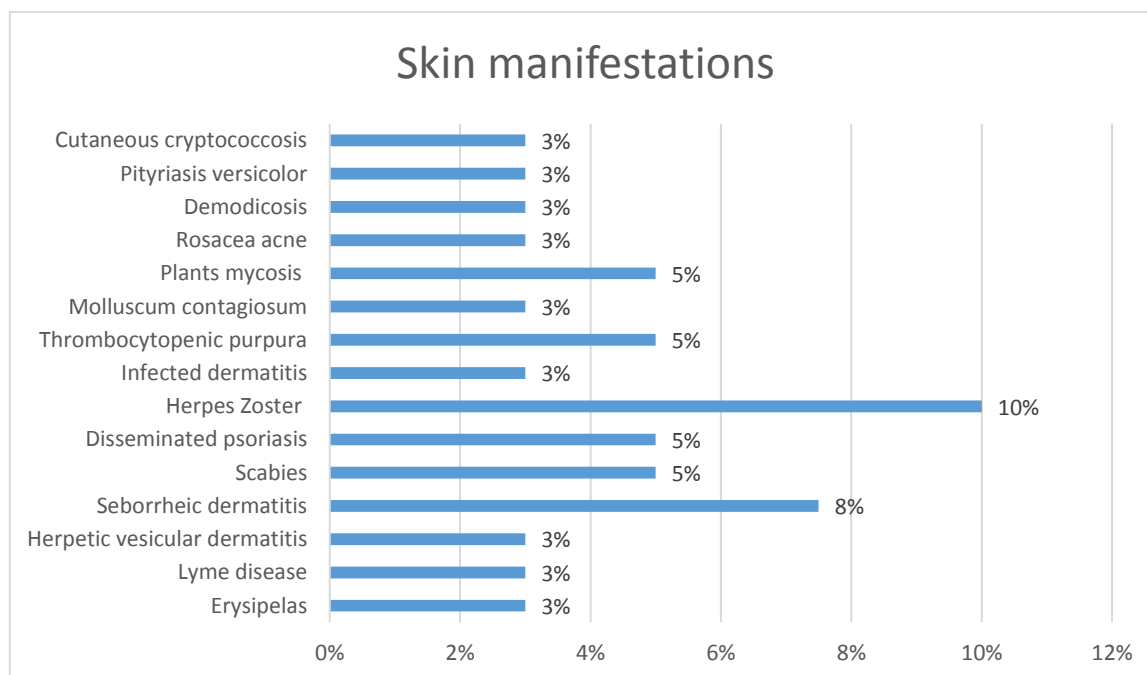


Figure 3. Skin manifestations in HIV/AIDS patients

A correlation was observed between CD4+ level and mucocutaneous manifestations. Thus, we found that the highest percentage of 52 (64%) of the total of 81 lesions were present in 23 patients (57%), who had a CD4+ value <200 cells/mm<sup>3</sup>. It results that each patient is assigned about 2.26 injuries. In 11 patients (27%) with a CD4+ value between 200-500 cel/mm<sup>3</sup>, 14 lesions (17%) were recorded, all of which represented mucosal damage by *C. albicans*. In 6 patients (15%) with a CD4+ level >500 cells/mm<sup>3</sup>, 15 lesions were registered, of which 40% were oropharyngeal candidiasis, 20% - bacterial infection,

33% - fungal infection, other than oropharyngeal candidiasis and 7% - inflammatory manifestations (table 1).

In patients with a CD4+ value <200 cells/mm<sup>3</sup>, viral infections constituted 13%, comprising 100% of all viral infections. Mycotic involvement was found in 35 lesions out of 52 (67%), and 57% of all mycotic infections. Parasitic etiology was present in 2 cases, constituting 3.84% of all lesions with a CD4+ level <200 cells/mm<sup>3</sup>, and 100% of parasitic lesions. The rest of the manifestations were of non-infectious origin, 15.38% of all inflammatory lesions.

Tabel 1.

<b>Mucocutaneous manifestations in HIV/AIDS patients in correlation with the CD4 level</b>			
<b>Nivel CD4+ (cel/mmc)</b>	<b>&lt;200</b>	<b>200-500</b>	<b>&gt;500</b>
<b>Mucocutaneous manifestations</b>			
Erysipelas	0	0	1
Lyme disease	0	0	1
Herpetic vesicular dermatitis	1	0	0
Seborrheic dermatitis	3	0	0
Scabies	2	0	0
Disseminated psoriasis	2	0	0
Herpes Zoster	4	0	0
Infected dermatitis	0	0	1
Thrombocytopenic purpura	1	0	1
Molluscum Contagiosum	1	0	0
Plants mycosis	1	0	1
Rosacea acne	1	0	0
Demodicosis	1	0	0
Pityriasis versicolor	0	0	1
Cutaneous cryptococcosis	1	0	0
Oropharyngeal candidiasis	23	11	6
Vaginal candidiasis	5	3	3
Esophageal candidiasis	4	0	0
Oral leukoplakia	1	0	0
Acute perirectitis	1	0	0
<b>Total nr. of lesions</b>	<b>52</b>	<b>14</b>	<b>15</b>

### Discussion

Mucocutaneous manifestations are very common in patients with HIV/AIDS infection, whether of infectious or non-infectious etiology. These can be either the first signs of immunosuppression or the marker of an unfavorable evolution, therefore, it is important to know these mucocutaneous HIV indicator entities.

In the this study, it was pointed out that the average age for this infection is 39.77 years, prevailing between 31-40 years. Among the manifestations affecting the mucous membranes, the highest proportion was oropharyngeal candidiasis 100%. In a similar study carried out in the Republic of Moldova, V. Gogu, M. Bețiu reported 96% damage to the oral mucosa, in most cases being involved mycotic infection by *C. albicans* [2]. Cutaneous contact, in combination with mucosal contact, was 37%, more compared to the previously mentioned study (21%). The most relevant skin manifestation was Herpes Zoster infection, established in 10% of cases. A similar prevalence was also revealed in the study carried out by Sanín in Colombia, in which Varicello-Zosterian virus infection was recorded in 11.5% of patients [6].

Of the patients with non-infectious mucocutaneous lesions, there were 22.5%, and the infectious ones were 77.5%. Different statistical data were reported in the study by Gogu, in which infectious involvement was reported in 52% of cases [2]. Inflammatory manifestations were probably less often diagnosed during the present study, due to the low addressability to the doctor during the pandemic period, and only the more serious infectious cases led the patients to go to the hospital.

It is important to note that 64% of lesions were present in 23 patients (57%) who had a CD4+ count <200 cells/mmc. These values indicate severe immunosuppression, and viral infections such as Molluscum Contagiosum, Herpes Zoster, villous leukoplakia of the tongue were exclusive to these CD4+ levels. Also, esophageal candidiasis (10%) was reported only in patients with a CD4+ level below 200 cells/mmc. Another skin condition indicative of HIV/AIDS is cutaneous cryptococcosis, which resulted in the death of the patient, who also suffered from esophageal candidiasis, pneumocystis pneumonia, and Herpes Zoster in the recent anamnesis.

### Conclusions

1. Muco-cutaneous manifestations in patients with HIV/AIDS infection are very common, according to the conducted study, affecting the mucous membranes in 100%, and the teguments - in 37% of cases.

2. Mycotic infection constituted 72.83% of all muco-cutaneous lesions, and the most frequent pathology was oropharyngeal candidiasis, established in 100% of patients.

3. Immunodeficiency was an important factor in the occurrence of opportunistic infections and non-inflammatory lesions. Thus, the medical records of the dermatological manifestations correlated with the value of CD4+ lymphocytes below 200 cel/mmc. In 1/2 of the patients, 64% of all lesions were registered, including those indicative of AIDS, such as esophageal candidiasis and cutaneous cryptococcosis.

4. In this way, muco-cutaneous manifestations, especially mycotic infections, become the indirect marker of low immunity, making it possible to identify HIV/AIDS early and to provide a certain prognosis in relation to life expectancy in these patients.

### References

1. <https://ansp.md/situatia-epidemiologica-prin-infectia-cu-hiv-masurile-de-control-si-raspuns-anul-2021/>
2. Vladislav GOGU , Mircea BEȚIU , Lucia PÂRȚĂNĂ , Angela NAGĂȚ , Svetlana POPOVICI , Irina CUCEROVA , Tatiana CAIȘÎM , Anna IASINCOVSCAIA , Vasile ȚĂBĂRNĂ. Manifestările cutaneo-mucoase în infecția HIV/SIDA. În: Curierul medical, Iunie 2016, Vol. 59, No 3. <http://hdl.handle.net/20.500.12710/2967>
3. Holban, T., Plăcină, Gh., Cojocaru, S., Iarvoi, L., Cebătorescu, V. Ghid practic Infecția cu HIV: ETIOLOGIE, PATOGENIE, TABLOU CLINIC, DIAGNOSTIC, TRATAMENT, Chișinău 2011 <https://library.usmf.md/sites/default/files/2020-10/Infec-tia%20cu%20HIV%20Etiologie%20Patologie%20Tablou%20clinic%20Diagnostic%20Tratament%202011.pdf>
4. Bețiu M., Dermatovenerologie. Manual pentru studenți. Chișinău 2013, 425p. <https://dermatovenerologie.usmf.md/sites/default/files/inline-files/Dermatovenerologie%20manual.pdf>
5. Cedeno-Laurent F., Gomez-Flores M., Mendez N., Ancer-Rodriguez J., Bryant J., Gaspari A., Trujillo J.. New insights into HIV-1-primary skin disorders. Journal of the International AIDS Society. 2011. Volume 14, Issue 1. p.1-17. <https://doi.org/10.1186/1758-2652-14-5>
6. Sanín AM, Londoño Ángela M, Gil V, Mejía AM, Aguirre HD, Vásquez EM, Valencia C, Cardona C. Manifestaciones mucocutáneas y su relación con el recuento de linfocitos T CD4 en pacientes infectados con el virus de inmunodeficiencia humana hospitalizados en Medellín, Colombia. Biomédica 2022;42:278-89. DOI: <https://doi.org/10.7705/biomedica.6117>

### UPDATES IN ETIOPATHOGENESIS, CYTOLOGICAL AND IMMUNOCYTOCHEMICAL DIAGNOSIS IN LOW-GRADE SQUAMOUS INTRAEPITHELIAL LESIONS OF THE CERVIX (LSIL)

**Capatina Elena,**

*Student, Faculty of General Medicine,  
State University of Medicine and Pharmacy  
„Nicolae Testemitanu”  
Republic of Moldova, Chisinau*

**Tudor Rotaru**

*Associate Professor, Department of Oncology,  
State University of Medicine and Pharmacy  
„Nicolae Testemitanu”  
Republic of Moldova, Chisinau*

### Abstract

#### Introduction:

Low-grade squamous intraepithelial lesions (LSIL) is the primary underlying modification of the development of cervical cancer, and the most important etiological factor is the human papillomavirus. In the Republic of Moldova this diagnosis tends to progress due to an insufficiently developed screening programme.

**Materials and methods:** retrospective and prospective data including medical records of 135 patients admitted to the Oncology Institute of the Republic of Moldova during the period 2017-2021 in which those patients diagnosed with LSIL were detected and studied.

**Results:** Of the 135 patients studied, the prevalence of ASC-US in patients aged 17-26 years was about 18.75%. About 49.63% detected with high-risk HPV types 16, 18, 31, 33, 35, 39, 45, 51, 52, 56, 59, 66, 68. The method most chosen by patients in the diagnostic process was the ThinPrepPap test, about 49% of patients.

**Conclusions:** The incidence of cervical cancer is increasing in developing countries where cervical screening programmes are not yet well organized. The human papillomavirus (HPV) has an affinity for epithelial tissue, especially at sites with lesions, and infection itself depends on changes in the basal layer of the epithelium.

**Keywords:** LSIL, HPV, cervix.

### Introduction

Cervical cancer is one of the most common diseases detected in women with a global distribution, ranking second among malignant neoplasms of the cervix, second only to breast cancer [5]. The condition of development of the malignant process at the level of the cervix, is represented by precancerous changes induced by the infection with human papillomavirus (HPV), generating low-grade intraepithelial lesions (LSIL). However, not all women infected with HPV develop

cervical cancer, as it depends on the immune system of the infected body and the type of HPV genotype.

The papillomavirus genome possesses three regions [7] the short, circular HPV genome encoded by 8 proteins (E1, E2, E4, E5, E6 and E7) and late genes (L1 and L2) [10]. The viral capsid moves HPV into basal squamous cells where it is extended and encoded by L1 and L2 genes. E5, E6 and E7 genes are important for integration into host DNA and uncontrolled activation of oncogenes in basal layer cells [14].