

A Monthly e Magazine
ISSN:2583-2212
February, 2023; 3(02), 158-160

Popular Article

Transmissible venereal tumors (TVT) in dogs and their treatment

S.K. Sheetal*, D. Sengupta and C.S. Azad

Assistant Professor, Department of Veterinary Gynaecology and Obstetrics, Bihar Veterinary College, Bihar Animal Sciences University, Patna, Bihar, India

Transmissible venereal tumors (TVTs) are an excessive and uncontrolled proliferation of histiocyte cells with no defined function. Histiocytes is a type of immune cells which is found in many areas of the body cells including skin. Transmissible venereal tumor (TVT) is a malignant tumor of dogs of both sexes which mostly affect the external genitalia. It is mainly spread reproduction or sexual interactions. This tumor may also be spread through bites, smelling or licking of tumors or affected areas. This tumor is generally seen in young sexually intact and active dogs which roams freely with uncontrolled or arbitrary reproduction. TVTs is found in dogs of any breed, age and sex however most commonly seen in mixed breed or stray dogs.

Canine transmissible venereal tumor has many names which includes Sticker tumor, Contagious venereal tumor, transmissible lymphosarcoma venereal granuloma, infectious granuloma and infectious sarcoma. Transmissible venereal tumours (TVTs) in dogs are varying shaped of cauliflower, in the nodular form, papillary, or with multi-lobulations in appearance. Their size ranges from in the form of a small nodule to a large form. The surface of the TVTs have generally ulceration and inflammation with frequent bleeding. Thus, affected dogs becomes anaemic. TVTs may be single or multiple and are usually located on the genitalia. They found in both male (Photo 1) and female dogs (Photo 2).

Causes

- ✓ Histiocytic cells mutated in their basic genetic materials, which leads to malignancy (Cancerous).
- ✓ The direct contact (sexual contact, licking, biting, and sniffing) with TVT affected dogs leads to spread of TVTs.
- ✓ The high incidence of TVT in stray dog population is due to uncontrolled sexual contacts.

Signs and Symptoms

- ✓ It depends on location of the tumour.
- ✓ If tumour on the penis/prepuce in male or vulva in female, the thickening of the affected tissues seen along with discomfort, intermittent bleeding.
- ✓ Excessive licking of the tumour affected areas.
- ✓ This tumour is also located within the mouth or on the tongue in a cauliflower like growth. There is frequent bleeding and ulceration seen in the tumour.

Diagnosis

- ✓ TVTs is usually diagnosed by Cytology of the tumour cells called TVT cells (Photo 3). Sample is usually taken by swab method or by fine needle aspiration of the tumour directly. Then making of thin slide and staining with Giemsa or Lishman stain gives clear picture of cytology in a microscope.
- ✓ Biopsy or histopathology of the tumour also indicated if not diagnosed properly with cytology.

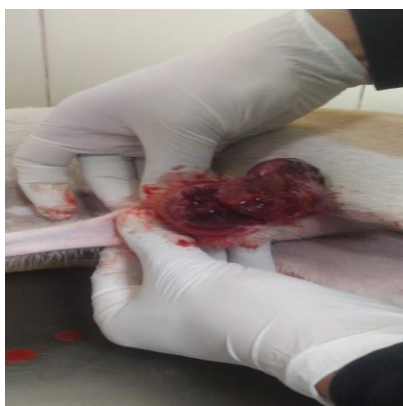

Photo 1: TVT Male Dog

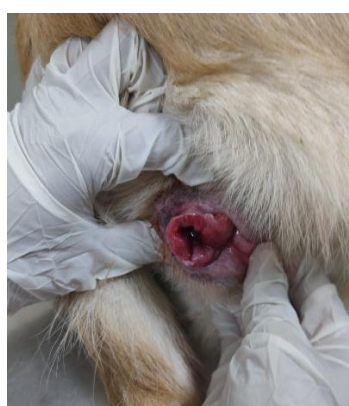

Photo 2: TVT Female Dog

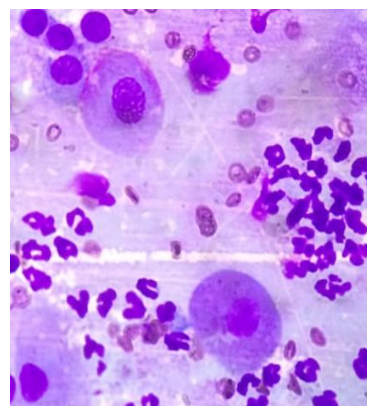


Photo 3: TVT Cells



Treatment

- ✓ The chemotherapy with Vincristin sulphate (@ 0.5–0.7 mg/m², IV, once weekly for 3–6 weeks) is treatment of choice in dogs affected with TVTs.
- ✓ Non responded dogs with above drugs may be tried with Adriamycin (30 mg/m² for dogs weighing >10 kg; 1 mg/kg for dogs weighing ≤10 kg; IV, once every 3 weeks) and radiation therapy.
- ✓ Another treatment for TVTs is complete surgical excision of the tumour. However, it may be difficult due to location or roots of the tumours. More often surgery alone leads to recurrence of the tumours.

Advice to pet owners

Dogs with TVTs spread through direct contact with another one. So isolate the diagnosed dogs until completion of the treatment to avoid transfer of the disease. There is need to educate Pet owners for better compliance and elimination of the tumour from the local areas.

