

SURGICAL MANAGEMENT OF TRAUMATIC MANUBRIO-STERNAL DISLOCATION WITH LOCKING COMPRESSION PLATE: A CASE REPORT AND REVIEW OF LITERATURE

Fareed Shaikh^{*,1}, Syed Shahabuddin*, Haroon Rashid* and Noman Shahzad*

*Department Of Surgery, Aga Khan University Hospital, Karachi, Pakistan.

ABSTRACT Background: Manubriosternal joint dislocation as a result of trauma is rare with only few case reports published in the literature. Materials that have been used for fixation of displaced manubriosternal joint are steel wires, polydioxanone ropes, and plates with screws. **Case:** We present a case of manubriosternal dislocation in which fixation was done with locking compression plate. It is a case of 32 years old lady with a history of road traffic accident; car ran over her chest. She had bilateral lung contusions with multiple rib fractures on right side and manubriosternal joint dislocation of type-I. The patient was initially stabilised in high dependency unit, and once her contusions got better, she underwent fixation of her manubriosternal dislocation with locking compression plate. Post-operatively she remained pain-free and was discharged home. **Conclusion:** This case is an important addition to literature regarding options that can be used for fixation of manubriosternal joint dislocation.

KEYWORDS Manubriosternal joint, Plate fixation, Joint dislocation, Chest trauma

letter from the Institutional Ethical Review Committee was acquired (3368-Sur-ERC-14)

Introduction

Manubrio-sternal dislocation as a result of trauma is rare with only few case reports published in the literature till now [1]. The materials used for fixation of displaced manubrio-sternal joint are steel wires [1], Polydioxanone ropes [2], and Plates with screws [1, 3, 4].

We describe a case of the young lady with traumatic manubrio-sternal dislocation. She underwent fixation with locking compression plate. Informed consent was taken from the patient for reporting the case with images and an exemption

Case Description:

We had a 32 years old woman who presented to our emergency department after sustaining blunt chest trauma as a result of road traffic accident. She was a motorcycle rear seat rider and had a head-on collision with a car. There was no history of loss of consciousness. She was found to be awake, alert and vitally stable. Airway, breathing and circulation were intact. On the subsequent survey, she was found to have a bruise over sternum with a palpable deformity at the manubrio-sternal joint that was tender to touch. Rest of the examination was unremarkable. Her X-Ray chest and CT scan chest revealed multiple bilateral rib fractures, bilateral lung contusions and manubrio-sternal dislocation as shown in **Figure 1**. After initial management at the emergency department, she was kept in intensive care unit (ICU) and later in high dependency unit for the management of lung contusions. Over next four days of conservative management (Pain control, negative balance of fluids, O₂ support and chest physiotherapy) her lung contusions improved. However,

Copyright © 2019 by the Bulgarian Association of Young Surgeons
DOI: 10.5455/IJMRCR.surgical-management-traumatic-manubrio-sternal-dislocation
First Received: March 26, 2017

Accepted: May 09, 2017

Manuscript Associate Editor: George Baytchev (BG)

Editor-in Chief: Cvetanka Hristova (BG)

Reviewers: Atsushi Sano (JP)

¹[Department of Surgery Aga Khan University Hospital, Karachi, Pakistan. Email: fareed.shaikh@aku.edu

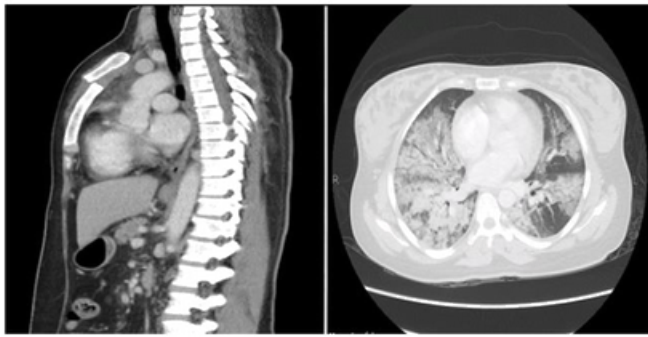


Figure 1: (Left) Sagittal view of CT scan showing manubriosternal dislocation. (Right) Lung window of CT scan showing pulmonary contusions more marked on Right

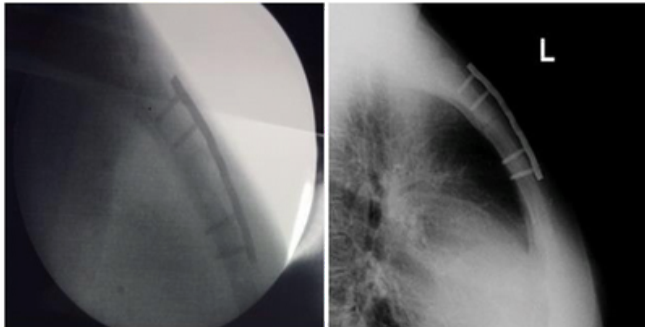


Figure 2: (Left) Post-operative C-arm lateral view of sternal plate. (Right) Lateral view chest x-ray showing sternal plate in place and alignment of fracture.

her sternal pain persisted restricting movement of upper limbs. Manubrio-sternal dislocation being the only factor responsible, it was decided to fix the sternal dislocation.

Under general anaesthesia, in the supine position, the fracture site was approached using a vertical incision in the midline over the palpable deformity. The hematoma was evacuated; the fracture was reduced and fixed using locking compression plate with the help of screws. The length of the screws was predetermined with the support of CT scan as the distance between anterior and posterior cortices of the sternum. Fixation, alignment and position of screws were confirmed using intraoperative fluoroscopy and with lateral radiograph postoperatively **Figure 2**. She had unremarkable post-operative course; her pain improved with a better range of motion in upper limbs. She was discharged home on the third postoperative day. She is pain-free with full range of motion in upper limbs at follow-up in the clinic after six months of surgery.

Discussion:

Traumatic dislocation of manubrio-sternal joint is rare and surgical correction requires an individualised decision. There is limited literature regarding large series regarding surgical fixation. Both wires and plates are being reported to be used with an acceptable outcome. Thirupathi and Husted [5] classified manubrio-sternal dislocations into two; Type-I, the rare variety, is one in which the body of the sternum is displaced posterior to manubrium, whereas, in type-II, the commoner variety, the body is displaced anteriorly. Direct trauma to the chest is the common mechanism involved in type-I, whereas deceleration injuries resulting in hyperflexion of the torso, rheumatoid disease and kyphosis are the predisposing factors for type-II.

There has been a lengthy discussion on conservative vs. sur-

gical treatment for sternal fractures, but due to the rarity of cases and literature, no consensus has been reached at. In general undisplaced fractures are considered for non-operative treatment whereas displaced fractures, persistent pain affecting respiration, chronic non-union and sternal instability are the primary indications for surgical fixation as reported by Harston A et al.[6].

In our patient, the manubrium was anteriorly displaced categorising it to be type I and the mechanism were a direct traumatic impact [6, 7].

Although people have used different tools for fixing this type of fractures as mentioned above but consensus has not been established yet. The reason for preferring locking compression plate over the steel wires in our case was the former is much safer if performed under fluoroscopic guidance, taking care not to push screws much beyond posterior cortex; approximates bone closely and it requires minimal dissection of tissues, hence less interruptions in the blood supply of sternum as compared to latter [8-10]. Moreover, the previous experience with sternal wires, as reported by Salloum W et al.[1], was not good, as they had to remove the wires and apply a metallic plate for fixation two months after initial fixation by wires. In this regard CT scan helped us in measuring the distance between the outer and inner table of the sternum, hence the size of the screws to be used was decided preoperatively. The timing of fixation has long been debated, but Harston A et al.[6] reported that most of the sternal fractures had been surgically fixed during the same hospital stay as done in our case.

CONCLUSION:

Manubrio-sternal dislocations are extremely rare. Due to the paucity of literature, a consensus has not been established yet on the ideal method of fixation. However, this case report will be a valuable addition to literature to achieve desirable outcome after surgical management of sternal fractures with titanium plate during the same hospitalisation.

AUTHORS' STATEMENTS

Competing Interests

References

1. Salloum W, Nikolaidis N, Weeden D. Manubriosternal Joint Dislocation—A Treatment Dilemma. *The Internet Journal of Thoracic and Cardiovascular Surgery*. 2009;15(1).
2. Lemaitre J, Koriche C, Massard G, Wihlm J. Manubriosternal Disjunction: a New Approach for Surgical Repair. *Acta chirurgica Belgica*. 2004;593-5.
3. Nijs S, Broos P. Sterno-manubrial dislocation in a 9-year old gymnast. *Acta chirurgica Belgica*. 2005;105(4):422.
4. Gaines RJ, Wilson A, Antevil J, Demaiio M. Parallel plating for a sternomanubrial dislocation. *Orthopedics*. 2012;35(8):e1276-8.
5. Thirupathi R, Husted C. Traumatic disruption of the manubriosternal joint. A case report. *Bulletin of the Hospital for Joint Diseases Orthopaedic Institute*. 1981;42(2):242-7.

6. Harston A, Roberts C. Fixation of sternal fractures: a systematic review. *Journal of Trauma and Acute Care Surgery*. 2011;71(6):1875-9.
7. Chou SS, Sena MJ, Wong MS. Use of SternaLock plating system in acute treatment of unstable traumatic sternal fractures. *The Annals of thoracic surgery*. 2011;91(2):597-9.
8. Abdul-Rahman MR, Seong NK, Hee TG, Aljada ME, Reda TA, SuMin JO, et al., editors. Comminuted sternal fracture—a sternotomy wire fixation: report of 2 cases. *The heart surgery forum*; 2009: Carden Jennings.
9. Al-Qudah A. Operative treatment of sternal fractures. *Asian Cardiovascular and Thoracic Annals*. 2006;14(5):399-401.
10. Severson EP, Thompson CA, Resig SG, Swiontkowski MF. Transverse sternal nonunion, repair and revision: a case report and review of the literature. *Journal of Trauma-Injury, Infection, and Critical Care*. 2009;66(5):1485-8.