

Paediatric Tenosynovial Giant Cell Tumor of Little Finger- A Case Report

Aditi Vijay Dalvi*, Maitreyee Save, Paras Kothari, Abhaya Gupta, Shahaji Deshmukh, Apoorva Kulkarni, Saurabh Tiwari, Shalika Jaiswal, Saket Jha, Dhvani Shah

Lokmanya Tilak Municipal Medical College and General Hospital Mumbai, Maharashtra, India

Citation: Aditi Vijay Dalvi, Maitreyee Save, Paras Kothari, Abhaya Gupta, Shahaji Deshmukh, Apoorva Kulkarni, et al. Paediatric Tenosynovial Giant Cell Tumor of Little Finger- A Case Report. *Int Clinc Med Case Rep Jour.* 2023;2(1):1-3.

Received Date: 05 January, 2023; **Accepted Date:** 07 January, 2023; **Published Date:** 09 January, 2023

***Corresponding author:** Aditi Vijay Dalvi. Lokmanya Tilak Municipal Medical College and General Hospital Mumbai, Maharashtra, India

Copyright: © Aditi Vijay Dalvi, Open Access 2023. This article, published in *Int Clinc Med Case Rep Jour* (ICMCRJ) (Attribution 4.0 International), as described by <http://creativecommons.org/licenses/by/4.0/>.

ABSTRACT

Tenosynovial giant cell tumor (TSGCT) is the second most common tumor after ganglion cyst. Here we talk about an 8year girl presented with left little finger swelling since 3 months. On excision it showed Tenosynovial giant cell tumor – localized type.

Keywords: Tenosynovial giant cell tumor

INTRODUCTION

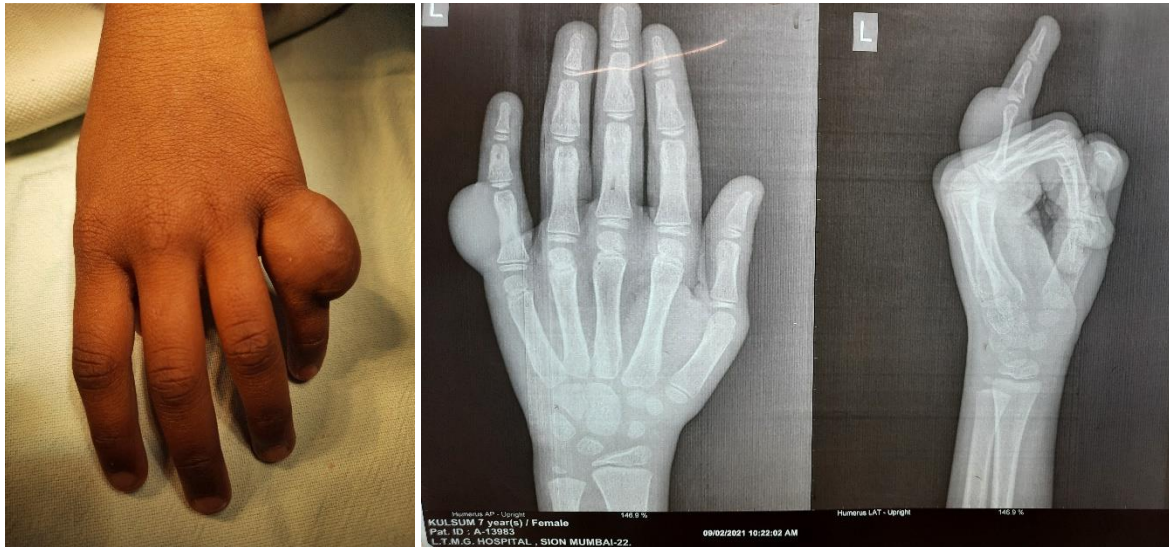
Tenosynovial giant cell tumor (TSGCT) is the second most common tumor after ganglion cyst.^[1] They arise from the synovium due to recruitment of macrophages thus a mass is formed.^[2] TSGCT's are rare, benign tumors involving bursae, tendon sheath, and synovium. WHO classified these tumors in 2013 in two distinct types -

1. Tenosynovial giant cell tumors- localized form (intraarticular or extra articular)
 2. Pigmented villonodular synovitis (PVNS) also known as Diffuse type of giant cell tumors.
- 20-50 years is the common age group and occurrence in children is rare.^[3]

CLINICAL SUMMARY

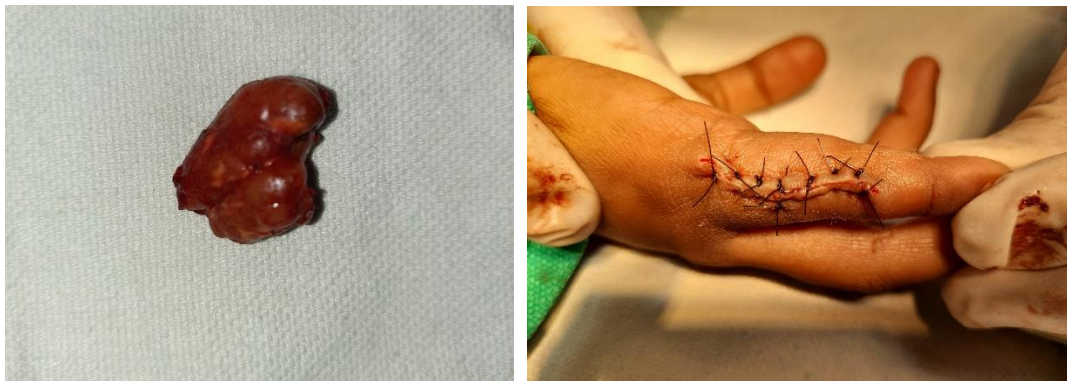
8 years, female child brought by mother with complaint of swelling over the left little finger since three months. It was spontaneous in onset, gradually progressive up to the current size. The swelling was not associated with any history of trauma, pain, discharge or ulceration. There was no history of any other such swelling over the body.

On examination, there was a 2 x 1.5 cm single, well defined, ovoid swelling over the proximal 1/3rd of the left little finger. On palpation, the temperature was normal, it was non-tender, firm, not mobile, did not increase or decrease in size on flexion or extension of the finger with full range of motion and skin above the swelling was pinchable.



Baseline blood investigations were within normal limits. X ray left hand AP & lateral suggestive of mild scalloping of 5th proximal phalanx due to pressure changes, no bony involvement seen.

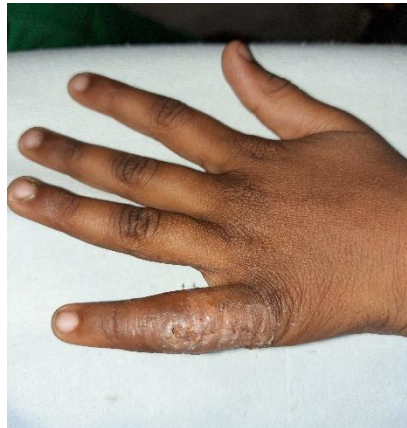USG local: 1.3 x 2 x 2.3 cm well defined, ovoid, solid, homogenous, hypoechoic lesion seen in subcutaneous plane with minimal peripheral vascularity and few calcific foci within. Lesion not seen separate from adjacent tendinous and does not move with flexion and extensions of the tendons. No obvious communication with joint cavity or skin. Surgical excision of the tumor in Toto was done and sent for histopathological examination.



HPE report: Sections studied show a tumor compound of cells arranged in lobular pattern separated by fibrous septa. Polymorphs cell population, composed of osteoclast like giant cells, large histiocytoid cells with abundant eosinophilic cytoplasm and eccentric nucleus and focally clustered foamy histiocytes.

Impression- Tenosynovial giant cell tumor – localized type.

Suture removal was done on post op day 10, with no deficit and full range of movements. No signs of recurrence seen at 3 months follow up.



DISCUSSION

Tenosynovial giant cell tumors are rare, benign fibrous tissue tumors more commonly seen in 30-50 age group and are uncommon in children under 10 years of age with 4.3% as the incidence.^[3] They are more common in females (3:2) ratio.^[3] It was first described as fibrous xanthoma by Chassaignac in 1952.^[3] There are slow growing, painless masses involving the extremities, most commonly index finger of the hand. Exact etiology is not known, may be associated with inflammatory reaction, trauma, infection, chromosomal translocations including over expression of CSF 1.

Surgical resection with total clearance is considered diagnostic as well as therapeutic. Most feared complications are recurrence and joint damage affecting range of movements due to increasing size and pressure effects.

Newer systemic therapies like tyrosine kinase inhibitor Pexidartinib and monoclonal antibody emactuzumab can be used owing to molecular mechanism of targeting CSF1R.^[2]

CONCLUSION

We report this case owing to the rarity of age group and involvement of a single digit, left little finger, near the proximal interphalangeal joint, unlike most commonly involved index finger and distal interphalangeal joint. Recurrence can be reduced by complete excision en-bloc. Preserving the function of the hand should always be kept in mind whilst surgical excision.

REFERENCES

1. Zhengming LV, Jie Liu. Giant cell tumor of tendon sheath at the hand: A case report and literature review. Ann Med Surg (Lond). 2020;58:143-6.
2. Nicholas Giustini, Nicholas M Bernthal, Susan V Bukata, Arun S Singh. Tenosynovial giant cell tumor: case report of patient effectively treated after Peridartinib (PLX3397) and review of literature. Clin Sarcoma Res. 2018;8:14.
3. Saba Mohammed Musaddique Ansari, Swagata Arvind Tambe, Chitra Shivanand Nayak. Giant cell tumor of tendon sheath in children. Indian J Dermatol Venerol Leprol. 2019;85(5):495-8.