

## BIBLIOGRAPHIC INFORMATION SYSTEM

**Journal Full Title:** Journal of Biomedical Research & Environmental Sciences

**Journal NLM Abbreviation:** J Biomed Res Environ Sci

**Journal Website Link:** <https://www.jelsciences.com>

**Journal ISSN:** 2766-2276

**Category:** Multidisciplinary

**Subject Areas:** Medicine Group, Biology Group, General, Environmental Sciences

**Topics Summation:** 128

**Issue Regularity:** Monthly

**Review Process type:** Double Blind

**Time to Publication:** 7-14 Days

**Indexing catalog:** [Visit here](#)

**Publication fee catalog:** [Visit here](#)

**DOI:** 10.37871 ([CrossRef](#))

**Plagiarism detection software:** iThenticate

**Managing entity:** USA

**Language:** English

**Research work collecting capability:** Worldwide


**Organized by:** [SciRes Literature LLC](#)

**License:** Open Access by Journal of Biomedical Research & Environmental Sciences is licensed under a Creative Commons Attribution 4.0 International License. Based on a work at SciRes Literature LLC.

Manuscript should be submitted in Word Document (.doc or .docx) through

**Online Submission**

form or can be mailed to [support@jelsciences.com](mailto:support@jelsciences.com)

 **Vision:** Journal of Biomedical Research & Environmental Sciences main aim is to enhance the importance of science and technology to the scientific community and also to provide an equal opportunity to seek and share ideas to all our researchers and scientists without any barriers to develop their career and helping in their development of discovering the world.

CASE REPORT

# Successful 4-Year Outcome Following Convergent Ablation for Longstanding Persistent Atrial Fibrillation in an Octogenarian – Novel Therapy for an Old Condition in the Very Elderly

Omar Ahmed<sup>1,2</sup>, Azza Elbadri<sup>1,2</sup>, Aziz Momin<sup>1,2</sup> and Riyaz A Kaba<sup>1,2\*</sup>

<sup>1</sup>Cardiovascular Clinical Academic Group, St. George's, University of London, and St George's Hospitals NHS Foundation Trust, UK

<sup>2</sup>Department of Cardiology, Ashford and St. Peter's Hospitals NHS Foundation Trust, Surrey, UK

## ABSTRACT

The most common age range for Atrial Fibrillation (AF) prevalence over the coming decades will potentially be in those over 75 years old. However, despite widespread recognition of the strong association between AF burden and age, the elderly are under-represented within trials evaluating invasive rhythm control strategies. We report the outcomes of a gentleman in his late eighties that underwent Convergent hybrid ablation for highly symptomatic and longstanding persistent AF. Now four years later and into his nineties, he remains in sinus rhythm and enjoys good cardiac health without the need for anti-arrhythmic drugs or further intervention. To our knowledge, this case report is the oldest patient to have successfully undergone Convergent ablation with enduring sinus rhythm with long-term follow-up, despite significant risk factors for AF recurrence. As the overall population ages, the emergence of this minimally invasive multidisciplinary ablation technique for AF may offer to similar patients benefits over percutaneous ablation strategies alone.

## Introduction

Atrial Fibrillation (AF) is the commonest cardiac arrhythmia worldwide and is estimated to affect between 2-4% of adults [1]. Prevalence continues to increase despite improvements in care, primarily due to the steadily ageing population and the rising burden of comorbidities such as hypertension, diabetes, heart failure, obesity, and chronic kidney disease. With the currently shifting United Kingdom (UK) age demographic, the number of patients with AF is expected to increase from 700,000 in 2010 to 1.8 million by 2060 [2].

In AF, regular atrial electrical activity is lost and replaced by a more chaotic and unpredictable rhythm that leads to ineffective atrial contraction and loss of atrioventricular electromechanical synchrony. As a result, AF is a significant risk factor for heart failure, stroke, dementia, and premature death [3]. Restoration of usual sinus rhythm is possible and most effectively achieved in the long term with catheter ablation, which is routinely offered to symptomatic patients [4]. However, older patients, particularly those with longstanding persistent AF, have been under-represented within interventional ablation trials. Hence, in common with other strategies such as angiography [5], it is less often utilised in these cohorts.

Most recently, Convergent hybrid AF ablation has emerged as a minimally invasive technique that may offer selected patients benefits over percutaneous

## \*Corresponding author(s)

**Riyaz A Kaba**, Cardiovascular Clinical Academic Group, St. George's, University of London, and St George's Hospitals NHS Foundation Trust, UK


Email: rkaba@sgul.ac.uk

DOI: 10.37871/jbres1611

Submitted: 27 October 2022

Accepted: 25 November 2022

Published: 28 November 2022

Copyright: © 2022 Ahmed O, et al. Distributed under Creative Commons CC-BY 4.0 

OPEN ACCESS


## Keywords

- > Atrial fibrillation
- > Hybrid ablation
- > Elderly
- > Convergent ablation

## MEDICINE GROUP

CARDIOVASCULAR DISEASES | CLINICAL CARDIOLOGY

VOLUME: 3 ISSUE: 11 - NOVEMBER, 2022



**How to cite this article:** Ahmed O, Elbadri A, Momin A, Kaba RA. Successful 4-Year Outcome Following Convergent Ablation for Longstanding Persistent Atrial Fibrillation in an Octogenarian – Novel Therapy for an Old Condition in the Very Elderly. 2022 Nov 28; 3(11): 1404-1407. doi: 10.37871/jbres1611, Article ID: JBRES1611, Available at: <https://www.jelsciences.com/articles/jbres1611.pdf>

ablation alone [6]. As a strategy, the procedure benefits from the involvement of cardiac electrophysiologists, cardiac surgeons, and associated specialist teams that aim to ablate more effectively AF triggers and substrate(s) that may be responsible. However, the efficacy and safety of Convergent hybrid ablation in the elderly remains unclear.

### Case Presentation

An active and independent male in his late eighties developed persistent AF. After three years of longstanding persistent AF, including an unsuccessful attempt at electrical cardioversion, he was referred to an electrophysiologist for consideration of ablation therapy. His past medical history included well-controlled hypertension and coeliac disease. Clinical history revealed exertional dyspnoea, palpitations, and fatigue. Notably, there was a significant reduction in his exercise tolerance, and he could not continue regular exercise at the gym, something he had previously enjoyed for many years. Echocardiography demonstrated severe Left Atrial (LA) dilatation (5.0 cm), good biventricular function, and no significant valve disease. Blood tests, including BNP, were unremarkable.

He commenced amiodarone and underwent electrical cardioversion, which failed to restore sinus rhythm for longer than ten days. Furthermore, despite optimal rate control with Bisoprolol, he remained highly symptomatic. Repeat cardioversion was inappropriate considering the previously short-lasting effect under the influence of amiodarone, together with the presence of severely dilated LA and the three-year history of persistent AF. Given these factors, an invasive strategy was indicated, particularly given his previous level of independence and fitness, for which he too was keen to explore this option.

His case was discussed at our Arrhythmia Multidisciplinary Team (MDT) meeting. Whilst endocardial ablation has a class one indication after the failure of anti-arrhythmic drug therapy [1], our patient had significant risk factors for AF recurrence, as reported above. Hence, there was a high probability that multiple procedures would be required over the next few years, which he would be less likely to tolerate with advancing age. After extensive discussion, the collective opinion was that he could benefit from minimally invasive Convergent hybrid ablation. The Convergent technique was preferred since it is currently the least invasive of all the hybrid techniques, requiring short recovery times and is well tolerated. The advantages, limitations, and risks of all treatments were discussed, and the patient elected to proceed with the MDT recommendation.

### Management

Convergent hybrid ablation is a multidisciplinary, two-stage procedure aiming to provide complete endo-epicardial isolation of the pulmonary veins and the left atrial posterior

wall. Stages are performed sequentially, either on the same day or often on separate days, 1-3 months apart. In our patient, stage one involved a minimally invasive epicardial surgical ablation utilising a transdiaphragmatic, posterior pericardioscopic approach. In stage two, adjunctive percutaneous endocardial catheter ablation was performed to enable completion of the transmural lesion sets and target regions that the epicardial approach could not reach, such as the region of the transverse sinus and parts of the anterior and superior aspects of the superior pulmonary veins. Our patient underwent both stages without complications and was discharged the day after each component of the two-staged procedure.

### Discussion

Successful and enduring rhythm control of longstanding persistent AF remains challenging in those with advanced age. Patients over the age of 75 account for one-third of all AF patients [7] and will account for the most significant growth in AF prevalence in the coming decades [8]. Despite this, they are heavily under-represented in interventional and surgical studies. Consequently, conservative approaches (with rate-control medications) remain the most utilised management strategies for elderly patients with persistent AF [7]. This may be related to conventionally low success

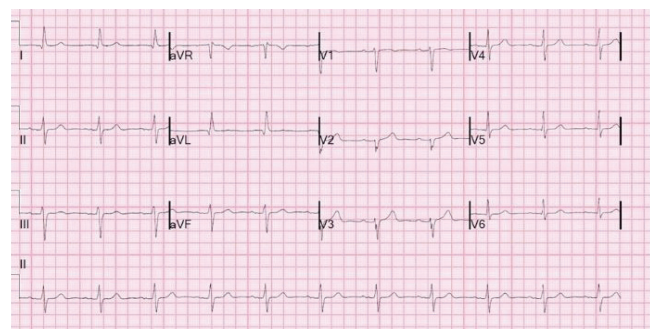


Figure 1 12-lead ECG, showing long-term maintenance of sinus rhythm following Convergent hybrid ablation.

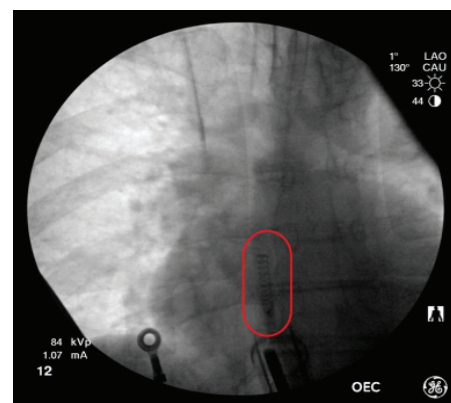


Figure 2 Antero-posterior fluoroscopic view of the ablation catheter in the posterior pericardial space.

rates following catheter ablation therapy in persistent and longstanding persistent AF, with rates as low as 43% at 25 months [9]. In addition, maintaining sinus rhythm following ablation is even more challenging in patients with a dilated LA [10]. As both adverse factors were present in our elderly patient, longstanding persistent AF for three years and a severely dilated LA, the anticipated success from endocardial catheter ablation was expected to be particularly low. Hence, such an approach would likely necessitate multiple attempts to achieve long-lasting sinus rhythm, if at all. For patients with advanced age, the need for repeat procedures over several years presents a unique challenge. An alternative therapy could have been an 'ablate and pace' strategy. However, our patient had very well rate-controlled persistent AF, so restoring atrioventricular synchrony in sinus rhythm was a more critical factor [11].

Considering all the factors discussed above, we elected to perform an emerging hybrid technique in AF ablation, the Convergent procedure, which substantially enhances outcomes in patients with longstanding persistent AF [12]. The procedure involves minimally invasive surgical epicardial ablation, followed by percutaneous endocardial catheter ablation, aiming to produce transmural lesions and improve long-term efficacy. Furthermore, it is essential to undertake both components of the Convergent hybrid ablation since there is a significant recovery of electrical activity following the surgical epicardial ablation alone [13].

Elderly patients with AF are less likely to be referred for specialist cardiology opinion and are less likely to be offered treatments to restore normal sinus rhythm [14]. Our case highlights 1) the merit of involving specialists in arrhythmia services, caring for elderly patients with symptomatic and debilitating persistent AF and 2) to consider the minimally invasive Convergent hybrid ablation therapy much earlier in the management pathway for those of advanced age. Indeed, for patients with severely dilated atria and longstanding persistent AF over the age of 75. There is a solid case to be made undertake Convergent hybrid ablation as a first-line therapy to optimise their outcomes and minimise the possibility of multiple catheter ablations over the ensuing years, as during this time, the patient may become less tolerant of repeat invasive procedures. To the best of our knowledge, our patient is the oldest patient reported to have undergone successful Convergent hybrid AF ablation therapy for personally having multiple risk factors for early recurrence at such long-term follow-up. Many other patients of advanced age may similarly benefit from this emerging form of minimally invasive ablation therapy.

## Conclusion

AF is the commonest cardiac dysrhythmia in clinical practice and is associated with loss of coordinated atrioventricular electrical and functional activity. Despite increased prevalence and incidence, elderly patients with AF

are less likely to be referred for a cardiologist's opinion, less well-represented in intervention AF ablation trials, and less likely to be offered an invasive treatment to restore normal sinus rhythm.

In persistent AF, particularly longstanding persistent AF, outcomes from percutaneous strategies are guarded, and patients often require multiple procedures over time. This presents a challenge to the elderly, who may be less well able to tolerate repeat procedures over several years. Recent advances in minimally invasive surgical and hybrid strategies for AF ablation, such as Convergent hybrid ablation, may offer similar patients' unique benefits over percutaneous ablation alone.

## References

1. Benjamin EJ, Muntner P, Alonso A, Bittencourt MS, Callaway CW, Carson AP, Chamberlain AM, Chang AR, Cheng S, Das SR, Delling FN, Djousse L, Elkind MSV, Ferguson JF, Fornage M, Jordan LC, Khan SS, Kissela BM, Knutson KL, Kwan TW, Lackland DT, Lewis TT, Lichtman JH, Longenecker CT, Loop MS, Lutsey PL, Martin SS, Matsushita K, Moran AE, Mussolino ME, O'Flaherty M, Pandey A, Perak AM, Rosamond WD, Roth GA, Sampson UKA, Satou GM, Schroeder EB, Shah SH, Spartano NL, Stokes A, Tirschwell DL, Tsao CW, Turakhia MP, VanWagner LB, Wilkins JT, Wong SS, Virani SS; American Heart Association Council on Epidemiology and Prevention Statistics Committee and Stroke Statistics Subcommittee. Heart disease and stroke statistics-2019 update: A report from the American heart association. *Circulation*. 2019 Mar 5;139(10):e56-e528. doi: 10.1161/CIR.0000000000000659. Erratum in: *Circulation*. 2020 Jan 14;141(2):e33. PMID: 30700139.
2. Lane DA, Skjøth F, Lip GYH, Larsen TB, Kotecha D. Temporal trends in prevalence, incidence, and mortality of atrial fibrillation in primary care. *J Am Heart Assoc*. 2017 Apr 28;6(5):e005155. doi: 10.1161/JAHA.116.005155. PMID: 28455344; PMCID: PMC5524079.
3. Aldrugh S, Sardana M, Henninger N, Saczynski JS, McManus DD. Atrial fibrillation, cognition and dementia: A review. *J Cardiovasc Electrophysiol*. 2017 Aug;28(8):958-965. doi: 10.1111/jce.13261. Epub 2017 Jun 21. PMID: 28569383; PMCID: PMC5783292.
4. Camm AJ, Naccarelli GV, Mittal S, Crijns HJGM, Hohnloser SH, Ma CS, Natale A, Turakhia MP, Kirchhof P. The increasing role of rhythm control in patients with atrial fibrillation: JACC State-of-the-art review. *J Am Coll Cardiol*. 2022 May 17;79(19):1932-1948. doi: 10.1016/j.jacc.2022.03.337. PMID: 35550691.
5. Rashid M, Fischman DL, Gulati M, Tamman K, Potts J, Kwok CS, Ensor J, Shoaib A, Mansour H, Zaman A, Savage MP, Mamas MA. Temporal trends and inequalities in coronary angiography utilisation in the management of non-ST-Elevation acute coronary syndromes in the US. *Sci Rep*. 2019;9(1):240. doi: 10.1038/s41598-018-36504-y
6. DeLurgio DB, Ferguson E, Gill J, Blauth C, Oza S, Mostovych M, Awasthi Y, Ndikintum N, Crossen K. Convergence of epicardial and endocardial RF ablation for the treatment of symptomatic persistent AF (CONVERGE Trial): Rationale and design. *Am Heart J*. 2020 Jun;224:182-191. doi: 10.1016/j.ahj.2020.02.016. Epub 2020 Feb 29. PMID: 32416333.
7. Fumagalli S, Said SAM, Laroche C, Gabbai D, Marchionni N, Boriani G, Maggioni AP, Popescu MI, Rasmussen LH, Crijns HJGM, Lip GYH; EORP-AF Investigators. Age-related differences in presentation, treatment, and outcome of patients with atrial fibrillation in Europe: The EORP-AF general pilot registry (EURObservational Research Programme-Atrial Fibrillation). *JACC Clin Electrophysiol*. 2015 Aug;1(4):326-334. doi: 10.1016/j.jacep.2015.02.019. Epub 2015 Apr 20. PMID: 29759321.
8. Hindricks G, Potpara T, Dagres N, Arbelo E, Bax JJ, Blomström-Lundqvist C, Boriani G, Castella M, Dan GA, Dilaveris PE, Fauchier L, Filippatos G, Kalman JM, La Meir M, Lane DA, Lebeau JP, Lettino M, Lip GYH, Pinto FJ, Thomas GN, Valgimigli M, Van Gelder IC, Van Putte BP, Watkins CL; ESC Scientific Document Group. 2020 ESC Guidelines for the diagnosis

and management of atrial fibrillation developed in collaboration with the european association for cardio-thoracic surgery (EACTS): The task force for the diagnosis and management of atrial fibrillation of the european society of cardiology (ESC) developed with the special contribution of the european heart rhythm association (EHRA) of the ESC. *Eur Heart J.* 2021 Feb 1;42(5):373-498. doi: 10.1093/eurheartj/ehaa612. Erratum in: *Eur Heart J.* 2021 Feb 1;42(5):546-547. Erratum in: *Eur Heart J.* 2021 Oct 21;42(40):4194. PMID: 32860505.

9. Brooks AG, Stiles MK, Laborderie J, Lau DH, Kuklik P, Shipp NJ, Hsu LF, Sanders P. Outcomes of long-standing persistent atrial fibrillation ablation: A systematic review. *Heart Rhythm.* 2010 Jun;7(6):835-846. doi: 10.1016/j.hrthm.2010.01.017. Epub 2010 Jan 22. PMID: 20206320.

10. McCreedy JW, Smedley T, Lambiase PD, Ahsan SY, Segal OR, Rowland E, Lowe MD, Chow AW. Predictors of recurrence following radiofrequency ablation for persistent atrial fibrillation. *Europace.* 2011 Mar;13(3):355-361. doi: 10.1093/europace/euq434. Epub 2010 Dec 8. PMID: 21148171.

11. Betts TR. Atrioventricular junction ablation and pacemaker implant for atrial fibrillation: Still a valid treatment in appropriately selected patients. *Europace.* 2008 Apr;10(4):425-432. doi: 10.1093/europace/eun063. Epub 2008 Mar 12. PMID: 18339612.

12. Elbadri A, Gukop P, Gallagher M. Results of minimally invasive hybrid ablation therapy for longstanding persistent AF. *European Journal of Arrhythmia & Electrophysiology.* 2019;5(Suppl. 1):160.

13. On YK, Park KM, Jeong DS, Park PW, Lee YT, Park SJ, Kim JS. Electrophysiologic results after thoracoscopic ablation for chronic atrial fibrillation. *Ann Thorac Surg.* 2015 Nov;100(5):1595-1602; discussion 1602-1603. doi: 10.1016/j.athoracsur.2015.04.127. Epub 2015 Jul 26. PMID: 26215779.

14. Fumagalli S, Nieuwlaat R, Tarantini F, de Vos CB, Werter CJ, Le Heuzey JY, Marchionni N, Crijns HJ. Characteristics, management and prognosis of elderly patients in the euro heart survey on atrial fibrillation. *Aging Clin Exp Res.* 2012 Oct;24(5):517-523. doi: 10.3275/8408. Epub 2012 May 8. PMID: 22572627.

**How to cite this article:** Ahmed O, Elbadri A, Momin A, Kaba RA. Successful 4-Year Outcome Following Convergent Ablation for Longstanding Persistent Atrial Fibrillation in an Octogenarian – Novel Therapy for an Old Condition in the Very Elderly. 2022 Nov 28; 3(11): 1404-1407. doi: 10.37871/jbres1611, Article ID: JBRES1611, Available at: <https://www.jelsciences.com/articles/jbres1611.pdf>