



Journal Homepage: -www.journalijar.com

INTERNATIONAL JOURNAL OF ADVANCED RESEARCH (IJAR)

Article DOI:10.21474/IJAR01/15773
DOI URL: <http://dx.doi.org/10.21474/IJAR01/15773>



RESEARCH ARTICLE

A STUDY OF OCULAR MANIFESTATIONS AMONG COVID-19 AND POST COVID PATIENTS ATTENDING A TEACHING HOSPITAL, VISHAKAPATNAM

Dr. K. Ravi Naini M.S¹, Dr. V.V.L. Narasimha Rao M.S.D.O² and Dr. R. Sai Sushma M.D³

1. Assistant Professor.
2. Professor and HOD.
3. Assistant Professor.

Manuscript Info

Manuscript History

Received: 28 September 2022
Final Accepted: 30 October 2022
Published: November 2022

Key words:-

Covid and Post Covid patients,
Ocular Manifestations, Teaching
Hospital

Abstract

Introduction: At the end of 2019, the rapid spread of a new corona virus led to a Severe Acute Respiratory Syndrome, known as COVID-19, which was declared a pandemic in March 2020 by the World Health Organization. Until now, it already killed more than 2.7 million people worldwide. Among the patients with COVID-19, approximately 10% exhibited ocular symptoms.

Objective: To study the ocular findings among covid and post covid patients who are attending a teaching hospital.

Methods And Materials: In this cross-sectional study, we have examined total 200 patients who had either Active phase of Covid(136), Post Covid Syndrome(pcs)(46) or Chronic Covid disease(18). All the patients had undergone anterior segment evaluation. Visual acuity measured by snellen chart, Intraocular pressure (IOP) by NCT, Dry eye evaluation, Fundus examination and Optical Coherence Tomography (OCT) were done only for patients with positive findings.

Results: In this study, out of 200 Covid-19 patients, 36 patients had clinical symptoms. Out of 36 patients, 23 were male and 13 were female aged between 18-75 years. We observed ocular findings such as Redness(7), Itching(5), tearing(8), FB sensation(6), blurring of vision(9) and swelling of eyelids(1). The ocular diseases observed were conjunctivitis(24 eyes), Dry Eyes(28 eyes), Glaucoma(10 eyes), Central serous chorioretinopathy(3 eyes), Mucormycosis(1 eye) and Herpes Zoster Ophthalmicus(1 eye).

Conclusion: Almost 18% of patients had ocular abnormalities which required treatment and became asymptomatic in 1-4 weeks. Hence all covid and post covid patients should undergo ocular examination for period of 6 months to prevent further progression of the condition and possible complications.

Introduction:-

At the end of 2019, the rapid spread of a new coronavirus led to a severe acute respiratory syndrome (SARS CoV-2), known as COVID-19, which was declared a pandemic in March 2020 by the World Health Organization. Until now, it already killed more than 2.7 million people worldwide.

Among the patients with COVID-19 in the acute phase of the disease, approximately 10% exhibited ocular symptoms, particularly related to Anterior and Posterior segment commitment apart from other systematic conditions.

Greenhalgh et al.(1) defined PCS as COVID symptoms extending beyond three weeks from the onset of first symptom and chronic COVID-19 as extending beyond 12 weeks. Post-COVID Syndrome (PCS) has been proposed, taking into account the high frequency numbers (from 10 to 35%) of people affected by SARS-CoV-2 among whom the symptoms persist after the disease's acute phase. The most common findings were cough, low-grade fever, and fatigue, all of which may relapse and remit. Other reported symptoms of the PCS include shortness of breath, chest pain, headaches, neurocognitive difficulties, muscle pains and weakness etc.(2)

In these publications about PCS, we did not find any information about ocular manifestations persisting after COVID-19. Hence, the present study has been taken up with the following objective.

Objective:-

To study the ocular manifestations in covid and post covid patients who are attending a teaching hospital.

Methodology:-**Study design:**

Hospital based cross sectional study

Study setting:

GITAM Institute of Medical Sciences and Research (GIMSR), a teaching hospital in Visakhapatnam

Study population:

COVID and Post COVID patients, attending ophthalmology outpatient department and inpatients admitted under various departments in the hospital with ocular complaints

Study duration:

6months from December 2021 to may 2022. During this period, GIMSR was COVID hospital admitting all moderate and severe cases of COVID 19 infection.

Sample size:

All the COVID and post COVID patients attending the hospital during the study period were included in the present study. A total of 200 patients attended GIMSR during the study period.

Inclusion criteria:

Patients between 18-75 years who had active covid, Post Covid Syndrome (PCS) and chronic covid.

Exclusion criteria:

1. Patients under 18 years of age were excluded
2. Patients who had previous history of dry eyes, corneal disease, retinal disease and neurological disease were excluded.
3. Patients who recovered from covid beyond 6 months

Study Procedure:

All the patients had undergone anterior segment evaluation. The visual acuity using Snellen chart, intraocular pressure (IOP) using NCT, fundus examination and optical coherence tomography (OCT) were done only for patients with positive findings.

Dry eye tests like Break- up time (BUT), Corneal Fluorescent Staining and Schirmer's test were performed for all the patients.

The break-up time (BUT) assessment was considered positive if dark spot appears < 7 sec on the worse eye.

Corneal fluorescein staining-

The corneal area was divided into five zones, one central area and four peripheral ones, each region was classified as no stain (= 0), 1, 2 or 3 (great stain) .

A total score varying from 0 to 15 was calculated for the entire cornea, following the Dry eye workshop guidelines.

The Tear flow was measured by the Schirmer 's test (Fig 1) without anesthesia and considered positive for dry eye if the worse eye showed ≤ 5 mm of wetness.

All the patients were given symptomatic treatment from 1 week to 4 weeks. Mucormycosis patient was referred to higher center for surgical management.

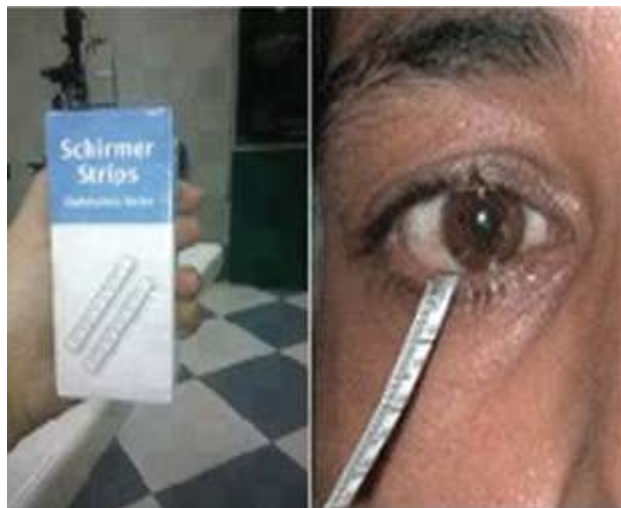

Fig 1:- Tear Flow Test.

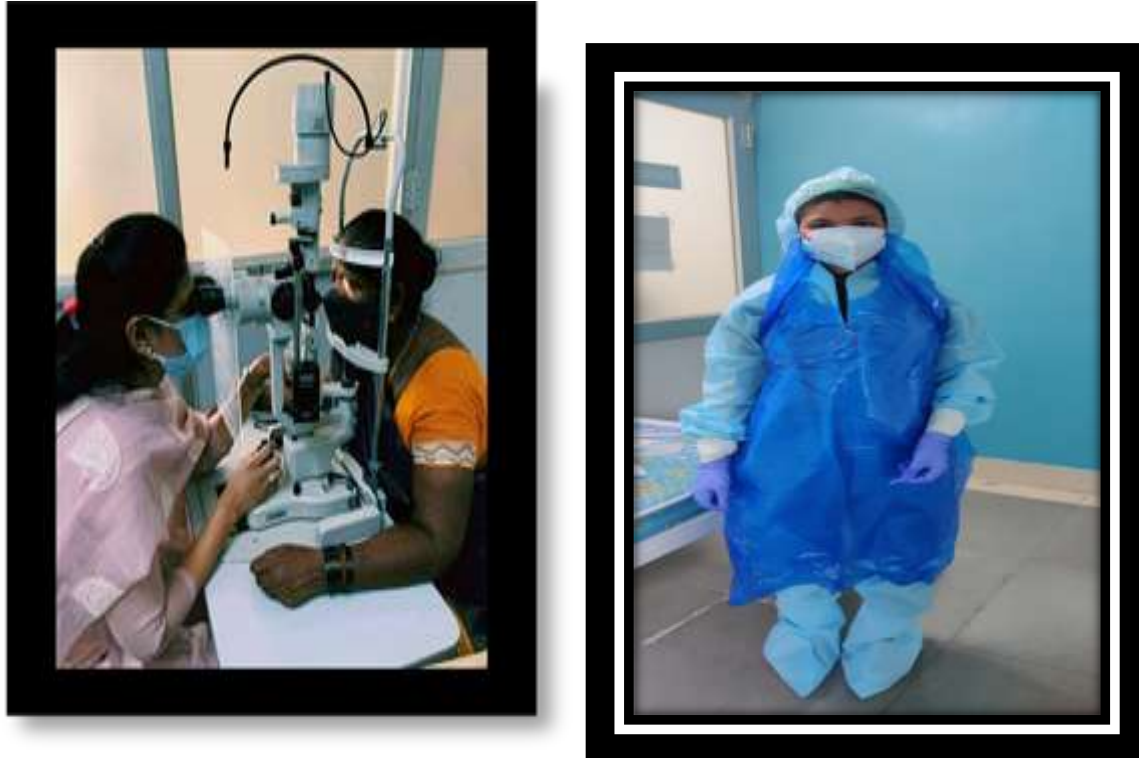

Fig 2&3:- Researcher examining the patient; Researcher wearing PPE.

Ethical consideration:

Permission was taken from Institutional Ethics Committee, GIMSR, Visakhapatnam.

Data analysis:

Data was entered in excel sheet and qualitative data is represented as proportions and percentages.

There is no conflict of interest or financial support.

Results:-

In the present study, among the total 200 patients, there were 136 in active covid phase, 46 in Post-covid Syndrome and 18 in Chronic covid disease.

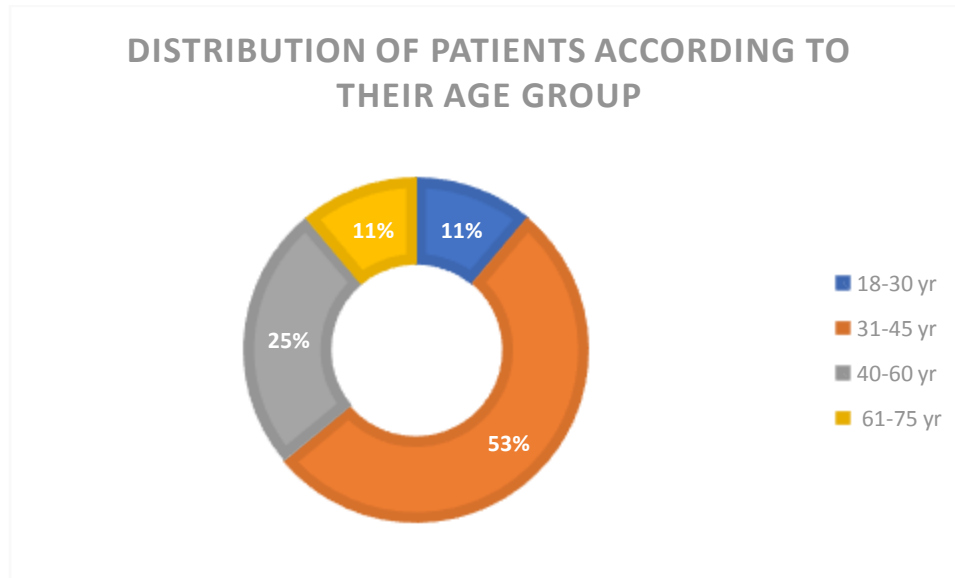


Fig 4:- Distribution of patients according to their age group.

Majority of the patients (53%) presenting with ocular findings were in the age group of 31-45 years, followed by 40-60 years with 25% and 31-45 years and 18-30 years with 11% in each group.

Table 1:- Distribution of the study population on the basis of ocular complaints and gender:

complaints observed	Male	Female	Total (%)
Redness	4	3	7 (19.4)
Itching	4	1	5(13.9)
Tearing	7	1	8(22.2)
F.B sensation	3	3	6(16.7)
Blurred vision	5	4	9(25)
Swelling eyelids	0	1	1(2.8)
Total	23	13	36(100)

Out of 200 patients, 36 patients (23 males and 13 females) presented with ocular complaints such as redness (19.4%), itching (13.9), tearing (22.2%), Foreign Body (F.B) sensation (16.7%), blurring of vision(25%), swelling of eyelids(2.8%).

Among males with ocular complaints, 30% had tearing sensation followed by blurred vision(21.7%), Itching(17.4%), Redness(17.4%) and Foreign body(F.B) sensation(13%).

Among females with ocular complaints, 30% had blurred vision, 23% had F.B sensation and redness independently and 7.6% had itching, tearing and swelling of eyelids independently.

Table 2:- Distribution of the study population on the basis of ocular diseases and eyes involved:

Disease	N(%)	eyes(%)
Conjunctivitis	12(33.33)	24(35.8)
CSCR	3(8.33)	3(4.5)
Dry eye	14(38.89)	28(41.7)
Glaucoma	5(13.89)	10(15)
HZO	1(2.78)	1(1.5)
Mucormycosis	1(2.78)	1(1.5)
Total	36(100)	67(100)

Total 67 eyes out of 36 patients had ocular diseases, dry eye being the commonest followed by conjunctivitis.

The ocular diseases observed in the present study were Dry eye(38.89%), Conjunctivitis(33.33%), Glaucoma(13.89%), Central Serous ChorioRetinopathy(CSCR) (8.33%), Herpes Zoster Ophthalmicus(HZO) (2.78%) and Mucormycosis(2.78%).

In CSCR, HZO and Mucormycosis, single eye involvement was observed. In rest of the conditions both eyes were involved in the present study.

Discussion:-

In a systematic review and Meta-analysis by Nasiri et al(3), the prevalence of dry eye or foreign body sensation, redness of eye, tearing and itching sensation were observed to be 16%, 13.3%, 12.8% and 12.6% respectively and in the present study, the prevalence of the same was 38.89%, 19.4%, 22.2% and 13.9% respectively. The observed variation may be because of the difference in sample size and sampling techniques.

The incidence of conjunctivitis among COVID patients was found to range from 0.8% to almost 65% in different study populations. Wong et al(4). described a prevalence of 0.8%–31.6% where as in our study conjunctivitis was found in 33.3%. According to Nasirin et al(3) conjunctivitis is most common and found in 88.8%.

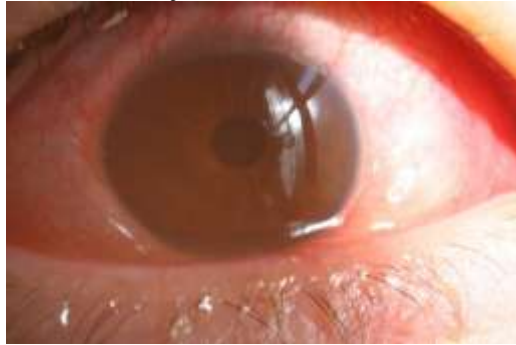


Fig 5:- Conjunctivitis.

Costa IF et al.(2) showed a previous overall diagnosis of dry eye 38.7%, especially in women, whereas in the present study, 38.9% of the patients presented with dry eye and required treatment for the same.

According to Dalia Tohamy, Mohamed Sharaf(5), 2% were having central serous chorioretinopathy (CSCR) where as in our study (8.3%) were having CSCR.

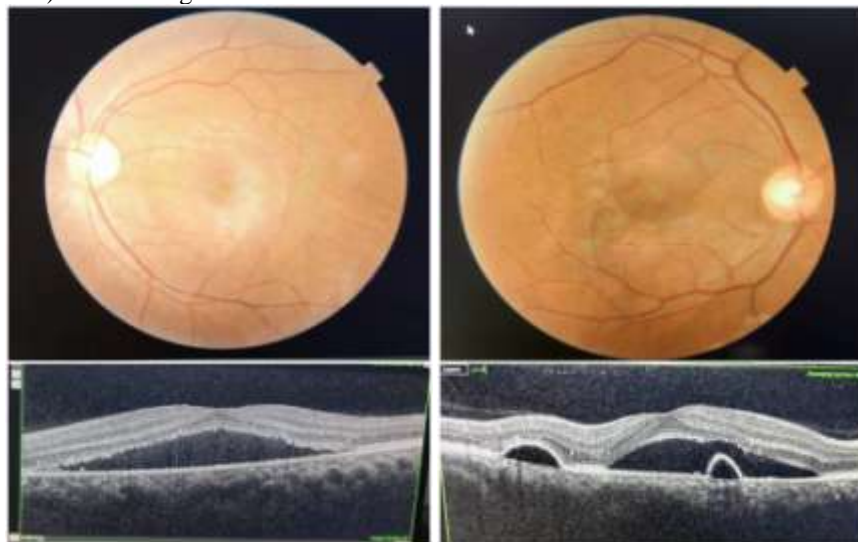


Fig 6 &7:- (a)Show fundus and OCT image of patient with CSCR.(b) Show fundus and OCT Image of other patient with CSCR WITH PED.

Mucormycosis was predominantly seen in males (78.9%) according to Awadhesh Kumar Singh, Ritu Singh(6). In the present study, 1 male patient case presented with mucormycosis(**Fig 8**).

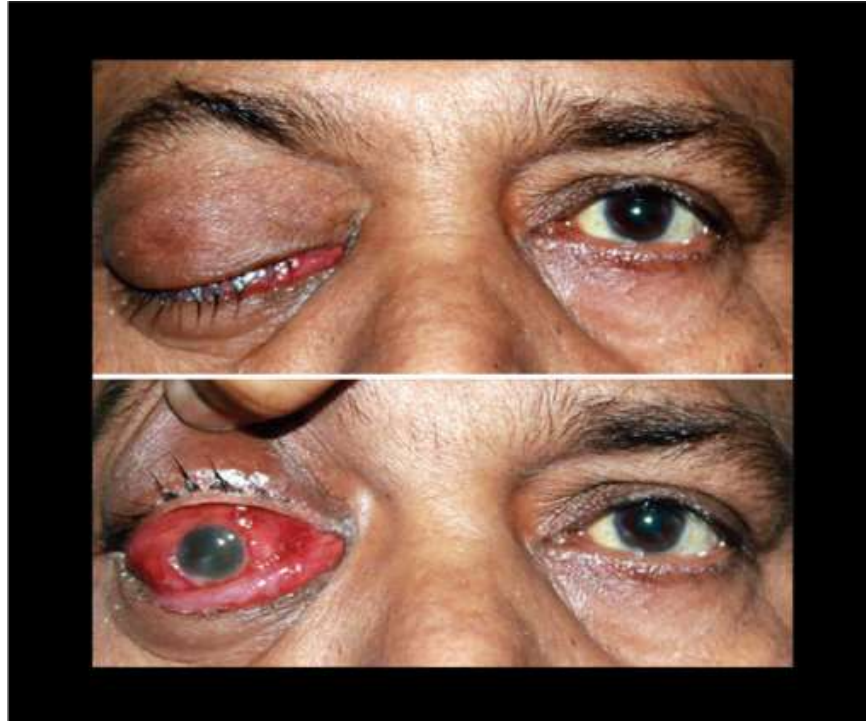

Fig 8:- Mucormycosis in covid patient.

In our study, Herpes Zoster Ophthalmicus(**Fig 9**), a very rare manifestation of Post Covid Syndrome, was observed in a patient, who underwent medical treatment and recovered.

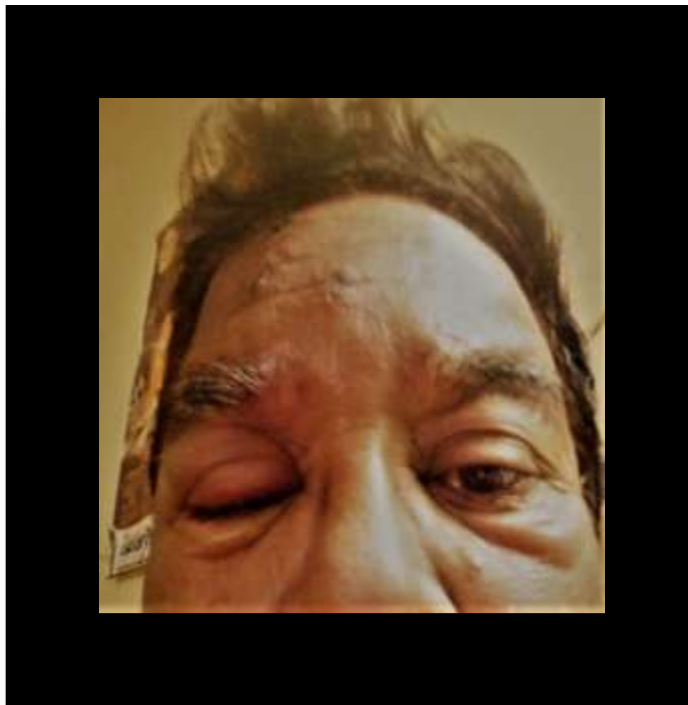

Fig 9:- HZO seen in post covid patient before 6 weeks of duration.

Conclusion:-

In the present study, 18% of patients had ocular abnormalities which required treatment and became asymptomatic in 1-4 weeks.

Hence all covid and post covid patients should undergo ocular examination for a period of 6 months to check for any ocular abnormalities and prevent further progression of the condition and possible complications.

References:-

1. Greenhalgh T, Knight M, A'Court C, Buxton M, Husain L. Management of post-acute covid-19 in primary care. *BMJ*. 2020 Aug 11;m3026.
2. Costa ÍF, Bonifácio LP, Bellissimo-Rodrigues F, Rocha EM, Jorge R, Bollela VR, et al. Ocular findings among patients surviving COVID-19. *Sci Rep*. 2021 May 26;11(1):11085.
3. Nasiri N, Sharifi H, Bazrafshan A, Noori A, Karamouzian M, Sharifi A. Ocular Manifestations of COVID-19: A Systematic Review and Meta-analysis. *J Ophthalmic Vis Res*. 2021 Jan 20;16(1):103–12.
4. Wong RLM, Ting DSW, Wan KH, Lai KHW, Ko CN, Ruamviboonsuk P, et al. COVID-19: Ocular Manifestations and the APAO Prevention Guidelines for Ophthalmic Practices. *Asia-Pac J Ophthalmol Phila Pa*. 2020 Jul 10;10.1097/APO.000000000000308.
5. Tohamy D, Sharaf M, Abdelazeem K, Saleh MG, Rateb MF, Soliman W, et al. <p>Ocular Manifestations of Post-Acute COVID-19 Syndrome, Upper Egypt Early Report</p>. *J MultidiscipHealthc*. 2021 Jul 23;14:1935–44.
6. Mucormycosis in COVID-19: A systematic review of cases reported worldwide and in India | Elsevier Enhanced Reader [Internet]. [cited 2022 Jul 2]. Available from: <https://reader.elsevier.com/reader/sd/pii/S1871402121001570?token=C5665E957A44032B595CDFC490938EF06BAE85019F8D91AC513DB00FD95C392B8C6CC7841A49B11FBE7ABEC4A641365E&originRegion=eu-west-1&originCreation=20220702101035>.