

Case Series

The use of collagen fleece for healing purposes

Damir Jelušić ^{1*} , Stjepan Siber ² 

¹ Institute Dentalna Jelusic, Opatija, 51410, Croatia

² Specialist office of oral surgery, Osijek, 31 000, Croatia; siberstjepan@yahoo.com (S.S.)

* Correspondence: damir@jelusic.com

Abstract: The collagen fleece is widely used biomaterial for healing in dental regeneration procedures. The aim of this work was to evaluate the regenerative potential of collagen sponge (collafleece®) in combination with other biomaterials being used in immediate implantation and sinus lift. For that reason, four patients were retrospectively analysed. The collagen fleece successfully supported the wound healing, controlled the bleeding, and assisted the healing of the Schneiderian membrane. The use of collafleece® led to successful treatment in combination with other biomaterials when used in immediate implantation and sinus lift.

Keywords: collagen fleece, immediate implantation, sinus lift, healing



Published: 24.05.2022

DOI: <https://doi.org/10.56939/DBR221020j>

Introduction

Collagen is a well-known natural biomaterial that is regularly used for regeneration purposes [1]. Nowadays the collagen biomaterials products mainly have porcine, bovine or equine origin [2]. For dental regeneration application the collagen can be processed into fleeces, barrier membranes and collagen matrices [3].

The collagen fleece is mostly used to support the wound healing and control the bleeding [4]. That is because the collagen has hemostyptic reactivity that leads to fast blood clot formation [5]. Then such combination of fast resorbing collagen and blood clot represents the ideal healing matrix [6]. However, variations in the collagen production process can significantly influence the clinical outcome [2].

Many indications in implantology, periodontology and oral and craniomaxillofacial surgery require the use of collagen fleece either alone or in combination with other biomaterials [7]–[9]. Immediate implant placement without bone grafting and collagen sponge only, leads to significant horizontal ridge reduction and minor mucosal recession [10]. However, the placement of dental implants via lateral sinus lift by using only a collagen sponge is accompanied by a high implant survival rate [7].

The aim of this work was to evaluate the regenerative potential of collagen fleece (collafleece®) in combination with other dental regeneration biomaterials. To verify the healing capacity of this resorbable collagen sponge, we retrospectively analyzed four patients that underwent immediate implantation and sinus lift.

Materials and Methods

Four patients were retrospectively analyzed after being successfully treated with collagen sponge (collafleece®, botiss biomaterials GmbH, Zossen, Germany) (Table 1). There were not any selection criteria, and the patients were randomly treated with this sponge per ``on-spot`` indication request. The patients provided informed consent and all treatments

were conducted in accordance with the Declaration of Helsinki 2013. Also, the local health authorities allow publication upon presence of informed consent and without any additional requirements.

Table 1. Overview of the indications and re-entry period

	Indication	Re-entry period
Patient 1	Immediate implantation	4 months
Patient 2	Immediate implantation	4 months
Patient 3	One-stage sinus lift	6 months
Patient 4	Two-stage sinus lift	6 months

Patient 1 underwent teeth extraction at position 24, 25 and 26 due to advanced periodontal disease, furcation involvement on all teeth and consequential tooth mobility. However, due presence of deep pockets, bone resorption around the roots of tooth 26 and the close relationship of the tooth to the floor of the sinus, an immediate implantation was contraindicated. On the other hand, positions 24 and 25 had a satisfactory volume of residual bone ridge. For that reason, an immediate implant placement was performed at positions 24 and 25 (Figure 1a). After detailed wound debridement, the bone defect around the implants was filled with xenograft granules (cerabone®, 1-2 mm particles size, botiss biomaterials GmbH, Zossen, Germany) that were tightly compressed to enable greater stability during osseointegration. Here the soft tissue defect resulting from the extraction required a healing support, which was achieved by using exposed collafleece® in a double layer (Figure 1b). Since the wound mucous edges couldn't join, the collafleece® acted as an ``open healing wound stabilizer`` that prevented the bone substitute disintegration in the early and most sensitive healing phase (Figure 1c).

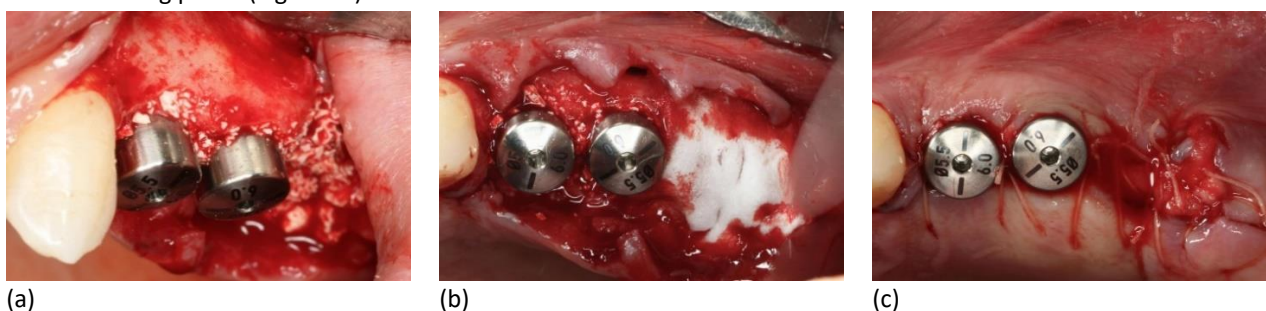

Figure 1. Patient 1: (a) Immediate implants placement and filling the gaps with cerabone®; (b) Treatment with collafleece®; (c) Wound closure with open healing.

Patient 2 showed himself with deep periodontal pocket at tooth 21 and the 3D CBCT diagnostics revealed the presence of a very thin vestibular bone wall, which allowed tooth extraction followed by immediate implant placement (Figure 2a). The clinical procedure in such situations requires prosthetically guided implant positioning according to the biological principles of bone resorption, which is most evident on the vestibular bone wall. Following this, the implant placement creates a horizontal bone defect between the surface of the implant and the vestibular bone wall. If the gap is 2 mm or greater, it needs to be regenerated to prevent the vestibular bone wall collapse [11]. Therefore, the gap was filled with xenograft granules (cerabone®, 0,5-1 mm particles size, botiss biomaterials GmbH, Zossen, Germany) that were firmly packed and compressed into the gap itself, while the implant and its access opening were protected with a narrow healing abutment. The bone substitute was filled up to the marginal bone edges while the soft tissue edges were carefully cleaned (Figure 2a). Then the wound was sealed with collafleece® by rolling and pressing around the healing abutment (Figure 2b), followed by fixation with a cross-sutures (Figure 2c). This ensured wound bleeding control, prevention of bone substitute scattering and assisted the soft tissue open healing.

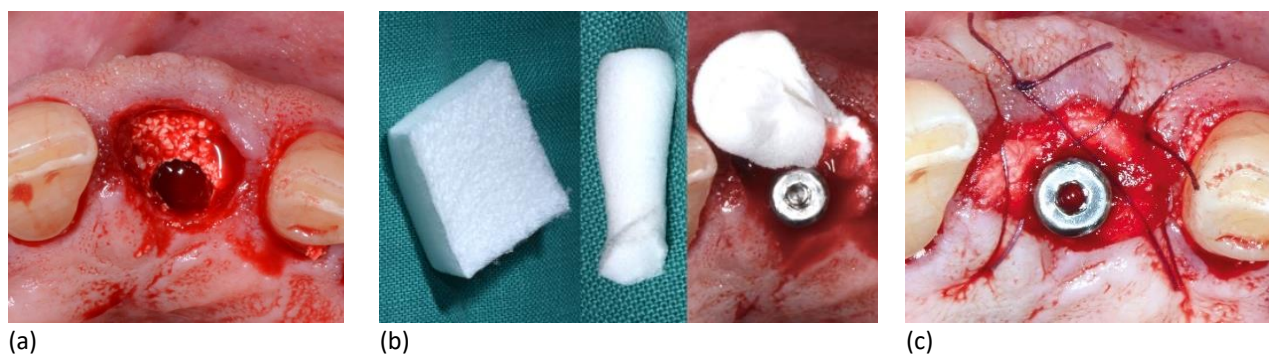


Figure 2. Patient 2: (a) Immediate implant placement and packing with cerabone®; (b) Placement of collafleece®; (c) Open healing and fixation by a cross-sutures.

Patient 3 had a visible perforation in the Schneiderian membrane during one-stage preparation of the lateral sinus window (Figure 3a). More specifically, it was a medium sized perforation with fully detached margins in a favorable position for stabilization. For that reason, collafleece® was first inserted for perforation healing purpose (Figure 3b) and then the cavity was filled up with long-term volume stability material cerabone® 1-2 mm (Figure 3c). Then once three implants were inserted, the sinus window was covered with collafleece® to stabilize the granules (Figure 3d). The area also required additional augmentation, for which cerabone® 1-2 mm was used again (Figure 3e) and was covered by a long-lasting collagen barrier membrane (Jason® membrane, botiss biomaterials GmbH, Zossen, Germany) (Figure 3f) before suturing.

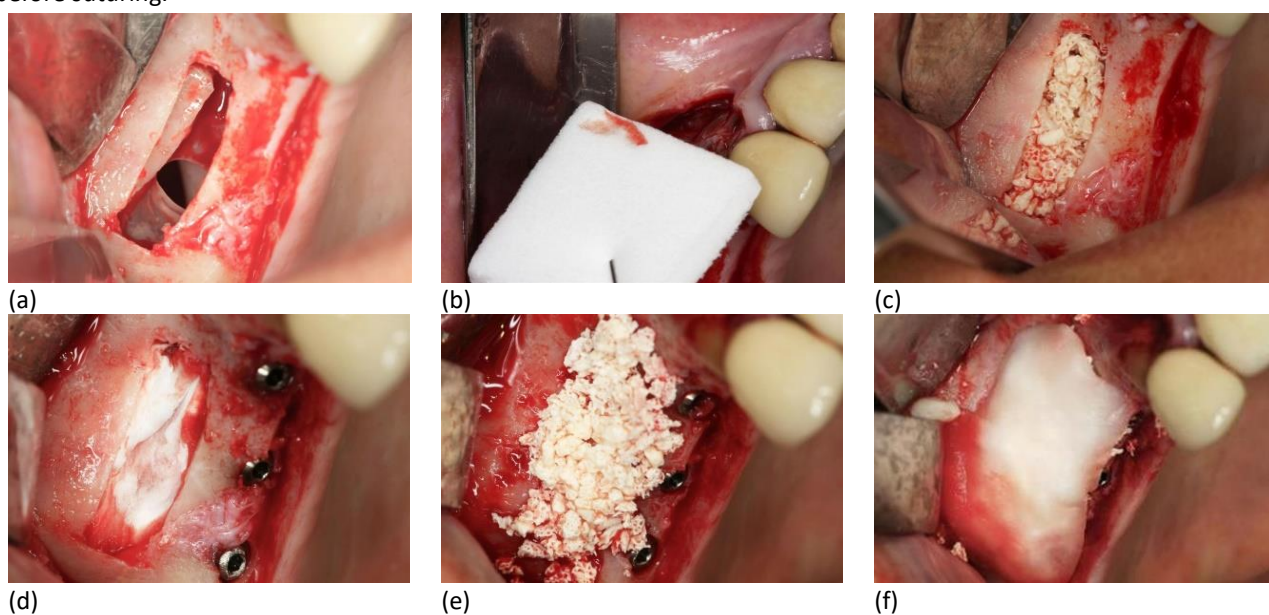


Figure 3. Patient 3: (a) Perforation of the Schneiderian membrane; (b) Application of collafleece® to heal the Schneiderian membrane; (c) Use of cerabone® to fill the sinus cavity; (d) Coverage with collafleece® to stabilize the granules; (e) Additional augmentation with cerabone®; (f) Coverage with Jason® membrane.

Patient 4 had a perforation of the Schneiderian membrane during two-stage preparation of the lateral sinus window (Figure 4a). This perforation position was favourable, visible and with solid possibility of surgical manipulation. However, the perforation margins were not detached which made the case more demanding. The perforation extended from the vestibular bone window inward, and the edge was adhered to the bone window cranial edge (Figure 4a). For that reason, Jason® membrane was modified according to the surgical field, defect, and bone window size by making two membrane notches. The notches represented anchors as one membrane part remained fixed and anchored to the outside vestibular

bone wall, while the other part closed the Schneiderian membrane (Figure 4b). This allowed grafting procedure continuation and insertion of cerabone® 0,5-1 mm into the sinus (Figure 4c). Then once the sinus window was closed by again using Jason® membrane, the extraction socket was also filled with cerabone® 0,5-1 mm (Figure 4d). This was performed to ensure long-term volume stability in the sinus and the socket. However, collafleece® had to be used to cover the socket and facilitate open healing (Figure 4e, f).

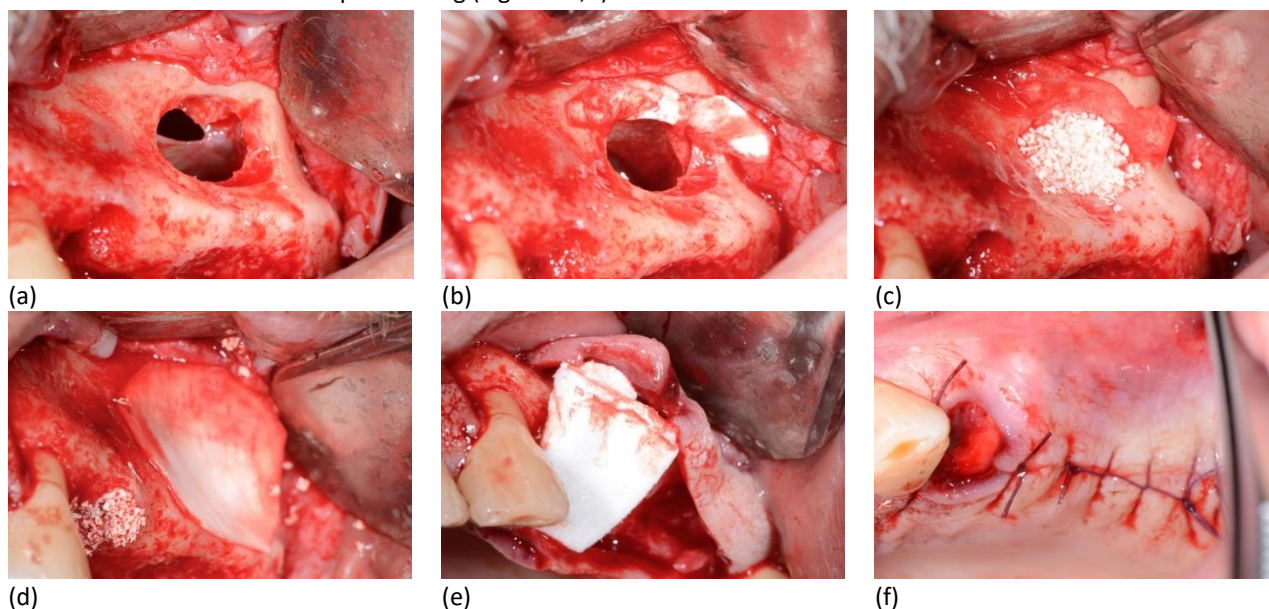


Figure 4. Patient 4: (a) Perforation of the Schneiderian membrane; (b) Application of Jason® membrane to heal the Schneiderian membrane; (c) Use of cerabone® to fill the sinus cavity; (d) Coverage with Jason® membrane to stabilize the granules and socket augmentation with cerabone®; (e) Coverage of the socket with collafleece®; (f) Open wound healing.

Results

Patient 1 had successful open healing and without any complications at 4 months after the operation (Figure 5). Here the successful implant integration and healthy peri-implant soft tissue allowed the production of individual abutments and tooth 26 was restored as a cantilever. The cerabone® particles were visible within the soft tissue and without any inflammatory reaction. This is a common finding and does not compromise the therapy, because the particles can be easily removed using a sharp instrument. Especially at tooth position 26, where the wound had open healing with collafleece®, looked very healthy, the volume was retained, and the soft tissue quality was excellent.

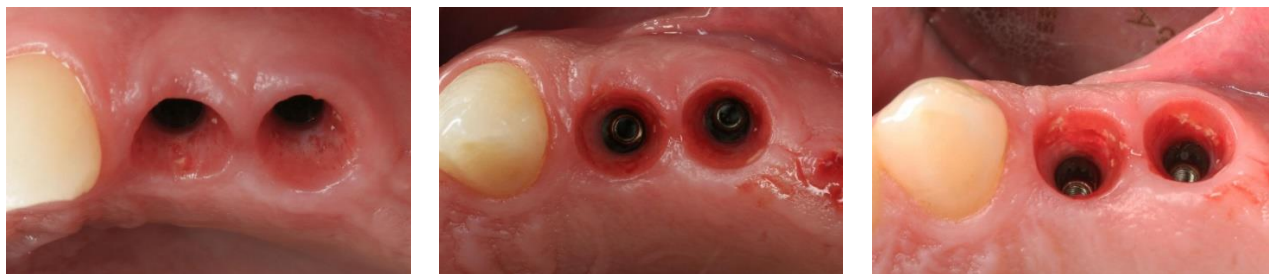


Figure 5. Patient 1: Healing at 4 months post-op.

Patient 2 had successful open healing and stable implant after four months (Figure 6c). First, a screw-retained temporary crown was made in accordance with the rules of immediate loading (Figure 6a). In addition to the fixed aesthetic restoration of the central incisor, the transmucosal section was conditioned with the desire to achieve the final emergence profile. A post-op control CT scan showed the desired bone substitute and implant position with a screw-

retained temporary crown (Figure 6b). Final healing after four months and emergence profile shape was achieved with a temporary crown as the peri-implant soft tissues were healthy and with satisfactory height and volume (Figure 6c).

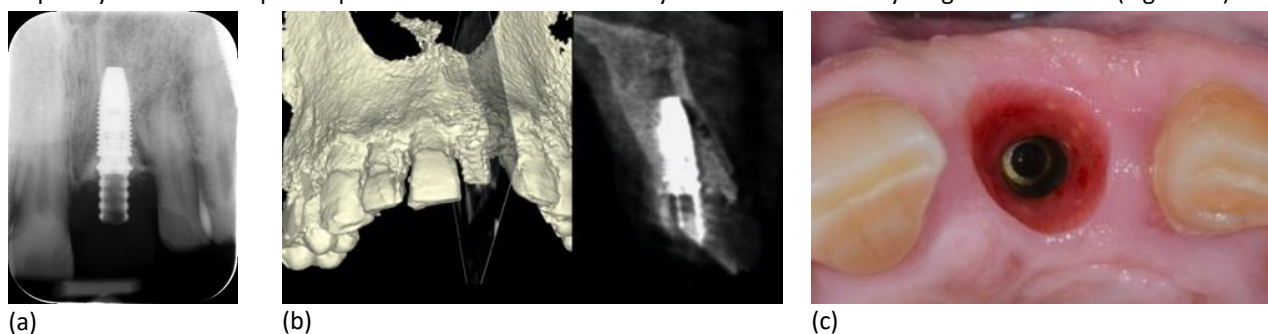


Figure 6. Patient 2: (a) Post OP dental x-ray shows implant & provisional crown with cerabone® particles on lateral sides; (b) Post OP CBCT shows cross sectional aspect of implant position, saved vestibular bone plate and defect filled with bone substitute; (c) Final soft tissue contour after four months shows nice emergence profile in its circumference and in its height.

Patient 3 had a stable integration of the cerabone® granules after 6 months re-entry (Figure 7a). Here the implants were successfully osseointegrated, which enabled fabricating a fixed prosthetic rehabilitation in the form of a bridge. Consequently, the healing abutments were inserted (Figure 7b) and the patient had very successful result after their removal (Figure 7c). Prosthetic rehabilitation was started after healing of the peri-implant mucosa for a period of 6 weeks.

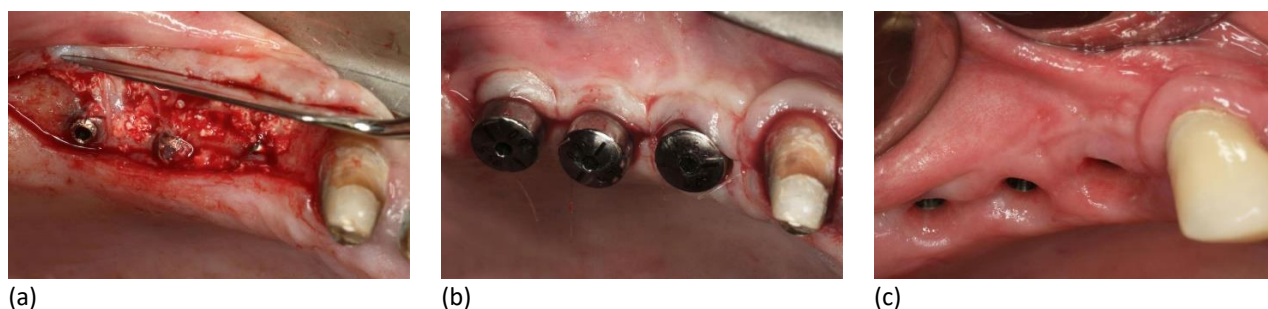

Figure 7. Patient 3: (a) Re-entry after 6 months; (b) Use of healing abutments; (c) Final soft tissue healing.

Patient 4 had successful open healing and 6 months later, a control 3D CBCT was performed (Figure 8a). The CT scan showed homogeneous osseointegration of the bone substitute within the newly formed bone, which enabled the future implants position planning (Figure 8b). Especially at position 24, the site of open healing and alveolar preservation, the bone substitute was fully integrated and well distributed, which was an excellent basis for the placement of future implants. The volume of newly formed bone in the sinus area was sufficient for a standard size implant placement, thus fulfilling all the conditions for the continuation of the implant-prosthetic therapy. More important, the alveolar ridge mucosa was healthy, firm, and keratinized, both in the distal (25,26,27) and post-extraction open healing site (Figure 8c). Also, the volume of the alveolar ridge was completely preserved.

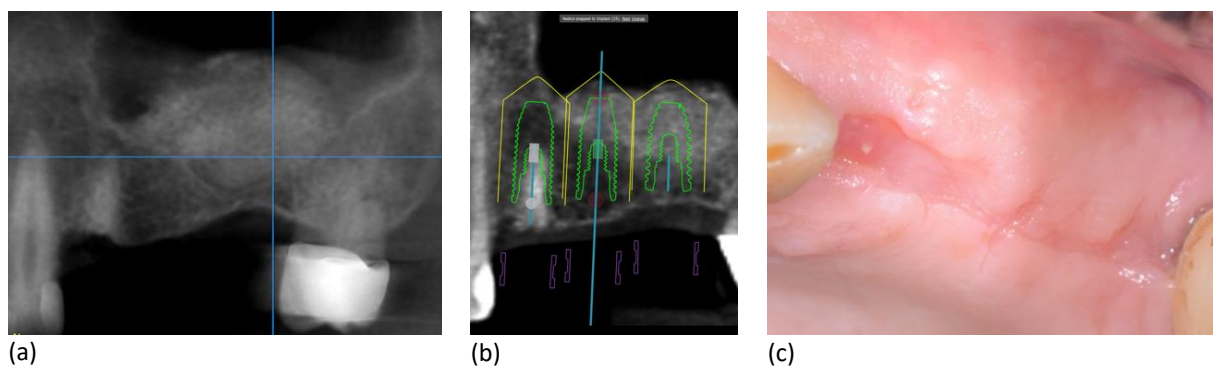


Figure 8. Patient 4: (a) CBCT and homogeneous cerabone® osseointegration after 6 months; (b) Implant planning in the grafted sinus; (c) Healthy, firm and keratinized alveolar ridge mucosa.

Discussion

The aim of this was to verify the healing capacity of a resorbable collagen sponge in combination with other biomaterials. Given the limitations of this study, we retrospectively analyzed four patients that underwent immediate implantation and sinus lift. The collagen sponge - collafleece® successfully supported the wound healing, controlled the bleeding, and assisted the healing of the Schneiderian membrane when combined with other biomaterials in immediate implantation and sinus lift.

Collagen sponges have been widely used in protection and hemostatic treatment of minor oral wounds, as well as protection of the Schneiderian membrane [12], [13]. In fact, the use of collagen sponges is recommended for the prevention of complications after teeth extraction low incidence of complications [12]. While the effectiveness of collagen membrane in the treatment of schneiderian membrane perforation has been widely investigated, the use of collagen sponges for the same indication has been poorly recorded [13]. They also find use in covering of biopsy or transplant harvesting sites and protection or hemostatic treatment after tooth extraction [4]. That is because they are highly effective hemostatic materials that undergo fast resorption by enzymatic degradation within 2-4 weeks [14]. As such, they almost immediately stabilize the blood clot and form the ``collagen-blood clot`` healing matrix [4].

The collagen fleece can be rolled into cylindrical shape, which is useful for an extraction wound (Figure 2b). It can be easily placed around the transmucosal element of the implant in single-phase immediate extraction with or without the use of bone substitutes, as well as in immediate implantation with immediate loading and temporary crown fabrication [15]. Here the fleece stabilizes the wound and supports its volume, which is very important in the aesthetic zone (Figure 1, 2). Socket seal effect with collagen fleece can be used in both immediate implantation and alveolar preservation [16]. The alveolar preservation requires the use of bone substitute, where it is necessary to seal the wound and stabilize the inserted bone substitutes. In such case, the collagen fleece can be double folded to obtain a four-layer sponge and then adjusted to the socket by stabilization with a suture (Figure 1). Such thickening by folding enhances the bone substitute stabilizing effect, which is beneficial for the wound healing and prevention of post-extraction resorption. On the other hand, the complete collagen fleece resorption ensures uninterrupted healing during the following months and the transformation of the bone substitute into newly formed bone (Figure 5, 6).

It is quite common to observe perforation in the Schneiderian membrane during preparation of the lateral sinus window (Figure 3, 4). In such case, critical assessment should be made whether to perform the procedure. To continue the sinus grafting, it is necessary to protect the graft from scattering within the sinus space. More specifically, the size, position and perforation shape are the key decision elements about the procedure. If the perforation is small, visible and with detached margins, the grafting can be continued after prior stabilization and perforation repair with collagen fleece (Figure 3). However, if the perforation margins are not detached, that makes the case more demanding and requires

long-lasting collagen barrier membrane to facilitate the perforation treatment, while using collagen fleece only to cover the socket and support open healing (Figure 4). In both cases, a homogeneous osseointegration of the bone substitute within the newly formed bone was observed, which enabled the following implant treatment (Figure 7, 8).

Based on fast regenerative mechanism, the collagen sponges could be successfully used in various healing indications [7]–[9]. For that reason, we analyzed the application of collafleece® in immediate implantation and sinus lift. Here the collagen was almost immediately resorbed and successful healing was achieved in all cases.

Conclusions

The current findings indicate that the collagen fleece successfully supported the wound healing, controlled the bleeding, and assisted the healing of the Schneiderian membrane. The use of collafleece® led to successful treatment when combined with other dental regeneration biomaterials in immediate implantation and sinus lift. Further study with larger number of patients is needed to verify our observations.

Funding and conflict of interest statement: The authors claim no conflict of interest and no funding or sponsorship was received for this work.

Board review and informed consent statement: In compliance with the Declaration of Helsinki (2013), the patients were informed orally and in written about the planned procedures and were given at least two weeks for consideration. The patients had the right to withdraw consent and to interrupt treatment at any time without reprisal. The local health authorities allow publication upon presence of informed consent and without any additional requirements.

References

- [1] R. Parenteau-Bareil, R. Gauvin, and F. Berthod, "Collagen-Based Biomaterials for Tissue Engineering Applications," *Materials (Basel)*, vol. 3, no. 3, p. 1863, 2010, doi: 10.3390/MA3031863.
- [2] M. Meyer, "Processing of collagen based biomaterials and the resulting materials properties," *Biomed. Eng. OnLine* 2019 181, vol. 18, no. 1, pp. 1–74, Mar. 2019, doi: 10.1186/S12938-019-0647-0.
- [3] N. Gallo, M. L. Natali, A. Sannino, and L. Salvatore, "An Overview of the Use of Equine Collagen as Emerging Material for Biomedical Applications," *J. Funct. Biomater.*, vol. 11, no. 4, Dec. 2020, doi: 10.3390/JFB11040079.
- [4] M. Zirk, T. Fienitz, R. Edel, M. Kreppel, T. Dreiseidler, and D. Rothamel, "Prevention of post-operative bleeding in hemostatic compromised patients using native porcine collagen fleeces-retrospective study of a consecutive case series," *Oral Maxillofac. Surg.*, vol. 20, no. 3, pp. 249–254, Sep. 2016, doi: 10.1007/S10006-016-0560-7.
- [5] R. W. Farndale, J. J. Sixma, M. J. Barnes, and P. G. De Groot, "The role of collagen in thrombosis and hemostasis," *J. Thromb. Haemost.*, vol. 2, no. 4, pp. 561–573, Apr. 2004, doi: 10.1111/J.1538-7836.2004.00665.X.
- [6] H. H. Versteeg, J. W. M. Heemskerk, M. Levi, and P. H. Reitsma, "New fundamentals in hemostasis," *Physiol. Rev.*, vol. 93, no. 1, pp. 327–358, Jan. 2013, doi: 10.1152/PHYSREV.00016.2011.
- [7] G. Menassa, A. R. Kassir, L. Landi, N. B. A. Naaman, and C. Chakar, "Implant placement with sinus floor elevation via the lateral approach using only absorbable collagen sponge: 12-month post-loading radiographical outcomes and implant survival rate," *Oral Maxillofac. Surg.*, vol. 25, no. 2, pp. 231–236, Jun. 2021, doi: 10.1007/S10006-020-00908-W.
- [8] C. Roberto, T. Paolo, C. Giovanni, C. Ugo, B. Bruno, and M.-F. Giovanni-Battista, "Bone remodeling around implants placed after socket preservation: a 10-year retrospective radiological study," *Int. J. Implant Dent.* 2021 71, vol. 7, no. 1, pp. 1–8, Jul. 2021, doi: 10.1186/S40729-021-00354-7.

- [9] Y. K. Kim, P. Y. Yun, H. J. Lee, J. Y. Ahn, and S. G. Kim, "Ridge preservation of the molar extraction socket using collagen sponge and xenogeneic bone grafts," *Implant Dent.*, vol. 20, no. 4, pp. 267–272, Aug. 2011, doi: 10.1097/ID.0B013E3182166AFC.
- [10] A. Hattingh, H. De Bruyn, M. Van Weehaeghe, G. Hommez, and S. Vandeweghe, "Contour Changes Following Immediate Placement of Ultra-Wide Implants in Molar Extraction Sockets without Bone Grafting," *J. Clin. Med.* 2020, Vol. 9, Page 2504, vol. 9, no. 8, p. 2504, Aug. 2020, doi: 10.3390/JCM9082504.
- [11] S. Kabi, R. Kar, D. Samal, K. C. Deepak, I. B. Kar, and N. Mishra, "Immediate dental implant placement with or without autogenous bone graft: A comparative study," *Natl. J. Maxillofac. Surg.*, vol. 11, no. 1, p. 46, Jan. 2020, doi: 10.4103/NJMS.NJMS_59_19.
- [12] H. Cho, H.-D. Jung, B.-J. Kim, C.-H. Kim, and Y.-S. Jung, "Complication rates in patients using absorbable collagen sponges in third molar extraction sockets: a retrospective study," *J. Korean Assoc. Oral Maxillofac. Surg.*, vol. 41, no. 1, p. 26, 2015, doi: 10.5125/JKAOMS.2015.41.1.26.
- [13] J. Y. Lee, J. J. Kwon, G. K. Sándor, and Y. D. Kim, "Effectiveness of Collagen Membrane in the Treatment of Schneiderian Membrane Perforation," *Appl. Sci.* 2019, Vol. 9, Page 1514, vol. 9, no. 7, p. 1514, Apr. 2019, doi: 10.3390/APP9071514.
- [14] Y. Kimura, T. Inamoto, and Y. Tabata, "Adipose tissue formation in collagen scaffolds with different biodegradabilities," *J. Biomater. Sci. Polym. Ed.*, vol. 21, no. 4, pp. 463–476, Mar. 2010, doi: 10.1163/156856209X424396.
- [15] K. Zeren, "Use of Bone Morphogenetic Protein-2 in Molar Extraction Sockets for Immediate Implant Placement: A Prospective Case Series," *Int. J. Periodontics Restorative Dent.*, vol. 38, no. 1, pp. 87–93, Jan. 2018, doi: 10.11607/PRD.2542.
- [16] S. Fickl, F. Kauffmann, C. Stappert, A. Kauffmann, and U. Schlagenhauf, "Scar Tissue Formation Following Alveolar Ridge Preservation: A Case Control Study," *Int. J. Periodontics Restorative Dent.*, vol. 38, no. 1, pp. e1–e7, Jan. 2018, doi: 10.11607/PRD.3347.