

Functional Outcome of Lisfranc Injury after Open Reduction and Internal Fixation with Transarticular Screws: A Prospective Observational Study

Authors:

¹S. Biju, ²Akhil Suseelan, ³R Shibu*,

¹ Associate Professor, ² Senior Resident, ³ Assistant Professor
^{1,2,3}Department of Orthopaedics Govt. Medical College, Trivandrum

Corresponding Author:

R. Shibu*, Assistant Professor,
Department of Orthopaedics, Govt Medical College, Trivandrum

Article Received: 22-10-2022

Revised: 12-11-2022

Accepted: 02-12-2022

ABSTRACT:

Introduction: The term 'Lisfranc injury' refers to an injury in which one or more of the metatarsals are displaced with respect to the tarsus. The use of this term is very broad and can refer to a low-energy sports injury or a high-energy lesion, as well as lesions that are purely ligamentous or those that are associated with fractures of the metatarsals, cuneiform bones, or cuboid bone. Early and accurate diagnosis of these injuries are fundamental requirements for their appropriate treatment and to prevent long-term sequelae. Early accurate diagnosis combined with prompt anatomical reduction and stable internal fixation provides optimal results. **Objectives:** To evaluate the functional outcome of Lisfranc injury after open reduction and internal fixation using transarticular screw fixation after a follow up of minimum period of 6 months using AOFAS midfoot score. **Methods:** The study was conducted as a prospective observational study at the Department of Orthopaedics, Government Medical College, Thiruvananthapuram during the period January 2020 to May 2021. Sixty eight consecutive patients of 20-70 years, who underwent surgical fixation for lisfranc injury using transarticular screw fixation were followed up. Functional outcomes at one year follow up were assessed. **Results:** Most of the patients were between age group of 31 to 40 with mean age 42(SD±1.2). In the study 41 were males (60.3%) and 27 (39.7%) were females. Road traffic accidents (RTA) was the mode of injury for 46 patients (68%). 18 (26%) sustained injuries due to fall from height and 4 (6%) due to crush injury. Eight patients (11.8%) had open fractures and 60 (88.2%) had closed injury. Anatomical reduction was obtained in 55 patients (81%). Post-operative arthritis was seen in 16 patients (23.5%), implant failure in 5 (7.4%) and 3 (4.4%) patients needed a second surgery. The mean AOFAS mid foot score was 78.8 (SD±1.62). Sixty one (89.7%) patients had good score ≥ 60 . **Conclusion:** The study with transarticular screw fixation for Lisfranc fractures showed very good functional outcome. Our results support the concept that stable anatomical reduction of fracture-dislocations of the Lisfranc joint leads to the best long-term outcomes. Although it was not free of complications, our study has shown very good results. Further biomechanical studies and clinical trials are required to evaluate the validity of screws for the treatment of Lisfranc injuries.

Keywords: Lisfranc injury, trans-articular screws, functional outcome

INTRODUCTION:

The osseous tarsal complex is comprised of the navicular, the cuboid, and the three cuneiform bones¹. Due to its positioning, resulting from a relative short intermedial cuneiform and sandwiched between the adjacent medial and lateral cuneiforms, the second metatarsal has been recognized as the keystone within this osseous scaffold^{1,2}. This architectural characteristic accounts for substantial bony stability. The cuboid is the keystone in the lateral column of the foot articulating with the calcaneus and the bases of the fourth and fifth metatarsals in the axial plane, and the navicular and the lateral cuneiform in the coronal plane. The navicular is the keystone in the medial

column. The tarso-metatarsal (TMT) joint complex is a three column system: the medial column (first TMT joint), the intermediate column (second/third TMT joints), and the lateral column (fourth/fifth TMT joints). The base of the second metatarsal is recessed between the medial and lateral cuneiforms which limits translation of the metatarsals in the frontal plane. In the coronal plane, the middle three metatarsal bases are trapezoidal, forming a transverse arch that prevents plantar displacement of the metatarsal bases. The second metatarsal base is the keystone in the transverse arch of the foot. The strong ligaments linking the bases of the second through fifth metatarsals forms the ligamentous support. The most important ligament is

Lisfranc ligament, which attaches the medial cuneiform to the base of the second metatarsal^{1,2}. Patients present with variable foot deformity, pain, swelling, and tenderness on the dorsum of the foot. Plantar ecchymosis is pathognomonic for a Lisfranc injury. Compartment syndrome of the foot must be ruled out by compartment pressure monitoring². Operative treatment should be considered when displacement of the tarsometatarsal joint is 2 mm^{3,4}. The best results are obtained through anatomic reduction and stable fixation⁴. The approach is by using two longitudinal incisions. The first is centered over the first intermetatarsal space, allowing access to the medial two tarsometatarsal joints. A second longitudinal incision is made over the fourth metatarsal. The key to reduction is correction of the fracture-dislocation of the second metatarsal base³. Accuracy and maintenance of reduction are of utmost importance. Once reduction is accomplished, screw fixation is advocated for the medial column³. The lateral metatarsals frequently reduce with the medial column, and Kirschner(K) wire fixation is acceptable. Primary arthrodesis for the treatment of Lisfranc injuries has also been advocated⁵. Dorsal and/or medial plating also can be used for fixation, which avoids damage to articular surfaces. Studies show that the strength of fixation is similar to that of transarticular screws⁶ and that clinically anatomic reduction can be obtained with good clinical outcomes. For high energy injuries in which soft-tissue compromise is significant, consideration should be given to temporary external fixation or k-wire fixation^{5,7} after closed reduction until the soft tissues allow for definitive fixation. Lisfranc injuries if untreated or diagnosed late can lead to severe long term sequelae such as post traumatic osteoarthritis and foot deformities such as pes cavus^{8,9}. Early accurate diagnosis combined with prompt anatomical reduction and stable internal fixation provide optimal results^{4,6}. This study was done to assess the functional outcome after open reduction and internal fixation with transarticular screws.

MATERIAL AND METHODS

The study was done as a prospective observational study at Department of Orthopaedics, Government Medical College Thiruvananthapuram during the period January 2020 to May 2021, after getting IEC clearance (HEC No. 04/22/2021/MCT). 68 consecutive patients of 15-70 age group with Lisfranc fractures who satisfy the selection criteria were recruited for the study after getting written informed consent. The inclusion criteria were- patients of age group 15- 70 years of either sex, closed or open Lisfranc fractures of Gustilo grade-1 and 2, patients who have given written informed consent. The exclusion criteria were- Patients with previous disability or foot surgery, patients with severe comorbidities, who were not willing to give consent,

multiple trauma and open fracture with Gustilo Grade-III. The patients were treated with open reduction and transarticular screw fixation. Patients were followed up at 1 month,3 month,6 month and 1 year by using a validated questionnaire 'AOFAS midfoot score'. American Orthopaedic Foot and Ankle Society (AOFAS) score is based on pain, deformity, surgical site infection, range of ankle and foot movements, walking ability with or without support and radiological evaluation of union, implant failure, osteoarthritis. An AOFAS score ≥ 60 out of 100 implies good functional outcome. Data was collected using patient case records, case interviews and clinical examination. Data were entered into Excel sheet. Categorical variables were expressed as proportions and quantitative variables as mean and standard deviation. Analysis of data was done using statistical software (IBM SPSS Statistics 27).

Surgical Technique:

All cases were done under spinal anaesthesia. Open injuries were treated with irrigation and debridement accompanied by open reduction and internal fixation or staged temporary external fixation^{3,4} with later open reduction and internal fixation. Operative treatment of closed injuries was delayed until soft-tissue swelling subsided. Operative reduction and fixation proceeded from a medial to a lateral direction. The first and second tarsometatarsal joints were approached through a single dorsal incision over the first intermetatarsal space. The first and second metatarso-cuneiform joints were opened and irrigated. Comminuted fragments were reduced when possible; smaller, irreducible fragments were removed. The first tarso-metatarsal joint was aligned by reducing the medial border of the medial cuneiform to the medial border of the first metatarsal. The plantar-medial aspect of the joint was directly visualized to ensure that there was no plantar gap. The joint was held reduced with a provisional Kirschner wire, and then one 3.5mm transarticular countersunk cortical screw was inserted from the metatarsal base proximally into the medial cuneiform. If instability persisted, an additional 3.5mm screw was placed from proximal to distal and lateral to the first screw to add rotational stability. The second metatarsal was then reduced to the medial border of the middle cuneiform and was held provisionally with a Kirschner wire. A 3.5mm countersunk cortical screw was placed from distal to proximal across the joint. An additional screw (the Lisfranc screw) was inserted under biplanar fluoroscopy from the medial cuneiform into the base of the second metatarsal to increase the stability of the fixation. When the third metatarsal base was dislocated, a second dorsal incision was made between the third and fourth metatarsals to expose the third metatarso-cuneiform joint. This joint was then reduced and was stabilized with a 3.5mm screw from a distal to a proximal direction. The fourth and fifth

tarsometatarsal joints usually reduced once the above three reductions were achieved, and they were held with one or two transarticular percutaneous Kirschner wires from the base of the fifth metatarsal into the cuboid. Open reduction of these lateral two joints was required in only four patients. The alignment of the fractures and tarsometatarsal joints and the position of the implants were checked with fluoroscopy. A short leg splint was applied at the end of the procedure with the ankle in the plantigrade position. It was worn for two weeks, and then a short leg non-weight bearing cast was worn for an additional four weeks. At six weeks, the percutaneous lateral Kirschner wires were removed. The patients were then advanced to full weight-bearing in a walking boot over four to six weeks.

RESULTS:

Most of the patients were between age group of 31 to 40 with mean age 42(SD±1.2) (Table-1). In the study 41 were males (60.3%) and 27 (39.7%) were females (Table-2). Road traffic accidents (RTA) was the mode of injury for 46 patients (68%). 18 (26%) sustained injuries due to fall from height and 4 (6%) due to crush injury (Table-3). 18 patients (26.5%) were smokers and 18 (26.5%) had diabetes mellitus and 5 patients (7.4%) had peripheral occlusive vascular disease (POVD) (Table-4). Eight patients (11.8%) had open fractures and 60 (88.2%) had closed injury (Table-5). Forty (58.8%) had metatarsal fractures, 23 (33.8%) had cuboid fractures and 15 (22.1%) had associated cuneiform fractures (Table-6). Anatomical reduction was obtained in 55 patients (81%) (Table-7). Post-operative arthritis was seen in 16 patients (23.5%), implant failure in 5 (7.4%) and 3 (4.4%) patients needed a second surgery (Table-8). The mean AOFAS mid foot score was 78.8 (SD±1.62). Sixty one (89.7%) patients had good score ≥60 (Table-9).

Table 1: age distribution

Age group	N	Percent (%)
Up to 20	3	4.4
21-30	7	10.3
31-40	21	30.9
41-50	19	27.9
51-60	15	22.1
61-70	3	4.4

Table 2 : Gender distribution

Sex	Frequency	Percent (%)
Male	41	60.3
Female	27	39.7
Total	68	100

Table 3 : Mode of injury

Mode Of Injury	Frequency	Percentage
Road traffic accident	46	68
Fall from height	18	26
Crush injury	4	6
Total	68	100

Table 4: habits and co morbidities

Habits/ co morbidities	Number	Percentage%
Peripheral occlusive vascular disease	5	7.4
Diabetes mellitus	18	26.5
Smoking	18	26.5

Table 5: type of injury

Type Of Fracture	Number	Percentage
Open	8	11.8
Closed	60	88.2
Total	68	100

Table 6: Fractured bone

Fractured Bone	Number	Percentage
Cuboid fracture	23	33.8
Cuneiform fracture	15	22.1
Metatarsal fracture	40	58.8

Table 7: type of surgical reduction

Type Of Reduction	Number	Percentage
Anatomical	55	81
Non anatomical	13	19
Total	68	100

Table 8: complications

Complications on follow up	Number	Percent (%)
Post-operative Osteoarthritis	16	23.5
Implant failure	5	7.4
Second surgery	3	4.4

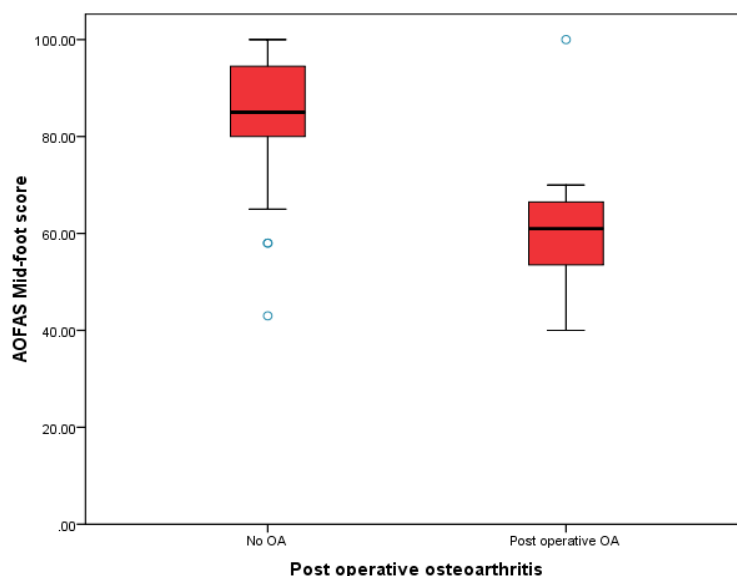
Table 9: AOFAS mid foot score

Score range	Frequency	Percentage
40-49	5	7.4
50-59	2	2.9
60-69	11	16.2
70-79	9	13.2
80-89	21	30.9
90-100	20	29.4

Table 10: summary of outcome scores

Subgroup		Number of patients	Mean AOFAS mid foot score	p value
Base of metatarsal fracture	Yes	40	75.7	0.54
	No	28	83.3	
Cuneiform/Cuboid fracture	Yes	33	76.2	0.203
	No	35	81.2	
Type of injury	Open	8	74.3	0.411
	Closed	60	79.4	
Time of diagnosis	Early	62	79.6	0.188
	Delayed	6	70.5	
Type of reduction	Anatomical	55	81.9	0.001
	Non-anatomical	13	65.4	
Postoperative OA	Yes	16	60.8	<0.001
	No	52	84.3	
Implant failure	Yes	5	53.6	<0.001
	No	63	80.8	
Second surgery	Yes	4	48.5	<0.001
	No	64	80.7	

Fig 1: Relation between AOFAS score and postoperative osteoarthritis



DISCUSSION:

The Lisfranc injury constitutes 0.2% of all fractures or dislocations with incidence of 1 in 55,000 people every year^{1,2,10}. Almost 20% of fractures are missed initially. It usually occurs after high-energy collision such as motor vehicle accident^{1,10}. The most common mode of injury in our study was road traffic accident (68%). Males predominated in the study (60.3%), with male to female ratio 3:2. The mean age of patients was 42. The mean age in most of studies are around 40 years with male preponderance^{5,6,11}. The accuracy of post-operative reduction was determined in x-ray by the following- the first and second metatarsal distance, continuous line from medial side of second metatarsal and intermediate cuneiform on antero-posterior view, and continuous line from medial side of fourth metatarsal and cuboid on oblique view¹¹. Fifty five (81%) patients in this study obtained anatomical reduction. Anatomical reduction and stable internal fixation has become a standard principle governing treatment of tarsometatarsal fracture-dislocations. Most authors have agreed that stable anatomical reduction leads to optimal results^{11,12,13}. Our study supports this concept as patients with anatomical reduction had a significantly better average AOFAS score ($p = 0.001$) and a significantly lower prevalence of secondary osteoarthritis ($p = 0.001$) (Table-10). The advantage of open reduction is that it allows direct visualization of the fracture-dislocation for the debridement of comminuted fracture fragments, soft tissue, and osteochondral debris. This facilitates precise reduction of the fracture^{11,14}. An AOFAS mid foot score ≥ 60 implies good clinical outcome. Sixty one (89.7%) patients treated with transarticular screws

had mid foot score ≥ 60 . The mean AOFAS mid foot score was 78.8. Most of the patients with AOFAS mid foot score < 60 had postoperative osteoarthritis (Fig-1). Osteoarthritis was seen in 23.5% and 7.4% had implant failure. Second surgery was needed in 3 patients (4.4%). The results in this study were comparable with that of previous studies^{11,12,13,15}.

CONCLUSION:

The study with transarticular screw fixation for Lisfranc fractures showed very good functional outcome. Our results support the concept that stable anatomical reduction of fracture-dislocations of the Lisfranc joint leads to the best long-term outcomes. Although it was not free of complications, our study has shown very good results. Further biomechanical studies and clinical trials are required to evaluate the validity of screws for the treatment of Lisfranc injuries.

REFERENCES:

1. Benirschke SK, Meinberg E, Anderson SA, Jones CB, Cole PA. Fractures and dislocations of the midfoot: Lisfranc and Chopart injuries. *J Bone Joint Surg [Am]* 2012;94(14):1325–1337.
2. Gotha HE, Lareau CR, Fellars TA. Diagnosis and management of lisfranc injuries and metatarsal fractures. *Orthop Rehabil* 2013;96(5):33–6.
3. Bandac RC, Botez P. Lisfranc midfoot dislocations: correlations between surgical treatment and functional outcomes. *Rev Med Chir Soc Med Nat Iasi* 2012;116(3):834–9.

4. Schepers T, Oprel PP, Van Lieshout EM. Influence of approach and implant on reduction accuracy and stability in Lisfranc fracture-dislocation at the tarsometatarsal joint. *Foot Ankle Int.* 2013;3,4(5):705-710.
5. Smith N, Stone C, Furey A. Does open reduction and internal fixation versus primary arthrodesis improve patient outcomes for Lisfranc trauma? A systematic review and meta-analysis. *Clin Orthop Relat Res.* 2016; 474(6):1445-1452.
6. Lau S, Guest C, Hall M, et al. Functional outcomes post Lisfranc injury—transarticular screws, dorsal bridge plating or combination treatment? *J Orthop Trauma.* 2017;31(8): 447-452.
7. Herscovici D Jr , Scaduto JM . Acute management of high-energy lisfranc injuries: A simple approach. *Injury* 2018;49(2):420–424.
8. Podolnick JD , Donovan DS , DeBellis N , Pino A . Is pes cavus alignment associated with Lisfranc injuries of the foot? *Clin Orthop Relat Res* 2017;475(5):1463–1469.
9. Panagakos P, Patel K, Gonzalez CN. Lisfranc arthrodesis. *Clin Podiatr Med Surg.* 2012 Jan;29(1):51–66.
10. Yan A, Chen SR, Ma X, Shi Z, Hogan M. Updates on Lisfranc Complex Injuries. *Foot Ankle Orthop.* 2021 Jan 25;6(1):2473011420982275.
11. Stavlas, P.; Roberts, C. S.; Xypnitos, F. N.; and Giannoudis, P. V.: The role of reduction and internal fixation of Lisfranc fracture-dislocations: a systematic review of the literature. *Int Orthop,* 34(8): 1083-91, 2010.
12. Schepers T, Oprel PP, Van Lieshout EMM. Influence of approach and implant on reduction accuracy and stability in lisfranc fracture-dislocation at the tarsometatarsal joint. *Foot Ankle Int.* 2013 May;3,4(5):705–10.
13. Qiao Y, Li J, Shen H, Bao H, Jiang M, Liu Y, et al. Comparison of Arthrodesis and Non-fusion to Treat Lisfranc Injuries. *Orthop Surg.* 2017 Mar 9;9(1):62–8.
14. Buda M, Kink S, Stavenuiter R, Hagemeyer CN, Chien B, Hosseini A, et al. Reoperation Rate Differences Between Open Reduction Internal Fixation and Primary Arthrodesis of Lisfranc Injuries. *Foot Ankle Int.* 2018 Sep;39(9):1089–96.
15. Mascio A, Greco T, Maccauro G, Perisano C. Lisfranc complex injuries management and treatment: current knowledge. *IntJ Physiol Pathophysiol Pharmacol.* 2022 Jun 15;14(3):161–70.

