



INTERNATIONAL JOURNAL OF CLINICAL PHARMACOKINETICS AND MEDICAL SCIENCES

Published by Pharma Springs Publication Journal Home Page: <https://pharmasprings.com/ijcpms/>

An Observational Prospective Study on Treatment of Pemphigus Vulgaris and Pemphigus Foliaceus

Shring Sandilya^{*1}, Anuska Khakhlari¹, Akshay Prasad Ramani², Tanya Verma³, Mohit Buddhadev¹

¹Parul Institute of Pharmacy and Research, Vadodara-391760, Gujarat, India

²Parul Institute of Pharmacy, Gujarat, India

³NET Pharmacy College, Raichur-584103, Karnataka, India



Article History:

Received on: 15 Aug 2021

Revised on: 18 Sep 2021

Accepted on: 20 Sep 2021

Keywords:

Pemphigus,
Prednisone,
Pulse Therapy,
Clinical Protocols,
Immunosuppressive
Agents

ABSTRACT

Pemphigus vulgaris and Pemphigus foliaceus are chronic, painful diseases which treatment causes great impact. This study focuses on age, gender, mucosal lesions, therapy with oral prednisone, clinical remission rates and side effects. Six males/15 females with Pemphigus vulgaris and three males/six females with non-endemic pemphigus foliaceus attended at a tertiary care hospital in a period of 12 months were submitted to histopathology through skin or mucosa biopsy. Oral prednisone (monotherapy) in seven Pemphigus vulgaris and two pemphigus foliaceus; in case of no control or relapses, association with cyclophosphamide pulse therapy (12PV/4PF), dexamethasone pulse therapy (ten PV/two PF), hydroxychloroquine (three PV/four PF), azathioprine (five PV), methotrexate (four PV/one PF), immunoglobulin cycles (two PV/two PF). Mostly patients were female aged 30-59 years old; oral mucosal lesions in 19 (90,4%) pemphigus vulgaris. After a certain period of monitoring it was observed in the group of monotherapy: one PV/one PF achieved complete remission on low dose of prednisone; two PV achieved partial remission on low dose and four PV/one PF on high dose. In the group with combined drugs, four PV were off prednisone, four PV/one PF achieved complete remission on low dose and two PF on high dose; two PV/three PF achieved partial remission on low dose and four PV/one PF on high dose. The most common side effects of prednisone were mucocutaneous candidiasis, arterial hypertension, subcapsular posterior cataracts, bacterial and viral infections and diabetes mellitus. Both diseases ran a chronic and unpredictable course which management was extremely difficult. Females with pemphigus vulgaris developed severe multiple mucosal lesions.

*Corresponding Author

Name: Shring Sandilya

Phone:

Email: shringsandilya86@gmail.com

eISSN: 2583-0953

DOI: <https://doi.org/10.26452/ijcpms.v1i3.229>



Production and Hosted by

Pharmasprings.com

© 2021 | All rights reserved.

INTRODUCTION

Pemphigus vulgaris and Pemphigus foliaceus are chronic, painful diseases which treatment causes great impact. This study focuses on the age, gender, mucosal lesions, therapy with oral prednisone, clinical remission rates and Side effects. Pemphigus vulgaris (PV) is an autoimmune bullous disorder of the skin and mucous membranes which runs an unpredictable course and prognosis. Endemic Pemphigus foliaceus (PF) in South America occurs particularly in Brazil where it is known as fogo selvagem. Differs from sporadic non - endemic PF for

high incidence in rural areas, mostly in children and young adults (20-30 years old), affecting both sexes equally besides familial incidence. Both forms of PF have not mucous membrane involvement even with widespread disease. We present an observational prospective study of the clinical course of PV and non - endemic PF over 15 years period [1, 2].

MATERIAL AND METHODS

Six males/15 females with Pemphigus vulgaris and three males/six females with non-endemic Pemphigus foliaceus attended at a tertiary care hospital were submitted to histopathology through skin or mucosa biopsy. Oral prednisone (monotherapy) in seven PV and two PF; in case of no control or relapses, association with cyclophosphamide pulse therapy (12 PV/4 PF), dexamethasone pulse therapy (ten PV/two PF), hydroxychloroquine (three PV/ four PF), azathioprine (five PV), methotrexate (four PV/one PF), immunoglobulin cycles (two PV/two PF).

Twenty-one cases of PV and nine cases of non-endemic PF diagnosed through histopathological skin biopsy exam were investigated at tertiary care hospital.

- All patients were submitted to an initial treatment with oral prednisone in single morning daily dose (Figure 1).
- Before starting the systemic immunosuppressive agents, the following tests were performed: complete blood count, renal and liver function tests, fasting lipid profile, hepatitis panel, stool examination, urinalysis, thorax X-Rays, ophthalmological examination, prophylaxis for *Strongyloides stercoralis*; close following for signs or symptoms of infection or malignancy.
- Criteria for adding cyclophosphamide, dexamethasone, azathioprine, methotrexate and immunoglobulin: refractoriness to initial oral prednisone; severe relapses; in those cases of prednisone maintenance dose > 20 mg; to prevent corticosteroid side effects.
- Criteria for adding hydroxychloroquine: photo-distributed lesions of Pemphigus vulgaris and foliaceus. Previous and yearly ophthalmological examination. Dose: 6.5 mg/Kg/day
- Contraception during the use of cyclophosphamide, azathioprine and methotrexate in female patients of childbearing age.

a. Pulse therapy [2, 3]

- Cyclophosphamide: Dose: 600 mg/m² corporal area each 3 weeks in IV infusion.
- Ondansetron: Dose: 8 mg IV infusion immediately before the cyclophosphamide
- Dexamethasone: Amylase and electrocardiogram before pulses. Dose: 100 mg/day for 3 days at each 2-3 weeks interval or 100 mg/weekly in 500 ml of 5% dextrose as slow IV infusion over 2 hours.

b. Azathioprine: 2-3 mg/kg/day

c. Methotrexate: 20 mg weekly subcutaneous.

d. Immunoglobulin (IVIG)- 400 mg/kg/day intravenously for five days at monthly interval cycles.

6. Complete remission of the diseases was defined as no new lesions appearing for the last seven days and complete healing of cutaneous and mucosal lesions. Partial remission was defined up to three active mucosal lesions and up to ten cutaneous lesions. Low maintenance dose of prednisone was defined as 2.5 mg - 10 mg and high maintenance dose as >10 mg.

7. The following variables were analyzed: age, gender, multiplicity of mucosal lesions (patients with PV), clinical remission rates and oral corticosteroid side effects.

RESULTS

Mostly patients were female aged 30-59 years old; oral mucosal lesions in 19 (90.4%) PV. After a certain period of monitoring it was observed in the group of monotherapy: one PV/one PF achieved complete remission on low dose of prednisone; two PV achieved partial remission on low dose and four PV/one PF on high dose. In the group with combined drugs, four PV were off prednisone, four PV/one PF achieved complete remission on low dose and two PF on high dose; two PV/three PF achieved partial remission on low dose and four PV/one PF on high dose. The most common side effects of prednisone were mucocutaneous candidiasis, arterial hypertension, sub-capsular posterior cataracts, bacterial and viral infections and diabetes mellitus.

A peak incidence was found to occur in the fourth decade of life for PV and there was a predominance of the females (Table 1). Mucosal lesions were detected in PV patients as follows: oral (19/90.4%); nasal (7/33%); laryngeal (6/28.5%) confirmed by laryngoscopy; vaginal (6/28.5%); esophageal (3/23%) confirmed by endoscopy; conjunctival (2/9.5%), perianal (1/4.7%).

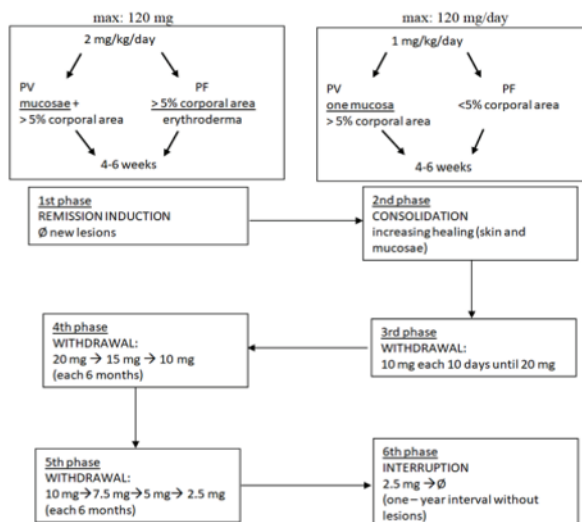


Figure 1: Oral Prednisone

Table 1: Distribution of Cases According to Age and Gender

S.No	Age	PV		PF		Total
		Male	Female	Male	Female	
1.	20-29	1	1	1	-	3
2.	30-39	2	3	1	-	6
3.	40-49	2	6	-	3	11
4.	50-59	1	3	1	1	6
5.	60-69	-	1	-	1	2
6.	70-79	-	1	-	-	1
7.	80-89	-	-	-	1	1

Table 2: Distribution of Cases According to Clinical Remission in Treated Patients with Prednisone

Prednisone	No. of Cases				Total	
	Complete Remission		Partial Remission			
	Low dose 2.5-10 mg	High dose >10 mg	Low dose 2.5-10 mg	High dose >10 mg		
PV	-	1	-	2	4	7
PF	-	1	-	-	1	2
Total	-	2	-	2	5	9

Table 3: Distribution of Cases According to Clinical Remission in Treated Patients with prednisone + other immunosuppressive agents

Prednisone	No. of Cases				Total	
	Complete Remission		Partial Remission			
	Low dose 2.5-10 mg	High dose >10 mg	Low dose 2.5-10 mg	High dose >10 mg		
PV	4	4	-	2	4	14
PF	-	1	2	3	1	7
Total	4	5	2	5	5	21

Prednisone was administered as oral monotherapy (Figure 1) in 7 PV/2 PF cases. In combination with cyclophosphamide pulse therapy: 12 PV (on average ten pulses)/four PF (on average seven pulses); with dexamethasone pulse therapy: ten PV (on average eight pulses)/two PF (on average five pulses); with hydroxychloroquine: three PV/four PF; with azathioprine: five PV; with methotrexate: four PV/one PF; with IVIG: two PV (five cycles)/two PF (two cycles) [4–6]. Patients were divided into two groups according to clinical remission after ten-year follow-up; those treated with prednisone only (n= 9) (Table 2) and those submitted to a combined scheme (n=21) (Table 3).

A complete remission was achieved by two patients (one PV/one PF) on low dose of prednisone; a partial remission by two PV on low dose and by five (four PV/one PF) on high dose (Table 2). Four patients (PV) were off prednisone; five patients (four PV/one PF) achieved complete remission on low dose of prednisone and two PF on high dose; five patients (two PV/three PF) achieved partial remission on low dose and five (four PV/one PF) on high dose (Table 3). The most common side effects of corticosteroid (both groups) were mucocutaneous candidiasis (18/60%); arterial hypertension (17/55.6%); subcapsular posterior cataracts (11/36.6%); bacterial and viral infections (10/36.6%) diabetes mellitus (10/36.6%); gastroesophageal reflux disease (6/20%); obesity (5/16.6%).

DISCUSSION

Patients with PV and those with PF display similar direct and indirect immunofluorescence findings with IgG in the cell surface of epidermal cells throughout the epidermis. Therefore, it is not possible to differentiate both diseases by the pattern of immunofluorescence. Considering the typical clinical and histopathological picture, direct and indirect immunofluorescence seemed unnecessary. We have previously observed a homogeneous distribution of PV from the third decade and an increased frequency on the third and sixth decades for PF. The female predominance in pemphigus is in accordance with these series [2, 4, 5]. In the present investigation, laryngeal lesions and esophageal occurred exclusively in females with PV. The vaginal lesions remained active for a long period after cutaneous lesions' remission (four years). The mucosae involvement is currently refractory to treatment, specially the laryngeal [7, 8].

Guidelines vary in their recommendations, on the starting dose of prednisone in treating pemphigus.

The consensus is that the initial dose is 0.5–1.5 mg/Kg depending on the severity. Recent consensus guidelines recommended decreasing prednisone dose every two weeks until 20 mg/day is reached. Then decrease by 2.5 mg every week until 10 mg daily dose is reached (9). In the present study higher initial doses of prednisone and slower tapering were used (Figure 1). Evidence-based tapering regimens are not available. In this study patients with arterial hypertension and diabetes were encouraged to a lifestyle modification, and proper nutrition besides blood pressure and diabetic medications. They were referred to an ophthalmologist annually to detect signs of cataract development. Adjuvant therapy with cyclophosphamide brought rare immediate adverse effects (nausea, dyspepsia); delayed effects as diffuse scalp hair loss and generalized hyperpigmentation were not observed; hemorrhagic cystitis, myelotoxicity, Stevens Johnson syndrome, amenorrhea and leucopenia were observed one case from each. Although cyclophosphamide resulted in need for a smaller maintenance dose of prednisone it did not prevent multiple recurrences in the course of the diseases. The steroid-sparing effects of cyclophosphamide are demonstrated in the literature, but relapses occurred during therapy [9, 10].

Pulsed intravenous dexamethasone aimed to achieve a rapid control in case of extensive and progressive PV, erythrodermic PF and relapses. Clinical and dermatological improvement were observed within 2 weeks. No adverse effects during infusion pulse days of dexamethasone. Elevated serum amylase (twice) was transient and asymptomatic. It has been observed an effect on bone mineral density. In the present study, prophylactic prevention of fractures was done with oral vitamin D (800 UI/day) and calcium (1 gm/ day). As osteonecrosis of the jaws can result either from radiation used in radiotherapy for treatment of malignant tumors or from the bisphosphonates use, we have avoided them [11]. In the present study, the photoprotective effects of hydroxychloroquine for one year were defined by the decrease in the frequency of new lesions and allowing tapering of prednisone (1PV/2PF) [12]. The steroid-sparing effect from addition of azathioprine was achieved when the dose was increased to 3 mg/kg. Although azathioprine resulted in need for a smaller maintenance dose of prednisone, it did not prevent the recurrences. A systematic review [9] indicates a positive sparing effect of azathioprine. Methotrexate is considered as a useful and well-tolerated therapy with considerable steroid-sparing effect in patients with PV [13]. Our patients experienced a

therapeutic benefit after 6 months, but the drug was stopped for abnormalities in the hepatic enzymes. The IVIG was prescribed for progressive, extensive PV and PF cases although the efficacy is controversial. High dose IVIG may be recommended [14] for patients who do not achieve clinical remission while on the recommended therapy. In the present study the drugs – cyclophosphamide, dexamethasone, azathioprine, IVIG – initially allowed the clearing of lesions and tapering of corticosteroid but did not prevent further relapses [2]. Pemphigus is a chronic disease and subjected to acute exacerbations. The long course makes the patients to discontinue the therapy. Relapses were triggered by infections, by tapering the corticosteroids, by stress or by unknown etiologies. They occurred in both groups (only prednisone/prednisone in combination).

In PF cases we could observe that hot weather plus humidity and sun exposure worsened the clinical picture. One death occurred in a female with PV (shock and sepsis) who developed toxic epidermal necrolysis linked to sulfamethoxazole-trimethoprim employed for a kidney infection. The superimposed drug reaction to a relapse of PV contributed to the outcome. Some authors [7] point out that prophylaxis for *Pneumocystis carinii* should be considered in those on long term oral corticosteroids or other immunosuppressive. We chose the strict monitoring for symptoms and signs of infection. All patients required hospitalization for multiple relapses and comorbidities. In our investigation, the relapses were seen even in patients who were initially successful. According to some reports [1, 15], 3, 5% of PV patients achieved complete remission off therapy after two years, 10.3% after five years or 25% after ten years. In the present study, 19% of PV patients achieved complete remission off therapy after 10 years while PF patients did not achieve it. Perhaps these data may reflect different methodological approaches: the estimation of the severity of the disease as well as in the criteria to designate off therapy status. Low adherence to treatment is still to be assessed as an important variable. Work and family related reasons, financial problems, complications of treatment, traveling long distance and other illnesses have been pointed out as possible causes.

CONCLUSION

Both diseases ran a chronic and unpredictable course which management was extremely difficult. Females with pemphigus vulgaris developed severe multiple mucosal lesions. Our study revealed a protracted course of both pemphigus and a remark-

able severity of PV in females who developed multiple and refractory mucosal lesions. The descriptive analysis of the data did not allow concluding the role of prednisone alone or in combination.

ACKNOWLEDGEMENT

Thankful to all the medical staff and paramedical staff who were supported us to collect the relevant information for this project.

Funding Support

The authors declare that they have no funding support for this study.

Conflict of Interest

The authors declare that there is no conflict of interest.

Ethical Issues

We conducted the research in the presence of registered physician and obtained the consent form from the patients enrolled.

REFERENCES

- [1] K. E. Harman, D. Brown, L. S. Exton, R. W. Groves, P. J. Hampton, M. F. Mohd Mustapa, J. F. Setterfield, and P. D. Yesudian. British Association of Dermatologists' guidelines for the management of pemphigus vulgaris 2017. *British Journal of Dermatology*, 177(5):1170–1201, 2017.
- [2] N C Fernandes and M Perez. Treatment of pemphigus vulgaris and pemphigus foliaceus: experience with 71 patients over a 20 year period. *Revista Do Instituto de Medicina Tropical de São Paulo*, 43(1):33–36, 2001.
- [3] Pradeep K. Sethy, Sujay Khandpur, and Vinod K. Sharma. Randomized open comparative trial of dexamethasone+cyclophosphamide pulse and daily examethasone+cyclophosphamide pulse and daily oral cyclophosphamide versus cyclophosphamide ral cyclophosphamide versus cyclophosphamide pulse and daily oral prednisolone in pemphigus ulse and daily oral prednisolone in pemphigus vulgaris. *Indian Journal of Dermatology, Venereology and Leprology*, 75(5):476–482, 2009.
- [4] N C Fernandes and Vanessa M Zubaty. Cyclophosphamide pulse therapy in pemphigus: report of seven cases. *Anais Brasileiros de Dermatologia*, 80(2):165–168, 2005.
- [5] N C Fernandes and Mariana Menezes. Pulse therapy in pemphigus: report of 11 cases.

- Anais Brasileiros de Dermatologia*, 88(4):672–675, 2013.
- [6] Sakthi Kandan and Devinder Mohan Thappa. Outcome of dexamethasone-cyclophosphamide pulse therapy in pemphigus: a case series. *Indian Journal of Dermatology, Venereology and Leprology*, 75(4):373–378, 2009.
- [7] Richelle M. Knudson, Amer N. Kalaaji, and Alison J. Bruce. The management of mucous membrane pemphigoid and pemphigus. *Dermatologic Therapy*, 23(3):268–280, 2010.
- [8] M. Kavala, S. Altıntaş, E. Kocatürk, I. Zindancı, B. Can, Ç. Ruhi, and Z. Turkoglu. Ear, nose and throat involvement in patients with pemphigus vulgaris: correlation with severity, phenotype and disease activity. *Journal of the European Academy of Dermatology and Venereology*, 25(11):1324–1327, 2011.
- [9] Rebecca L. Yanovsky, Michael McLeod, and A. Razzaque Ahmed. Treatment of pemphigus vulgaris: part 1 – current therapies. *Expert Review of Clinical Immunology*, 15(10):1047–1060, 2019.
- [10] Dubravka Zivanovic, Ljiljana Medenica, Srdjan Tanasilovic, Sonja Vesic, Dusan Skiljevic, Maja Tomovic, and Milos M. Nikolic. Dexamethasone-Cyclophosphamide Pulse Therapy in Pemphigus. *American Journal of Clinical Dermatology*, 11(2):123–129, 2010.
- [11] Guilherme H. Ribeiro, Emanuely S. Chrun, Kamile L. Dutra, Filipe I. Daniel, and Liliane J. Grando. Osteonecrosis of the jaws: a review and update in etiology and treatment. *Brazilian Journal of Otorhinolaryngology*, 84(1):102–108, 2018.
- [12] Sharon R. Hymes and Robert E. Jordon. Pemphigus foliaceus: use of antimalarial agents as adjuvant therapy. *Archives of Dermatology*, 128(11):1462–1464, 1992.
- [13] K. D. Tran, J. E. Wolverton, and N. A. Soter. Methotrexate in the treatment of pemphigus vulgaris: experience in 23 patients. *British Journal of Dermatology*, 169(4):916–921, 2013.
- [14] Enno Schmidt, Michael Sticherling, Miklós Sárdy, Rüdiger Eming, Matthias Goebeler, and Michael Hertl. S2K guidelines for the treatment of pemphigus vulgaris/ foliaceus and bullous pemphigoid: 2019 update. *Journal der Deutschen Dermatologischen Gesellschaft*, pages 516–527, 2020.
- [15] Danka Svecova. Pemphigus vulgaris: a clinical study of 44 cases over a 20-year period. *International Journal of Dermatology*, 54(10):1138–1144, 2015.

Copyright: This is an open access article distributed under the terms of the Creative Commons Attribution-NonCommercial-ShareAlike 4.0 License, which allows others to remix, tweak, and build upon the work non-commercially, as long as the author is credited and the new creations are licensed under the identical terms.

Cite this article: Shring Sandilya, Anuska Khakhlari, Akshay Prasad Ramani, Tanya Verma, Mohit Buddhadev. An Observational Prospective Study on Treatment of Pemphigus Vulgaris and Pemphigus Foliaceus. Int. J. of Clin. Pharm. Med. Sci. 2021; 1(3): 102-107.



© 2021 Pharma Springs Publication.