

# Chiropractic BioPhysics® 44<sup>th</sup> Annual Convention

## September 2-4, 2022

### Nashville, TN, USA

#### Oral Presentations

## 1

# Improvement in Chronic Low Back Pain, Disability, and Quality of Life Following Correction of Sagittal and Frontal Spinal Alignment and Posture Using Chiropractic BioPhysics® Structural Spinal Rehabilitation After 5 Years of Failed Chiropractic Manipulation: A Case Report and 1-Year Follow-Up

Katally Sanchez, DC<sup>1</sup>, Paul A Oakley, DC, MSc, PhD(c)<sup>2</sup>, Deed E Harrison, DC<sup>2</sup>

<sup>1</sup>Private Practice, Mount Pleasant, SC, USA

<sup>2</sup>CBP Nonprofit, Eagle, ID, USA

### Abstract

**Objective:** To successful treatment for a patient with chronic low back pain (cLBP) and decreased quality of life through corrective chiropractic care. LBP has been the leading cause of disability globally for the past few decades resulting in decreased quality of life physically and emotionally.

**Clinical Features:** A38-year-old male presented to a chiropractic practice with constant, severe, 7/10 (on a Numeric Rating Scale (NRS) of 0-10 where 0 is no pain and 10 is max pain) cLBP for over 5 years. The patient reported that he had been treated by another chiropractor who administered chiropractic manipulation for the previous 5 years, but did not result in improvement in symptoms. The patient completed a Revised Oswestry Low Back Pain Disability Index (RODI) questionnaire used to determine how his LBP pain affects his daily life and to assess self-rated LBP disability. His initial RODI score was 54% indicating severe disability due to low back pain. The patient completed a Short-Form 36 (SF-36) health-related quality of life (HRQOL) questionnaire to assess self-reported effects of the patient's cLBP on his HRQOL. The SF-36 is a 36-question survey that provides scaled scores for nine different HRQOL domains on a scale of 0 to 100, where 0 is the lowest HRQOL and 100 is the highest. Pre-treatment SF-36 scores showed: Physical Functioning (PF) was 25, Bodily Pain (BP) was 22.5, Role Limitations Due to Physical Health Problems (RP) was 0, Role Limitations due to Personal or Emotional Problems (RE) was 0, General Mental Health (MH) was 76, Social Functioning (SF) was 25, Energy/Fatigue or Vitality (VIT) was 45, General Health (GH) was 50, and Change in Health Status ( $\Delta$ H) was 45.

The patient presented with abnormal spinal posture. Posture examination and analysis was performed using PostureScreen® Mobile Posture Analysis (PostureCo, Inc., Trinity, FL, USA) and revealed the following: in the sagittal plane, the patient stood with anterior head translation (+TzH), posterior thorax translation (-TzT), and anterior pelvic translation (+TzP) Figure 1A); in the frontal plane, the patient stood with left thorax (+TxT) translation, right head translation (-TxH) and a high left shoulder (Figure 2A).

Radiographic examination and analysis revealed the following: decreased sagittal curvature of the cervical spine

from C2 to C7 (ARA C2-C7) measuring  $-18.1^{\circ}$  (ideal is  $-42^{\circ}$ ); increased right lateral flexion angle relative to true vertical of the lower cervical and upper thoracic spine (RZA T5) measuring  $5.6^{\circ}$  (ideal is  $0^{\circ}$ ); right translation of C2 with respect to T5 (-Tx C2-T5) measuring  $-17.2$  mm (ideal is 0 mm); increased mid-thoracic angle with right concavity from T1 to T12 (MTA T1-T12) of  $9.1^{\circ}$  (ideal is  $0^{\circ}$ ); increased translation at T8 apex of mid-thoracic angle with respect to T12 (+Tx T8-T12) measuring  $15.2$  mm (ideal is 0 mm); decreased sagittal curvature of the lumbar spine from L1 to L5 (ARA L1-L5) measuring  $-17.9^{\circ}$  (ideal is  $-40^{\circ}$ ); sacral base unleveling in the frontal plane measuring  $-11.3$  mm low on the right; and lumbosacral angle from L1 to L5 with an L3 apex (LSA L1-L5) of  $-84.9^{\circ}$  (ideal is  $90^{\circ}$ ) (Figures 3A-7A).

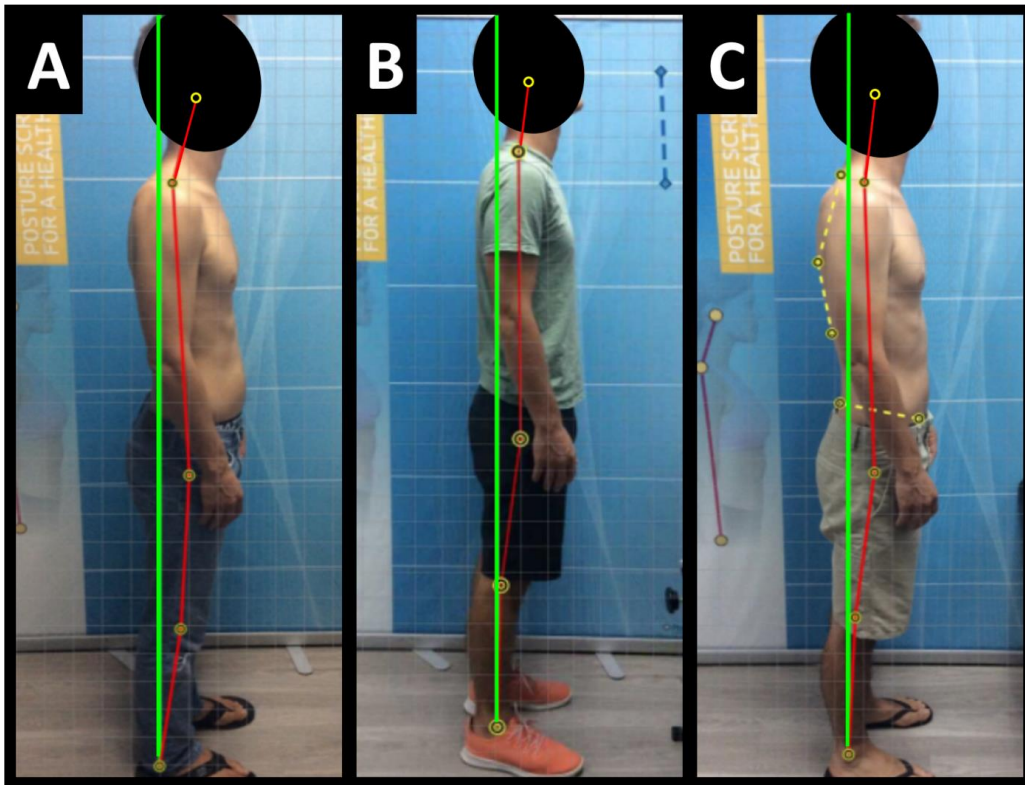
**Intervention & Outcomes:** The patient was treated 36 times in-office over 3 months. The patient received manual Diversified and CBP<sup>®</sup> Mirror Image<sup>®</sup> adjustments using a chiropractic drop table and instrument adjusting using an Impulse Adjusting Instrument (Neuromechanical Innovations, Chandler, AZ, USA). The Mirror Image<sup>®</sup> adjustments involved positioning the patient in his corrected or overcorrected spinal alignment and posture on a chiropractic drop table and using the drop pieces to administer the adjustment or with the patient standing in his corrected Mirror Image<sup>®</sup> position and using the Impulse adjusting instrument to administer a corrective spinal adjustment. Mirror Image<sup>®</sup> traction was performed using Universal Tractioning Systems (UTS) Total Spine unit (Universal Tractioning Systems, Inc., Las Vegas, NV, USA) with the patient in a standing position, posterior-to-anterior (PA) static pull at L3-L4 through the disc plane lines, an anterior-to-posterior (AP) static pull at T6-T8 to stabilize the thorax, a PA dynamic weighted cervical pull at the mid-cervical spine, and a posterior and superior static distraction pull to the head and neck. The patient also performed seated UTS Mirror Image<sup>®</sup> traction with a left head translation (+TxH) pull and a right thoracic counterstress. Mirror Image<sup>®</sup> exercises were performed including +TxH, left thoracic lateral flexion (-RzT), and McKenzie extension exercises for the lumbar spine. Core stabilizing exercises were also prescribed. The patient was prescribed daily Mirror Image<sup>®</sup> traction and exercises to be completed at home using a Pro-Lordotic Neck Exerciser and Cervical and Lumbar Dennerolls<sup>™</sup> to create cervical and lumbar extension corrections. The patient was also prescribed a 12 mm cork full foot lift to be worn in his right footwear to correct for his right short leg anatomical leg length inequality (ALLI).

Post-treatment posture analysis showed improved posture. Post-treatment radiographic examination revealed the following: improved ARA C2-C7 measuring  $-29.4^{\circ}$ ; RZA T5 measuring  $1.8^{\circ}$ ; improved -Tx C2-T5 measuring  $-5.7$  mm; improved MTA T1-T12 measuring  $2.1^{\circ}$ ; improved +Tx T8-T12 measuring  $3.5$  mm; improved ARA L1-L5 measuring  $-25.1^{\circ}$ ; improved sacral base unleveling in the frontal plane measuring  $-1.0$  mm low on the left; and improved LSA L1-L5 of  $-88.0^{\circ}$  (Figures 3B-7B). Post-treatment RODI score was 12% indicating minimal disability. Post-treatment SF-36 scores showed: PF was 90, BP was 77.5, RP was 100, RE was 100, MH was 80, SF was 87.5, VIT was 85, GH was 80, and  $\Delta$ H was 100.

One-year follow-up posture analysis showed maintained improved posture. One-year follow-up radiographic examination revealed maintained sagittal and frontal spinal alignment correction improvements (Figures 3C-7C). One-year follow-up RODI score was 2% indicating minimal or resolved disability. Post-treatment SF-36 scores showed maintained or further improved HRQOL measures reported by the patient.

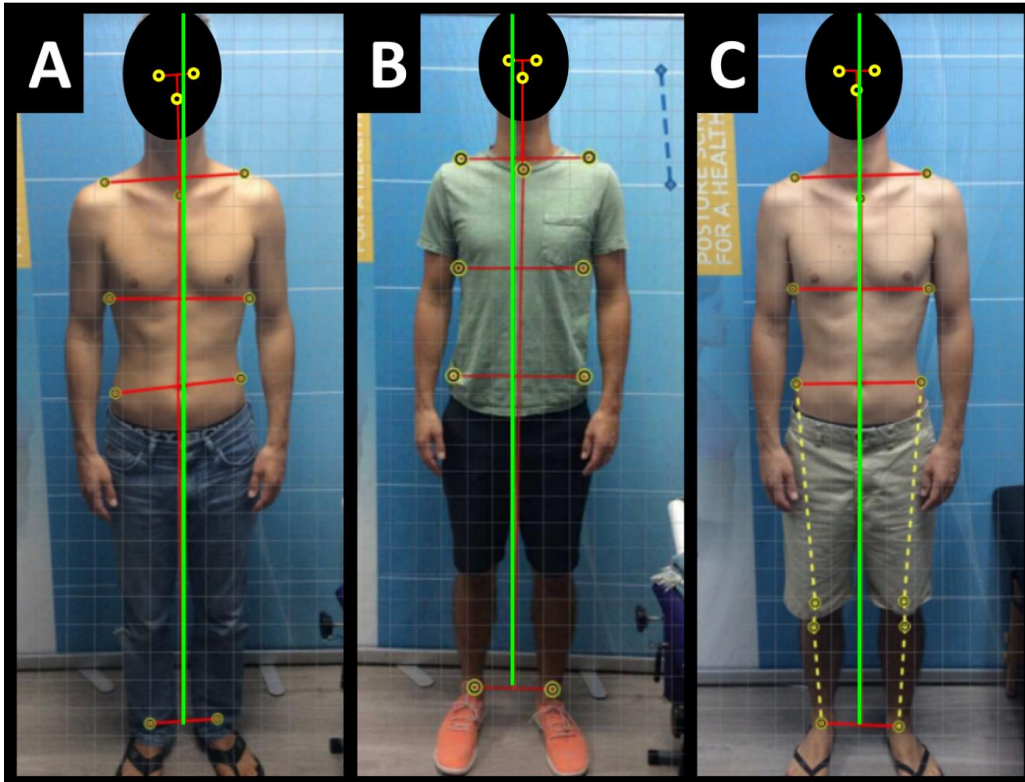
**Conclusion:** The results of this case indicate that CBP<sup>®</sup> corrective chiropractic care is an effective method to treat abnormal spinal alignment and posture which contributes to cLBP and disability causing decreased HRQOL. Improvement in spinal alignment and posture may result in long-term reduction or resolution of cLBP and improved HRQOL. This case study shows the need for more research involving spinal biomechanics and rehabilitation in patients with cLBP.

Figure 1A-C. Pre-Treatment, Post-Treatment, and 1-Year Follow-Up Sagittal Posture



**Image Features:** The green line represents a normal, ideal sagittal posture. The red line represents the actual frontal posture of the patient. The yellow circles with the black ring inside are anatomical landmarks made to analyze the patient's posture.

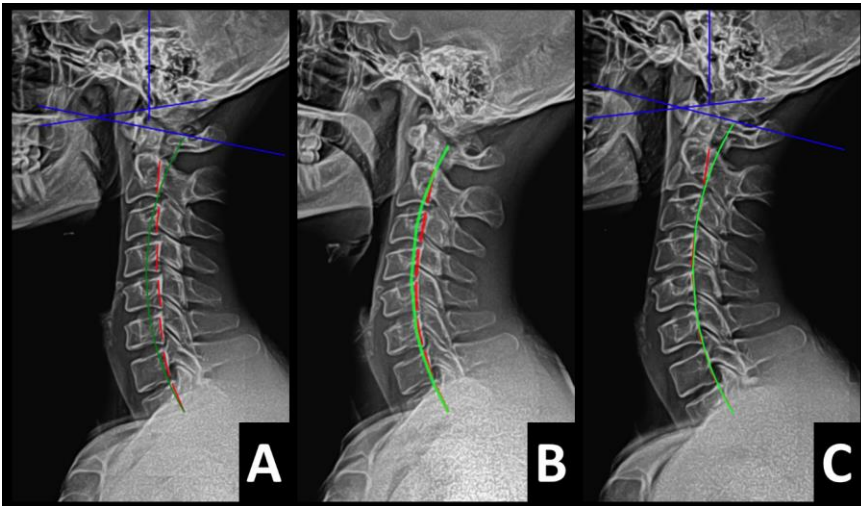
Figure 2A-C. Pre-Treatment, Post-Treatment, and 1-Year Follow-Up Frontal Posture



**Image Features:** The green line represents a normal, ideal frontal posture. The red line represents the actual frontal posture of the patient. The yellow circles with the black ring inside are anatomical landmarks made to analyze the patient's posture. The yellow dotted lines are the lines from the patient's ASIS to superior aspect of the knee and the inferior aspect of the knee to the talus landmarks. The right side of the pictures are the left side of the patient.

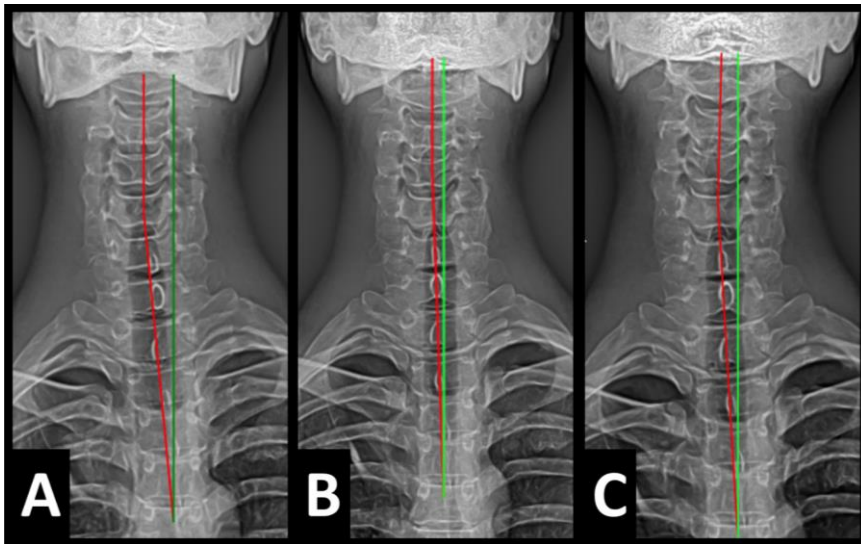


**Figure 3A-C.** Pre-Treatment, Post-Treatment, and 1-Year Follow-Up Neutral Lateral Cervical Radiographs



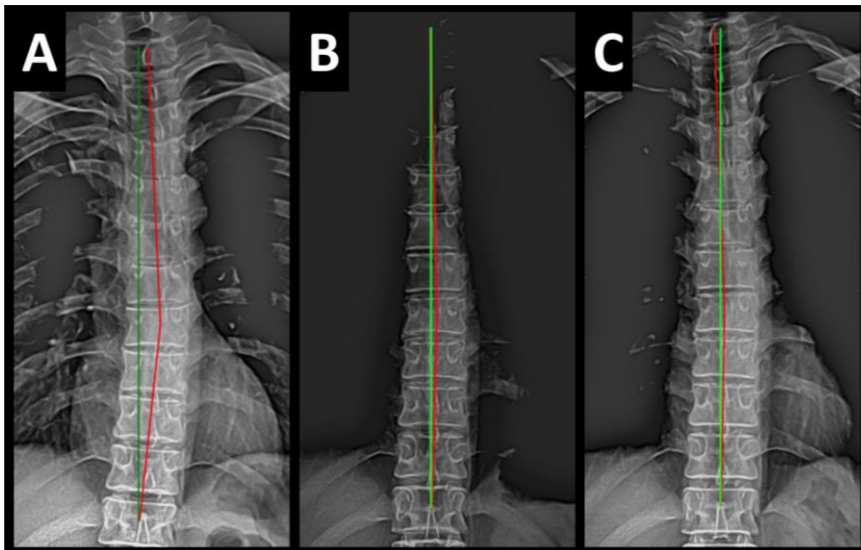
**Image Features:** The green line represents a normal, ideal sagittal cervical spinal alignment. The red line represents the actual posterior tangent lines of the C2-T1 vertebrae.

**Figure 4A-C.** Pre-Treatment, Post-Treatment, and 1-Year Follow-Up AP Cervical Radiographs



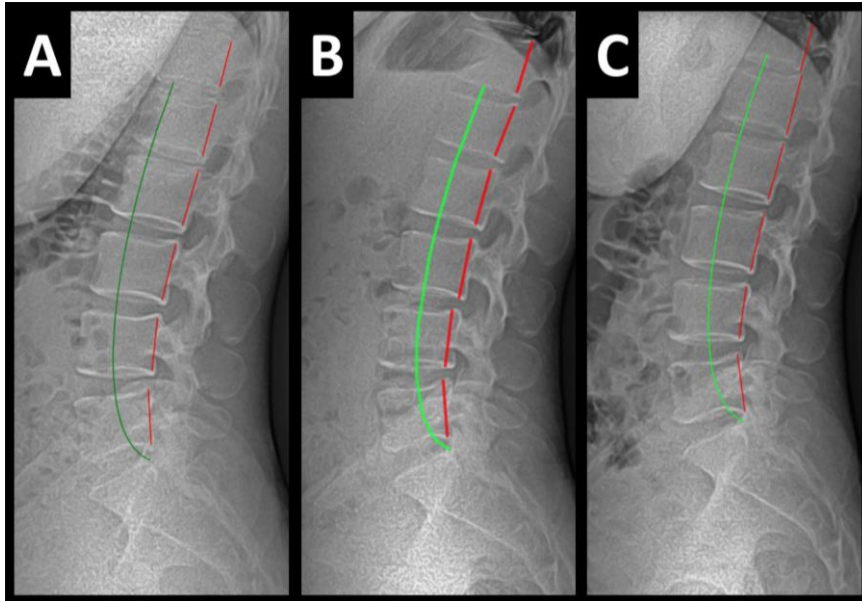
**Image Features:** The green line represents a normal, ideal frontal cervical spinal alignment. The red line represents the actual frontal cervical alignment of the C1-T2 vertebrae. The right side of the radiographs are the left side of the patient.

**Figure 5A-C.** Pre-Treatment, Post-Treatment, and 1-Year Follow-Up AP Thoracic Radiographs



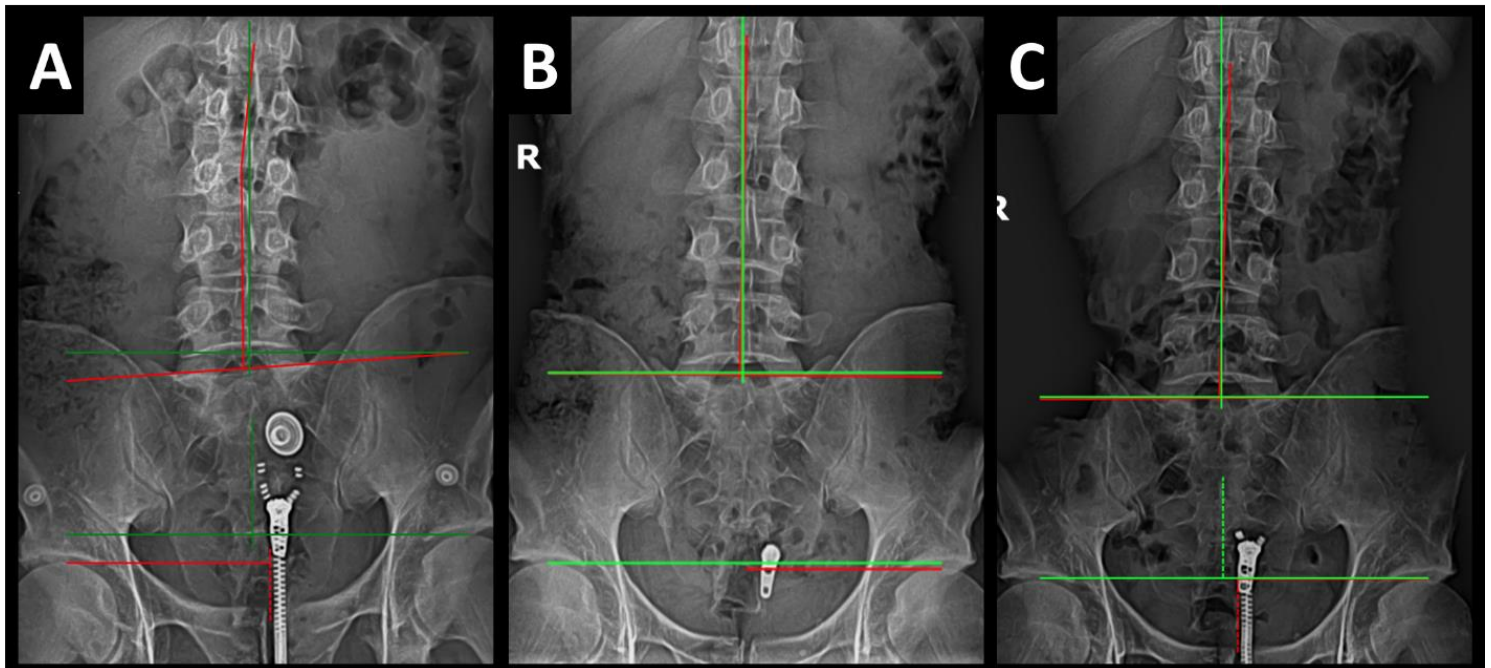
**Image Features:** The green line represents a normal, ideal frontal thoracic spinal alignment. The red line represents the actual frontal cervical alignment of the T1-T12 vertebrae. The right side of the radiographs are the left side of the patient.

**Figure 6A-C.** Pre-Treatment, Post-Treatment, and 1-Year Follow-Up Lateral Lumbar Radiographs



**Image Features:** The green line represents a normal, ideal frontal cervical spinal alignment. The red line represents the actual frontal cervical alignment of the C1-T2 vertebrae. The right side of the radiographs are the left side of the patient.

**Figure 7A-C.** Pre-Treatment, Post-Treatment, and 1-Year Follow-Up AP Modified Ferguson Lumbopelvic Radiographs



**Image Features:** The green line represents a normal, ideal frontal lumbopelvic spinal alignment including sacral base and leg length. The red line represents the actual frontal lumbopelvic alignment including sacral base and leg length. The right side of the radiographs are the left side of the patient.

## 2

# Dissociative Seizures Under Control and Resolution of Neck and Chronic Low Back Pain in a 49-Year-Old Male Following Correction of Spinal Alignment and Posture Using Chiropractic BioPhysics® Technique: A Case Report

Joseph Palmer Salamone, DC<sup>1</sup>, Jay Johannsen, DC<sup>2</sup>, Paul A Oakley, DC, MSc, PhD(c)<sup>3</sup>, Deed E Harrison, DC<sup>3</sup>

<sup>1</sup>Private Practice, Fairfield, NJ, USA

<sup>2</sup>Private Practice, Bettendorf, IA, USA

<sup>3</sup>CBP Nonprofit, Eagle, ID, USA

### Abstract

**Objective:** To describe a case of resolved neck pain (NP) and chronic low back pain (cLBP) and psychogenic nonepileptic seizures (PNES) in a 49-year-old male patient following correction of abnormal spinal alignment and posture using through Chiropractic BioPhysics® corrective chiropractic care.

**Clinical Features:** A 49-year-old male presented to a chiropractic office with intermittent, 3/10 (on a numeric rating scale (NRS) of 0-10 where 0 is no pain and 10 is max pain) NP, 3/10 cLBP for the last 20 years, and a medical diagnosis of dissociative seizures (PNES) at a consistency of 3 to 5 seizures each day lasting 3 to 10 minutes. The patient reported that prior to getting seizures, he was as a kitchen manager in a restaurant but needed to leave his profession due to safety issues regarding his seizures. The patient stated that he now works as an insurance salesman. The patient reported a history of multiple spinal injuries. The patient stated that he received chiropractic care involving adjustments in the past that resulted in pain relief lasting for 3 to 4 months and no change in his seizures. Initial physical exam revealed the following: multiple regions of spinal pain; physical deconditioning; unremitting pain; decreased cervical, thoracic, and lumbar range of motion (ROM) and strength; and abnormal deep tendon reflexes (DTR).

The patient presented with abnormal spinal posture. Radiographic examination and analysis revealed the following: anterior head translation from C2 to C7 (+Tz C2-C7) measuring 20.4 mm (ideal is 0 mm); decreased sagittal curvature of the cervical spine from C2 to C7 (ARA C2-C7) measuring -6.5° (ideal is -42.0°); thoracolumbar kyphosis (RRA T12-L1) measuring 8.5° (ideal is -1°); a decreased sacral base angle (SBA) measuring 14.7° (ideal is 40°); and sacral base unleveling in the frontal plane measuring 5.9 mm low on the left (Figures 1A-3A).

**Intervention & Outcomes:** The patient was treated 36 times in-office over 3 months. The patient received Diversified and CBP® Mirror Image® adjustments. The Mirror Image® adjustments involved positioning the patient supine with a Cervical Denneroll™ (Denneroll™ Spinal Orthotics, New South Wales, Australia) under the cervical spine and a Lumbar Denneroll™ under the lumbar spine on a chiropractic drop table and using the thoracic and lumbar drop pieces to administer the Mirror Image® chiropractic adjustment with the patient's neck and low back in a corrected extension position. Adjustment for +TzH was performed using an IMPAC Pro-ArthroStim® Instrument (I.M.P.A.C. Inc., Salem, OR, USA) in a seated Mirror Image® -TzH position at first and progressing to supine position on the chiropractic drop table using the cervical drop piece adjusting the head and neck -TzH. Mirror Image® traction was performed using Universal Tractioning Systems (UTS) Total Spine unit (Universal Tractioning Systems, Inc., Las Vegas, NV, USA) with the patient in a seated position, posterior-to-anterior (PA) static pull at T12-L1 through the disc plane lines, an anterior-to-posterior (AP) static pull at T6-T8 to stabilize the thorax, a PA dynamic weighted cervical pull at the mid-cervical spine with 5° cephalic angle, and a posterior and superior static distraction pull to the head and neck. Mirror Image® exercises were performed including anterior

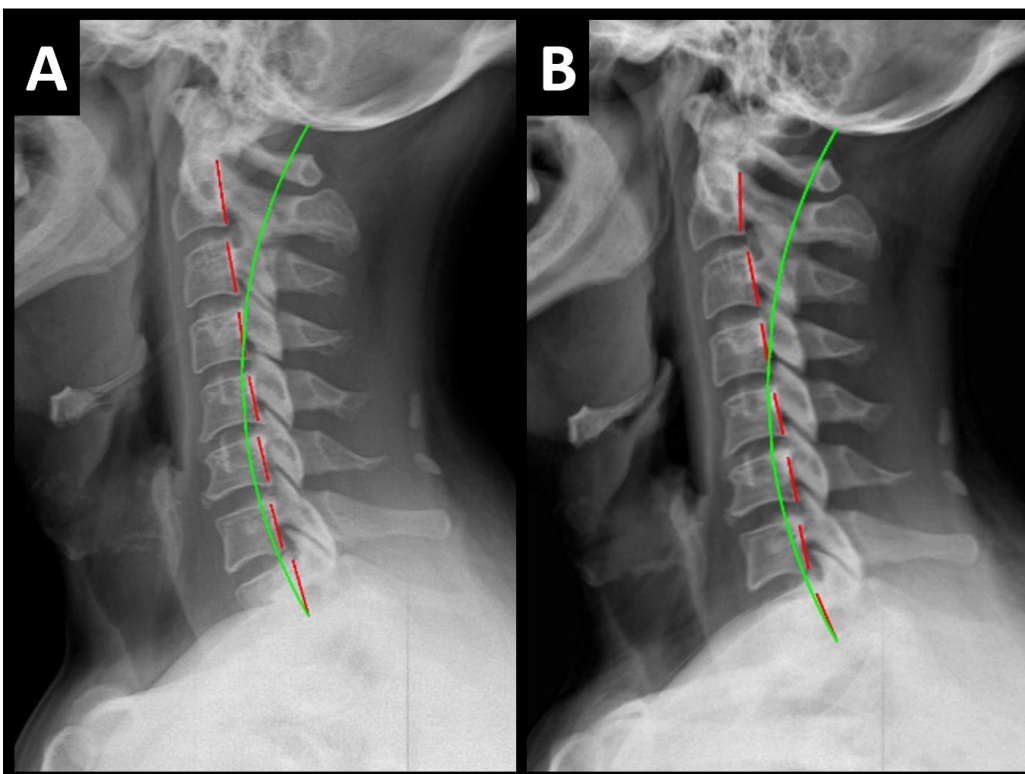
thoracic translation (+TzT) on a Power Plate® Pro5 (Power Plate Performance Health Systems, LLC, Northbrook, IL, USA) for multi-plane movement whole body vibration (WBV). The patient was prescribed daily Mirror Image® traction using a Cervical Denneroll™ with mid-cervical placement and a Lumbar Denneroll™ at L1-L2 as well as Mirror Image® exercises to be completed at home. Sacral base unleveling was addressed by prescribing a left foot lift worn in the left shoe.

Post-treatment posture analysis showed improved posture. Post-treatment radiographic examination revealed the following: improved ARA C2-C7 measuring  $-10.6^\circ$ ; improved RRA T12-L1 measuring  $-0.5^\circ$ ; improved SBA measuring  $21.6^\circ$ ; and resolved sacral base unleveling in the frontal plane measuring 0.0 mm low on the left (Figures 1B-3B).

At re-exam after 36 visits, the patient reported resolution of his neck and low back pain. He reported that his seizures were under control with 0 seizures each day as long as he maintained in-office Mirror Image® chiropractic adjustments once a week and home prescribed Mirror Image® exercises and traction. Two months following CBP® corrective care, the patient contracted COVID and was unable to continue with his chiropractic care. His seizures returned until he recovered from COVID and was able to resume chiropractic care after which his seizures ceased again and have been reported resolved at 1-year follow-up.

**Conclusion:** The results of this case indicate that CBP® corrective chiropractic care is an effective method to treat abnormal spinal alignment and posture which may contribute to abnormal sensory, motor, and autonomic neurological findings including dissociative seizures. Improvement in spinal alignment and posture may result in reduction or resolution in abnormal sensory, motor, and autonomic neurological findings including dissociative seizures. This case study indicates the need for future research involving spinal biomechanical analysis and rehabilitation in patients with PNES.

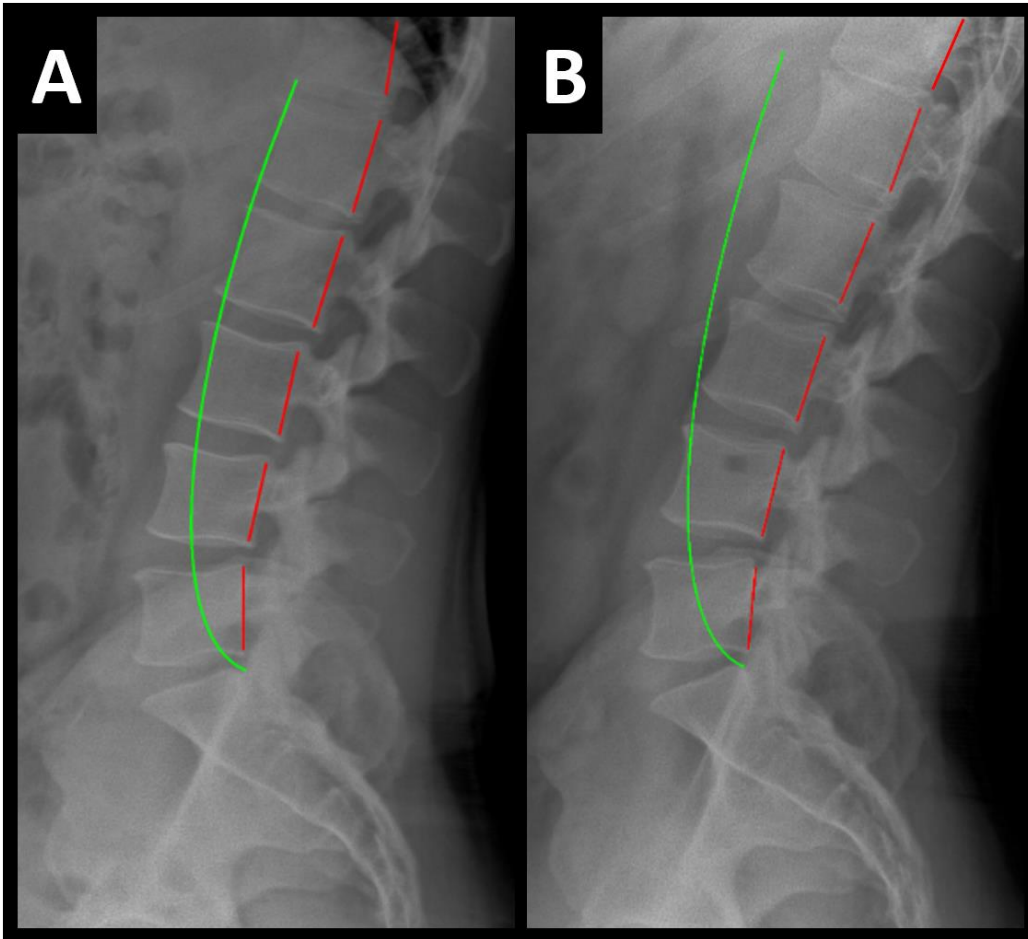
**Figure 1A-B.** Pre-Treatment and Post-Treatment Neutral Lateral Cervical Radiographs



**Image Features:** The green line represents a normal, ideal sagittal cervical spinal alignment. The red line represents the actual posterior tangent lines of the C2-T1 vertebrae.

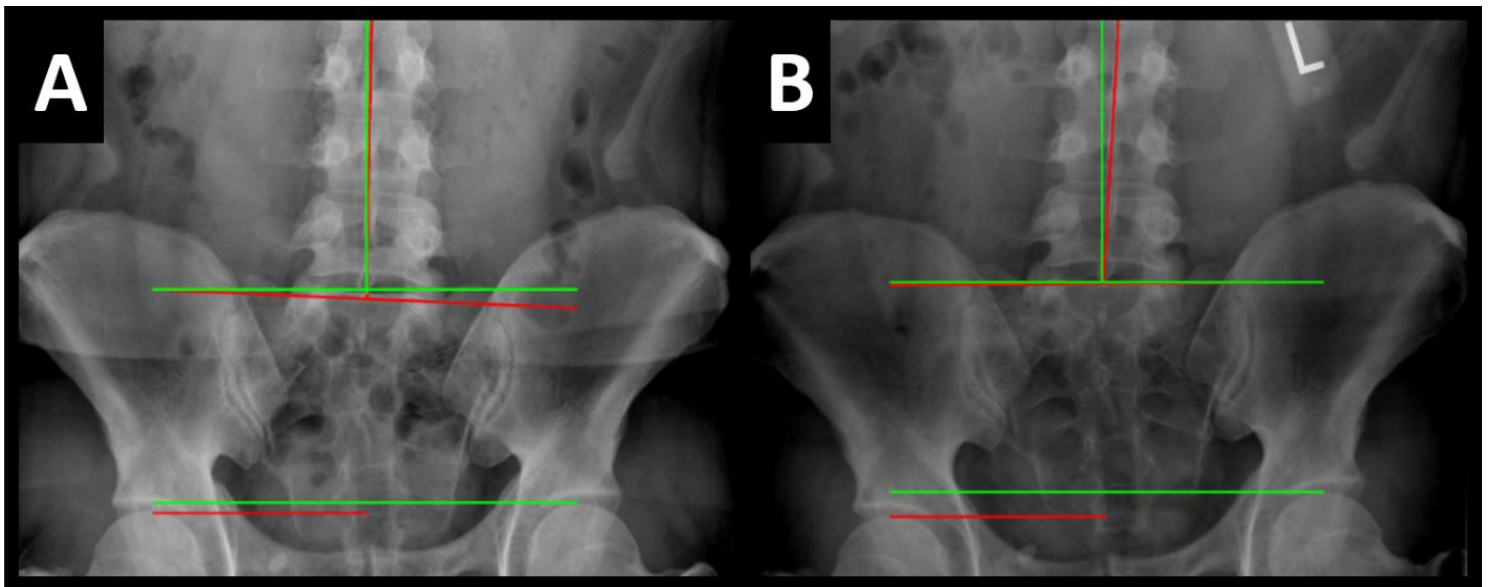


**Figure 2A-B.** Pre-Treatment and Post-Treatment Lateral Lumbar Radiographs



**Image Features:** The green line represents a normal, ideal sagittal lumbar spinal alignment. The red line represents the actual posterior tangent lines of the T12-L5 vertebrae.

**Figure 3A-B.** Pre-Treatment and Post-Treatment AP Modified Ferguson Lumbopelvic Radiographs



**Image Features:** The green line represents a normal, ideal frontal lumbopelvic spinal alignment including sacral base and leg length. The red line represents the actual frontal lumbopelvic alignment including sacral base and leg length. The right side of the radiographs are the left side of the patient.



### 3

## Restoration of Grip Strength and Improvement in Neck Pain, Mobility, and Disability, Shoulder Pain, Headaches, and Dizziness Following Correction of Abnormal Cervical Spinal Alignment and Posture Using Chiropractic BioPhysics® Structural Rehabilitation: A Case Report

Tor Østhus, DC<sup>1</sup>, Paul A Oakley, DC, MSc, PhD(c)<sup>2</sup>, Deed E Harrison, DC<sup>2</sup>

<sup>1</sup>Private Practice, Stjørdal, NOR

<sup>2</sup>CBP Nonprofit, Eagle, ID, USA

#### Abstract

**Objective:** To present a case of restoration in grip strength and improvement in neck pain (NP), mobility, and disability, shoulder pain, headaches, and dizziness following correction of abnormal cervical spinal alignment and posture using Chiropractic BioPhysics® (CBP®) structural rehabilitation.

**Clinical Features:** A 51-year-old male farmer presented to a chiropractic office with constant, moderate, 6/10 (on a numeric rating scale (NRS) of 0-10 where 0 is no pain and 10 is max pain) neck and shoulder pain that was worsening over the past week. He reported a history of chronic NP for many years as well as headaches (HA), and generalized dizziness. Initial exam findings included reduced cervical range of motion (ROM) and increased neck pain upon cervical compression and distraction tests. The patient performed grip strength dynamometry which showed he had decreased right hand grip strength (43 kg with his right hand, 70 kg with his left hand) which is his dominant hand. The patient completed a neck disability index (NDI) questionnaire used to determine how his neck pain affects his daily life and to assess self-rated NP disability. His initial NDI score was 30% indicating moderate disability due to neck pain.

The patient presented with abnormal spinal posture. Posture examination and analysis was performed using PostureScreen® Mobile Posture Analysis (PostureCo, Inc., Trinity, FL, USA) and revealed the following: in the sagittal plane, the patient stood with anterior head translation (+TzH), posterior thorax translation (-TzT), and anterior pelvic translation (+TzP) (Figure 1A); in the frontal plane, the patient stood with left pelvic (+TxP) and thorax (+TxT) translation, right head lateral flexion (+RzH) and a high left shoulder (Figure 2A).

Radiographic examination and analysis revealed the following: decreased sagittal curvature of the cervical spine from C2 to C7 (ARA C2-C7) measuring -22.2° (ideal is -42°); increased right lateral flexion angle relative to true vertical of the lower cervical and upper thoracic spine (RZA T4) measuring 3.6° (ideal is 0°); right translation of C2 with respect to T4 (-Tx C2-T4) measuring -17.2 mm (ideal is 0 mm); anterior head translation of C2 with respect to C7 (+Tz C2-C7) measuring 51.9 mm (ideal is 0 mm); and anterior full spine translation of C2 with respect to S1 (+Tz C2-S1) measuring 53.9 mm (ideal is 0 mm) (Figures 3A-5A).

**Intervention & Outcomes:** The patient received 24 in-office sessions of Manual Diversified adjustments and CBP® Mirror Image® chiropractic adjustments, exercises, and traction at a frequency of 2 sessions per week for 12 weeks. The Mirror Image® adjustments involved positioning the patient with his opposite, overcorrected position using an IMPAC Pro-ArthroStim® Instrument (I.M.P.A.C. Inc., Salem, OR, USA) and also on a chiropractic drop table and drop pieces to administer the Mirror Image® chiropractic adjustments. Mirror Image® traction™ was performed using the 3-D Denneroll™ Traction Table System (Denneroll™ Spinal Orthotics, New South Wales, Australia) with a thoracic retractor to create thoracic extension and with the patient's head extended and hanging off the table with 3 pounds of weight. Mirror Image® exercises were performed including posterior head translation (-TzH) with a thoracic retractor at the thoracic spine to

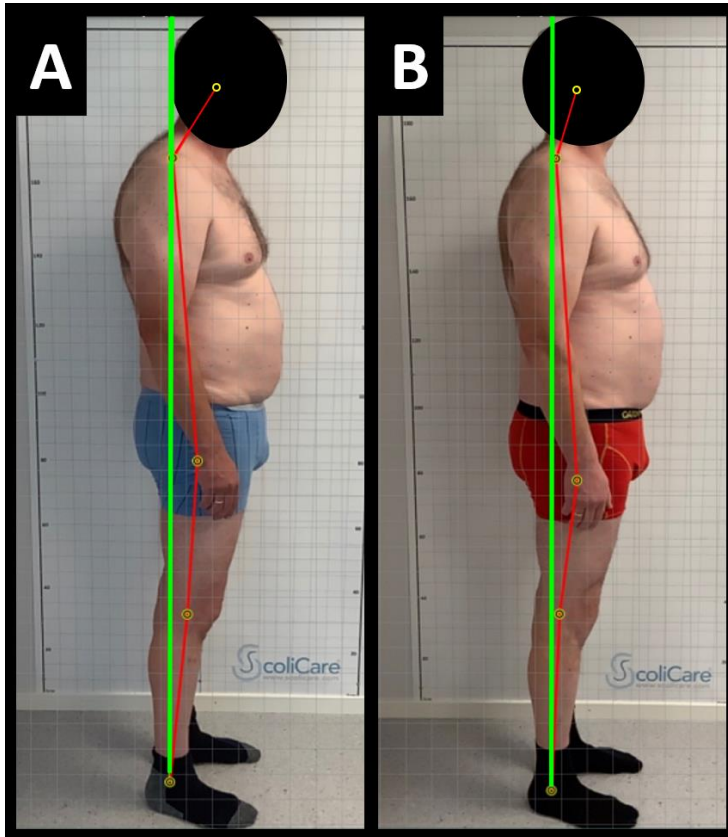
create thoracic extension and also right thoracic translation (-TxT) and left head translation (+TxH) exercises. The patient was prescribed home Mirror Image® traction as well including Denneroll™ cervical compression extension system with thoracic retractor and Mirror Image® exercises including -TzH.

Post-treatment posture analysis showed improved posture (Figures 1B-2B). Post-treatment radiographic examination revealed the following: improved ARA C2-C7 measuring -36.3°; improved RZA T4 measuring -1.9°; improved -Tx C2-T4 measuring -4.8 mm (ideal is 0 mm); improved +Tz C2-C7 measuring 13.0 mm; and improved +Tz C2-S1 measuring 15.5 mm (Figures 3A-5A).

The patient reported improvements in neck pain and mobility of 80%, shoulder pain of 80%, headaches of 50%, and generalized dizziness of 70% based on a self-reporting questionnaire on self-perceived changes from pre- to post-treatment. Post-treatment grip strength dynamometry showed restoration of right hand grip strength (64 kg with his right hand, 72 kg with his left hand). Post-treatment NDI score was 8% indicating minimal disability due to neck pain and represents a significant improvement.

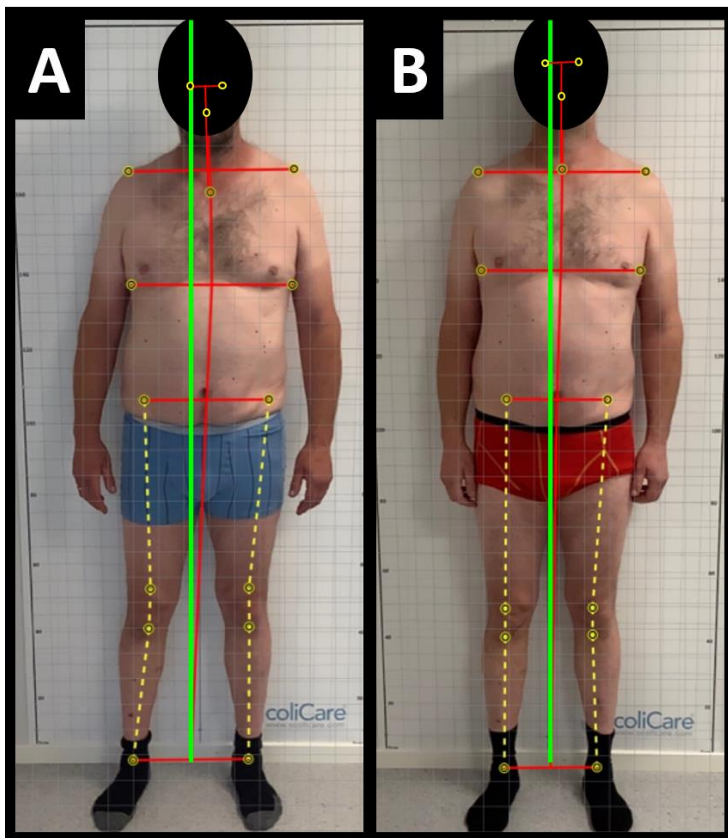
**Conclusion:** This case shows significant improvements in both symptomatic and functional health parameters following structural spinal rehabilitation using CBP®. Improvement in spinal alignment and posture may result in restoration of physical or functional impairments and improvement in pain and disability symptoms. More research is needed on this topic, in particular with correction of spinal alignment and posture on grip strength and other physical, functional health parameters.

Figure 1A-B. Pre-Treatment and Post-Treatment Sagittal Posture



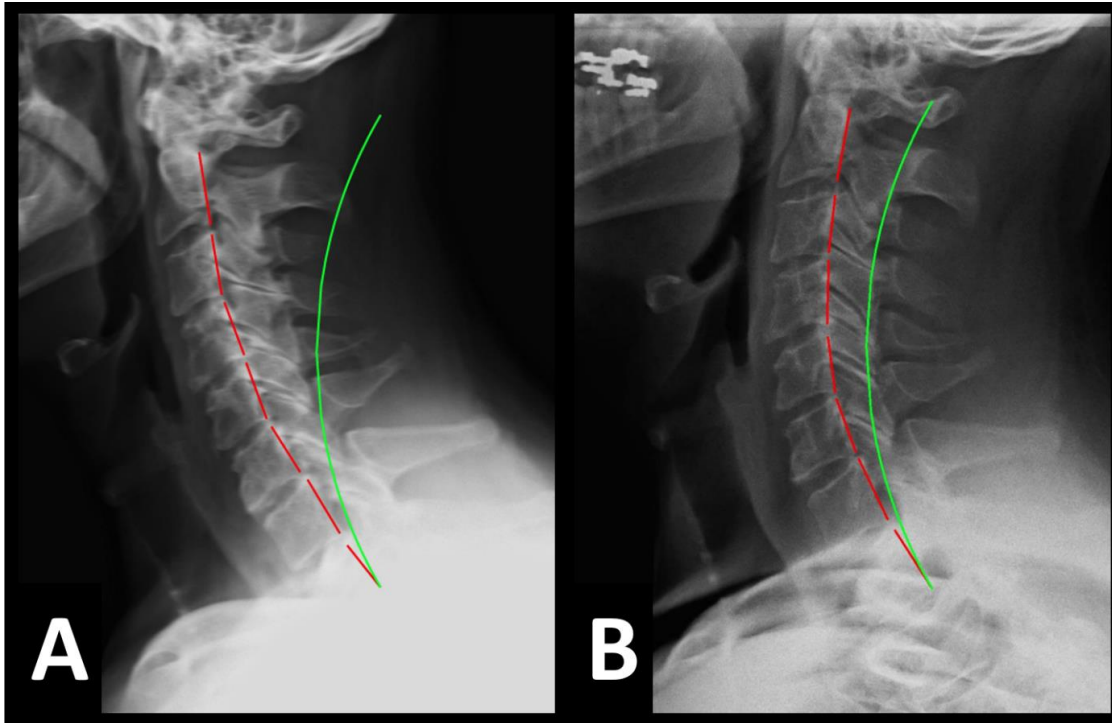
**Image Features:** The green line represents a normal, ideal sagittal posture. The red line represents the actual frontal posture of the patient. The yellow circles with the black ring inside are anatomical landmarks made to analyze the patient's posture.

Figure 2A-B. Pre-Treatment and Post-Treatment Frontal Posture



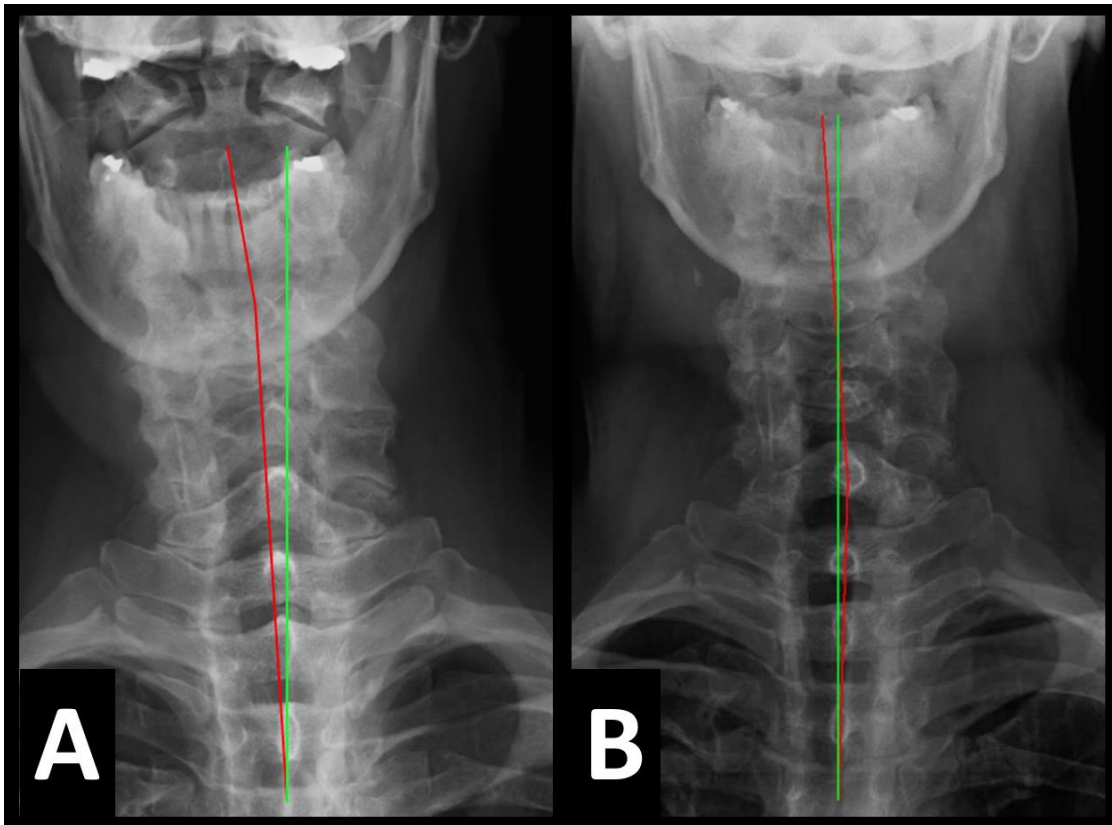
**Image Features:** The green line represents a normal, ideal frontal posture. The red line represents the actual frontal posture of the patient. The yellow circles with the black ring inside are anatomical landmarks made to analyze the patient's posture. The yellow dotted lines are the lines from the patient's ASIS to superior aspect of the knee and the inferior aspect of the knee to the talus landmarks. The right side of the pictures are the left side of the patient.

**Figure 3A-B.** Pre-Treatment and Post-Treatment Neutral Lateral Cervical Radiographs



**Image Features:** The green line represents a normal, ideal sagittal cervical spinal alignment. The red line represents the actual posterior tangent lines of the C2-T1 vertebrae.

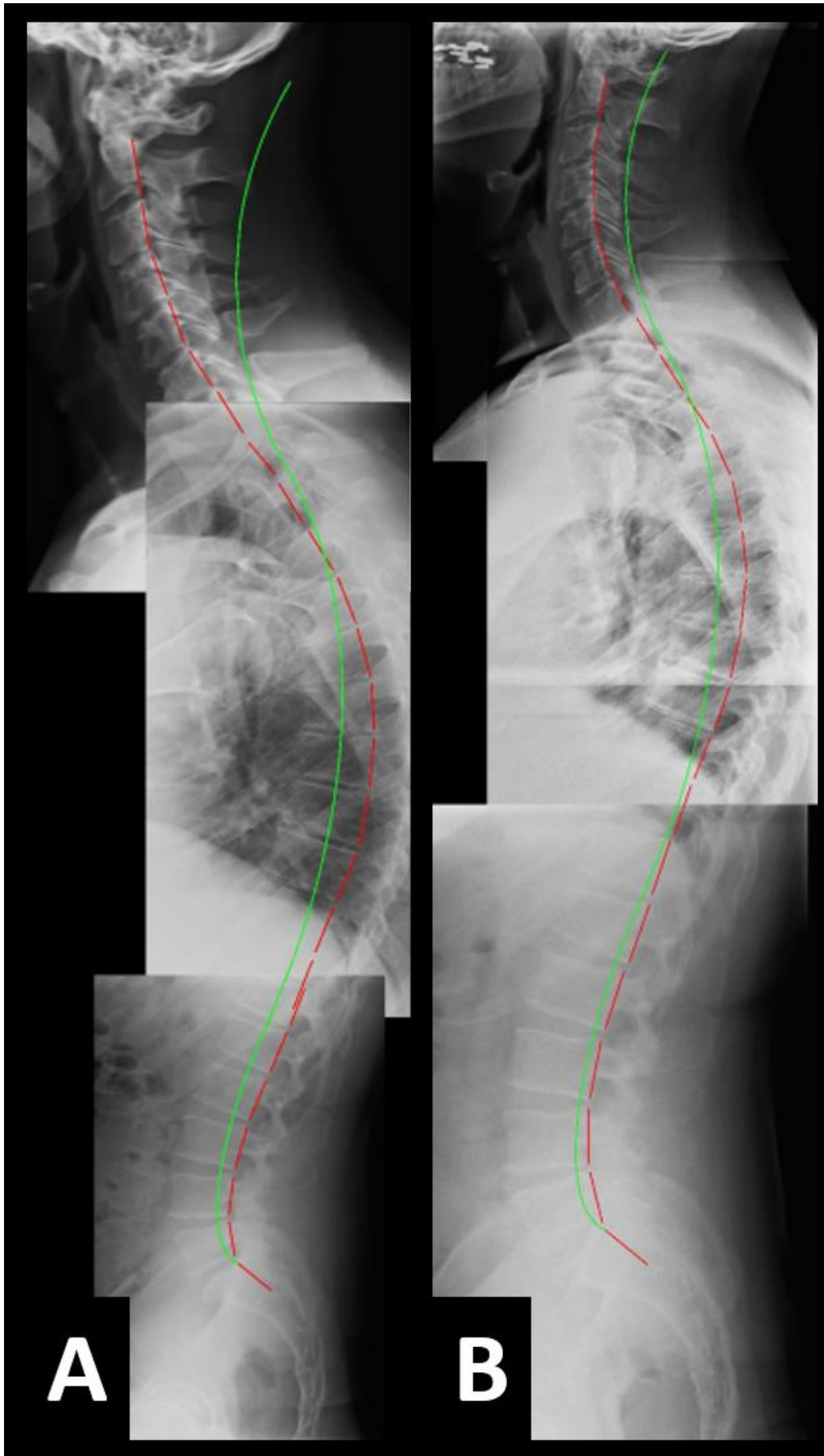
**Figure 4A-B.** Pre-Treatment and Post-Treatment Anteroposterior Lateral Cervical Radiographs



**Image Features:** The green line represents a normal, ideal frontal cervical spinal alignment. The red line represents the actual frontal cervical alignment of the C1-T2 vertebrae. The right side of the radiographs is the left side of the patient.



**Figure 5A-B.** Pre-Treatment and Post-Treatment Lateral Full Spine Radiographs (Stitched Lateral Cervical, Thoracic, and Lumbar Radiographs)



**Image Features:** The green line represents a normal, ideal sagittal full spinal alignment. The red line represents the actual posterior tangent lines of the C2-L5 vertebrae.

## 4

# Reduction in Nocturnal Enuresis and Improvement in Physical, Mental, and Behavioral Performance in an 11-Year-Old Male with Autism Following Correction of Spinal Alignment and Posture Using Chiropractic BioPhysics® Mirror Image® Rehabilitation Program: a Case Report

Todd Royse, DC<sup>1</sup>, Paul A Oakley, DC, MSc, PhD(c)<sup>2</sup>, Deed E Harrison, DC<sup>2</sup>

<sup>1</sup>Private Practice, Redding, CA, USA

<sup>2</sup>CBP Nonprofit, Eagle, ID, USA

### Abstract

**Objective:** To present a case demonstrating reduction in nocturnal enuresis and improvement in physical, mental, and behavioral parameters in an 11-year-old male with autism following correction of abnormal spinal alignment and posture using Chiropractic BioPhysics® (CBP®) Mirror Image® exercises, adjustments, and traction modalities.

**Clinical Features:** An 11-year-old male with autism was referred to a chiropractic office from his pediatrician due to abnormal posture. Patient history revealed that he was diagnosed with autism at 5 years-of-age and that he suffered from nocturnal enuresis 6 to 7 nights each week. The parents stated they had the patient in diapers at night because the nocturia was so frequent, but he would urinate through them even when liquids were eliminated after dinner. The patient's parents also noted various physical, mental, and behavioral issues. The patient's parents noted the following about the patient: he would slap a basketball without control when bouncing; he would lose control when moving a ball from hand to hand; his feet would turn outwards when walking or running; he would not understand social cues or acknowledge emotions well; he would have a dragging out or slurring speech delay for 3 seconds between thoughts when speaking; he would need several minutes to write a sentence; and he would self-stimulate involving running back-and-forth in a room, making noise, and flapping his arms 4 to 5 times each day.

The patient presented with abnormal spinal posture. Posture analysis was performed using PostureScreen® Mobile Posture Analysis (PostureCo, Inc., Trinity, FL, USA) and showed the patient had right thoracic translation, right thoracic lateral flexion, anterior head translation, and left head translation (Figure 1A). Radiographic examination and analysis revealed the following: anterior head translation from C2 to C7 (+Tz C2-C7) measuring 26.2 mm (ideal is 0 mm); the right side of the Atlas (C1) is shifted to the right of the Axis (C2) measuring -4.3 mm (ideal is 0 mm) and indicating possible C1-C2 instability; posterior translation of T1 with respect to T12 (-Tz T1-T12) measuring -41.7 mm (ideal is 0 mm); decreased sagittal curvature of the lumbar spine from L1 to L5 (ARA L1-L5) measuring -24.8° (ideal is -40°); posterior translation of T12 with respect to S1 (-Tz T12-S1) measuring -35.5 mm (ideal is 0 mm); a decreased sacral base angle (SBA) measuring 27.9° (ideal is 40°); and right translation of T12 with respect to L5 (-Tz T12-L5) measuring -14.7 mm (ideal is 0 mm) (Figures 2A-5A).

**Intervention & Outcomes:** The patient was treated 28 times in-office over 3 months. The patient received Diversified and CBP® Mirror Image® adjustments. The Mirror Image® adjustments involved positioning the patient with his right side down on a chiropractic drop table and using the cervical drop piece to administer the Mirror Image® chiropractic adjustment with the patient's head in right translation. Mirror Image® traction was performed using extension cervical traction with an added weight to the head for increased intensity. Mirror Image® exercises were performed including neck extension exercises using a Pro-Lordotic Neck Exerciser and left thoracic cage translation exercises using a block between the patients left hip and the wall to provide room for the thoracic cage to translate left. The patient was prescribed home Mirror Image®

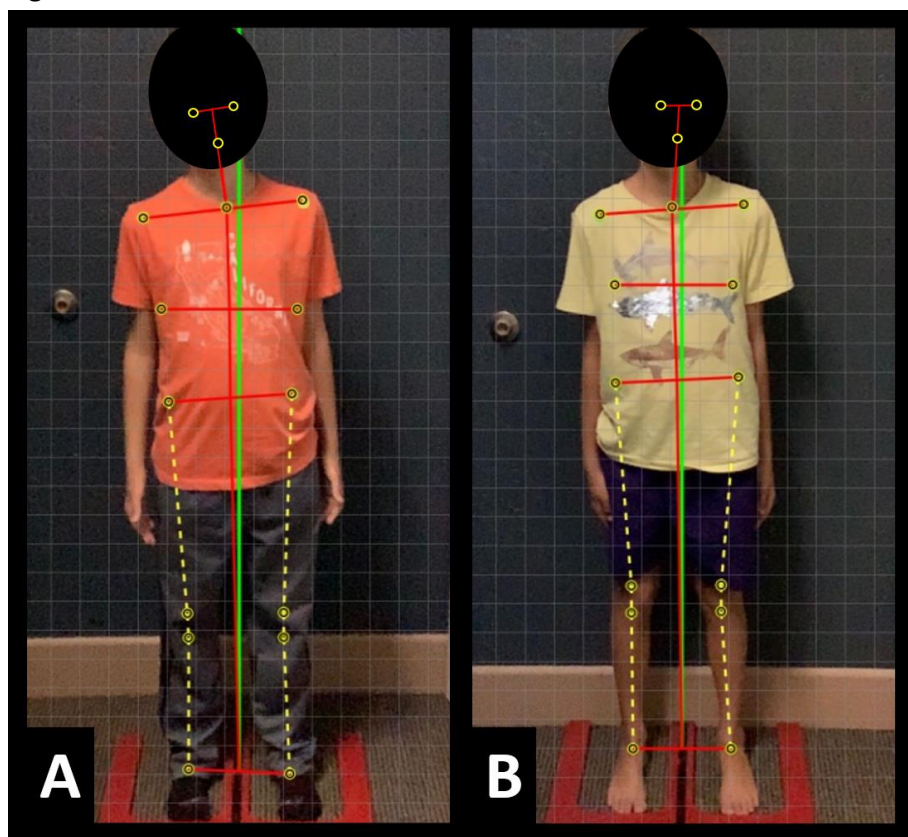
traction as well in which the patient would lie supine with a block under his thoracic spine for anterior thoracic translation and thoracic extension and Lumbar Denneroll™ Spinal Orthotic (Denneroll™ Spinal Orthotics, New South Wales, Australia) for lumbar spine correction.

Post-treatment posture analysis showed improved posture (Figure 1B). Post-treatment radiographic examination revealed the following: improved +Tz C2-C7 measuring 13.9 mm; improved right shift of C1 on C2 measuring -3.4 mm; improved -Tz T1-T12 measuring -1.5 mm; improved ARA L1-L5 measuring -29.7°; improved -Tz T12-S1 measuring -21.6 mm; improved SBA measuring 30.8°; and improved -Tz T12-L5 measuring -7.9 mm (Figures 2B-5B).

The patient's parents reported that his nocturia is near resolved since receiving chiropractic care. At post-treatment exam, the patient's parents reported the following about the patient: improvement in his ability to control a basketball; he is able to walk and run without his feet turning out; improvement in communication, reading body language, engaging with emotions, and picking up on social cues in conversations; near resolution of speech delay between thoughts when speaking; approximate 60% improvement in mental processing and writing speed; and near resolution of self-stimulating behavior. The patient's mother stated that "his nervous system is more at peace."

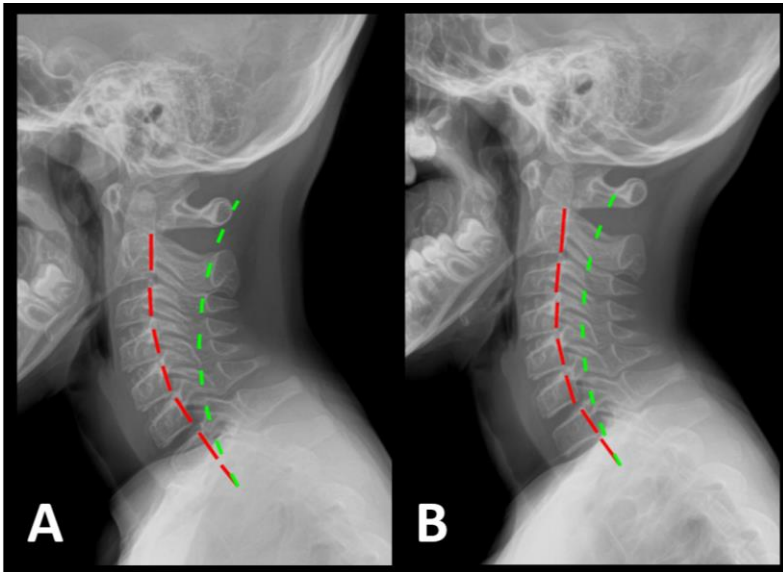
**Conclusion:** In this case, CBP® corrective chiropractic Mirror Image® exercises, adjustments, and traction were an effective method to treat abnormal spinal alignment and posture. Improvement in spinal alignment and posture may result in reduction or resolution in nocturnal enuresis as well as physical, mental, and behavioral parameters in autistic children. More research is needed on this topic, in particular with correction of spinal alignment and posture in pediatric autistic populations.

**Figure 1A-B.** Pre-Treatment and Post-Treatment Frontal Posture



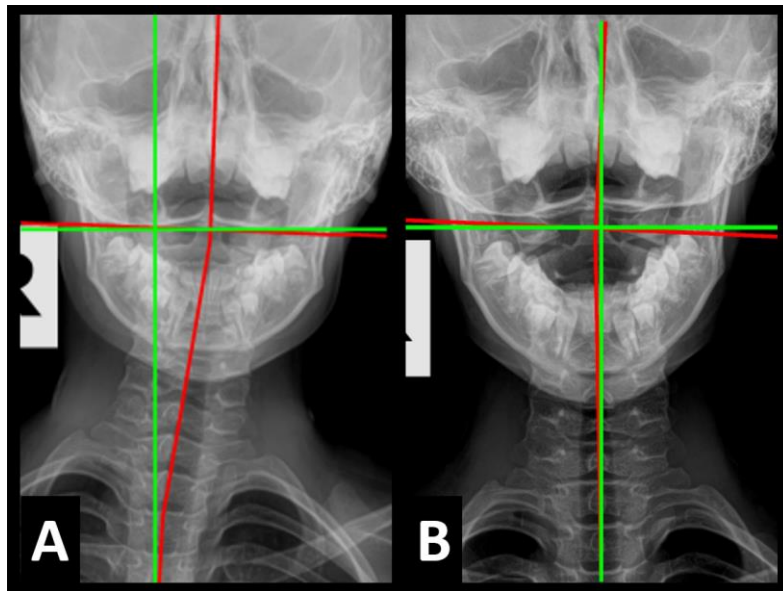
**Image Features:** The green line represents a normal, ideal frontal posture. The red line represents the actual frontal posture of the patient. The yellow circles with the black ring inside are anatomical landmarks made to analyze the patient's posture. The yellow dotted lines are the lines from the patient's ASIS to superior aspect of the knee and the inferior aspect of the knee to the talus landmarks. The right side of the pictures are the left side of the patient.

**Figure 2A-B.** Pre-Treatment and Post-Treatment Neutral Lateral Cervical Radiographs



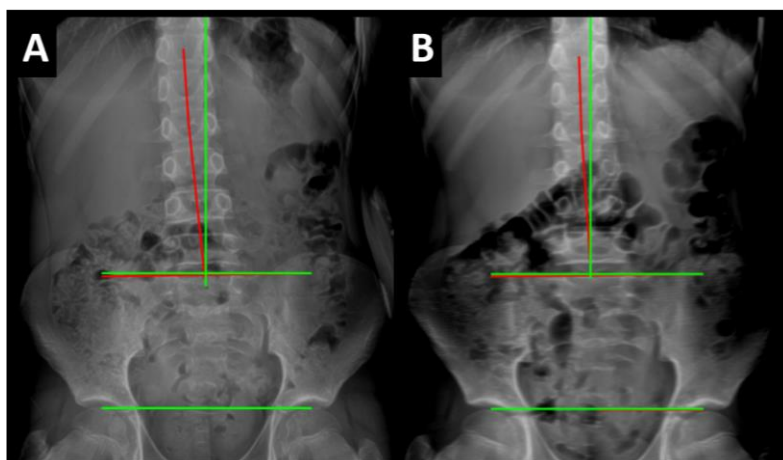
**Image Features:** The green line represents a normal, ideal sagittal cervical spinal alignment. The red line represents the actual posterior tangent lines of the C2-T1 vertebrae.

**Figure 3A-B.** Pre-Treatment and Post-Treatment AP Cervical Radiographs



**Image Features:** The green line represents a normal, ideal frontal cervical spinal alignment. The red line represents the actual frontal cervical alignment of the C1-T2 vertebrae. The right side of the radiographs are the left side of the patient.

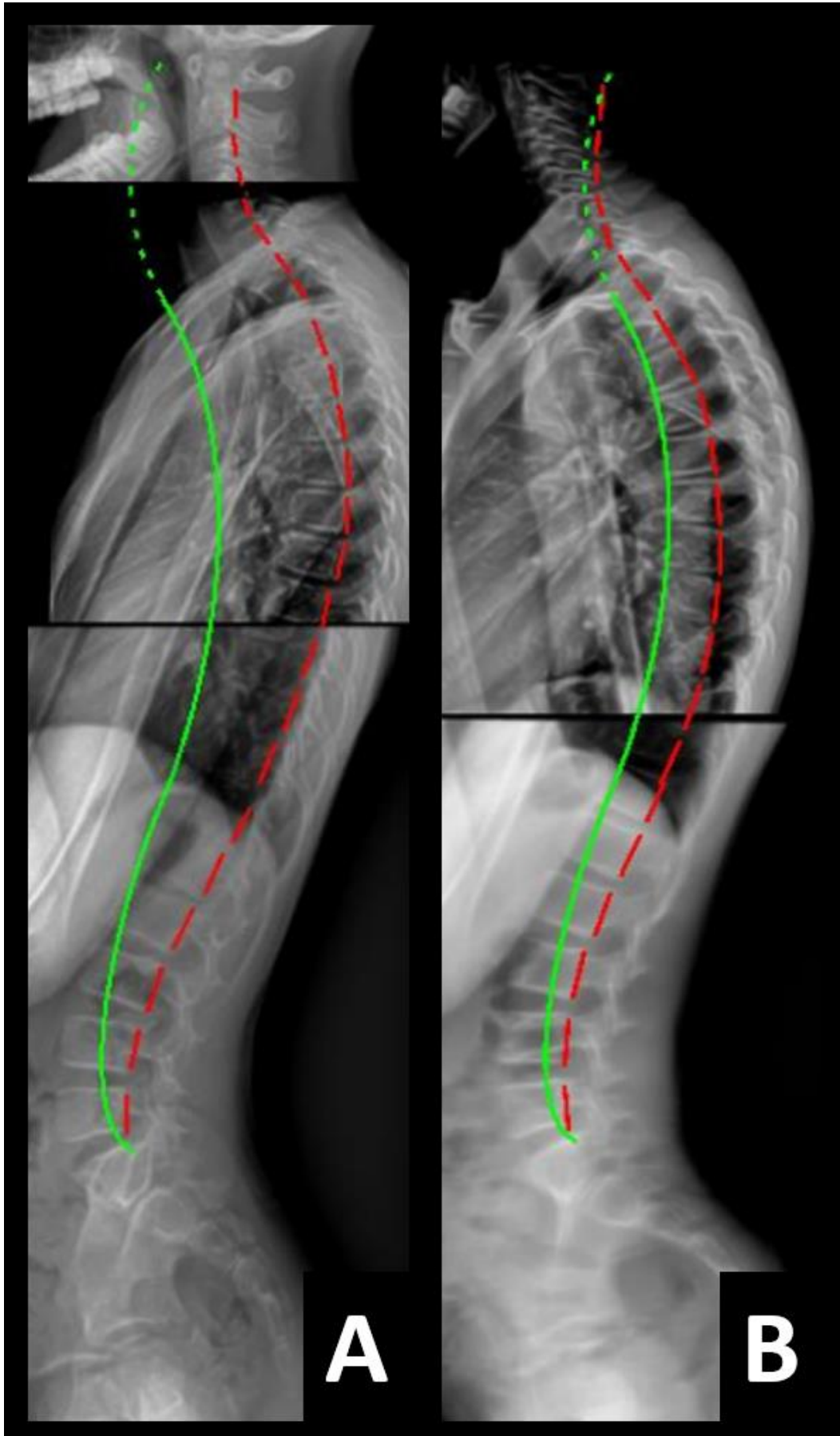
**Figure 4A-B.** Pre-Treatment and Post-Treatment AP Modified Ferguson Lumbopelvic Radiographs



**Image Features:** The green line represents a normal, ideal frontal lumbopelvic spinal alignment including sacral base and leg length. The red line represents the actual frontal lumbopelvic alignment including sacral base and leg length. The right side of the radiographs are the left side of the patient.



**Figure 5A-B.** Pre-Treatment and Post-Treatment Lateral Full Spine Radiographs (Stitched Lateral Cervical, Thoracic, and Lumbar Radiographs)



**Image Features:** The green line represents a normal, ideal sagittal full spinal alignment. The red line represents the actual posterior tangent lines of the C2-L5 vertebrae.

## 5

# Improvement of Lumbar Disc Height, Pain, and Physical Performance Following Correction of Sagittal Plane Thoracolumbar Spinal Alignment and Posture Using Chiropractic BioPhysics® Corrective Care Technique: A Case Study

Greg Payne, DC<sup>1</sup>, Paul A Oakley, DC, MSc, PhD(c)<sup>2</sup>, Deed E Harrison, DC<sup>2</sup>

<sup>1</sup>Private Practice, Ottawa, ON, CAN

<sup>2</sup>CBP Nonprofit, Eagle, ID, USA

### Abstract

**Objective:** To present a case of improvement in lumbar disc height following correction of sagittal plane thoracolumbar spinal alignment and posture using Chiropractic BioPhysics® (CBP®) corrective care technique. Biomechanics drives proper sagittal balance and function of the spine. Loss of healthy spinal alignment and posture lead to altered physiologic function, ligament instability, disc degeneration, and other pathologies.

**Clinical Features:** A 31-year-old, female, who was working as staff for a Senator, and had recently started a running program presented to a chiropractic practice with low back pain (LBP), and low back limited range of motion, stiffness, and swelling. Her walking was slow, taking small steps in an antalgic posture. The patient stated that she had injured her back approximately 10 years prior while stepping from a truck and received physical therapy for her back pain that lasted about 2 months. For her recent complain, the patient engaged in low back stretches and was taking an over-the-counter (OTC) pain medication and a skeletal muscle relaxant, but she reports it did not help.

The patient presented with abnormal spinal posture. Posture analysis showed the patient had left thoracic translation with respect to the pelvis. Radiographic examination and analysis revealed the following: decreased sagittal curvature of the thoracic spine from T3 to T10 (ARA T3-T10) measuring 12.6° (ideal is 37°); anterior translation of T3 with respect to T10 (+Tz T3-T10) measuring 18.8 mm (ideal is 0 mm); decreased sagittal curvature of the lumbar spine from L1 to L5 (ARA L1-L5) measuring -28.7° (ideal is -40°); a decreased sacral base angle (SBA) measuring 30.1° (ideal is 40°); anterior translation of T12 with respect to S1 (+Tz T3-T10) measuring 44.0 mm (ideal is 0 mm); and decreased intervertebral disc (IVD) height at L4-L5 measuring 1.5 mm at the anterior and 4.8 mm at the posterior and L5-S1 measuring 4.4 mm at the anterior and 2.9 mm at the posterior (Figures 1A-3A).

**Intervention & Outcomes:** The patient was treated 36 times over 3 months. For the first 12 visits during the first month, the patient received Diversified and CBP® Mirror Image® adjustments. The Mirror Image® adjustments involved positioning the patient to increase lumbar and thoracic sagittal curvatures and using an Impulse IQ Adjusting Instrument (Neuromechanical Innovations, Chandler, AZ, USA) (Figure 4). The remaining 24 visits included Diversified and CBP® Mirror Image chiropractic adjustments in combination with CBP® Mirror Image® spinal exercise and traction. Right thoracic translation exercises were performed by the patient and her traction utilized Lumbar Denneroll™ Spinal Orthotic (Denneroll™ Spinal Orthotics, New South Wales, Australia) and two-way seated traction for the thoracic and cervical spine focusing on increasing thoracic and lumbar sagittal curvatures and improving sagittal balance (Figure 5).

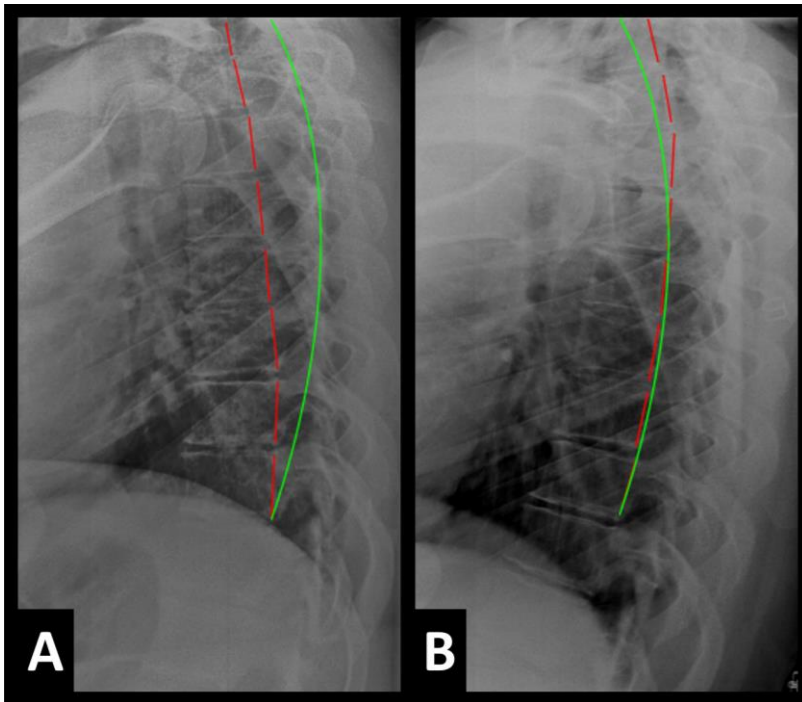
Post-treatment posture analysis showed improved frontal and sagittal posture. Post-treatment radiographic examination revealed the following: improved ARA T3-T10 measuring 28.7°; increased ARA L1-L5 measuring -48.5°; improved SBA measuring 36.3°; improved +Tz T3-T10 measuring 3.4 mm; and increased IVD height at L4-L5 measuring 7.2 mm at the anterior and L5-S1 measuring 6.2 mm at the anterior and 4.6 mm at the posterior (Figures 1B-3B).

The patient reported improved quality of life and range of motion giving her the freedom to stand, sit, and walk without pain or limitation. She reported resolution of pain without the need to take a pain medication and skeletal muscle

relaxant.

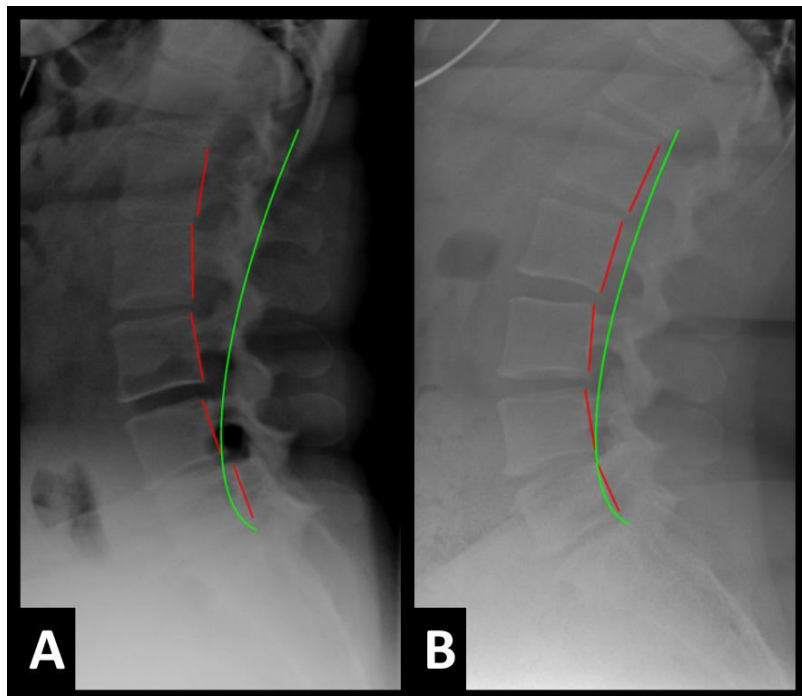
**Conclusion:** This case postulates that using CBP® corrective chiropractic technique to restore normal sagittal spinal alignment and posture can result in restored IVD height, improved quality of life, range of motion, and performance of activities of daily living as well as resolution of pain and removing the need for pain medication and skeletal muscle relaxants. More research is needed on this topic, in particular with correction of spinal alignment and posture and changes in IVD height.

**Figure 1A-B.** Pre-Treatment and Post-Treatment Lateral Thoracic Radiographs



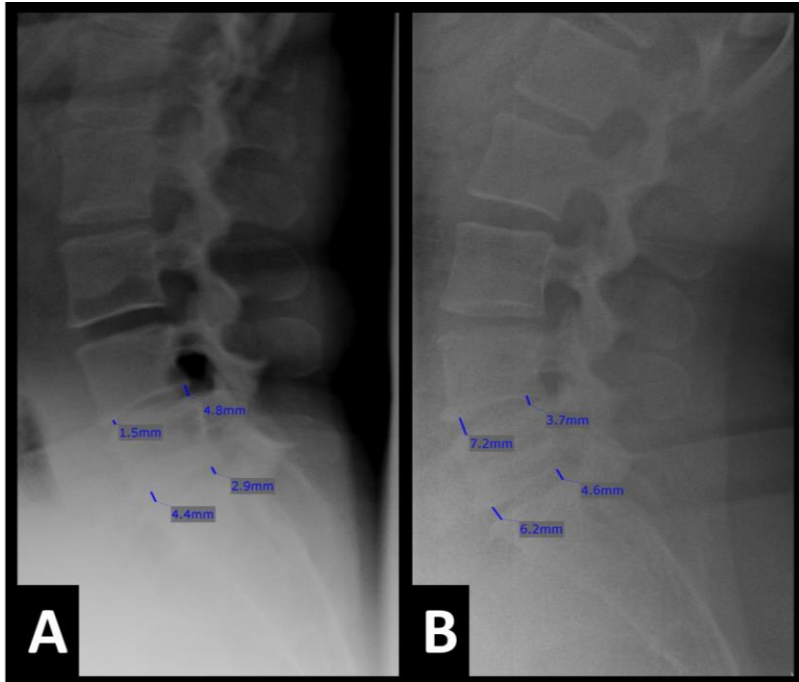
**Image Features:** The green line represents a normal, ideal sagittal thoracic spinal alignment. The red line represents the actual posterior tangent lines of the T3-T10 vertebrae.

**Figure 2A-B.** Pre-Treatment and Post-Treatment Lateral Lumbar Radiographs



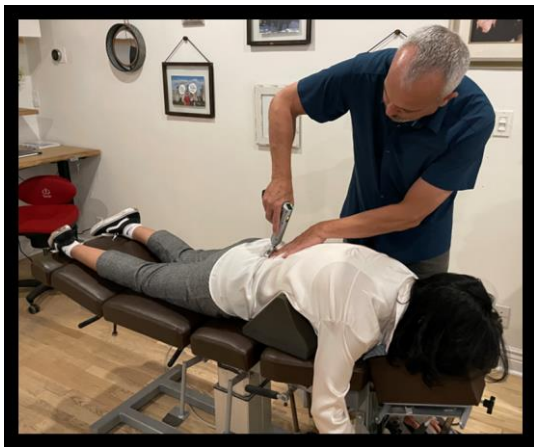**Image Features:** The green line represents a normal, ideal sagittal lumbar spinal alignment. The red line represents the actual posterior tangent lines of the L1-L5 vertebrae.

**Figure 3A-B.** Pre-Treatment and Post-Treatment Lateral Lumbar Radiographs IVD Heights

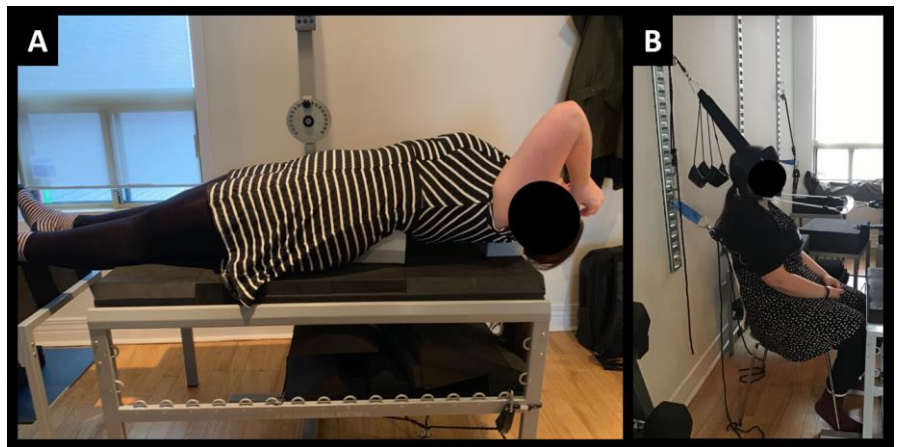


**Image Features:** The blue lines and measurements represent the actual anterior and posterior L4-L5 and L5-S1 IVD heights.

**Figure 4.** CBP® Mirror Image® Adjustment



**Figure 5A-B.** Chiropractic BioPhysics® Mirror Image® Spinal Traction





## 6

## Resolution of Frozen Shoulder Syndrome, Neck and Low Back Pain and Disability, and Difficulty Sleeping in a 65-Year-Old Male Following A Comprehensive, Multimodal Rehabilitation Program Including Sagittal Spine and Posture Correction Using Chiropractic BioPhysics®: A Case Report

Brian G Jang, DC<sup>1</sup>, Paul A Oakley, DC, MSc, PhD(c)<sup>2</sup>, Deed E Harrison, DC<sup>2</sup>

<sup>1</sup>Private Practice, Lynnwood, WA, USA

<sup>2</sup>CBP Nonprofit, Eagle, ID, USA

### Abstract

**Objective:** To present a case illustrating how utilization of a comprehensive, multimodal rehabilitation program including sagittal spine and posture correction using Chiropractic BioPhysics® (CBP®) resulted in resolution of frozen shoulder syndrome (FSS), neck pain (NP) and (LBP) and disability, and difficulty sleeping.

**Clinical Features:** A 65-year-old male, general contractor presented to a chiropractic office with inability to lift anything for 4 days due to chronic right FSS, NP, and LBP. The patient described his NP as a constant, severe, 9/10 (on a numeric rating scale (NRS) of 0-10 where 0 is no pain and 10 is max pain) pain which scored 88% indicating complete disability according to the Neck Disability Index (NDI). The patient described his LBP as a constant, severe, 8/10 pain which scored 80% indicating crippling disability according to the Revised Oswestry Low Back Pain Disability Index (RODI). The patient described his right shoulder pain as a constant, severe, 10/10 pain. The patient stated feeling pain in his right shoulder after falling while hiking 3 months prior. He stated he felt his right shoulder “slightly dislocate” and that he tried to “push it back in place.” He stated that following this fall, he was able use his right arm for activities of daily living (ADL) but that continued to worsen over time and he experienced NP and LBP and disability. Additionally, the patient reported difficulty sleeping due to the pain intensity in his neck, low back, and right shoulder which woke him up throughout the night.

The patient presented with abnormal spinal posture. Posture examination and analysis revealed the patient had right head translation (-TxH), anterior head translation (+TzH), left thoracic translation (+TxT), posterior thorax translation (-TzT), and a short right leg. Radiographic examination and analysis revealed the following: decreased sagittal curvature of the cervical spine from C2 to C7 (ARA C2-C7) measuring -17.5° (ideal is -42°); left thoracic translation of T1 with respect to T12 (+Tx T1-T12) measuring 15.1 mm; decreased sagittal curvature of the lumbar spine from L1 to L5 (ARA L1-L5) measuring -30.6° (ideal is -40°); posterior translation of T12 with respect to S1 (-Tz T12-S1) measuring -21.2 mm (ideal is 0 mm); a retrolisthesis from L2 to L3 (-Tz L2-L3) measuring -5.3 mm and a retrolisthesis from L3 to L4 (-Tz L3-L4) measuring -6.8 mm; a decreased sacral base angle (SBA) measuring 28.0° (ideal is 40°); and sacral base unleveling in the frontal plane sloping -2.3° down on the left (Figures 1A-4A). A radiolucency and a mild-to-moderate sclerotic lesion of the humeral head was also noted (Figure 5)

**Intervention & Outcomes:** The patient was treated 36 times in-office over 4 months. The patient received manual Diversified, Cox Flexion-Distraction, and CBP® Mirror Image® adjustments. The Mirror Image® adjustments involved positioning the patient with his opposite, overcorrected position on a chiropractic drop table and drop pieces to administer the Mirror Image® chiropractic adjustments. Mirror Image® traction was performed using the 3-D Denneroll™ Traction Table System (Denneroll™ Spinal Orthotics, New South Wales, Australia) for cervical and lumbar extension and the Universal Tractioning Systems (UTS) Total Spine unit (Universal Tractioning Systems, Inc., Las Vegas, NV, USA) for frontal spine correction (Figure 6A-B). Mirror Image® exercises were performed including neck extension exercises using a Pro-

Lordotic Neck Exerciser, McKenzie extension exercises for the lumbar spine, and intrinsic spinal musculature strengthening exercises for spinal stability (Figure 7A-B). The patient was prescribed home Mirror Image® traction as well in which the patient would lie supine with Cervical and Lumbar Denneroll™ Spinal Orthotics for cervical and lumbar spine correction.

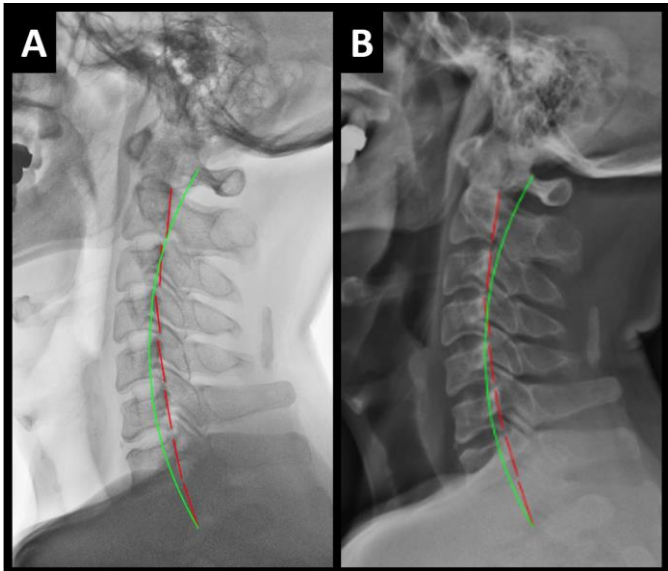
Post-treatment posture analysis showed improved posture. Post-treatment radiographic examination revealed the following: improved ARA C2-C7 measuring  $-25.3^\circ$ ; improved +Tx T1-T12 measuring 5.8 mm; improved ARA L1-L5 measuring  $-36.3^\circ$ ; improved -Tz T12-S1 measuring -13.9 mm; improved -Tz L2-L3 measuring -4.8 mm and -Tz L3-L4 measuring -3.5 mm; improved SBA measuring  $36.3^\circ$ ; and sacral base unleveling in the frontal plane sloping  $-1.0^\circ$  down on the left (Figures 1B-4B).

The patient reported complete resolution of his frozen shoulder symptoms, NP and LBP and disability. He scored 4% on the NDI indicating minimal neck disability and 2% on the RODI indicating minimal low back disability. Additionally, the patient reported resolution of difficulty sleeping and is able to sleep uninterrupted without pain. He is also able to work without restrictions.

**Conclusion:** In this case, frozen shoulder, also called adhesive capsulitis, was associated with cervical pain, degeneration, and decreased cervical lordosis. Improvement of shoulder range of motion and pain was achieved with cervical distraction and improvement in cervical lordosis. Even though adhesive capsulitis involves soft tissue injury and lesions to the shoulder, the patient reported resolution of frozen shoulder syndrome symptoms with spinal rehabilitation.

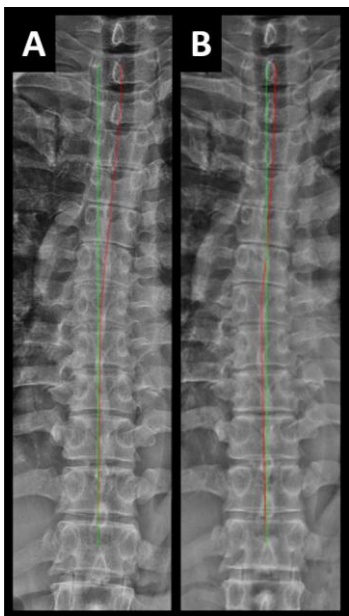
In this case, CBP® corrective chiropractic Mirror Image® exercises, adjustments, and traction were an effective method to treat abnormal spinal alignment and posture. Improvement in spinal alignment and posture may result in reduction or resolution in frozen shoulder syndrome symptoms and NP and LBP and disability as well as improvement in ADLs including sleeping and manual labor. More research is needed on this topic, in particular with correction of spinal alignment and posture in older populations with frozen shoulder syndrome.

**Figure 1A-B.** Pre-Treatment and Post-Treatment Neutral Lateral Cervical Radiographs



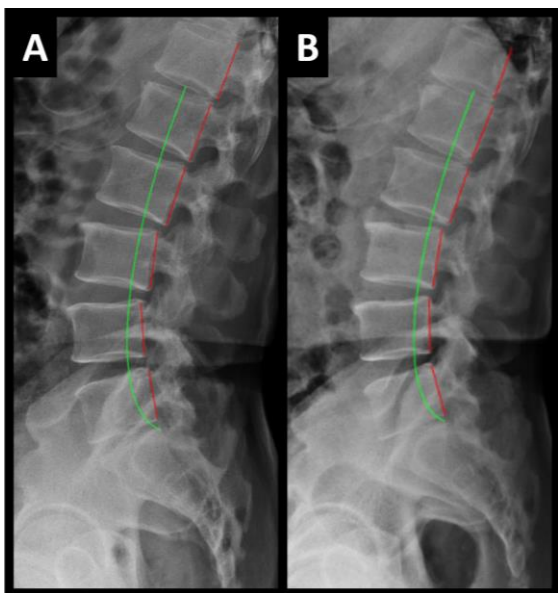
**Image Features:** The green line represents a normal, ideal sagittal cervical spinal alignment. The red line represents the actual posterior tangent lines of the C2-T1 vertebrae.

**Figure 2A-B.** Pre-Treatment and Post-Treatment AP Thoracic Radiographs



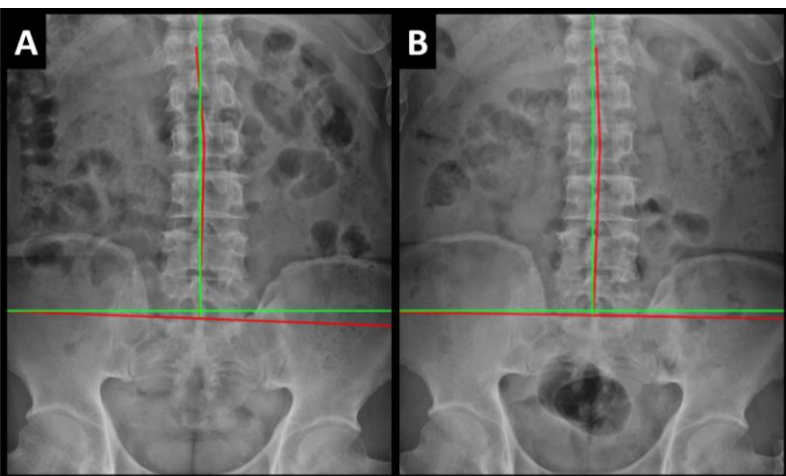
**Image Features:** The green line represents a normal, ideal frontal thoracic spinal alignment. The red line represents the actual frontal thoracic spinal alignment from T1-T12. The right side of the radiographs are the left side of the patient.

**Figure 3A-B.** Pre-Treatment and Post-Treatment Lateral Lumbar Radiographs IVD Heights



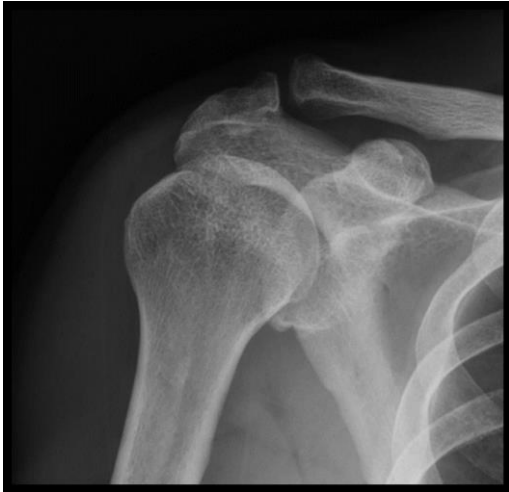**Image Features:** The green line represents a normal, ideal sagittal lumbar spinal alignment. The red line represents the actual posterior tangent lines of the T12-L5 vertebrae.

**Figure 4A-B.** Pre-Treatment and Post-Treatment AP Modified Ferguson Lumbopelvic Radiographs

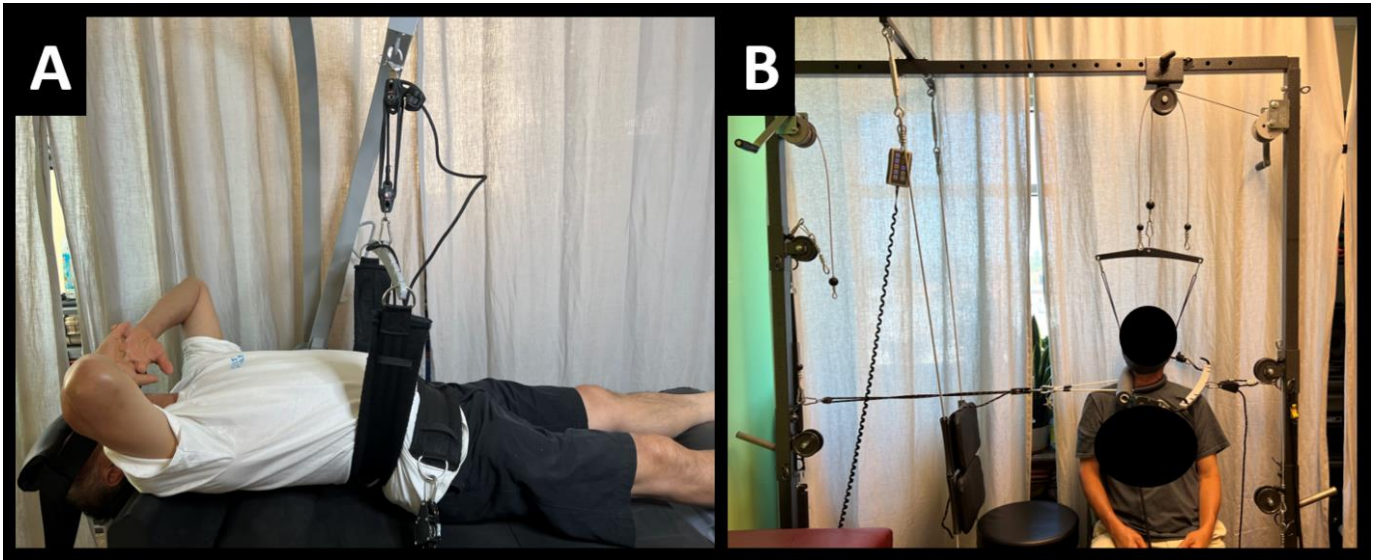


**Image Features:** The green line represents a normal, ideal frontal lumbopelvic spinal alignment including sacral base and leg length. The red line represents the actual frontal lumbopelvic alignment including sacral base and leg length. The right side of the radiographs are the left side of the patient.

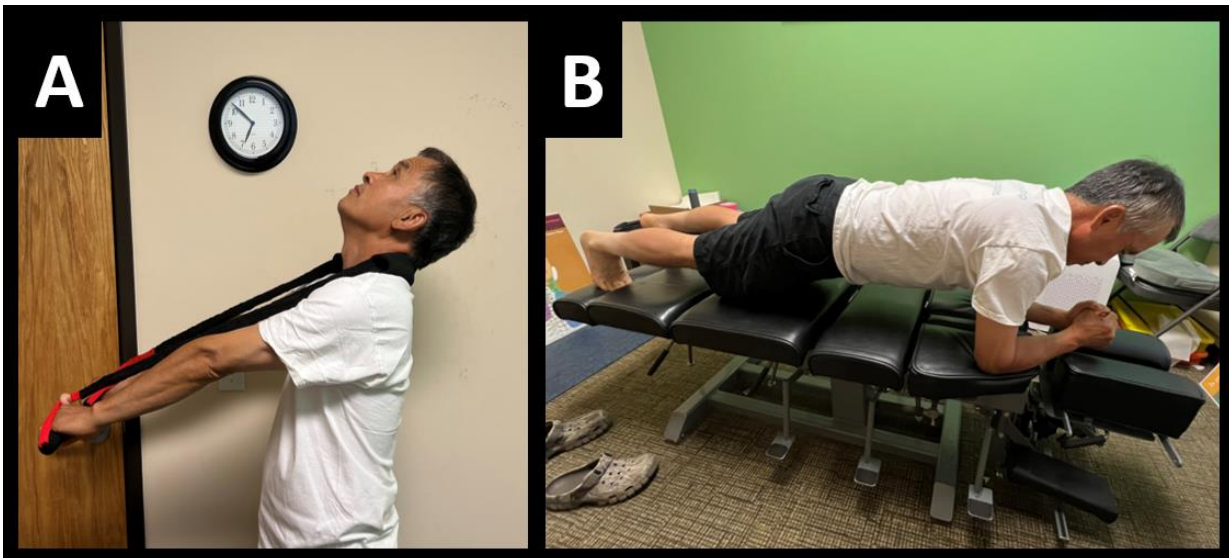
**Figure 5.** Pre-Treatment AP Right Shoulder Radiograph



**Figure 6A-B.** Chiropractic BioPhysics® Mirror Image® Spinal Traction



**Figure 7A-B.** Chiropractic BioPhysics® Mirror Image® Spinal Exercise





## 7

# Correction of Whiplash-Induced Cervical Subluxation Using Chiropractic BioPhysics® Methods: A Case Series

Tim C Norton, DC<sup>1</sup>, Paul A Oakley, DC, MSc, PhD(c)<sup>2</sup>, Deed E Harrison, DC<sup>2</sup>

<sup>1</sup>Private Practice, Shoreline, WA, USA

<sup>2</sup>CBP Nonprofit, Eagle, ID, USA

### Abstract

**Objective:** To illustrate how motor vehicle rear-end impacts subluxate the cervical spine and how cervical extension traction can re-establish the cervical lordotic alignment and facilitate patient recovery.

**Clinical Features:** A retrospective reporting of 7 adult patients (4 males and 3 females between 28 and 42 years-of-age) who were involved in a whiplash crash event. Each patient had been treated prior to the whiplash crash event for cervical spine subluxation (straightening of the cervical spine) in which they increased their lordosis after receiving Chiropractic BioPhysics® (CBP®) rehabilitation. All cases had radiographic assessment that quantified the return of subluxation of the cervical spine following the whiplash event. The patients then received CBP® rehabilitation procedures for a second time and demonstrated a reestablishment of the cervical lordosis.

**Intervention & Outcomes:** After an average of 3 years and 9 months following their initial program of care (ranging from 1 to 7 years), the 7 patients sought care for a second time due to being in a motor vehicle collision (MVC). At this time, compared to their previous post-treatment spine radiographs, there was an average alteration reduction of 19° in cervical lordosis, a 10 mm increase in anterior head translation (AHT or +TzH), a 11° reduction in the atlas plane angle (APL) and a 30% increase in Neck Disability Index (NDI) after their MVC. After the crash, a second round of CBP® rehabilitation was administered and there was an average 15° improvement in cervical lordosis, 11 mm reduction in AHT (+TzH), a 10° increase in the APL, and a 23.7% improvement in NDI after an average of 35 treatments over 9 weeks. This treatment restored them to pre-MVC injury alignment. There were no adverse events reported.

**Conclusion:** This case series demonstrates that MVCs directly alter the alignment of the cervical spine. Rehabilitation of the cervical curve using extension traction restores the patients' initial pre-crash injury alignment and may be responsible for improvement in patient conditions. Clinical trials are needed to confirm the findings.

## 8

# Resolution of Chronic Whiplash Associated Neck Pain and Disability Resulting from a Motor Vehicle Crash Following Correction of Sagittal Cervical Spinal Alignment and Posture Using Chiropractic BioPhysics® Structural Spinal Rehabilitation: A Case Series

Michael L Underhill, DC<sup>1</sup>, Paul A Oakley, DC, MSc, PhD(c)<sup>2</sup>, Deed E Harrison, DC<sup>2</sup>

<sup>1</sup>Private Practice, Beaverton, OR, USA

<sup>2</sup>CBP Nonprofit, Eagle, ID, USA

## Abstract

**Objective:** To present a case series documenting resolution of chronic whiplash associated neck pain (NP) and disability resulting from a motor vehicle crash (MVC) following correction of sagittal cervical spinal alignment and posture using Chiropractic BioPhysics® (CBP®) structural spinal rehabilitation in 7 patients.

**Clinical Features:** Seven adult patients (4 female and 3 male) between the ages of 33 and 67 years with a mean age of 43.0 ± 10.3 years (95% CI), height of 173.5 ± 5.7 kg, and weight of 97.2 ± 13.3 presented to a chiropractic practice with a history of a whiplash associated NP and disability resulting from a MVC and lasting between 6 and 9 months. No patient was included with less than 3 months of NP and disability or significant disability that required alternative management than that described in this study. The selection was based on a clinical examination indicating NP and disability using outcome assessments and spinal alignment and posture findings using plain radiography of the spine. Whiplash associated pain and disability lasting 3 months or longer is considered chronic [1]. Little recovery is expected to occur outside of 3 months following a MVC [2]. All initial exam findings were obtained after 3 months or longer of neck pain and disability.

Using a numeric rating system (NRS) to document pain on a scale of 0 to 10 where 0 is no pain and 10 is maximum pain, the patients rated their neck pain at initial and final exams. The mean initial NRS score was 5.7 ± 1.6. The patients completed a neck disability index (NDI) questionnaire used to determine how neck pain affects a patient's daily life and to assess self-rated NP disability. The mean initial NDI score was 34.9 ± 16.8% indicating moderate disability due to neck pain (Table 1).

Spinal alignment and posture findings were assessed using plain radiography of the spine. Initial radiographic examination and analysis revealed decreased sagittal curvatures of the cervical spine from C2 to C7 (ARA C2-C7) with a mean measurement of -13.3 ± 8.6° (ideal is -42°) and anterior translation of C2 with respect to C7 (+Tz C2-C7) with a mean measurement of 21.1 ± 4.3 mm (ideal is 0 mm) (Figures 1A and 2A, Table 1).

**Intervention and Outcomes:** The patients were treated over a range of 36 to 90 in-office visits with a mean of 58.1 ± 18.0 in-office visits using CBP® technique protocols consisting of Mirror Image® chiropractic spinal adjustments, exercises, and corrective traction. The Mirror Image® adjustments involved adjusting the patient with their neck in an extended position to account for the loss in cervical curvature. Mirror Image® traction was performed using a Cervical Denneroll™ (Denneroll™ Spinal Orthotics, New South Wales, Australia) to restore cervical extension (Figure 3). Mirror Image® exercises were performed including neck extension exercises using a Pro-Lordotic Neck Exerciser for spinal stability (Figure 4). The patient was prescribed a Cervical Denneroll™ for home Mirror Image® traction as well in which the patient would lie supine with Cervical Denneroll™ Spinal Orthotic for cervical spine correction.

Final outcome assessments revealed improved NRS scores with a mean of  $0.7 \pm 0.7$  and improved NDI scores with a mean of  $4.6 \pm 6.0\%$  indicating minimal or resolved disability due to neck pain. Six of 7 patients saw NDI improvements that meet the minimally clinically important difference (MCID) that reflects the change in an outcome which a patient would identify as meaningful or important. The other patient saw complete resolution of his NDI from 12% to 0% (Table 1). Final radiographic examination revealed improved ARA C2-C7 with a mean measurement of  $-23.2 \pm 7.6^\circ$  ( $9.9^\circ$  improvement) and improved +Tz C2-C7 with a mean measurement of  $14.1 \pm 4.8$  mm ( $7.0$  mm improvement) (Figures 1B and 2B, Table 1).

**Conclusions:** This case series shows that using CBP® corrective chiropractic technique to restore normal sagittal cervical spinal alignment and posture can result in resolved chronic whiplash associated neck pain and disability of 3 months or longer. There is limited research demonstrating resolution of chronic pain and disability in patients with chronic whiplash associated disorders (WAD) after 3 months. More research is needed to investigate the implications of CBP® structural spinal rehabilitation for patients with chronic WAD and who have failed rehabilitation programs without a focus on spinal alignment and posture.

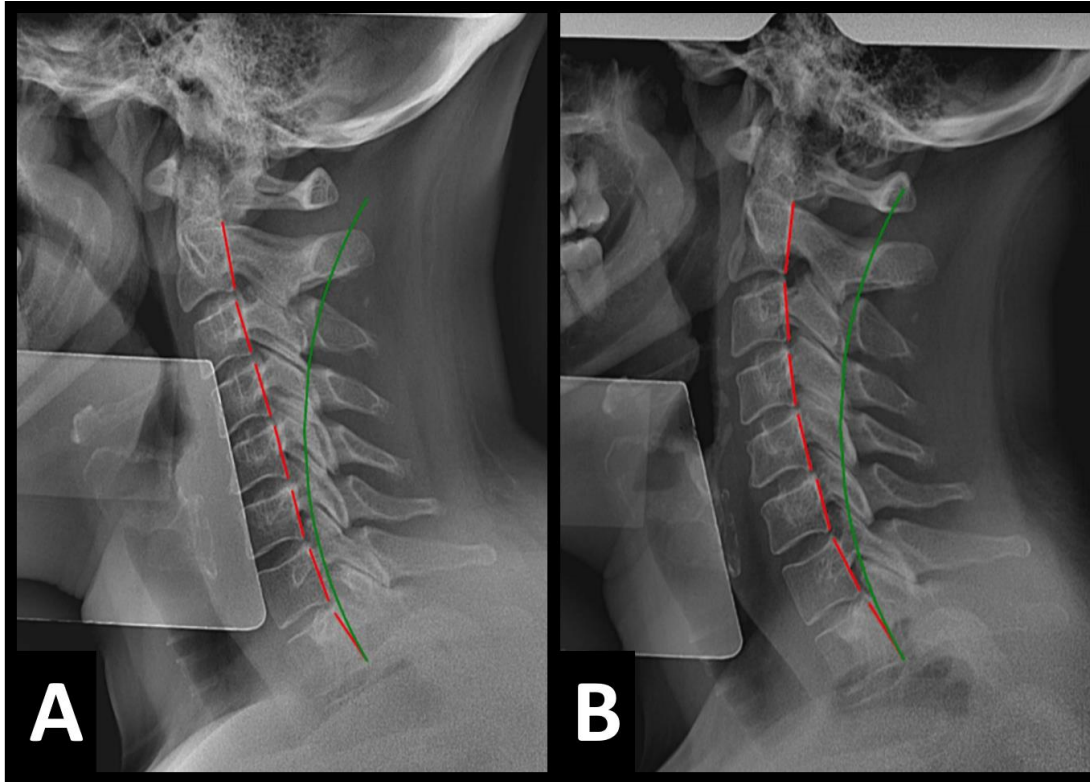
### References

1. Treede RD, Rief W, Barke A, Aziz Q, Bennett MI, Benoliel R, et al. A classification of chronic pain for ICD-11. *Pain*. 2015 Jun;156(6):1003-7.
2. Ritchie C, Sterling M. Recovery Pathways and Prognosis After Whiplash Injury. *J Orthop Sports Phys Ther*. 2016 Oct;46(10):851-61.

**Table 1.** Initial and Final Spinal Alignment and Posture Measurements and Neck Pain and Disability Outcome Measures

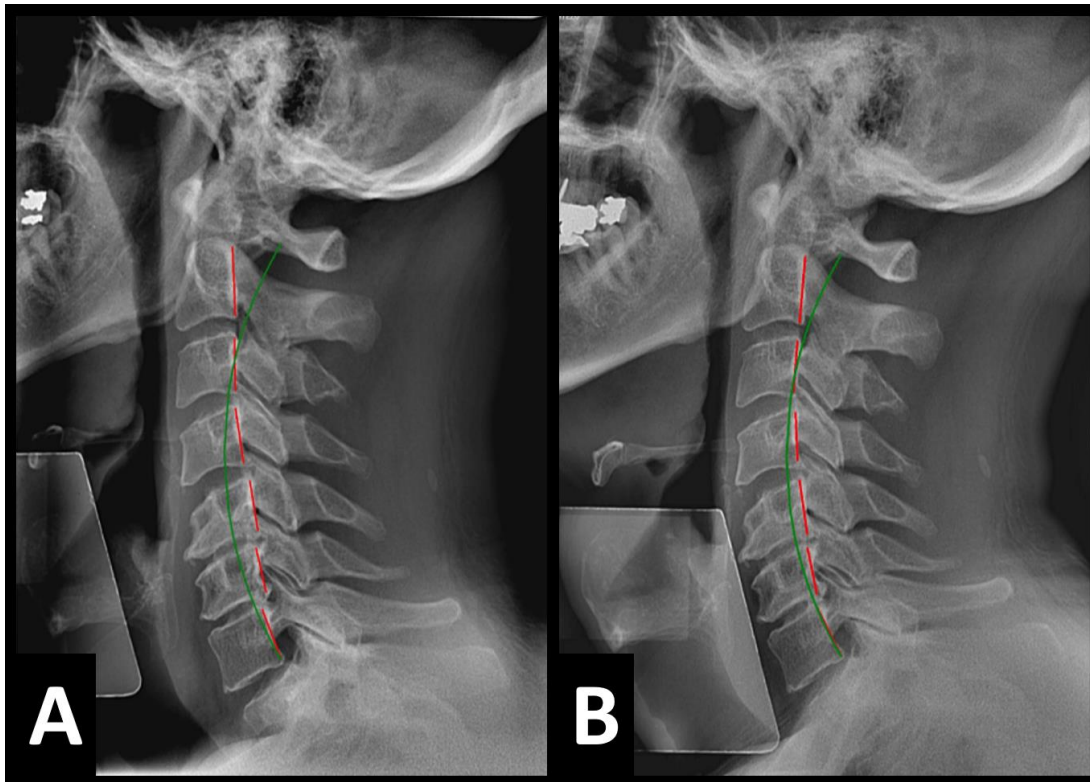
| Patient  | Spinal Alignment and Posture Measurements |                     |                       |                     | Neck Pain and Disability Outcome Measures |                       |                                 |                               |
|----------|---|---------------------|-----------------------|---------------------|---|-----------------------|---------------------------------|-------------------------------|
|          | Initial ARA C2-C7 (°)                     | Final ARA C2-C7 (°) | Initial Tz C2-C7 (mm) | Final Tz C2-C7 (mm) | Initial Neck Pain (NRS)                   | Final Neck Pain (NRS) | Initial Neck Disability (NDI %) | Final Neck Disability (NDI %) |
| 1        | -5.5                                      | -19.2               | 19.1                  | 6.2                 | 7   | 0                     | 34                              | 6                             |
| 2        | -29.4                                     | -36.1               | 17.2                  | 10.1                | 3   | 0                     | 12                              | 0                             |
| 3        | -13.3                                     | -16.3               | 22.1                  | 15.3                | 7   | 1                     | 48                              | 6                             |
| 4        | -6.4                                      | -16.9               | 18.1                  | 13.2                | 5   | 1                     | 26                              | 0                             |
| 5        | -9.6                                      | -33.2               | 30.2                  | 18.4                | 5   | 0                     | 30                              | 2                             |
| 6        | -6.4                                      | -16.9               | 18.1                  | 13.2                | 5   | 1                     | 26                              | 0                             |
| 7        | -22.6                                     | -23.6               | 23.0                  | 22.0                | 8   | 2                     | 68                              | 18                            |
| Average  | -13.3                                     | -23.2               | 21.1                  | 14.1                | 5.7                                       | 0.7                   | 34.9                            | 4.6                           |
| + 95% CI | 8.6                                       | 7.6                 | 4.3                   | 4.8                 | 1.6                                       | 0.7                   | 16.8                            | 6.0                           |

**Figure 1A-B.** Initial and Final Neutral Lateral Cervical Radiographs Example 1



**Image Features:** The green line represents a normal, ideal sagittal cervical spinal alignment. The red line represents the actual posterior tangent lines of the C2-T1 vertebrae.

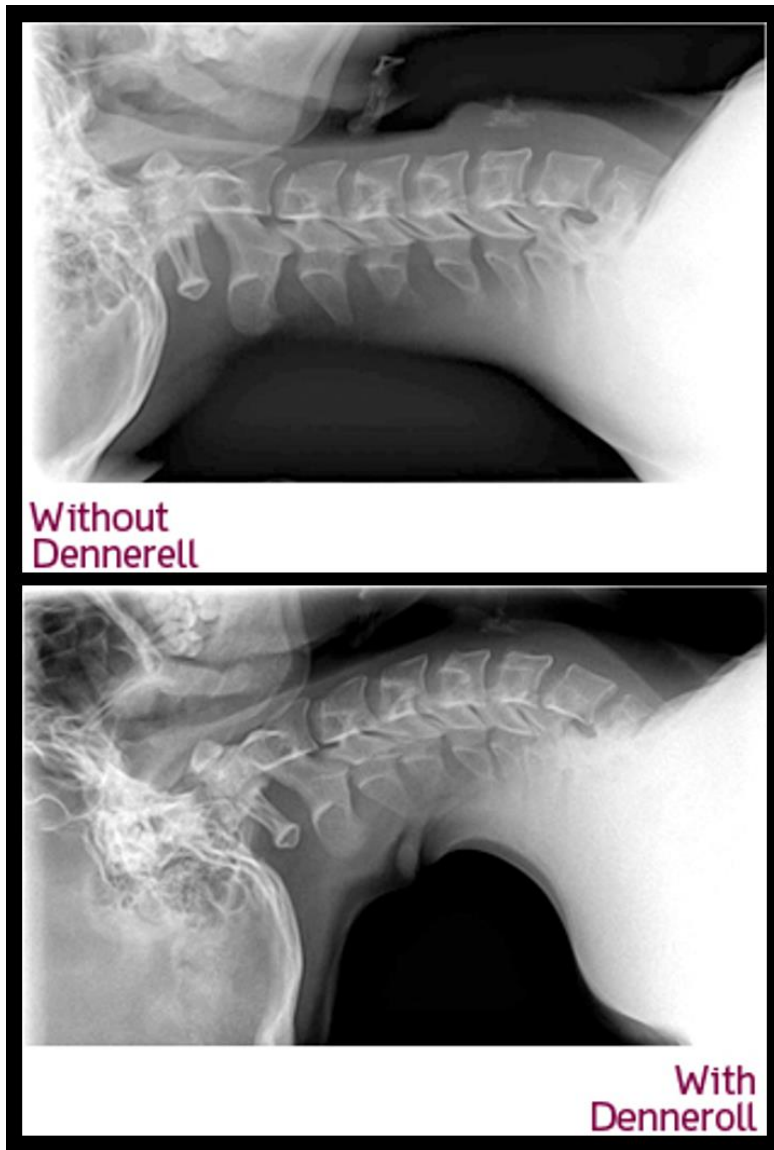
**Figure 2A-B.** Initial and Final Neutral Lateral Cervical Radiographs Example 2



**Image Features:** The green line represents a normal, ideal sagittal cervical spinal alignment. The red line represents the actual posterior tangent lines of the C2-T1 vertebrae.



**Figure 3.** Effects of Cervical Denneroll™ Spinal Orthotic on NLC Radiographs



**Figure 4.** Pro-Lordotic Neck Exerciser

