

The Role of Ultrasound in Detecting Brain Tumors During Surgery

Zhyar Polla Abdulla^{1*}, Anjam Ibrahim Sulayman², Azhin Shafeeq Tawfeeq³**Authors' Information**

1. MBChB, Trainee at Kurdistan Board of Medical Specialities- Neurosurgery, Hawler Teaching Hospital

2. Assist. Prof. Neurosurgeon, head of neurosurgery department, Hawler medical university, college of medicine, Hawler Teaching Hospital

3. Specialist Neurosurgeon, Hawler Teaching Hospital

***Corresponding author:**

Dr. Zhyar Polla Abdulla
polla.toufic@gmail.com

Funding information

Self-funded

Conflict of interest

None declared by authors

Received : August, 2022

Published: September, 2022

Abstract

Background: Intraoperative ultrasound (IOUS) have shown to be useful tool with an overall higher diagnostic value in detection of brain tumors and an effective tool to maximize the extent of resection which an important challenge in neurosurgical procedures

Aim of study: To evaluate the role of intraoperative ultrasound in resection of brain masses and the extent of removal

Patients and Methods: An observational cross-sectional study conducted at PAR private hospital in Erbil, Iraq, during a period of 2 years and followed up from the beginning of 2020 till the end of 2021. The study included 57 patients with brain mass lesions, they were operated on and followed up during the study period. In all operations ultrasound used during surgery to aid the resection of masses. Brain MRI was performed within 48 hours postoperatively to assess the extent of resection.

Results: The mean age of the patients was (45.1 ± 17.3) and range of 7-73 years. Males were relatively dominant than females among the studied groups, 54.4% vs. 45.6%, respectively. Glioblastoma (GBM) and pilocytic astrocytoma grade II, were more frequent type among the studied group, they contributed for 29.8% and 21.1%, respectively. Total resection was documented in 71.9% of the patients and it was not affected by the age, gender, type of tumor or its location, in all comparisons, P. value > 0.05, not significant.

Conclusions: Intraoperative ultrasound had a significant beneficial role in detecting brain tumors during surgery providing a high total resection rate of brain masses in both adults and pediatric patients. It was less time consuming, easy to performed and allow good monitoring for the progress of neurosurgical procedures

Keywords: Intraoperative imaging, ultrasound, brain tumors, neurosurgeries

This article is open access published under CC BY-NC Creative Commons Attribution Non-Commercial License: This License permits users to use, reproduce, disseminate or display the article provided that the author is attributed as the original creator and that the reuse is restricted to non-commercial purposes, (research or educational use).



1. INTRODUCTION

Malignant and non-malignant brain tumors represent a significant health problem worldwide, Regarding the risk factors of brain tumors, ionizing radiation and genetic factors are the major confirmed risk factor. The global annual incidence of brain tumors and spinal cord reaches in the world collectively reaches almost 7-11 /100,000. For a total of about 330,000 new cases of CNS cancers reported globally. Additionally, approximately 227,000 deaths and 7.7 million disabilities have been reported globally (1–3).

Primary brain tumors contributes for almost 1.7% of all cancers (4) with a global incidence of 3.9/100,000. The incidence rates of these cancers are vary according to the age, gender and region with higher rates in North Europe, Australia, United states and Canada. African populations show higher incidence rate of benign tumors while malignant tumors are more frequently reported in Caucasian population (5).

In Arab countries, the incidence of primary brain tumor is also varied, in Arab Gulf Cooperation Council Countries (GCC), the incidence rate ranged between 2.4 and 1.6 per/100000 in males and females, respectively (6). In Jordan, it is 5.01 per 100,000 (7).

In Iraq, the incidence rate of brain cancers is not much different than other countries, in 2016 it was about 2.97/100,000 (8). In Kurdistan region in Iraq, results of 7-year cancer registry in Erbil and Duhok have shown that total incidence of brain cancers in males and females was 2.9 and 2.3/100,000, respectively and the rate increased with advancing age (9). Globally, mortalities due to CNS tumors represent almost 3.7% of all cancers' mortalities, with higher mortality rates in adults than in child population. The 5-10- year survival rates ranged between 0.71% to 30%, according to the type of cancer. The more frequent primary brain tumors are meningiomas, they contribute for 36.8% of all tumors. Gliomas are the most frequent malignant type, representing 75% of all malignant CNS tumors (5).

Surgical therapy remain the gold standard therapeutic modality for almost all brain tumors unless contraindicated (10). Surgical resectability is the first and most important consideration in almost all instances when the brain tumors are diagnosed, with an exception when multiple brain metastases are found that been impractically resectable (11).

Complete surgical resection is crucial prognostic factor in brain tumors and associated with longer disease-free time and longer survival (12,13). Hence, neurosurgeons require the identification of residual tumors in the operation theater in addition to recognition of the adjacent normal tissues. Neurosurgeon mainly rely on and commonly use subjective assessment such as visualization of differences or textures palpation during resection of brain tumors to differentiate the tumor lesions from the normal tissues. This subjective assessment during resection, may results in potentially either incomplete resection of tumor or accidental removal of normal tissue (14). On the other hand, malignant brain tumors are commonly difficult to be differentiated from the normal proximal tissues. The resection of normal tissue may leads to postoperative neurological defects (12).

To get more precise and optimal resection margin in brain tumors therapy, different strategies and intraoperative techniques have been developed worldwide. Neuro-navigation MRI, spectroscopy, optical fluorescence imaging and intraoperative ultrasound have been used in many neurosurgeries for brain tumors (14,15). The standard of treatment in modern neurosurgery and neuroncology is focused on maximizing tumor resection , minimizing the possibilities of causing damage and improve patients' outcome (16).

Image Guided Surgery gives a perspective of the spatial location of the tumor and its surroundings. In addition to other intraoperative imaging modalities such as intraoperative MRI (iMRI), intraoperative Raman spectroscopy, positron emission tomography imaging, IOUS considered as a strong efficient modality in planning for resection of brain tumors, a quick to perform, safe and low costly, and has been compared favorably against magnetic resonance imaging (MRI) particularly in tumors that located in skull-base and eloquent areas(15)

Intraoperative ultrasound (IOUS) has historically played and continues to play an important role in neurosurgical procedures to maximize the extent of resection and increase the total resection rate of brain tumor (17–20)

Intraoperative MRI (iMRI) in brain surgery

Intraoperative MRI (iMRI) is the most important imaging modality of choice in diagnosis and recognition of tumor margins in parenchymal tissue of brain. High incorrect assumption made by surgeon about the extent of resection without the use of iMRI. It has a dramatic

optimization and improvement for the extent of resection (21,22) Despite its beneficial and significant role, iMRI system is costly and its use is need long time that increases the operation time, where an additional one hour is needed for surgeries involving iMRI compared to conventional surgeries (23), furthermore, it needs larger operating area and most iMRI had a relative low magnetic field strength. On the other hand, dose and timing of contrast add problems to the use of iMRI which influence the enhancement and may affect the judgment about the residual extent of brain tumor (24,25)

Intraoperative ultrasound (IOUS)

The first applications of intraoperative ultrasound in the neurosurgical field began in 1950 (26) Conventional intraoperative ultrasound (US) was described by Rubin and Dohrmann in the 1980s, and its use widely reported as an important accurate and ease to use technique in the localization and characterization of intracranial masses and help to guide surgical resection and reduce the accidental damage to normal brain tissues (27,28), since then, it has been a part of the routine intraoperative support and monitoring techniques in numerous neurosurgery departments. IOUS has applications in cranial and spinal cord surgery. With it, images with higher quality are obtained (29,30)

Intraoperative ultrasound characterized by low cost, harmless, reproducible, risk-free, without special preparations. It allows to observe, in real time, the location, the size, the borders, the relationship with neighboring structures, the vascularization, the state of the resection in the tumors. It can be done as many times as the surgeon requires. It does not use ionizing radiation, and it does not have specific contraindications, nor risks for patients or medical personnel (31).

It can be used, after the craniotomy on the dura mater, in the evasion of vessels; on the cerebral cortex, with the determination of the distance to the subcortical lesions; in the plan of approach, resection of lesions verified in real time, and, after closing the dura mater, it allows to detect complications. Saline solution should always be irrigated to achieve a better interface (32,33).

Nonetheless, despite its benefits, IOUS is not well defined in in routine clinical practice and the quality of images could be affected by motion artifact and inter-operator variability. Also its use is restricted in identification of deep tumors due to low resolution images (15,32)

Other intraoperative modalities:

Intraoperative Raman spectroscopy and optical fluorescence imaging are other techniques that can be used intraoperatively, when the conventional IOUS and iMRI cannot achieve optimal images or they lack a high sensitivity or specificity. Raman spectroscopy could be the necessary tool because it can provide spectroscopic properties of tissues based on vibrational information about chemical bonds that resulted from the inelastic scattering of incidental light, it has an accuracy of 90% to successfully identify invasive brain cancers (34). Intraoperative optical fluorescence imaging fluorescence has proved to be a powerful and promising tool for providing real-time information to the surgeon about the tumor site and its margins (15). However, some of the main challenges for intraoperative fluorescence imaging are limited accuracy, limited quantity, limited penetration depth, and limited availability of specific contrast agents (35)

2. METHODOLOGY

This was an observational cross-sectional study conducted at PAR private hospital in Erbil, Iraq, during a period of 2 years and followed up from the beginning of 2020 till the end of 2021.

A convenient sample of 57 patients who were operated on for resection of brain mass lesions were included and followed up postoperatively during the study period. In all operations ultrasound used to aid the resection of masses.

Inclusion criteria:

1. Patients of both genders and at any age
2. Patients who proved diagnosed to have intra axial or intradural brain masses including
 - a) High grade gliomas
 - b) Low grade gliomas
 - c) Metastatic lesions
 - d) Cavernomas

Exclusion criteria:

Patients with one or more of the following were excluded from the study

1. Extra axial lesions i.e. meningiomas
2. Extradural lesions
3. Bony lesions
4. Recurrent tumors
5. Incomplete data
6. Cases that managed with conventional surgery without using ultrasound.
7. Patients who refused to participate in the study (non-consenting)
8. Patients who were missed to follow-up

All ethical issues for the study protocol were approved by the Research Protocol Scientific Committee in Kurdistan Board of Medical Specialties, Ministry of Higher Education & Scientific Research, Kurdistan Regional Government-Iraq.

Data collection:

Data were collected using a pre-constructed data collection sheet (questionnaire) included four sections, the first one for demographic characteristics of the patients such as age, gender, duration of diseases, medical and surgical history. The second section for the clinical examination, laboratory findings, imaging findings before surgery; tumor type and site or location. The third section of the questionnaire for the operative findings and resection extent; total or subtotal. The fourth section for the postoperative and follow up imaging findings with registration of final decision about the extent of resection

Surgical and imaging procedures

All patients were examined clinically for general and neurological status, in addition, all preoperative routine investigations were performed. In all patients brain MRI was done before surgery to approve the diagnosis of brain masses.

The standard surgical procedures and interventions were applied and ultrasound device was used before, during and directly after resection

All surgeries were performed under general anesthesia which initiated by anesthesia and intensive care expert specialist.

Ultrasound digital scanner with endocavity transducer which is used in many surgeries. Frequencies that used in examination were applied accordingly. To examine deep details, particularly with large craniotomies, low frequencies were applied despite they provide low image spatial resolution, but low frequencies provide better deep penetration with low degree of attenuation waves.

The ultrasound device probe was covered with sterile glove filled with gel. To obtain the good and best resolution of image of the mass and the brain tissue, patient's head position that make the resection cavity to be that prevent the air artifact by keeping the saline in the cavity of resection. On the other hand a proper size of probe and frequency were selected, moreover, scanner brightness, depth , focus and frequency were set properly. All these factors were taken into account to get the best image resolution.

For delineation of the brain mass, ultrasound used before the dural opening. ultrasound used after dural opening for assurance and adapting of the site and direction of surgical access. During the resection, ultrasound aid to identify the surgical process taking into account the better path and best site of cortical incision with avoidance eloquent tissue as can as possible according to the pre-operative imaging information. However, the decision about the residuals detected by ultrasound in the eloquent area was made by the surgeon to decide about the extent of resection as gross-total or subtotal resection.

Brain MRI was performed within 48 hours postoperatively to assess the extent of resection, however, final decision about the resection was made according to the MRI that performed after three months of follow up after surgery. Total resection was considered when no mass detected by MRI. Subtotal resection was considered when more than 50% resection.

All patients were followed up by the surgical team from the hospital composed of the expert professional specialist neurosurgeon and neurosurgery residents

Data management and analysis:

Data of the patients were coded, entered into a computerized database software with statistical utilities; for this purpose, the statistical Package for Social Sciences version 26 was used in all statistical procedures and analysis. Descriptive statistics presented in tables with frequencies, percentages, mean and standard deviation. Appropriate statistical tests were applied accordingly, Chi-square test and Fisher's exact test used to assess the association

between degree of resection and other variables. Binary logistic regression analysis was performed using the degree of resection after three months as a dependent variable versus age, gender, type and location of tumor, as independent variables.

Regression coefficient (B) standard error (SE), Odds ratio and level of significance (P value) were reported. All statistical tests applied at a level of significance of 0.05 or less to be significant difference or correlation

3. RESULTS

This study included 57 patients presented with brain tumors and underwent surgical treatment, the mean age of patients was mean age of (45.1 ± 17.3) and range of 7-73 years; however, 7 patients (12.3%) aged 20 years or less, 8.8% at 21-30, 17.5% at age 31 – 40 years, 21.1% aged 41 – 50 years and the remaining 40.4% were older than 50 years. Males were relatively dominant than females among the studied groups, 54.4% vs. 45.6%, respectively, (Table 1).

Distribution of the patients according to the type of tumor is demonstrated in (Table 2) where glioblastoma (GBM) and pilocytic astrocytoma grade II, were more frequent type among the studied group, they contributed for 29.8% and 21.1%, respectively , followed by cavernoma, metastasis and astrocytoma grade I in a rate of 15.8%, 14% and 12.3%, respectively. Oligodendroglioma grade III was the least frequent type reported in only 7% of the studied group. Regarding the location of tumor, 52.6% of tumors were cortical and 47.4% were deep seated tumors, (Table 3).

After 3 months of follow up, assessment of degree of resection revealed a total resection in 41 (71.9%) of patients while subtotal resection in 16 (28.1%) patients, (Table 4 & Figure 1).

Further analysis was performed to assess the relationship between degree of resection after three months of follow up and patients' characteristics, using cross-tabulation, this analysis revealed that the total resection rate was better in younger age patients, where it was 85.7% in patients aged ≤ 20 years, followed by 80% in those aged 21-30 years , 60% in patients aged 31-40 years and the lower total resection rate was 58.3% in patients aged 41-50 years while a rate of 78.3% reported in patients older than 50 years, this reflected that total

resection rate was better in patients at extreme ages, 30 years or younger and older than 50 years, (**Table 5 and Figures 2**).

Total resection rate was higher in females than males, 76.9% vs. 67.7%, respectively, however, in both comparisons of degree of resection according to age and gender, the difference did not reach the statistical significance, (P. value > 0.05, not significant), (**Table 5 and Figures 3**).

Degree of resection after three months of follow up was not significantly affected by type or location of tumor, in both comparisons P. value was >0.05 not significant. Despite, this non-significant correlation, it had been observed, that best total resection rate of 88.9%, reported in patients with cavernoma, 75% in patients with pilocytic astrocytoma grade II patients, 75% in metastatic tumors, 70.6% in GBM, 57.1% in Astrocytoma grade I, and lower rate of 50% in patients with oligodendroglioma grade III, (**Table 6 and Figures 4**).

On the other hand , total resection rate was better in cortical than deep seated tumors, 76.7% vs. 66.7%, respectively, (**Table 6 and Figures 5**).

For more precise evaluation of the correlation between degree of tumor resection after three months and other variables that could have possible effect on degree of resection, a binary logistic regression analysis was performed using the degree of resection as dependent variable and other variables including age, gender, type of tumor and location of tumor, as independent variables. Results of binary logistic regression analysis are shown in (**Table 7**) where all variables still insignificantly associated with degree of resection. This findings indicated an important role for intraoperative ultrasound in detecting brain tumors during surgery reflected by high total resection rate of 71.9%, and not affected by patients' age, gender , tumor type or location.

Table 1. Age and sex distribution of the studied group

Variable		Frequency	Percentage (%)
Age (year)	≤ 20	7	12.3
	21 - 30	5	8.8
	31 - 40	10	17.5
	41 - 50	12	21.1
	> 50	23	40.4
	Mean (SD): 45.1 (17.3)		
Gender	Male	31	54.4
	Female	26	45.6
Total		57	100.0

SD: standard deviation of mean

Table 2. Distribution of the patients according to the type of tumor

Type of tumor	Frequency	Percentage (%)
GBM	17	29.8
Pilocytic astrocytoma grade II	12	21.1
Cavernoma	9	15.8
Metastasis	8	14.0
Astrocytoma grade I	7	12.3
Oligodendroglioma grade III	4	7.0
Total	57	100.0

Table 3. Distribution of the patients according to the Location of tumor

Location	Frequency	Percentage (%)
Cortical	30	52.6
Deep seated	27	47.4
Total	57	100.0

Table 4. Degree of resection after 3 months of follow up

Degree of resection	Frequency	Percentage (%)
Total resection	41	71.9
Subtotal resection	16	28.1
Total	57	100.0

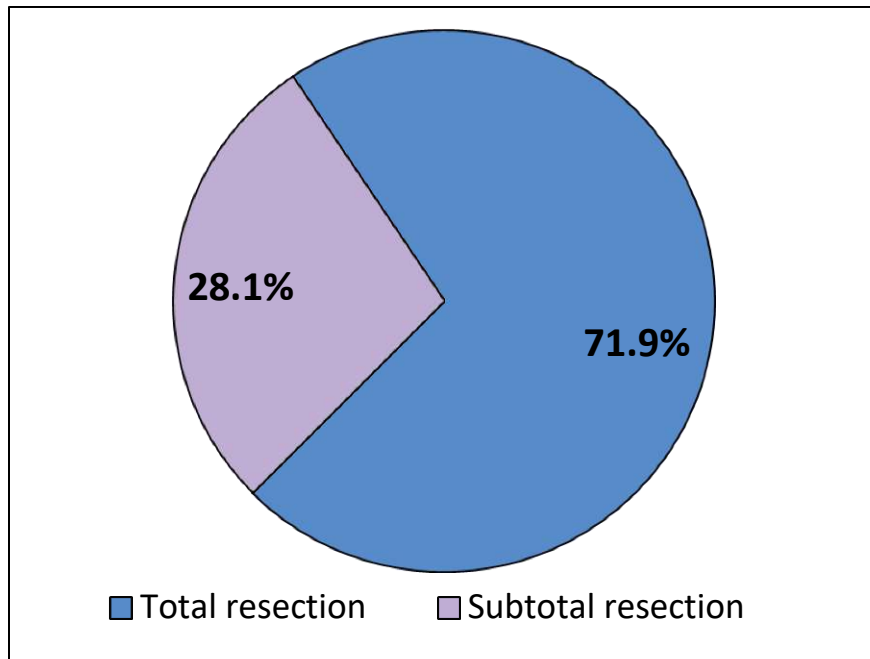
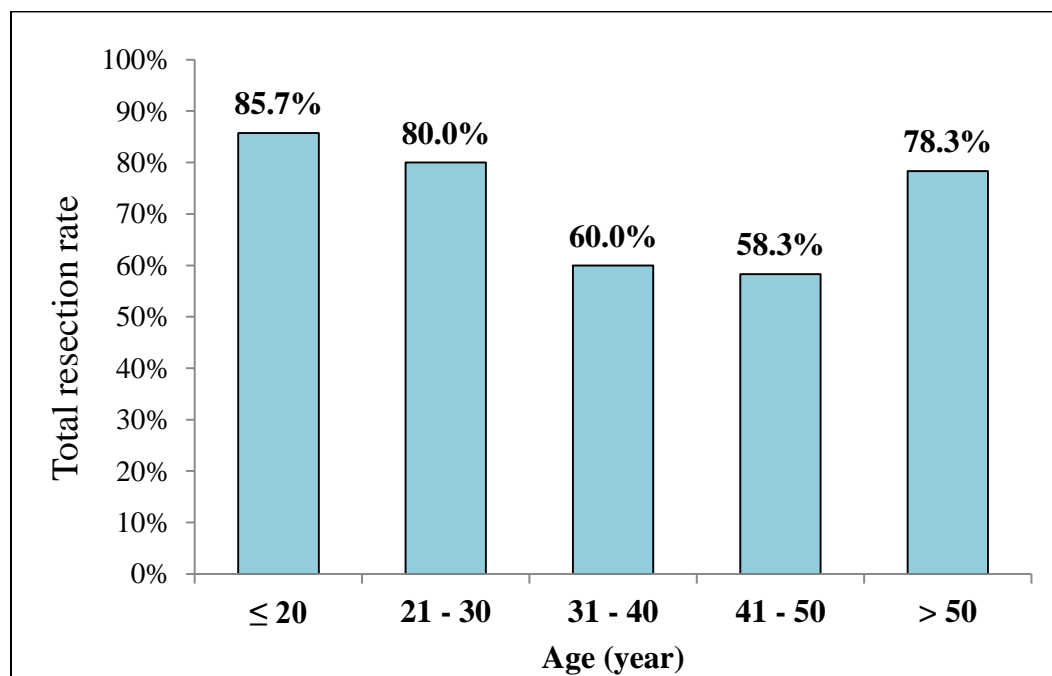


Figure 1. Total resection rate after three months of surgery

Table 5. Relationship between degree of resection after three months of follow up and patients' characteristics

Variable		Total resection		Subtotal resection		P. value
		No.	%	No.	%	
Age (year)	≤ 20	6	85.7	1	14.3	0.544 NS
	21 - 30	4	80.0	1	20.0	
	31 - 40	6	60.0	4	40.0	
	41 - 50	7	58.3	5	41.7	
	> 50	18	78.3	5	21.7	
Gender	Male	21	67.7	10	32.3	0.422 NS
	Female	20	76.9	6	23.1	

NS: Not significant

**Figure 2. Total resection rates after three months of follow up according to age of patients**

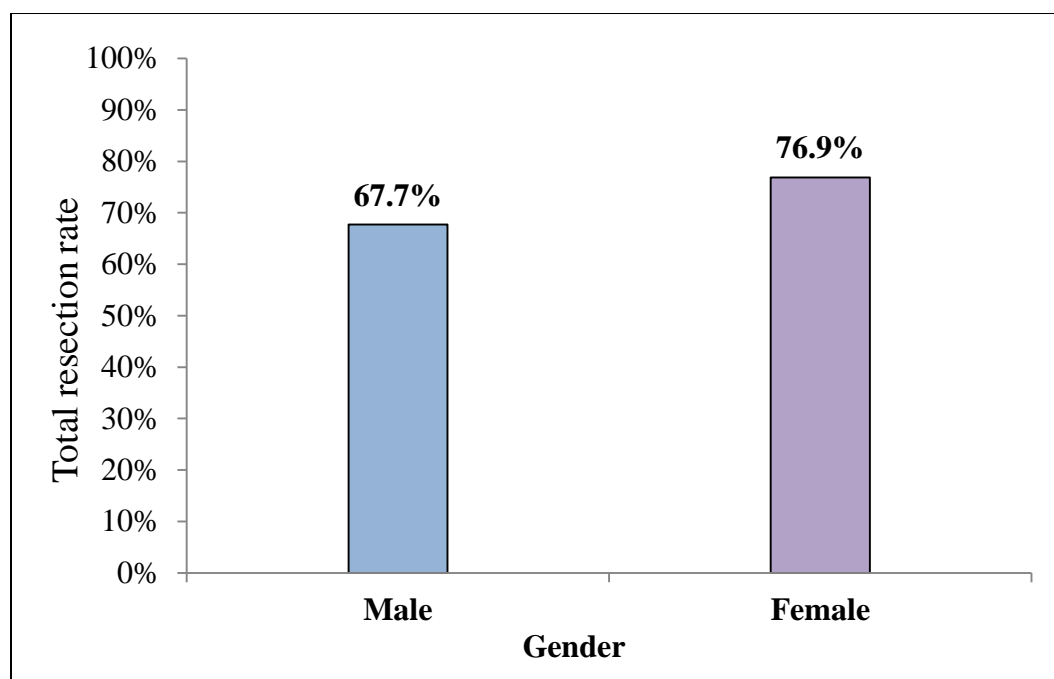


Figure 3. Total resection rates after three months of follow up according to gender of patients

Table 6. Relationship between degree of resection after three months of follow up and tumor characteristics

Characteristic	Total resection		Subtotal resection		P. value	
	No.	%	No.	%		
Type of tumor	GBM	12	70.6	5	29.4	0.684 NS
	Pilocytic astrocytoma grade II	9	75.0	3	25	
	Cavernoma	8	88.9	1	11.1	
	Astrocytoma grade I	4	57.1	3	42.9	
	Metastasis	6	75.0	2	25	
	Oligodendroglioma grade III	2	50.0	2	50	
Location	Cortical	23	76.7	7	23.3	0.402 NS
	Deep seated	18	66.7	9	33.3	

NS: Not significant

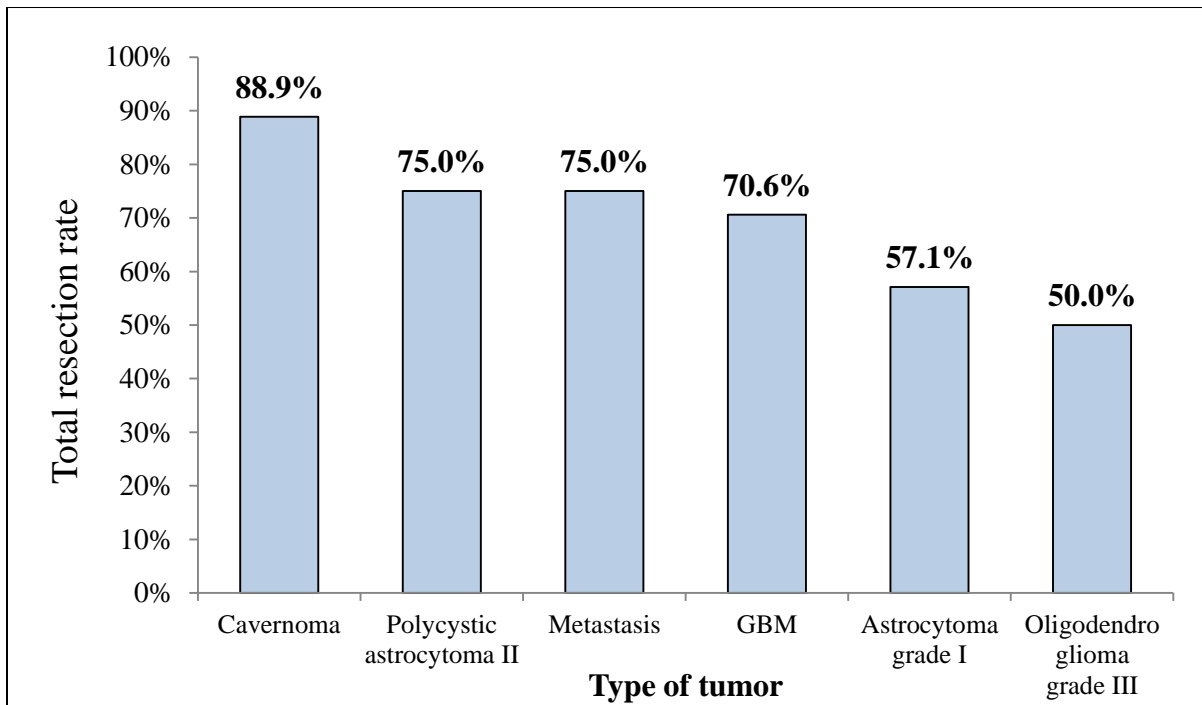


Figure 4. Total resection rates after three months of follow up according to tumor types

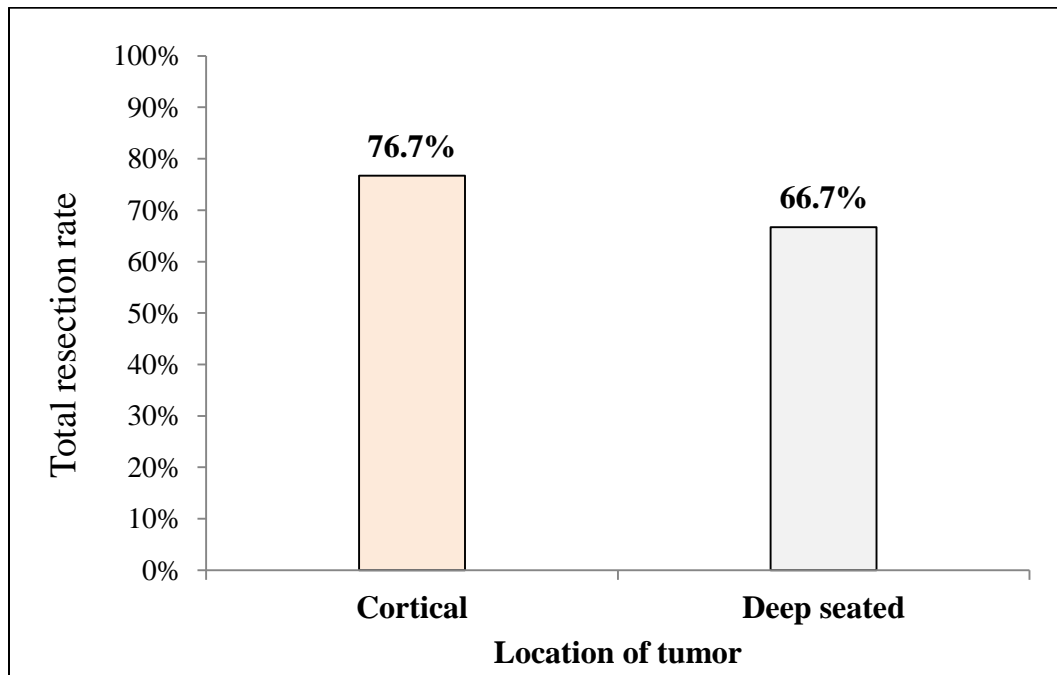


Figure 5. Total resection rates after three months of follow up according to tumor location

Table 7. Results of binary logistic regression for the association between degree of tumor resection after three months and other variables

Variables	B	S.E.	df	OR	P value
Gender	-0.503	0.624	1	0.605	0.420
Age Group	0.466	0.222	1	1.085	0.713
Type of tumor	0.134	0.186	1	1.143	0.471
Location of tumor	0.082	0.602	1	1.594	0.439

B: coefficient, SE: standard error of B, df: degree of freedom, OR: odds ratio

NS: Not significant

4. DISCUSSION

Brain tumor is one of the serious and significant health problem worldwide, surgical resection remains the gold standard option of treatment for operable brain tumors. Total resection of brain masses represents a real challenge for neurosurgeons in vast majority of neurosurgical centers, therefore, presence of a tool that help to the maximize the resection of tumor tissues without damaging the normal brain tissues is an important issue among surgeons, this can be achieved by well recognition between the normal and tumor tissues. Hence different imaging modalities are developed and adopted to achieve this goal (17–20). Intraoperative imaging is now an important adjunct in neurosurgery. Conventional image guided surgeries that mainly depend the CT or MRI that are obtained pre-operatively have some limitation due to the deformation because brain shift which occurs when the dura is opened and the manipulation of the brain that lead to inaccuracy of pre-operative acquired “maps” . This led to emerging of intraoperative imaging tools that provide updated and accurate imaging. Studies that assess the Intraoperative CT documented that it is not very useful due to lack of soft tissue resolution in addition to high exposure to radiation. From other point of view, despite the fact that navigation and intraoperative MRI is the most sensitive and specific diagnostic tool that preferred for detection of these lesions, and it is considered as the gold standard in this context, but it still has some limitations from logistic and financial points of view, that make it as non-attractive option for most neurosurgeons.

Additionally, using MRI intraoperatively increase the operation time which is not satisfactory to the surgeons, and also it needs larger operation area. Intraoperative US appeared as promising alternative and has proved to be a useful tool, more available, cost-effectiveness in neurosurgical procedures, less hazard to the patients and surgeons, easily applied and can be performed several times when it is needed, these characteristics help to overcome the limitations posed by CT and MRI, (31).

Many studies investigated the use and role of different imaging techniques intraoperatively, IOUS, have shown to be a useful tool in differentiation of brain edema tumors and normal tissues in the brain. Some investigators found that IOUS has an overall higher diagnostic value in detection of gliomas residuals also it has shown to be an effective tool to maximize the extent of resection (16,17,20,27,29,31).

Studies in Iraq about the IOUS use in brain tumors surgeries are scarce. Hence the present study aimed to assess the role of intraoperative ultrasound in resection of brain masses and to identify the extent of resection, therefore, a total of 57 patients with brain masses have been enrolled in this study. The mean age of the studied group was (45.1 ± 17.3) and range of 7-73, however, the 61.5% of the patients were older than 40 years and it had been observed that frequency of brain tumors increased with advancing age, on the other hand, males were relatively more frequent than females among the studied group, these were not unexpected findings and consistent with the epidemiological characteristics of brain tumors where epidemiological studies documented almost similar findings (2,36).

The present study found that glioblastomas (GBM) and pilocytic astrocytoma grade II, were more frequent types among the studied group followed by cavernoma, metastasis and astrocytoma grade I, while oligodendroglioma was least frequent. From another point of view, cortical masses were relatively more frequent than deep seated ones. The distribution and frequencies of types and sites of brain tumors vary in different studies and this could be attributed to the nature of the studied population, the age of patients, moreover, the survival rate of each type of these tumors significantly affects its prevalence in the population. Also the variation in the frequencies of brain tumor types could be attributed to the difference in the classification and definitions of these tumors where there is a variation between classification systems such as the third edition of international classification of

oncology diseases (ICD-O-3), Cancer institute's (NCI), center for disease control and prevention (CDC) and World Health Organization (37), previous studies also found that gliomas are the most common primary brain tumors in adults contributes for almost 75% of primary malignant brain tumors and of these more than half are glioblastomas. Pilocytic astrocytoma has been found as the most common non-infiltrative type (38–40).

In the current study after 3 months of follow up, the total resection was documented in 41 (71.9%) while subtotal resection in (28.1%) of patients. The extent of total resection is important in neurosurgery, therefore, the rate of total resection of brain tumor in our study can be considered good and high enough to get better outcome and survival, this high rate of total resection can be attributed to the role of intraoperative ultrasound used in our study which aid to increase the extent of resection with preserve eloquent structures.

These findings agreed that reported by Elmesallamy WA. (41) from Egypt who reported a total resection rate of 75% in patients who were operated on for brain mass lesions with using intraoperative US while the total resection rate was only 30% in patients underwent conventional surgeries without intraoperative US. However, several studies showed the important role of intraoperative US to achieve maximum and safe resection of brain masses(17,42–44).

The current study finding was close to that reported in India where Patil et al. documented that gross-resection of supratentorial lesions was 69.85% and for infratentorial lesions it was 89.29% while the subtotal resections were 19.12% and 7.14%, respectively, in Patil et al. study, biopsies were taken in the remaining 11.03% and 3.57%, of these lesions, respectively,(45).

Another study conducted by Moiyadi et al. compare radical resection with US control vs. awake craniotomy with intraoperative clinical monitoring for 22 patients with brain masses and found that intraoperative US was using intraoperative US was feasible and beneficial help to get a total resection rate of 78% (46).

In a retrospective study and included 260 patients, Sweeney et al. (20) found that IOUS was helpful to obtain more successful total resection in a rate of 81% in both adults and children groups, on the other hand, when IOUS combined with other imaging method, further

maximize the successful resection of brain masses. However, earlier studies reported a total resection rates of 74.5% (47) , 76% (17) and 81.8% (48).

The total resection rate reported in the current study was higher than that reported in a previous study conducted by Erdogan et al. who documented a total resection rate of 59.38% (19)

In the present study the total resection was lower than that reported by Serra et al. (18) and Steno et al. studies (49) who found that IOUS increases the gross-total resection rate in brain tumors, and they reported total resection rate of 95.5% and 97%, respectively, From other point of view, Zhang et al. proved that intraoperative ultrasound had high specificity and accuracy in identifying tumor residual with a sensitivity of 89.2%, specificity of 91.55% and accuracy of 90.38% (44)

Interestingly, IOUS has shown to have high detection rate for residual tumors in patients with high grade gliomas allowing a total resection rate of 73.3% (43). In this regard, Prada et al. reported that distortion due to brain shift could be corrected when correlate the intraoperative ultrasound images with that of pre-operative MRI. Hence they concluded that US is reliable, accurate and easy to use and not interrupted the surgery (50,51). The variation in the total resection rates among different studies could be attributed to the variation in the studied groups, types of tumors that resected and the US machines and techniques used in different studies.

The present study assessed the possible correlation between total resection rates and each of age and gender, despite the non-significant differences reported in total resection rates across the age groups or gender, higher total resection rate was observed in younger patients and in females. Also the current study did not find a significant difference in resection rates according to the type or location of tumors, nonetheless, higher rates reported in patients with Cavernoma and in patients with cortical tumors. The non-significant differences could be attributed to small sample size. However, previous studies did not discussed the differences of total resection rates according to patients' characteristics or tumor characteristics and further studies taking into account the possible effect of these variables can deal with these issues.

The present study is not free of some limitation, among these, the shortage in time lead to inclusion of small sample of patients, additionally, we couldn't include patients who were managed by conventional procedure without IOUS, because all the surgeries performed in our center were with the use of IOUS on the other hand the procedure that applied was according to the decision of neurosurgeon and patient's status that make it difficult to compare with patients from other centers. However, future studies with larger sample size and multiple centers are highly recommended for more precise comparison and conclusion.

5. CONCLUSIONS

According to the findings of this study, it can be concluded that intraoperative ultrasound had a significant beneficial role in detecting brain tumors during surgery providing a high total resection rate of brain masses in both adults and pediatric patients. It was less time consuming, easy to performed and allow good monitoring for the progress of neurosurgical procedures. Hence it is recommended to use intraoperative ultrasound in neurosurgical procedures for the resection of brain tumors as a useful imaging tool in defining the tumor tissues from the normal brain tissues and to maximize the resection and detection of residual tumor tissues, taking into account the fact that MRI is not available in all hospitals, cost-effectiveness and time of surgery.

6. BIBLIOGRAPHY

1. Vienne-Jumeau A, Tafani C, Ricard D. *Environmental risk factors of primary brain tumors: A review. Rev Neurol (Paris).* 2019;175(10):664–78.
2. Barnholtz-Sloan JS, Ostrom QT, Cote D. *Epidemiology of brain tumors. Neurol Clin.* 2018;36(3):395–419.
3. Mohammadi E, Ghasemi E, Azadnajafabad S, Rezaei N, Moghaddam SS, Meimand SE, et al. *A global, regional, and national survey on burden and Quality of Care Index (QCI) of brain and other central nervous system cancers; global burden of disease systematic analysis 1990-2017. PLoS One.* 2021;16(2):1–13.
4. Ferlay J, Colombet M, Soerjomataram I, Mathers C, Parkin DM, Piñeros M, et al. *Estimating the global cancer incidence and mortality in 2018: GLOBOCAN sources and methods. Int J cancer.* 2019;144(8):1941–53.
5. Reynoso-Noverón N, Mohar-Betancourt A, Ortiz-Rafael J. *Epidemiology of Brain Tumors.* In: Monroy-Sosa A, Chakravarthi SS, de la Garza-Salazar JG, Meneses Garcia A, Kassam AB, editors.

- Principles of Neuro-Oncology: Brain & Skull Base*. Cham: Springer International Publishing; 2021. p. 15–25.
6. Moin A, Rizvi SMD, Talib Hussain GD, Subaiea GM, Elsayed MMA, Ansari M, et al. *Current Status of Brain Tumor in the Kingdom of Saudi Arabia and Application of Nanobiotechnology for Its Treatment: A Comprehensive Review*. MDPI-Life. 2021;11(5):421–44.
 7. Tamimi AF, Tamimi I, Abdelaziz M, Saleh Q, Obeidat F, Al-Husseini M, et al. *Epidemiology of malignant and non-malignant primary brain tumors in Jordan*. Neuroepidemiology. 2015;45(2):100–8.
 8. Hussain AMA, Lafta RK. *Cancer Trends in Iraq 2000–2016*. Oman Med J. 2021;36(1):e219.
 9. Karwan M, Abdullah OS, Amin AMS, Mohamed ZA, Bestoon B, Shekha M, et al. *Cancer Incidence in the Kurdistan Region of Iraq: Results of a Seven-Year Cancer Registration in Erbil and Duhok Governorates*. Asian Pacific J Cancer Prev APJCP. 2022;23(2):601.
 10. Fernandes C, Costa A, Osório L, Lago RC, Linhares P, Carvalho B, et al. *Current standards of care in glioblastoma therapy*. Exon Publ. 2017;20:197–241.
 11. Johns Hopkins Medicine. *Brain Tumor Surgery [Internet]. Preparing for Brain Tumor Surgery*. 2022 [cited 2022 Jun 20]. Available from: www.hopkinsmedicine.org/brain-tumor/brain-tumor-surgery
 12. McGirt MJ, Chaichana KL, Attenello FJ, Weingart JD, Than K, Burger PC, et al. *Extent of surgical resection is independently associated with survival in patients with hemispheric infiltrating low-grade gliomas*. Neurosurgery. 2008;63(4):700–8.
 13. Laws ER, Parney IF, Huang W, Anderson F, Morris AM, Asher A, et al. *Survival following surgery and prognostic factors for recently diagnosed malignant glioma: data from the Glioma Outcomes Project*. J Neurosurg. 2003;99(3):467–73.
 14. Rosenthal EL, Warram JM, Bland KI, Zinn KR. *The status of contemporary image-guided modalities in oncologic surgery*. Ann Surg. 2015;261(1):46.
 15. Hu S, Kang H, Baek Y, El Fakhri G, Kuang A, Choi HS. *Real-Time Imaging of Brain Tumor for Image-Guided Surgery*. Adv Healthc Mater. 2018 Aug;7(16):e1800066.
 16. Alam IS, Steinberg I, Vermesh O, van den Berg NS, Rosenthal EL, van Dam GM, et al. *Emerging intraoperative imaging modalities to improve surgical precision*. Mol Imaging Biol. 2018;20(5):705–15.
 17. Moiyadi A V. *Objective assessment of intraoperative ultrasound in brain tumors*. Acta Neurochir (Wien). 2014;156(4):703–4.

18. Serra C, Stauffer A, Actor B, Burkhardt J-K, Ulrich N-B, Bernays R-L, et al. Intraoperative high frequency ultrasound in intracerebral high-grade tumors. *Ultraschall der Medizin-European J Ultrasound*. 2012;33(07):E306–12.
19. Erdoğan N, Tucer B, Mavili E, Menkü A, Kurtsoy A. Ultrasound guidance in intracranial tumor resection: correlation with postoperative magnetic resonance findings. *Acta Radiol*. 2005 Nov;46(7):743–9.
20. Sweeney JF, Smith H, Taplin A, Perloff E, Adamo MA. Efficacy of intraoperative ultrasonography in neurosurgical tumor resection. *J Neurosurg Pediatr*. 2018 May;21(5):504–10.
21. Rogers CM, Jones PS, Weinberg JS. Intraoperative MRI for brain tumors. *J Neurooncol*. 2021;151(3):479–90.
22. Hall WA, Truwit CL. Intraoperative MR-guided neurosurgery. *J Magn Reson Imaging An Off J Int Soc Magn Reson Med*. 2008;27(2):368–75.
23. Senft C, Bink A, Franz K, Vatter H, Gasser T, Seifert V. Intraoperative MRI guidance and extent of resection in glioma surgery: a randomised, controlled trial. *Lancet Oncol*. 2011;12(11):997–1003.
24. Nimsky C. Intraoperative MRI in glioma surgery: proof of benefit? *Lancet Oncol*. 2011;11(12):982–3.
25. Eljamel MS, Mahboob SO. The effectiveness and cost-effectiveness of intraoperative imaging in high-grade glioma resection; a comparative review of intraoperative ALA, fluorescein, ultrasound and MRI. *Photodiagnosis Photodyn Ther*. 2016;16:35–43.
26. Padayachy LC, Fieggen G. Intraoperative ultrasound-guidance in neurosurgery. *World Neurosurg*. 2014;82(3):e409–11.
27. Kane RA. Intraoperative ultrasonography: history, current state of the art, and future directions. *J Ultrasound Med*. 2004;23(11):1407–20.
28. Nielsen MB, Sjøgaard SB, Bech Andersen S, Skjoldbye B, Hansen KL, Rafaelsen S, et al. Highlights of the development in ultrasound during the last 70 years: A historical review. *Acta radiol*. 2021 Nov 1;62(11):1499–514.
29. Shores A, Beasley MB, Lee AM, Tollefson C, Seitz MA. Intraoperative Ultrasound Applications in Intracranial Surgery. *Front Vet Sci*. 2021;1339.
30. Ganau M, Syrmos N, Martin AR, Jiang F, Fehlings MG. Intraoperative ultrasound in spine surgery: history, current applications, future developments. Vol. 8, *Quantitative imaging in medicine and surgery*. 2018. p. 261–7.

31. Yeole U, Singh V, Mishra A, Shaikh S, Shetty P, Moiyadi A. Navigated intraoperative ultrasonography for brain tumors: a pictorial essay on the technique, its utility, and its benefits in neuro-oncology. *Ultrasonography*. 2020;39(4):394.
32. Sastry R, Bi WL, Pieper S, Frisken S, Kapur T, Wells III W, et al. Applications of ultrasound in the resection of brain tumors. *J Neuroimaging*. 2017;27(1):5–15.
33. Barone DG, Lawrie TA, Hart MG. Image guided surgery for the resection of brain tumours. *Cochrane Database Syst Rev*. 2014;(1).
34. Jermyn M, Mok K, Mercier J, Desroches J, Pichette J, Saint-Arnaud K, et al. Intraoperative brain cancer detection with Raman spectroscopy in humans. *Sci Transl Med*. 2015;7(274):274ra19-274ra19.
35. Kim T, O'Brien C, Choi HS, Jeong MY. Fluorescence molecular imaging systems for intraoperative image-guided surgery. *Appl Spectrosc Rev*. 2018;53(2–4):349–59.
36. McNeill KA. Epidemiology of brain tumors. *Neurol Clin*. 2016;34(4):981–98.
37. Miller KD, Ostrom QT, Kruchko C, Patil N, Tihan T, Cioffi G, et al. Brain and other central nervous system tumor statistics, 2021. *CA Cancer J Clin*. 2021;71(5):381–406.
38. Cohen AL, Colman H. Glioma biology and molecular markers. *Curr Underst Treat gliomas*. 2015;15–30.
39. Lapointe S, Perry A, Butowski NA. Primary brain tumours in adults. *Lancet*. 2018;392(10145):432–46.
40. de Robles P, Fiest KM, Frolkis AD, Pringsheim T, Atta C, St Germaine-Smith C, et al. The worldwide incidence and prevalence of primary brain tumors: a systematic review and meta-analysis. *Neuro Oncol*. 2015 Jun;17(6):776–83.
41. Elmesallamy WAEA. The role of intraoperative ultrasound in gross total resection of brain mass lesions and outcome. *Egypt J Neurol Psychiatry Neurosurg*. 2019;55(1):1–11.
42. Camp SJ, Apostolopoulos V, Raptopoulos V, Mehta A, O'Neill K, Awad M, et al. Objective image analysis of real-time three-dimensional intraoperative ultrasound for intrinsic brain tumour surgery. *J Ther Ultrasound*. 2017;5(1):1–8.
43. Pino MA, Imperato A, Musca I, Mauerer R, Giammalva GR, Costantino G, et al. New hope in brain glioma surgery: The role of intraoperative ultrasound. A review. *Brain Sci*. 2018 Nov;8(11).
44. Zhang G, Li Z, Si D, Shen L. Diagnostic ability of intraoperative ultrasound for identifying tumor residual in glioma surgery operation. *Oncotarget*. 2017 Sep;8(42):73105–14.

45. Patil D, Sharma V, Tiwar DP. Intraoperative Ultrasound in Intracranial Space Occupying Lesions. *World J Surg Med Radiat Oncol*. 2013;2(11):81–6.
46. Moiyadi A, Shetty P. Early Experience with Combining Awake Craniotomy and Intraoperative Navigable Ultrasound for Resection of Eloquent Region Gliomas. *J Neurol Surg A Cent Eur Neurosurg*. 2017 Mar;78(2):105–12.
47. Solheim O, Selbekk T, Jakola AS, Unsgård G. Ultrasound-guided operations in unselected high-grade gliomas--overall results, impact of image quality and patient selection. *Acta Neurochir (Wien)*. 2010 Nov;152(11):1873–86.
48. Wang J, Liu X, Ba YM, Yang YL, Gao GD, Wang L, et al. Effect of sonographically guided cerebral glioma surgery on survival time. *J ultrasound Med Off J Am Inst Ultrasound Med*. 2012 May;31(5):757–62.
49. Šteňo A, Karlík M, Mendel P, Čík M, Šteňo J. Navigated three-dimensional intraoperative ultrasound-guided awake resection of low-grade glioma partially infiltrating optic radiation. *Acta Neurochir (Wien)*. 2012 Jul;154(7):1255–62.
50. Prada F, Del Bene M, Mattei L, Lodigiani L, DeBeni S, Kolev V, et al. Preoperative magnetic resonance and intraoperative ultrasound fusion imaging for real-time neuronavigation in brain tumor surgery. *Ultraschall Med*. 2015 Apr;36(2):174–86.
51. Prada F, Del Bene M, Mattei L, Casali C, Filippini A, Legnani F, et al. Fusion imaging for intraoperative ultrasound-based navigation in neurosurgery. *J Ultrasound*. 2014 Sep;17(3):243–51.

Ethical Clearance:

All ethical issues for the study protocol were approved by the Research Protocol Scientific Committee in Kurdistan Board of Medical Specialties, Ministry of Higher Education & Scientific Research, Kurdistan Regional Government-Iraq. Patients enrollment and data collection were in accordance with the World Medical Association (WMA), declaration of Helsinki, The Ethical Principles for Medical Research Involving Human Subjects, 2013

Citation:

Abdulla Z.P, Sulayman A.I, Tawfeeq A.S. The Role of Ultrasound in Detecting Brain Tumors During Surgery. *AJMS* 2022; 8 (3): 239-61