



Journal Homepage: - www.journalijar.com

INTERNATIONAL JOURNAL OF ADVANCED RESEARCH (IJAR)

Article DOI: 10.21474/IJAR01/ 15164

DOI URL: <http://dx.doi.org/10.21474/IJAR01/ 15164>



RESEARCH ARTICLE

EOSINOPHILIC COLITIS: A RARE CASE REPORT AND REVIEW OF THE LITERATURE

Ahmed Mead¹, Zakarie Mohamud Mohamed², Omar Adam Sheikh^{2,3}, Yordanos Alem^{3,4} and Zebeaman Tibebu Gorfu⁵

1. Faculty of Medicine, Department of Basic Medical Science, Salaam University, Mogadishu, Somalia.
2. Department of Internal Medicine, Kalkaal Hospital, Mogadishu, Somalia.
3. Faculty of Medicine, Department of Basic Medical Science, Somali National University, Mogadishu, Somalia.
4. College of Health Science, School of Medicine, Addis Ababa University, Addis Ababa, Ethiopia.
5. Department of Internal Medicine, Adera Medical Center, Addis Ababa, Ethiopia.

Manuscript Info

Manuscript History

Received: 06 June 2022

Final Accepted: 10 July 2022

Published: August 2022

Key words:-

Eosinophilic Colitis, Bloody diarrhea,
Colonoscopy, Corticosteroids

Abstract

Primary eosinophilic gastrointestinal disease (EGID) is a rare inflammatory gastrointestinal disorder characterized by eosinophil infiltration in the gut. EGIDs are sub-grouped as eosinophilic esophagitis (EE), eosinophilic gastroenteritis (EG), and eosinophilic colitis (EC). The least frequent manifestation of EGIDs is EC which affects newborns and young adults. An 18-year-old male patient was admitted complaining of recurrent epigastric and lower abdominal pain, abdominal distension, vomiting, bloody diarrhea, and weight loss for a long time. Laboratory investigations performed showed a white blood cell (WBC) count of $14.5 \times 10^9/L$, with 62.1% neutrophils, 22.4% lymphocytes, 13.2% monocytes, 28.2% eosinophils, 0.1% basophils, and hemoglobin (HGB) level of 6.3 g/dL. Stool examination was positive in the helicobacter pylori test and occult blood. Colonoscopic biopsy showed active colitis with eosinophilia. We recommended corticosteroid treatment to the patient. With prednisolone treatment of 20 mg 2 times per day, the clinical features resolved.

Copy Right, IJAR, 2022.. All rights reserved.

Introduction:-

Primary eosinophilic gastrointestinal disease (EGID) is a rare inflammatory gastrointestinal disorder characterized by eosinophil infiltration in the gut, with no identified causes of secondary gut tissue eosinophilia. The exact incidence and prevalence of primary EGID remain unknown. However, secondary eosinophilic inflammation may occur in a wide range of gastrointestinal disorders such as IgE-mediated food allergy, reflux esophagitis, inflammatory bowel disease (IBD), Helicobacter pylori gastritis, vasculitis, connective tissue diseases, malignancy, and helminthic infestation; which have to be first excluded when considering primary EGID [1, 2].

The clinical presentation of EGID depends on the affected segment of the gastrointestinal tract, the depth of eosinophilic infiltration, and the local tissue response. Primary EGID can affect any segment in the gastrointestinal tract or combination of segments from the esophagus to the rectum, hence are sub-grouped as eosinophilic esophagitis (EE), eosinophilic gastroenteritis (EG), and eosinophilic colitis (EC). The least frequent manifestation of EGIDs is EC, with an estimated prevalence of 3.3 in 100,000 [1-3].

Corresponding Author:-Ahmed Mead

Address:-Faculty of Medicine, Department of Basic Medical Science, Salaam University,
Mogadishu, Somalia.

EC is a heterogeneous entity with a bimodal age distribution and no gender preference that primarily affects newborns appearing as either acute self-limited bloody diarrhea or to a lesser extent affects young adults as chronic relapsing colitis. Most studies indicate that EC is usually a non-IgE-associated disease, where some point to a Th2-mediated intestinal allergic disorder involving CD4(+) Th2 lymphocytes. However, other studies also indicate that IgE is responsible for mast cells accumulating in the colonic interstitium. Although the exact etiology of EC is unclear, important genetic and allergic factors have been recognized as key contributors. Around 16% of patients have a family relative with a similar disorder, whereas 80% report having atopic disease, and up to 62% have specific food sensitivities [1, 4, 5].

EC can present primarily as a separate condition or can present as a secondary manifestation of other diseases affecting the gastrointestinal tract. EC can cause a wide range of symptoms, depending on the extent and location of tissue involvement. Abdominal pain, bloody or non-bloody diarrhea, nausea/vomiting, and weight loss are the most typical symptoms. Other atopic disorders can be associated with primary EC. As shown (Table 1), Colonic eosinophilia can result secondary to helminthic infections, IBD, autoimmune diseases like scleroderma and Churg–Strauss syndrome, celiac disease, drug reactions, and in association with the hypereosinophilic syndrome (HES) [3, 4].

Table 1:- Classification of EGID [1].

Primary EGID		Secondary gut eosinophilia
Primary Esophagitis (EE)	Eosinophilic	Reflux esophagitis
Primary Gastroenteritis (EG)	Eosinophilic	Infections: Protozoal and other pathogens Drugs: naproxen, clozapine, rifampicin, enalapril, carbamazepine, gold, interferons tacrolimus
Primary Eosinophilic Colitis (EC)		Systemic disease: <ul style="list-style-type: none"> • HES (Hypereosinophilic Syndrome) • Connective tissue disease/vasculitis • Graft-versus-host disease • Gastroesophageal reflux disease • Helicobacter pylori gastritis • Celiac disease • Inflammatory bowel disease • Neoplasia • Transplantation
Food hypersensitivity/allergy	<ul style="list-style-type: none"> • IgE-mediated • Non-IgE 	Iatrogenic
Food protein-induced proctocolitis in infancy		

Symptoms presented by a patient with EC depend on the layer of the colon that is compromised. The most common type of EC, mucosa predominant EC is associated with mucosal injury and presents with abdominal pain, malabsorption, diarrhea, and protein-losing enteropathy. Transmural disease, which is less common, is characterized by thickening of the colonic wall and symptoms of acute intestinal blockage (intussusception or cecal volvulus), motility difficulties, or even perforation. Serosal disease, an extremely rare form with a favorable prognosis, presents with ascites in which eosinophils are the predominant cell type in up to 95% of cases. There are no distinct clinical signs or symptoms that distinguish the isolated colonic disease from more diffuse involvement that also affects the stomach and/or small intestine [1, 5, 6].

The pathophysiology of primary EC seems to be related to altered hypersensitivity, most notably as a food allergy in infants and T lymphocyte-mediated in young adults. Symptoms in adults include diarrhea, abdominal pain, and loss of weight. Endoscopic changes are modest, featuring edema and patchy granularity. Despite the lack of standardized criteria, the diagnosis of EC is based on histopathology, which identifies an excess of eosinophils. Currently, the histologic evaluation of EC is solely focused on the number of mucosal eosinophils [3, 4].

Histological findings of mast cell accumulations and loss of granular pattern in children's colonic mucosa suggest that IgE plays a predominant role in EC in children. Whereas, in adults, atypical anaphylaxis related to a specific diet implies the presence of a CD4(+) Th2 lymphocyte-mediated pathway. Sheets of eosinophils infiltrating the lamina propria and extending through the muscularis mucosa into the submucosa are typical findings in colonic mucosal biopsies (Figure 1) [3, 5].

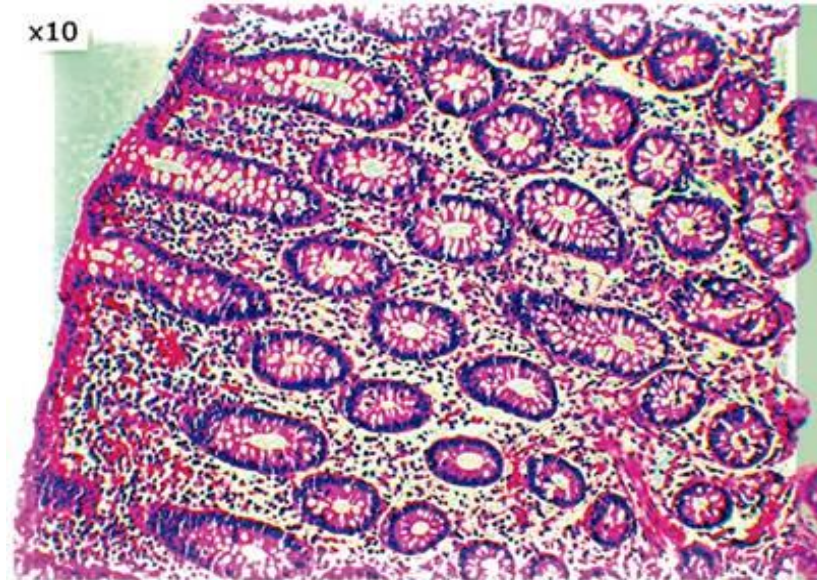


Figure 1:- Eosinophilic infiltration of the lamina propria [5].

Diagnosis

The presence of gastrointestinal symptoms, peripheral eosinophilia, endoscopic and histological findings, and eosinophilic ascites, with no well-defined causes of eosinophilia on a thorough evaluation, contributes to the diagnosis of EC. Normal tissue eosinophil counts differ significantly between segments of the colon, ranging from 10 eosinophils per high-power field (HPF) in the rectum to > 30 in the cecum; hence, the site of the biopsy is critical for the interpretation of findings. A diagnosis of EC is made when colonic eosinophilia is greater than 20 eosinophils per HPF based on clinical context and after exclusion of other causes of colonic eosinophilia. No consensus exists for EC's diagnostic threshold of eosinophils, although it is what is being used by most authors [2].

Diagnosis of primary EC is based on multiple colonic biopsies, which is especially difficult in the absence of diagnostic criteria. EC and IBD can coexist, and one disease may become more dominant or clearer over time. Laboratory testing can reveal anemia and hypoalbuminemia as a result of gastrointestinal losses but does not typically show signs of peripheral inflammation such as elevated sedimentation rate or C-reactive protein. Radiological findings may include strictures, thickening of the bowel wall and mucosal folds, a rigid ileocecal valve open to reflux, and ulcerative or polypoid lesions, depending on the region and layer affected. At colonoscopy, some patients have lymph nodular hyperplasia while others have endoscopic features of mild colitis including mucosal edema, patchy erythema, and loss of vascularity. Changes can occur anywhere in the colon but tend to be more prominent in the ascending colon and rectum [1, 4, 6].

Differential Diagnosis

EC has a broad differential diagnosis and is a diagnosis of exclusion. Thus, many other potential causes of an eosinophilic response must be ruled out before making a diagnosis of primary or idiopathic EC. Colon tissue eosinophilia often occurs in parasitic infection, drug-induced allergic reactions, IBD, and various connective tissue disorders, which require thorough searching for secondary causes [2, 7].

Colonic eosinophilia has been described in association with pinworms, roundworms, and whipworms. Helminth larvae are not always visible in histological sections, so the pathologist must be aware of the endoscopic findings as well as any relevant travel history. Stool examination or specific serology may be performed if parasitic etiology is suspected [8-10].

Nonsteroidal anti-inflammatory drugs, tacrolimus, carbamazepine, rifampicin, and naproxen have all been reported to cause colonic eosinophilia. Because EC is uncommon, establishing a causal link with specific drug therapy can be difficult. Thus, special attention should be paid to the temporal relationship between drug administration and symptoms, in addition, colonic eosinophilia should not be attributed to a drug reaction without adequate clinicopathological correlation [11-15].

EC has also been associated with autoimmune connective tissue disease including scleroderma, dermatomyositis, and polymyositis, as well as with allogeneic bone marrow transplantation. EC is also well described after liver transplantation in children [2, 16-20].

Patients with EC can have peripheral eosinophilia, and there is a statistically significant correlation between colonic eosinophil density and total serum IgE levels. Gut eosinophilias are thought to be mediated by IgE via the high-affinity receptor FcεRI [7, 21, 22].

There is a risk of misdiagnosing early or inactive IBD as EC since tissue eosinophils are raised in many chronic inflammatory conditions. In EC, unlike in quiescent IBD, the architecture of the colonic crypts is normally preserved. According to a study, children with IBD have a higher total colonic eosinophil density than children with food allergies, suggesting that diagnosing EC in the presence of IBD may be difficult [23-25].

Treatment

Treatment for primary EC is based solely on case reports and expert opinion. There are no treatment guidelines for primary eosinophilia. Treatment is usually dictated by the severity and persistence of symptoms [26].

In the treatment of EC, steroid-based medication and diet modification produce very good and long-lasting results, similar to other eosinophilic gastrointestinal illnesses. EC in infants is a relatively benign, often food-related condition, and removing the aggressor from the diet often resolves the problem within days. Patients who are adolescents or older require medical management such as glucocorticoids, antihistamines, leukotriene receptor antagonists as well as novel approaches employing biologics that target interleukin-5 (IL-5) and IgE [3, 6].

Corticosteroids are the mainstay for initial management and have proven to be effective for symptom control in EC. The ability of corticosteroids to treat eosinophilic diseases is mostly mediated by their ability to block eosinophil growth factors such as IL-3, IL-5, and GM-CSF. At a dose of 20–40 mg daily, the majority of cases will improve within two weeks of treatment even though other studies have also mentioned doses of more than 0.5-1 mg/kg/day. Relapse is common, and requires recurrent courses, which can result in steroid dependence. Treatment options for EC are currently limited to systemic or topical corticosteroids as well as anti-inflammatory medications such as aminosalicylates. EC mainly affects the proximal colon, even though several types of topical corticosteroids are designed to deliver drugs to the distal colon and rectum. In severe cases or patients' refractory to or dependent on systemic corticosteroid therapy, there are options including immunosuppressive antimetabolite therapy with azathioprine or 6-mercaptopurine. Clinical evidence suggests that eosinophilia that extends past the esophagus is less likely to respond to elimination diets. When it comes to dietary manipulation, an elemental diet is the most effective [3, 4, 6, 26].

Operative treatment is only indicated for the complications of EC such as obstruction, volvulus, intussusception, and perforation. Segmental anatomic colonic resection is recommended, while there is no clear consensus or evidence to support primary anastomosis or diversion [6].

Prognosis

Prognosis is highly determined by the age of onset of the disease, with a good prognosis in infancy and a somewhat more chronic relapsing and remitting course in adults. EC presenting in the first year of life has a very good prognosis, with the vast majority of patients being able to tolerate the causative food by 1–3 years of age. An association between allergic colitis and the later development of IBD has been reported, but it remains controversial [1, 5].

EC in adults is considered a chronic disorder with periods of activity and remission. Long-term follow-ups have revealed that up to 30% of patients experience spontaneous remissions, 60% respond to steroids or diet, and 10% have refractory disease. The prognosis for EC that develops later in life is less favorable. Since EC is frequently a

manifestation of other disease processes, routine cardiopulmonary surveillance, as well as upper and lower gastrointestinal endoscopy, are recommended [5, 27]. We report a case of EC in a male patient who was an 18-years-old and treated satisfactorily with corticosteroids. Our report aims to increase doctors' awareness of EC patients who frequently experience epigastric discomfort, abdominal distension, vomiting, and bloody diarrhea and who need corticosteroid treatment. Thus EC should be included in the differential diagnosis of these symptoms when there are no evident causes that point to it.

Case Report

An 18-year-old male patient complaining of recurrent epigastric and lower abdominal pain, abdominal distension, vomiting, bloody diarrhea, and weight loss for a long time went to Kalkaal Hospital, Department of Internal Medicine. The patient had no skin rash and known history of drug and food allergies. No aggravating or relieving factors were reported. There was no similar condition in the patient's family history.

On physical examination, the patient looked pallor, with abdominal distension, right iliac tenderness with normal bowel sounds, and blood pressure (BP) was 90/60. Laboratory investigations performed showed a white blood cell (WBC) count of $14.5 \times 10^9/L$, with 62.1% neutrophils, 22.4% lymphocytes, 13.2% monocytes, 28.2% eosinophils, 0.1% basophils, RBC $5.44 \times 10^{12}/L$, and hemoglobin (HGB) level of 6.3 g/dL. C-reactive protein (CRP), urea, creatinine, uric acid, syphilis test, HIV, HBsAg, HCV, Widal test IgM and IgG showed no abnormalities. Stool examination was positive in the helicobacter pylori test (stool AG) and occult blood and negative in mucus, RBC, and pus cells. The coagulation examination (APTT, PT, and INR) was normal.

Real-time abdominal ultrasonography scanning revealed normal liver, gall bladder, spleen, pancreas, and kidneys with no ascites. Colonoscopy of the rectum showed edematous, erythema, mucosal friability, and erosions noted in the rectal area (Figure 2). The rest of the colon was normal. A colonoscopic biopsy was done. Macroscopically the colonoscopic biopsy showed to consist of multiple soft tiny tan-grayish pieces of tissue measuring in aggregate 0.6x0.6 cm (Figure 3). Microscopically the colonoscopic biopsy showed active colitis with eosinophilia. There was no evidence of granuloma formation, cryptitis, or crypt abscess. There was no dysplasia and malignancy within the limits of the specimen (Figure 4).

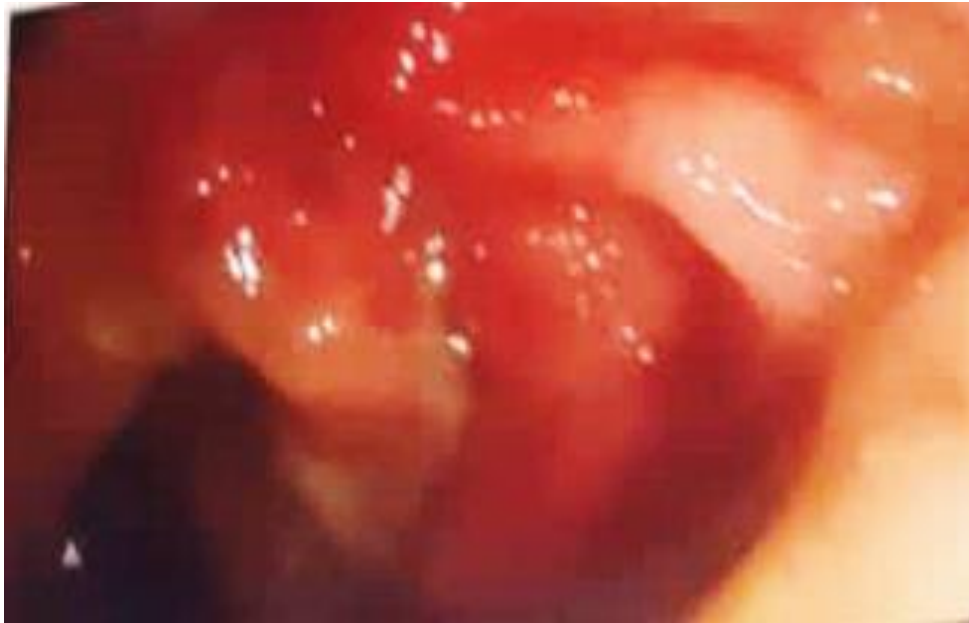

Figure 2:- Colonoscopy of the rectum showed edematous, erythema, mucosal friability, and erosions noted in the rectal area.

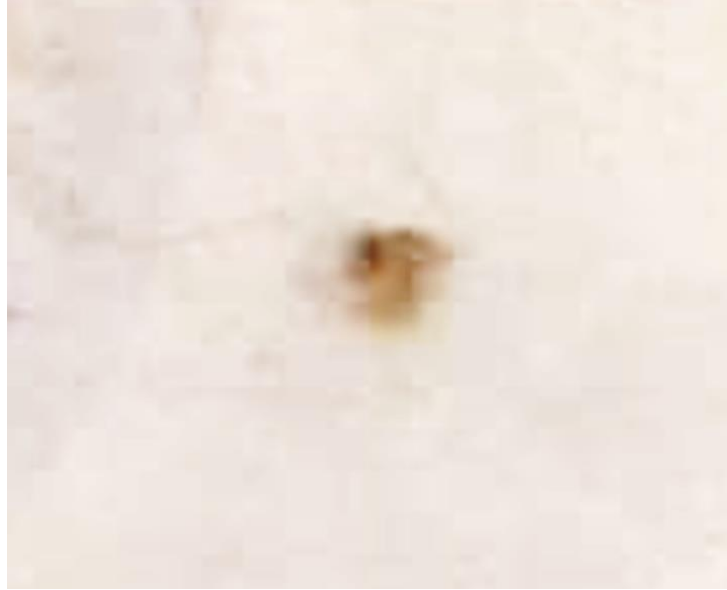

Figure 3:- Colonoscopic biopsy macroscopically showed to consist of multiple soft tiny tan-grayish pieces of tissue measuring in aggregate 0.6x0.6 cm.

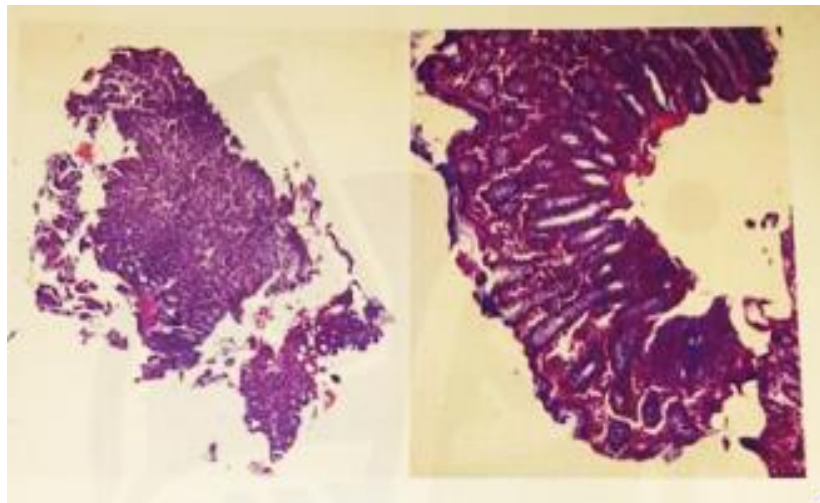


Figure 4:- Colonoscopic biopsy microscopically showed active colitis with eosinophilia.

The patient was admitted and diagnosed with EC and treated with Ringer's lactate 500 ml 2 times per day, metronidazole solution 400 mg 3 times per day, pantoprazole injection 40 mg 2 times per day, metoclopramide injection 10 mg 3 times per day, ceftriaxone injection 1g 2 times per day, ciprofloxacin solution 200 mg 2 times per day, 3 unit of blood transfusion. On discharge, prednisolone tab 20 mg 2 times per day for 4 weeks was prescribed, and then prednisolone was gradually reduced for 8 weeks. Other medications prescribed on discharge include montelukast/levocetirizine 10/5 mg tab once per day for 8 weeks, pantoprazole tab 40 mg for one month, and ciprofloxacin tab 500 mg 2 times per day for 7 days. After 2 weeks of treatment, the patient improved.

Discussion:-

EC is extremely rare, with only a few cases reported since 1979. The lack of clear histological criteria for a specific eosinophil count in the mucosa of the colon renders it difficult to diagnose. As a result, its accurate frequency is unknown. Abdominal pain, bloody or non-bloody diarrhea, and weight loss are common clinical manifestations. In infants, the clinical manifestations and pathophysiology are mild, self-limited, and much more food-related, whereas, in young adults, they are chronic. The predominant eosinophil infiltration of the colonic layer determines the mode of the manifestation, particularly in adults. Colonic biopsies are used to diagnose EC and are difficult

without diagnostic criteria and require the exclusion of secondary causes [28]. EC is diagnosed with peripheral eosinophilia, endoscopic and histopathological findings, and gastrointestinal symptoms [26]. In our case, we diagnosed the patient with EC. Our patient met the criteria for diagnosis based on peripheral eosinophilia, histopathological findings of eosinophilia in the colon, and clinical manifestations such as recurrent epigastric pain, abdominal distension, vomiting, and bloody diarrhea for a long time.

The treatment strategies of EC are currently based on case reports [26, 28]. Corticosteroids are the initial treatment and the most effective approach for symptomatic relief in EC [2]. Corticosteroids also delay and control organ impairment and can be used as initial treatment in patients with HES [29]. Corticosteroids are the treatment of choice for the remission of EC cases. Prednisolone is the most common corticosteroid treatment tapered gradually over 6-8 weeks [30]. In addition to corticosteroids, other treatments include dietary treatment, leukotriene receptor antagonists such as montelukast, antihistamines, mast cell stabilizers such as ketotifen, and sodium cromoglicate, IL-4 inhibitors, and biological substances such as omalizumab and mepolizumab [26]. We recommended corticosteroid treatment to the patient. With prednisolone treatment of 20 mg 2 times per day, the clinical features resolved. Despite stopping corticosteroids for six months, the patient experienced clinical relief without recurrence.

Conclusion:-

EC is the least frequent manifestation of EGIDs that affects newborns and young adults of both sexes, characterized by predominant eosinophil infiltration of the colon. Therefore EC should be considered for patients with elevated peripheral blood eosinophil counts and clinical manifestations. These highlight the importance of including EC in the differential diagnosis of EGID. The physician's awareness of the disease is essential for making a prompt and accurate diagnosis. EC is diagnosed with gastrointestinal symptoms, peripheral eosinophilia, endoscopic and histopathological findings, and exclusion of other causes. Corticosteroids are the primary treatment for EC patients. With prednisolone treatment, the clinical features of our patient resolved without recurrence.

Acknowledgments:-

The authors thank the patient for permitting the publication of the data regarding his case.

Conflict of Interests

The authors declare no conflict of interest.

References:-

1. Alfadda, A.A., M.A. Storr, and E.A. Shaffer, Eosinophilic colitis: an update on pathophysiology and treatment. *British Medical Bulletin*, 2011. 100(1): p. 59-72.
2. Okpara, N., B. Aswad, and G. Baffy, Eosinophilic colitis. *World journal of gastroenterology*, 2009. 15(24): p. 2975-2979.
3. Alfadda, A.A., M.A. Storr, and E.A. Shaffer, Eosinophilic colitis: epidemiology, clinical features, and current management. *Therapeutic advances in gastroenterology*, 2011. 4(5): p. 301-309.
4. Burks., A.W., et al., *Middleton's Allergy: Principles and Practice*. 2020.
5. Prieto O, R.G. and J.E. Prieto O, Colitis eosinofílica, un diagnóstico poco sospechado %J *Revista colombiana de Gastroenterología*. 2020. 35: p. 87-91.
6. Gaertner, W.B., et al., Eosinophilic Colitis: University of Minnesota Experience and Literature Review. *Gastroenterology Research and Practice*, 2011. 2011: p. 857508.
7. Bates, A.W.H., Diagnosing Eosinophilic Colitis: Histopathological Pattern or Nosological Entity? *Scientifica*, 2012. 2012: p. 682576.
8. Cacopardo, B., et al., Eosinophilic ileocolitis by *Enterobius vermicularis*: a description of two rare cases. 1997. 29(1): p. 51-53.
9. Al Samman, M., S. Haque, and J.D.J.J.o.c.g. Long, Strongyloidiasis colitis: a case report and review of the literature. 1999. 28(1): p. 77-80.
10. Chandrasekhara, V., S. Arslanlar, and J.J.G.e. Sreenarasimhaiah, Whipworm infection resulting in eosinophilic colitis with occult intestinal bleeding. 2007. 65(4): p. 709-710.
11. Hurrell, J.M., R.M. Genta, and S.D.J.A.i.a.p. Melton, Histopathologic diagnosis of eosinophilic conditions in the gastrointestinal tract. 2011. 18(5): p. 335-348.
12. Bridges, A.J., J.B. Marshall, and A.A.J.T.A.j.o.m. Diaz-Arias, Acute eosinophilic colitis and hypersensitivity reaction associated with naproxen therapy. 1990. 89(4): p. 526-527.

13. Saeed, S.A., et al., Tacrolimus-associated eosinophilic gastroenterocolitis in pediatric liver transplant recipients: Role of potential food allergies in pathogenesis. 2006. 10(6): p. 730-735.
14. Anttila, V.J. and M.J.E. Valtonen, Carbamazepine-induced eosinophilic colitis. 1992. 33(1): p. 119-121.
15. Lange, P., et al., Eosinophilic colitis due to rifampicin. 1994. 344(8932): p. 1296-1297.
16. Sunkureddi, P.R., et al., Eosinophilic enteritis with systemic lupus erythematosus. 2005. 98(10): p. 1049-1053.
17. Clouse, R.E., et al., Pericrypt eosinophilic enterocolitis and chronic diarrhea. 1992. 103(1): p. 168-176.
18. Barbie, D.A., A.A. Mangi, and G.Y.J.J.o.C.G. Lauwers, Eosinophilic gastroenteritis associated with systemic lupus erythematosus. 2004. 38(10): p. 883-886.
19. Ahmad, M., R.M. Soetikno, and A.J.J.o.c.g. Ahmed, The differential diagnosis of eosinophilic esophagitis. 2000. 30(3): p. 242-244.
20. Ashida, T., et al., Eosinophilic colitis in a patient with acute myeloid leukemia after allogeneic bone marrow transplantation. 2003. 78(1): p. 76-78.
21. Dehlink, E., E.J.I. Fiebiger, and a.c.o.N. America, The role of the high-affinity IgE receptor, FcεRI, in eosinophilic gastrointestinal diseases. 2009. 29(1): p. 159-170.
22. Behjati, S., et al., Defining eosinophilic colitis in children: insights from a retrospective case series. 2009. 49(2): p. 208-215.
23. Uzunismail, H., et al., Dense eosinophilic infiltration of the mucosa preceding ulcerative colitis and mimicking eosinophilic colitis: report of two cases. 2006. 17(1): p. 53-57.
24. Pensabene, L., et al., Evaluation of mucosal eosinophils in the pediatric colon. 2005. 50(2): p. 221-229.
25. Choy, M.-Y., et al., Activated eosinophils in chronic inflammatory bowel disease. 1990. 336(8707): p. 126-127.
26. Tuong., T.T.K., A Rare Case Report of Primary Eosinophilic Colitis. Biomedical Journal of Scientific & Technical Research, 2020. Volume 26: p. 19921-19923.
27. Zuo, L. and M.E. Rothenberg, 46 - Eosinophil-associated gastrointestinal disorders (EGID), in Clinical Immunology (Third Edition), R.R. Rich, et al., Editors. 2008, Mosby: Edinburgh. p. 691-699.
28. Alfadda, A.A., M.A. Storr, and E.A. Shaffer, Eosinophilic colitis: epidemiology, clinical features, and current management. Therap Adv Gastroenterol, 2011. 4(5): p. 301-9.
29. Stella, S., et al., Molecular Pathogenesis and Treatment Perspectives for Hypereosinophilia and Hypereosinophilic Syndromes. Int J Mol Sci, 2021. 22(2).
30. Bouchrit, S., et al., Unusual cause of acute abdominal pain: Eosinophilic colitis case report and review of the literature. Archives of Clinical Gastroenterology, 2021: p. 015-017.