

# Breast Involvement in Tuberculosis and Comparison with the Literature

Ayoub Amghar, Sara Tossi, Houssin Bouffetal, Skher Mahdaoui, Samouh Naima  
Department of Gynecology, IBN Rochd hospital, CHU Casablanca

**Abstract:-** Mammary tuberculosis is a very rare pathology. It poses a problem of differential diagnosis with breast cancer since the clinical and imaging findings are not specific. Mammary tuberculosis should be considered especially in endemic countries such as Morocco. We report a case of breast tuberculosis in a young woman to raise the problem of diagnosis that it raises.

## I. INTRODUCTION

Mammary tuberculosis is one of the rare extrapulmonary localizations of tuberculosis. It is a paucibacillary form characterized by a clinical and radiological polymorphism. We report a case of breast tuberculosis to raise the issue of differential diagnosis of breast tuberculosis with breast cancer.

## II. CASE REPORT

This is a 36 year old patient with no particular pathological history, who presented with mastodynia of the left breast associated with a 2 cm nodule of the superior internal quadrant mobile in relation to the two planes, fistulated to the skin with pus emission in some places, without inflammatory signs or nipple discharge, all evolving in a context of alteration of the general state with notion of loss of 4 Kg, the examination of the lymph nodes objectifying a left adenopathy of 2 cm.

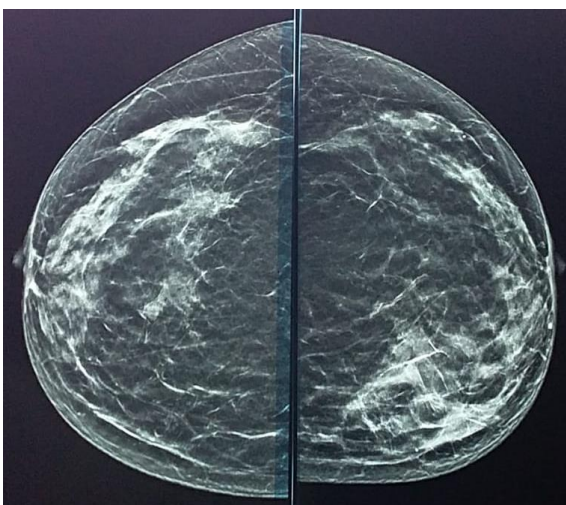


Fig 1: Mammogram of the patient

On echomammography: appearance of galactophore involvement by heterogeneous tissue proliferation accompanied by an axillary adenopathy. This appearance is highly suspicious and classified as ACR 4.

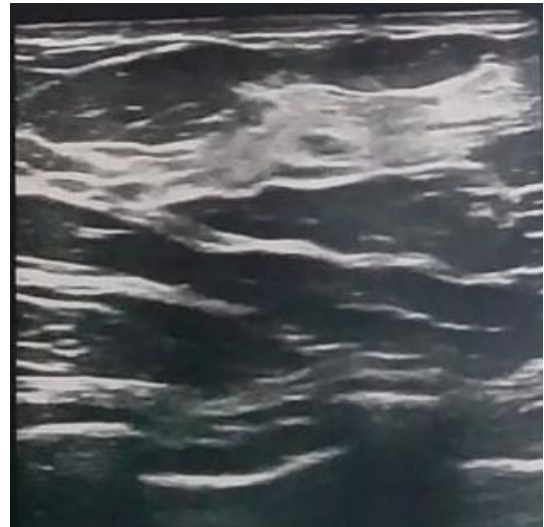

Fig 2: Breast ultrasound

The biopsy was performed with the trucut and showed a tuberculoid granulomatous mastitis without necrosis and without signs of malignancy.

An ELISA study by Quantiferon-TB Gold Plus was positive.

## III. DISCUSSION

Mammary tuberculosis is a very rare form of tuberculosis. Its frequency varies from 0.06% to 0.1% of tuberculosis cases [1,2]. The rarity of this clinical form could be explained by the fact that the breast tissue seems to be not very favorable to the survival and multiplication of the tubercle bacillus [3]. It mainly affects young women [4]. Pregnancy, lactation and multiparity are risk factors [5], which can be explained by the fact that galactophoric ectasia occurs during lactation. The routes of contamination are diverse [2]: the lymphatic route or an axillary adenopathy is often found; the hematogenous route, in the context of a tubercular millennium; spread by contiguity from a neighborhood focus; the ductal route: the dilation of the galactophoric ducts in women during pregnancy or lactation increases the sensitivity of these ducts to infection by bacilli; The direct route: exceptional, it is the penetration of Koch's bacillus into the breast following a skin or galactophoric abrasion. Classically, two types of mammary tuberculosis are distinguished: secondary with involvement of other organs and primary where the tuberculosis appears to be strictly localized to the breast, the latter being the most frequent [3,6]. In our patient, the involvement was primary. Clinically, breast tuberculosis is characterized by the absence of specific clinical signs [5], it presents either as a nodular mass or an inflammatory mass mimicking breast cancer. However,

certain clinical criteria point to tuberculosis [2]: the existence of recurrent abscesses that are resistant to antibiotics; the existence of fistulated axillary adenopathies and a breast fistula with nipple discharge. Radiologically, there are no specific mammographic signs of mammary tuberculosis [7,8]. Mammography may show irregular heterogeneous opacities, poorly limited with occasional calcifications, pointing to a malignant etiology. On ultrasonography, breast tuberculosis often appears as a hypoechoic, heterogeneous, well or poorly limited image with minimal posterior enhancement [8]. The diagnosis of certainty is based on histological examination [9] with the demonstration of epithelioid and gigante-cellular granuloma with caseous necrosis. The main differential diagnosis to be feared in breast tuberculosis is breast cancer, but other pathologies should be discussed, such as breast abscess, fibroadenoma, sarcoidosis and granulomatous mastitis. In our observation, in front of an inflammatory breast in an elderly and postmenopausal woman, the first diagnosis to be evoked is essentially breast cancer and only the histological examination which allowed the diagnosis of breast tuberculosis.

The therapeutic management of breast tuberculosis is based on antibacillary drugs, with possible percutaneous drainage of a breast abscess, which was not the case in our patient. Surgery (mastectomy) may be proposed in case of resistance to medical treatment [5].

#### IV. PATHOGENESIS

Classically, two types of breast tuberculosis are distinguished:

- Primary breast tuberculosis. This is the form where the tuberculosis appears to be strictly localized to the breast. It is clearly the most frequent type of tuberculosis [10], [11] and represents 60% of cases [12]. In our series, breast involvement appears to be primary in 97% of cases. However, this opinion is controversial, and some authors think that other tuberculous foci, mainly pulmonary scarring and intercostal lymph nodes, are in fact undetected [13], and that this primary form is rather extremely rare, reserved for cases of direct inoculation [14];
- secondary mammary tuberculosis. This is the form where there is involvement of other organs. This secondary form seems to be much less frequent than the primary form [18]. In our series, mammary tuberculosis was secondary in two patients (3%); once to left supraclavicular lymph node tuberculosis and once to progressive pulmonary tuberculosis.
- Five routes of tuberculosis contamination of the breast are distinguished:
- the hematogenous route. This route is rarely described [15]. The location of the lesions is not determined by the position of the vessels, but rather by the structure of the mammary gland. It has a lobular and ductal distribution as in the lung [18];
- the lymphatic route. Dissemination of Koch's bacillus occurs by retrograde or anterograde route from intrathoracic, cervical, supra-clavicular or axillary

adenopathies [16]. This hypothesis is based on the possibility of association of axillary adenopathy and tuberculous mastitis;

- the ductal route. This route of contamination is very rarely observed [17]. The dilation of the galactophore ducts in women during pregnancy and lactation, as well as the locoregional circulatory changes during this period, would increase the sensitivity of these ducts to infection, particularly by Koch's bacillus;
- by contiguity. This is the dissemination of Koch's bacillus from a tuberculous focus affecting a rib, the sternum, a cartilaginous focus, the sternocostal junction, the lung, the pleura, the chest wall or from an intra-abdominal focus;
- the direct route. This is a very rare, even exceptional, route of contamination [18]. It is the transcutaneous penetration of the bacillus into the breast following a cutaneous or galactophoric abrasion.

#### V. CLINICAL STUDY

Breast tuberculosis is characterized by the absence of specific clinical signs. Diagnosis remains difficult because it may mimic a large number of much more common conditions, particularly in older women where breast cancer remains the primary concern. Indeed, the pseudoneoplastic aspects revealed in the literature [19], illustrate well this difficulty. [21], [22], [23]

However, some clinical criteria seem useful to draw attention to a tuberculous etiology, namely:

- the existence of a recurrent breast abscess with a torpid evolution after standard antibiotic therapy and correct surgical drainage [23];
- fistulized axillary adenopathy associated with a breast nodule [20];
- rarely, a breast fistula with intermittent discharge according to the menstrual cycle [24].

#### VI. CONCLUSION

Mammary tuberculosis is a rare condition, even in endemic countries, and poses a problem of clinical and radiological diagnosis, particularly with breast cancer, hence the interest of a histological comparison.

#### REFERENCES

- [1]. Agoda-Koussema LK, Djibril AM, Adjenou KV et al. Breast tuberculosis: a case report. *African Journal of Medical Imaging*. 2014; 6(3).
- [2]. Ben Hassouna J, Gamoudi A, Bouzaïene H et al. Breast tuberculosis: a retrospective study of 65 cases. *Gynecology Obstetrics and Fertility*. 2005; 33(11): 870-6.
- [3]. Marinopoulos Spyridon, Lourantou Dionysia, Gatzionis Thomas et al. Breast tuberculosis: diagnosis, management and treatment. *International journal of surgery case reports*. 2012; 3(11): 548-550. PubMed | Google Scholar

- [4]. Boukadoum Nassim, Kaidi Chahine Hichem, Yassi Fatiha, et al. Tuberculous mastitis: a diagnosis not to be ignored. *Imagerie de la Femme*. 2012; 22(4): 221-223.
- [5]. Hawilo A, Abdelmalek R, Mebazaa A, et al. Tuberculosis of the breast: a rare, often unrecognized diagnosis. *Tropical Medicine and Health*. 2012; 22(3): 292-296.
- [6]. Gulpinar Kamil, Ozis S Erpulat, Ozdemir Suleyman et al. Primary breast tuberculosis : Report of a case. *Science chirurgicale*. 2013 ; 4 : 68-71. Google Scholar
- [7]. Morsad F, Ghazli M, Boumzgou K, Abbassi H, El Kerroumi M, Matar N, Belabidia B, Aderdour M, El Mansouri A. Tuberculose mammaire : à propos de 14 cas. *J Gynecol Obstet Biol Reprod*. 2000 ; 30(4) : 331-33.
- [8]. Filippou Dimitrios C, Rizos Spiros et Nissiotis, Athanasios. Primary breast tuberculosis : a case report. *Radiologie et oncologie*. 2003 ; 37(1).
- [9]. Mirsaedi SM, Masjedi MR, Mansouri SD, Velayati AA. Tuberculosis of the breast : report of 4 clinical cases and literature review. *Eas Mediter Health J*. 2007 ; 13(3):670- 6. PubMed | Google Scholar
- [10]. T.T. Alagaratnam, J. Wong Troubles bénins du sein dans les populations non-westem : Partie I - Troubles bénins du sein chez la femme chinoise. *World J. Surg.*, 13 (1989), pp. 743-745.
- [11]. A. Gamoudi, K. Farhat, R. Khatteeh, et al. La tuberculose mammaire. À propos de 58 cas *Gynecologie*, 8 (1995), pp. 413-418
- [12]. S.N. Banerjee, N. Ananthakrishnan, R.B. Mehta, et al. La mastite tuberculeuse : un problème persistant. *World J. Surg.*, 11 (1987), pp. 105-109
- [13]. A. El Mansouri, M. Moumen, S. Louahlia Tuberculose mammaire : à propos de trois cas *Sem. Hop. Paris*, 69 (1993), pp. 1277-1279
- [14]. J.P. Wilson, S.W. Chapman La mastite tuberculeuse *Chest*, 98 (1990), pp. 1505-1509
- [15]. R. Pieron, A. Gessain, M. Grivaux Un cas de tuberculose mammaire chez une africaine *Sem. Hop. Paris*, 61 (1985), pp. 2373-2376
- [16]. S. Najah, C. Birkowska La tuberculose mammaire *Tunis. Med*. 53 (1975), pp. 197-198
- [17]. P. Seffert, P. Berard, M. Papillon La tuberculose mammaire. *Revue de la littérature à propos d'un cas personnel. J. Gynecol. Obstet. Biol. Reprod. (Paris)*, 8 (1979), pp. 521-525
- [18]. L. Geffray, X. Moreau, J. Abgrall, et al. La mastite tuberculeuse pseudonéoplasique *Concours Med*, 107 (1985), pp. 4377-4380
- [19]. AmirH Tuberculose du sein se présentant comme un carcinome mammaire. *Cent. Afr. J. Med.*, 37 (1991), pp. 53-56
- [20]. D.M. Dent, B.L. Webber Tuberculose du sein *S. Afr. Med. J.*, 51 (1977), pp. 611-614
- [21]. Ellouz R, Tabane F, Ben Attia R et al. Aspects pseudotumoraux de la tuberculose.
- [22]. P.M. Roy, P. Cornu, F. Lebas, et al. Une cause rare de tuméfaction pseudonéoplasique du sein : la tuberculose mammaire. *Rev. Med. Interne*, 17 (1996), pp. 173-175
- [23]. A. ouhal, M. Outifa, A. Filali, et al. Les tumeurs pseudonéoplasiques du sein : la tuberculose mammaire à propos de deux cas. *Méd. Maghreb*, 82 (2000), pp. 11-14
- [24]. J. Bishara, S. Calderon, E. Okon, et al. Coexistence d'une tuberculose extrapulmonaire et d'une tumeur maligne. *Am. J. Med.*, 105 (1998), pp. 443-446.