

**BJMHR**British Journal of Medical and Health Research
Journal home page: www.bjmhr.com

Acromegaly in Young.

Kshitij Kumat*, Dharmendra Vatsaraj, Siddharth Shah, Deepali Lodha*Department of Medicine, Smt.B. K Shah Medical Institute and Research Centre, Sumandeep Vidyapeeth, Vadodara-391760.*

ABSTRACT

Acromegaly is a rare, slowly progressive disease caused by chronic hypersecretion of growth hormone (GH) and excess circulating insulin-like growth factor-1 (IGF-1). The aetiology of acromegaly is almost invariably an underlying GH-secreting pituitary adenoma. Rarely, it is due to a hypothalamic tumour secreting GHRH or ectopic growth hormone releasing hormone (GHRH) secretion, or very rarely GH from an ectopic source¹. Acromegaly is rare with an estimated prevalence of 36–60 cases per million with an annual incidence of 3–4 per million.² We are here reporting a case of 21 yrs old female who presented with headache and amenorrhea since 1 year which on investigating patient had Acromegaly due to Pituitary Adenoma. Therapy for Acromegaly is targeted at decreasing GH and IGF-1 levels, ameliorating patients symptoms and decreasing any local compressive effects of the pituitary adenoma. The therapeutic options for acromegaly include surgery, medical therapies (dopamine agonists, somatostatin receptor agonists and the GH receptor antagonist) and radiotherapy. A multi disciplinary approach is recommended with often a requirement for combined treatment modalities. With disease control, associated morbidity and mortality can be reduced.

Keywords: Acromegaly in Young, Pituitary Adenoma.

*Corresponding Author Email: kshitijkumat18@gmail.com

Received 03 March 2022, Accepted 07 May 2022

Please cite this article as: Kumat K *et al.*, Acromegaly in Young. British Journal of Medical and Health Research 2022.

INTRODUCTION

Acromegaly results from the hypersecretion of growth hormone (GH), usually by a pituitary tumour³. The average age at diagnosis is 40 years, with an equal number of men and women affected. The disease is uncommon, although the exact prevalence is unclear; a recent review noted estimates of between 40 and 130 cases per million adults⁴. By comparison, in 2011, diabetes was estimated to affect 8.3% of adults (i.e, 83,000 cases/million) aged over 20 years worldwide⁵. A confirmed diagnosis of acromegaly commonly takes several years⁶, leading to potentially serious consequences for patients' health and well-being. These delays may be due partly to the fact that many of the clinical features of acromegaly are nonspecific and similar to those seen with other conditions more often seen in primary care, such as hypertension or diabetes. The delay may also be because of the insidious onset of differentiating symptoms, such as acral enlargement.

Acromegaly is a rare disorder caused by excessive growth hormone production (GH), most commonly from an adenoma of the anterior pituitary gland. The resulting production of insulin-like growth factor 1 (IGF-1) causes the characteristic overgrowth of certain tissues resulting in coarsening of facial features, enlarging hands and feet, as well as effects on multiple systems throughout the body, including cardiovascular, rheumatologic, neurologic, pulmonary, neoplastic, and metabolic.

The causes of acromegaly can be divided into primary GH excess, ectopic or iatrogenic GH excess, and excess growth hormone-releasing hormone (GHRH).

Acromegaly is most commonly caused by a somatotroph GH-secreting adenoma of the anterior pituitary gland. The most commonly associated mutation involves activating the alpha subunit of the guanine nucleotide stimulatory protein gene.

Other causes of primary GH excess include pituitary adenomas that secrete multiple hormones and GH-cell carcinomas. Important familial syndromes to be aware of that are associated with acromegaly include Multiple endocrine neoplasia type 1, familial acromegaly, McCune-Albright syndrome, and Carney complex.

GH excess can also be ectopic and produced by other tumours such as lymphoma and pancreatic-islet cell tumours. GH excess can also be iatrogenic, resulting from excessive GH administration.

Rarer causes of acromegaly are related to GHRH excess. These can be further divided into central and peripheral causes. Central causes include hypothalamic hamartomas, choristoma, and ganglioneuroma. Peripheral causes include secretion of GHRH by bronchial carcinoid tumors, small cell lung cancer, adrenal adenoma, and even production by some medullary thyroid cancer or pheochromocytoma.

CASE REPORT

A 21-year-old female patient not a k/c/o of any co-morbidity presented with complaints of headache and amenorrhoea since 1 year. Patient's UPT was done, which came to be negative. Headache was more in frontal region, continuous dull aching type, associated with blurring of vision. Patient also had changes in facial features (large jaw, frontal prominent ridges, thickened skin) and deep husky voice. Patient was vitally stable. Hence, patient was further investigated for the cause.

On further investigating, it was revealed that patient had raised prolactin levels. Rest all routine tests including TSH,T3,T4,FSH, LH were in normal range.

Suspecting features of Acromegaly patient was further investigated with MRI Brain Plain.

MRI Brain revealed-Well defined soft tissue intensify lesion in sellar and supra sellar region causing mild compression of optic chiasma. The lesion is abutting the cavernous segment of bilateral ICA. Possibility of Pituitary Macroadenoma appears likely.

Patient was then referred to Neurosurgery for further management with appropriate medical therapy.



Figure 1: Features of Acromegaly showing Prognathism, Prominent frontal ridges.



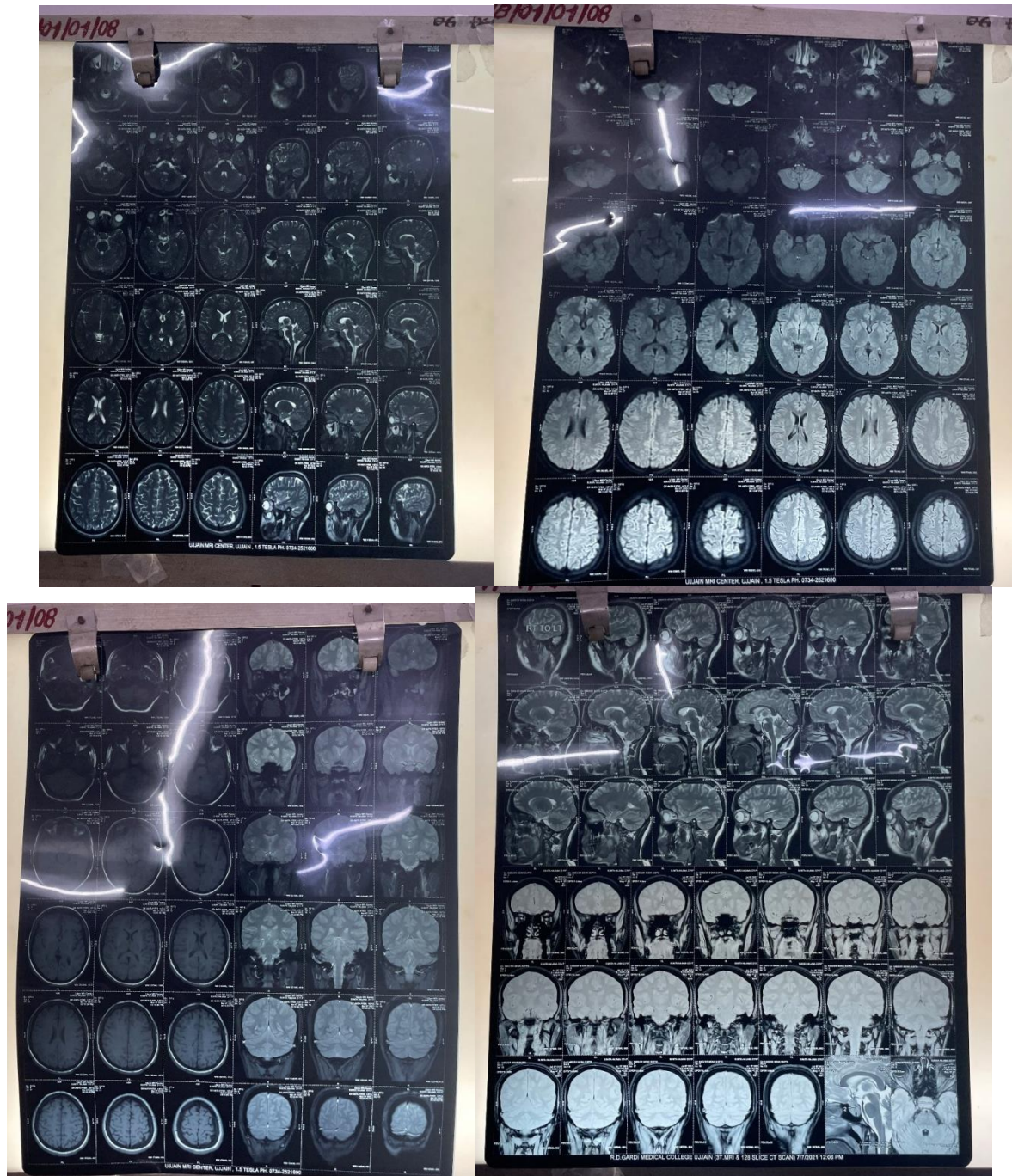Figure 2:Picture Suggestive Of Macroglossia



Figure 3:Large Hands In Acromegaly



Figure 4: Large Feet In Acromegaly



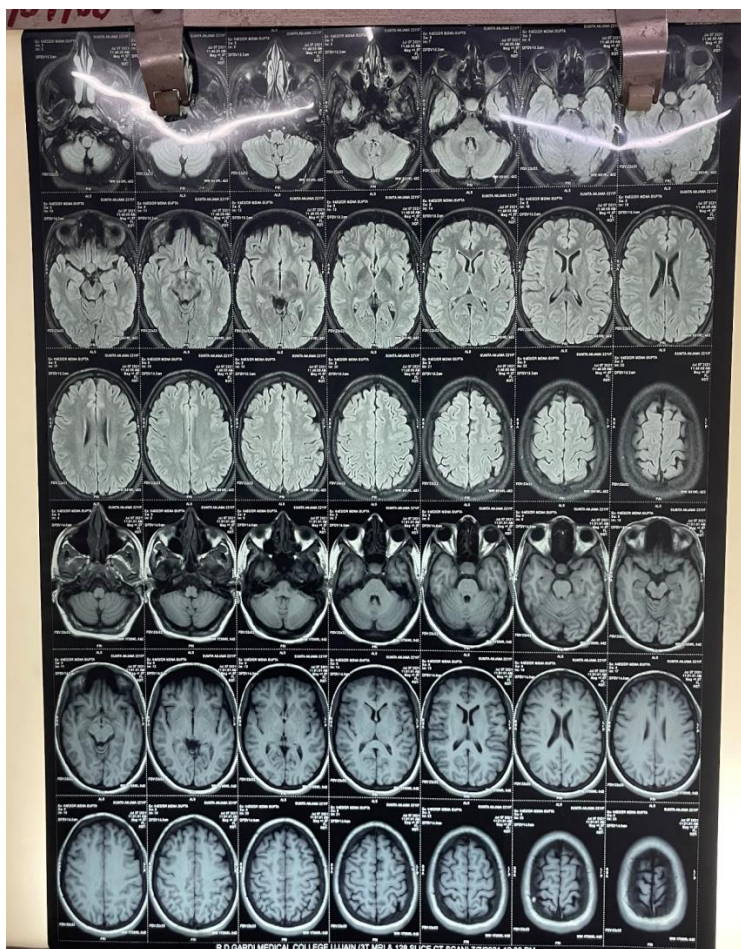


Figure 5: MRI Suggestive Of Pituitary Adenoma.

DISCUSSION

Pituitary tumor are monoclonal adenomas that account for ~10% of primary intracranial neoplasms⁷. GH is synthesized and stored in somatotroph cells, which account for >50% of pituitary hormone secreting cells⁸. GH production and secretion is regulated by hypothalamic GH-releasing hormone, ghrelin and somatostatin. IGF-1 inhibits GH secretion by both direct effect on the somatotrophs and indirectly through stimulation of somatostatin that inhibits GH secretion. GH is secreted in sporadic pulses with minimal basal secretion determined by sex, age, neurotransmitters, exercise and stress.

GH action is achieved via its interaction with a single-chain transmembrane glycoprotein receptor (GHR). The GH molecule interacts with a preformed dimer of identical GHR pairs, causing internalization of the receptor to initiate signalling. As a consequence, two Janus tyrosine kinase 2 molecules undergo autophosphorylation and in turn phosphorylate the GHR cytoplasmic domain. This activates intracellular proteins involved in signal transduction and transcription (STAT)⁹.

The gene encoding the GHR is ubiquitously expressed, particularly in liver, fat and muscle. GH activation of the intracellular molecule STAT5b induces transcription of IGF-1. Systemic IGF-1 is synthesized primarily in the liver but also in extrahepatic tissues including bone,

muscle and kidney and in the pituitary gland itself. IGF-1 circulates in serum bound to IGF-1 binding protein (IGFBP-3), or IGFBP-5, and acid-labile subunit in a 150-kD complex. Less than 1% of total serum IGF-1 circulates as a free hormone. The IGF-1 cellular effects are mediated by the IGF-1 receptor (IGF-1R), a heterotetrametric protein structurally similar to the insulin receptor. IGF-1 acts to mediate tissue growth or locally synthesized IGF-1 acts in a paracrine manner to regulate local GH target tissue growth¹⁰.

Several candidate genes that could account for the somatotroph clonal expansion have been examined in animal models. These include the retinoblastoma tumor suppression gene and p27. Disruption of the MENIN gene, results in multiple endocrine neoplasia type I. Ras mutations have been reported to activate GH secretion in experimental animal models, as have mutations of a pituitary tumor-transforming gene. Mutations in the tumor suppressor gene, aryl hydrocarbon receptor interacting protein (AIP), are prevalent in young-onset, GH excess patients and familial isolated and young-onset pituitary adenomas. In a longitudinal, international, collaborative study, Korbonits *et al*¹¹ identified AIP mutations in 46.7% of patients with gigantism in their cohort of 216 patients. Two histological subtypes of GH-secreting pituitary adenoma have been identified based on the pattern of cytoplasmic cytokeratin. Sparsely granulate cytokeratin at histology suggest more invasive lesions. These lesions are more common in younger patients and are less response to somatostatin receptor ligand therapy.¹²

The Acromegaly group consensus guidelines suggest that in a patient with persistent disease after surgery; repeat surgery may be an option if the tumor is accessible.¹³ The decision to initiate somatostatin therapy prior surgery remains controversial. In a prospective study of 30 patients with newly diagnosed acromegaly, reductions in GH and IGF-1 concentrations and tumor volume were observed following 24 weeks of preoperative lanreotide auto gel therapy.¹⁴ Further studies do not report any difference in the long-term results.¹⁵ Due to the lack of randomized controlled studies, the Acromegaly group consensus recommend against the routine use of preoperative somatostatin therapy. In certain circumstances, particularly for patients with severe soft tissue growth complicating anaesthetic risk or with significant comorbidities that may be improved by preoperative therapy, pre-treatment with somatostatin receptor ligands (SRL) may be considered¹⁶.

CONCLUSION

Prolonged exposure to elevated endogenous levels of GH and IGF-I results in a multisystem disease characterized by somatic overgrowth, multiple co-morbidities and premature mortality. Early detection prevents the development of irreversible complications of the disease, including cardiomyopathy, respiratory dysfunction, and arthropathy. Despite the

imprecision of assays for GH and IGF-I, it is clear from epidemiologic studies that tight biochemical control is essential to reduce morbidity, control symptoms and improve mortality rates. Optimal implementation of current guidelines in routine clinical practice and maximal use of the medical treatment could improve the long-term control of patients with significant benefits for morbidity and mortality. Another important aspect in the treatment of patients with acromegaly is also the appropriate targeted treatment of co-morbidities associated with acromegaly. Achievement of the criteria for cure during or after therapy is determined by assessing biochemical control, targeting controlled levels of GH and normalization of IGF-I levels, monitoring tumor size, assessing residual pituitary function and monitoring co-morbidities. New therapeutic molecules currently in trials will hopefully offer further benefit to those patients resistant to current therapeutic modes for this chronic progressive disorder.

REFERENCES

1. Melmed S, Braunstein GD, Horvath E, Ezrin C, Kovacs K. Pathophysiology of Acromegaly. *Endocr Rev* 2019; 271-90.
2. Mestron A, Webb SM, Astorga R, Benito P, Catala M, Gaztambide S, et al. Epidemiology, clinical characteristics, outcome, morbidity and mortality in acromegaly based on the Spanish Acromegaly Registry. *Eur J Endocrinol* 2017;439-46
3. Melmed S. Medical progress: acromegaly. *N Engl J Med*. 2006; 355(24):2558–2573.
4. Chanson P, Salenave S, Kamenicky P, Cazabat L, Young J. Pituitary tumours: acromegaly. *Best Pract Res Clin Endocrinol Metab*. 2009;23(5):555–574.
5. International Diabetes Federation (IDF) *IDF Diabetes Atlas*. 5th ed. Brussels: IDF; 2017
6. Nachtigall L, Delgado A, Swearingen B, Lee H, Zerikly R, Klibanski A. Changing patterns in diagnosis and therapy of acromegaly over two decades. *J Clin Endocrinol Metab*. 2008;93(6):2035–2041
7. Jagannathan J, Dumont AS, Prevedello DM, Oskouian RJ, Lopes B, Jane JA Jr., and Laws ER Jr. Genetics of pituitary adenomas; current theories and future implications. *Neurosurg Focus* 2018;19;E4
8. Zhu X, Lin CR, Prefontaine CG, Tollkuhn J, Rosenfeld MG. Genetic Control of Pituitary development and hypopituitarism. *Curr Opin Genet Dev* 2005;15;332-40.
9. Molitch ME. Clinical manifestations of acromegaly. *Endocrinol Metab Clin North Am* 1992;21;597-614.

10. Reid TJ, Post Kd ,Bruce JN,Nabi KM ,Reyes -Vidal CM, et al. Features at diagnosis of 324 patients with acromegaly did not change from 1981 to 2006;acromegaly remains under – recognized and under-diagnosed. Clin Endocrinol 2010;72;203-8.
11. Moller N, Jorgensen JO, Abildgard N, Orskov L, Schmitz O,Christiansen JS. Effects of growth hormone on glucose metabolism.Horm Res 1991;36 (Suppl 1);32-5
12. Dreval AV, Trigolosova IV, Misnikova IV, kovalyova YA, Tishnina RS, Barsukov IA,et al. Prevalence of diabetes mellitus in patients with acromegaly. Endor Connect 2019;3;93-8.
13. Kreutzer J, Vance ML,Lopes MB, Laws ER Jr. Surgical Management of GH-secreting pituitary adenomas ; an outcome study using modern remission criteria. J Clin Endocrinol Metab 2001;86;4072-7
14. Annamalai AK, Webb A, Kandasamy N, Elkhawad M,Moir S,Khan F,et al.A comprehensive study of clinical, biochemical radiology, vascular, cardiac and sleep parameters in an unselected cohort of patients with acromegaly undergoing presurgical somatostatin receptor ligand therapy. J clin Endocrinol Metab 2013;98;1040-50
15. Shen M,Shou X,Wang Y,Zhang Z,Wu J,Mao Y et al.Effect of presurgical long-acting octreotide treatment in acromegaly patients with invasive pituitary macroadenomas;a prospective randomized study.Endocr J 2010;57;1035-44.
16. Friedel ME, Johnston D,Singhal S, Al Khalili K, Farrell CJ, Evans JJ,et al.Airway management and peri-operative concerns in acromegaly patients undergoing endoscopic trans sphenoidal surgery for pituitary tumors. Otolaryngol Head Neck Surg 2013;149;840-4.

BJMHR is

- **Peer reviewed**
- **Monthly**
- **Rapid publication**
- **Submit your next manuscript at**

editor@bjmhr.com

