



Journal Homepage: -[www.journalijar.com](http://www.journalijar.com)

## INTERNATIONAL JOURNAL OF ADVANCED RESEARCH (IJAR)

Article DOI:10.21474/IJAR01/14911  
DOI URL: <http://dx.doi.org/10.21474/IJAR01/14911>



### RESEARCH ARTICLE

#### ADRENAL NEUROBLASTOMA WITH BONE MARROW METASTASIS IN AN ADULT: A CASE REPORT AND REVIEW OF THE LITERATURE

K. Raissouni<sup>1</sup>, L. Benbella<sup>1</sup>, A. Jahid<sup>1</sup>, H. Ouazzani<sup>2</sup>, Z. Bernoussi<sup>1</sup>, K. Znati<sup>1</sup> and F. Zouaidia<sup>1</sup>

1. Department of Pathological Anatomy, IbnSina Hospital, Faculty of Medicine and Pharmacy, Mohammed V University, Rabat, Morocco.
2. Department of Pathological Anatomy, Speciality Hospital, Faculty of Medicine and Pharmacy, Mohammed V University, Rabat, Morocco.

#### Manuscript Info

##### Manuscript History

Received: 18 April 2022  
Final Accepted: 20 May 2022  
Published: June 2022

##### Key words:-

Neuroblastoma, Adult, Adrenal

#### Abstract

Neuroblastoma is the most common malignancy of early childhood, although it is extremely rare in the adult population with a significantly worse prognosis. Given the sparse data available in the literature regarding natural history, genetic causes, treatment, and outcomes in adult, the emergence of any new case will contribute to improve understanding of the disease. In this case report; a 33 years old woman was admitted with adrenal tumor initially presented as pheochromocytoma with diffuse bone metastases. A bone marrow biopsy was performed; Microscopic and immunohistochemical staining, which were positive for synaptophysin made the diagnosis of neuroblastoma.

Copy Right, IJAR, 2022., All rights reserved.

#### Introduction:-

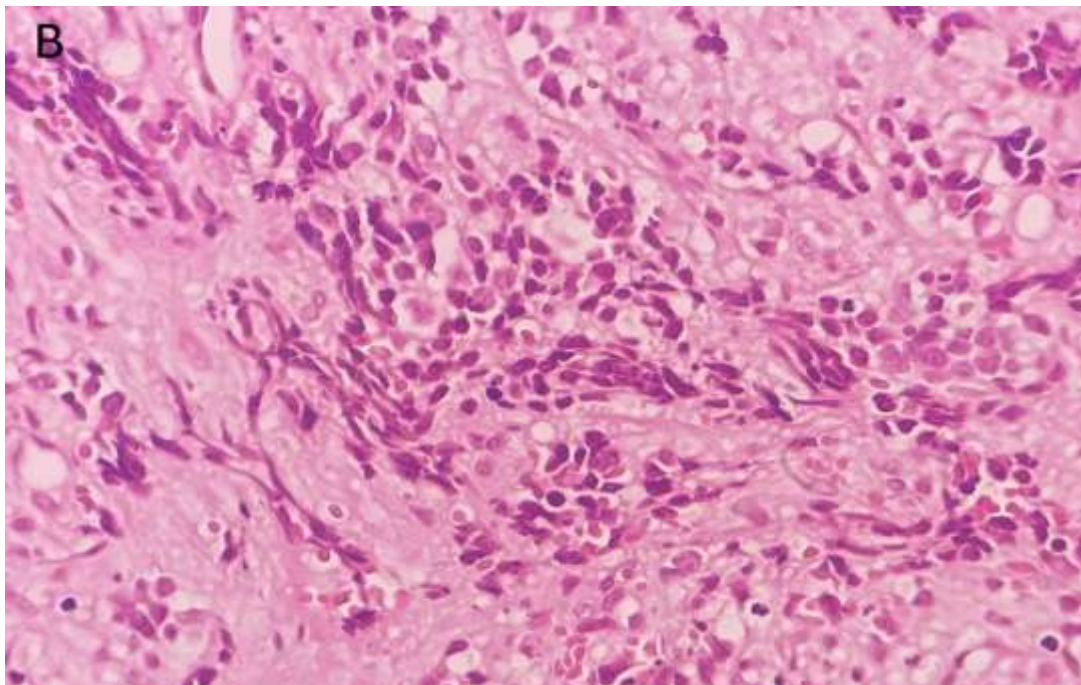
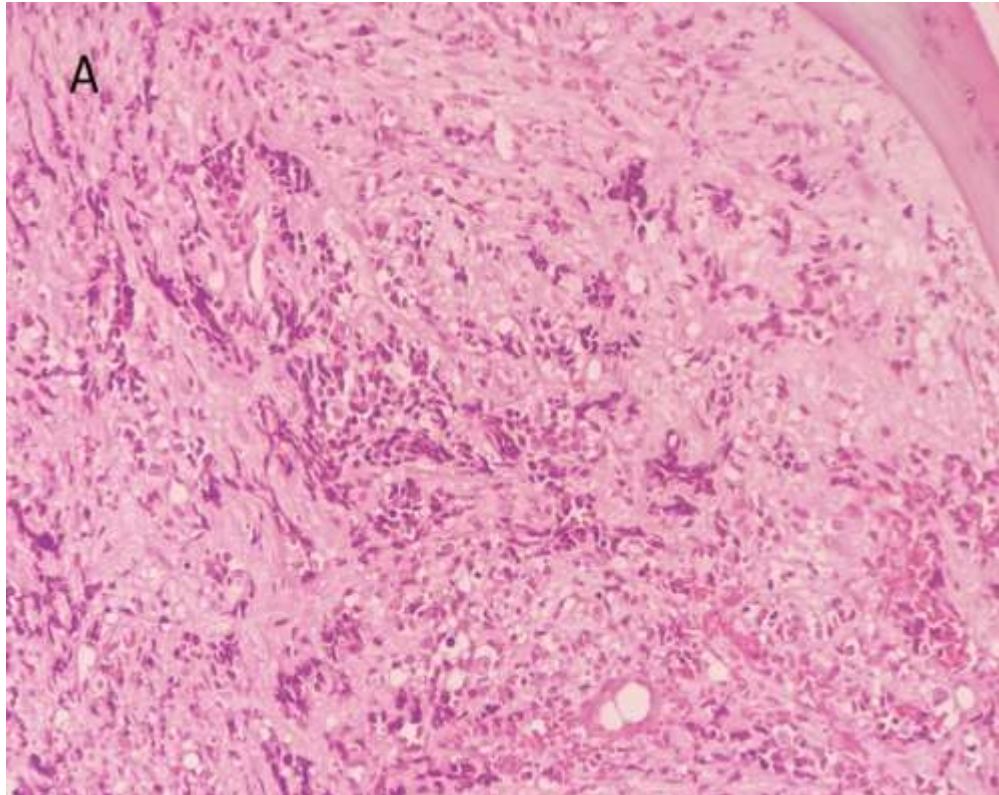
Neuroblastoma is an embryonal neural crest tumor involving the peripheral sympathetic nervous system. The adrenal gland is the most common primary site of neuroblastoma (NB) while bone is the most common site of distant metastasis of NB [1]. Furthermore it is the most common extracranial solid tumor in children [2]. It is extremely rare in adults and its total incidence is 1 case per 10 million adults per year [3], consequently the diagnosis may not be initially considered because of the rarity, which emphasizes the importance of immunohistochemical staining and cytogenetic testing in aiding the diagnosis.

#### Case Presentation:

A previously healthy 33 years old woman presented with abdominal and lower back pain of 2 months duration, evolving in a context of unquantified weight loss. Her past medical history was unremarkable. An abdomen computed tomography (CT) scans showed a left adrenal mass of 5x3.7x2 cm initially diagnosed as a pheochromocytoma with diffuse osseous metastases. Her 24-hours urine catecholamines showed elevated norepinephrine (180 ug/g, reference values 0-45) 4 times normal limit concerning neuroendocrine tumor. Vanillyl-mandelic acid, and homovanillic acid levels were unremarkable.

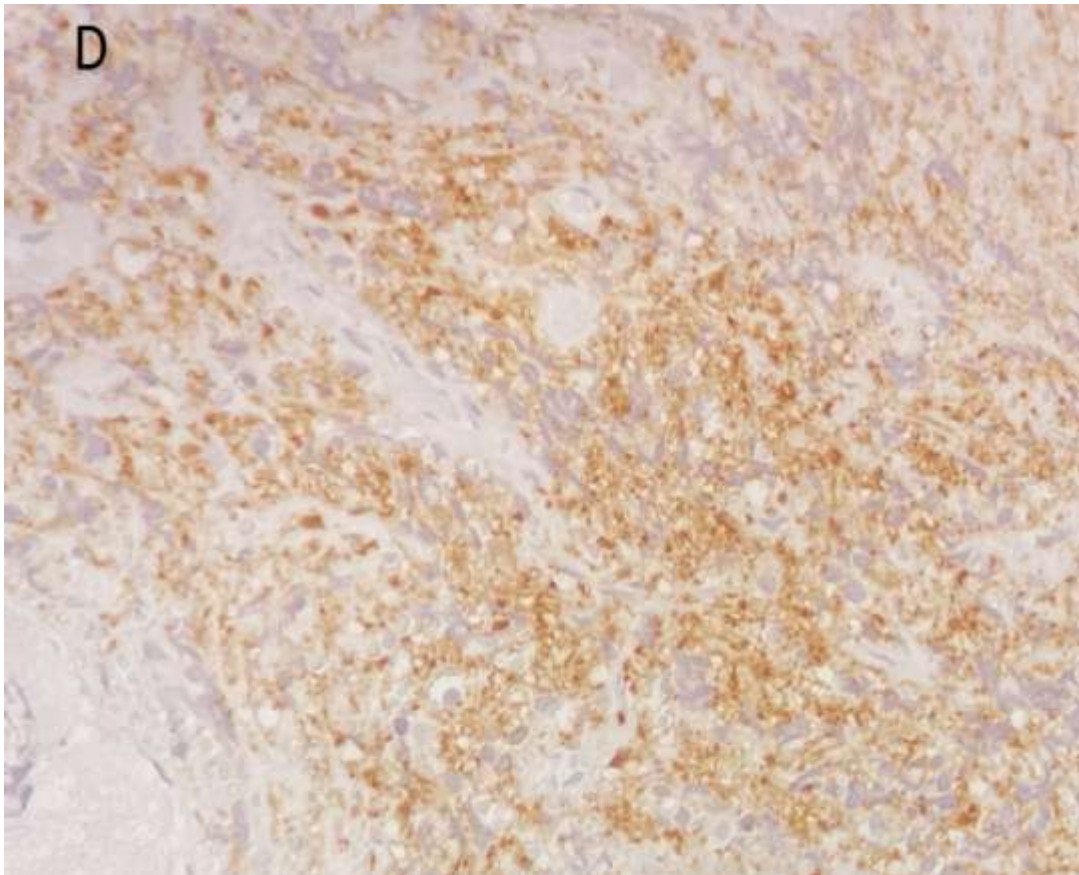
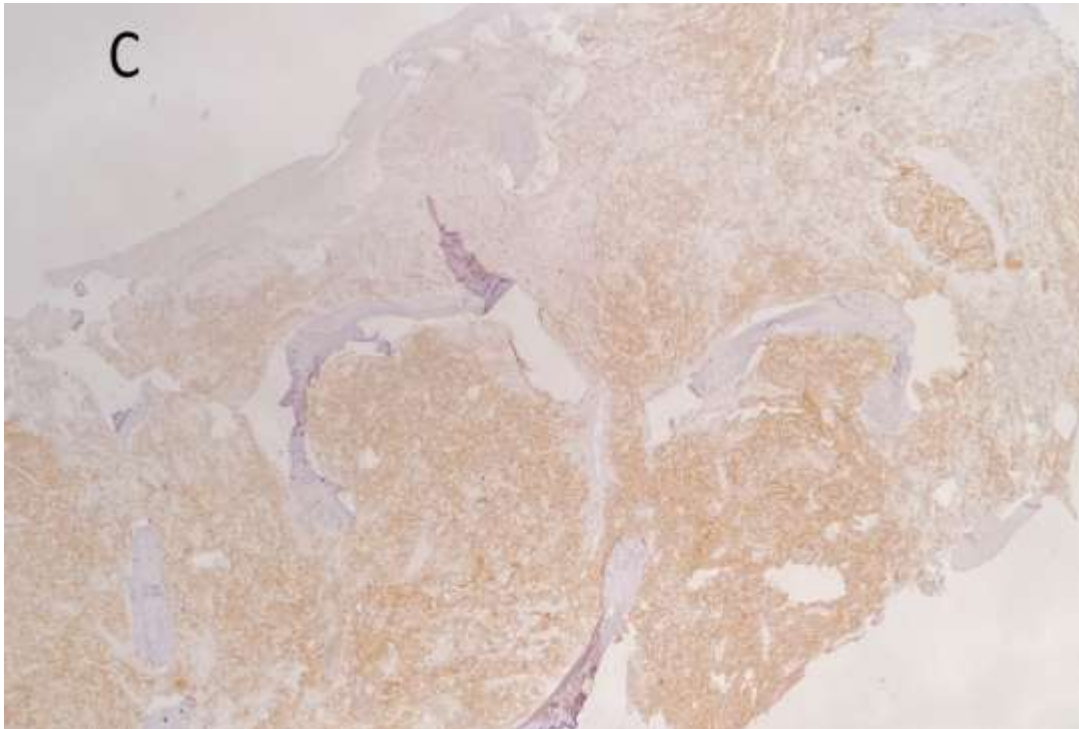
A bone marrow biopsy was performed. The anatomopathological examination included; on a background of diffuse myelofibrosis, a tumor proliferation; made up of clusters of round monomorphic small cells with hyperchromatic nuclei and little abundant cytoplasm (Fig A, B).

Immunohistochemical staining for CD99, Calretinin, Chromogranin A, Cytokeratin AE1 /AE3, CD99, S100 and CD45 was negative with positive staining for synaptophysin (FigC, D). Based on these findings, we made a diagnosis of neuroblastoma. No surgical resection was done; the patient was referred to an oncology center for further management.



**Figure (A, B):-** Bone marrow biopsy shows a hypercellular marrow diffusely infiltrated with small hyperchromatic tumor.





**Figure (C, D):-**synaptophysinimmunohistochemical stain is positive in these cells. Chromogranin, CD99, S100, Calretinin and cytokeratin AE1/AE3 stains were negative (not shown).

**Discussion:-**

Neuroblastoma is a pediatric malignancy that uncommonly affects the adults. It is rarely reported in the adult population, with <10% of the cases diagnosed after age 10 [4,5]. Neuroblastoma exhibits a wide spectrum of histopathologic heterogeneity, with poor outcomes in older patients and/or patients with advanced disease [6, 7,8,9]. Multiple studies suggest that adult neuroblastoma may have distinct biologic features, including low frequency of MYCN amplification, urine catecholamine elevation, and MIBG (iodine-131-meta-iodobenzylguanidine; an analog of norepinephrine) avidity [10,11].

Clinically, NB in adult patients varies from asymptomatic to critically ill. It depends on the tumor's primary location and the extent of metastatic disease; the most common presentations are abdominal mass, abdominal pain, muscle weakness, or presentations due to metastases such as back pain and bone marrow failure, [12,13, 14].

Biologically, NB causes an elevation of urinary catecholamines, which is another way to further characterize this malignancy. Literature reports urine catecholamine elevation rates from 46% to 90%, and thus while the test can be a useful aid, its negative predictive value is not high [15,16].

Besides abdominal and lower back pain, our patient had an excess level of urinary catecholamines which is suggestive of a neuroendocrine tumor but also could be secondary to pheochromocytoma and other complicating factors.

While neuroblastoma is rare in adult patients, it is important to consider in the differential diagnosis of small round blue cell tumors, at least three other neoplasms are routinely considered members of this group: Ewing's sarcoma, lymphoma, and soft-tissue sarcomas, especially rhabdomyosarcoma.

In our case, pheochromocytoma was initially suspected on computed tomography (CT) scan. It was morphologically excluded on bone marrow biopsy despite the negativity of the calretinin marker on IHC. Lymphoma was also excluded given the morphology of cells and with IHC.

Ewing sarcoma/PNET can express neuroendocrine markers, and can be differentiated from neuroblastoma by positive CD99 and cytokeratin staining [17].

Neuroblastoma may be diagnosed by morphology, and has been shown to express CD56, chromogranin A, synaptophysin, neurofilament, neuron-specific enolase and s100 [9]. Histopathological examination of the bone marrow showed positive expression of synaptophysin (Fig C, D)

MYCN examination by fluorescence in situ hybridization (FISH) was not performed in our patient. In addition to MYCN amplification, these tumors can also have loss of heterozygosity at 11q and 1p.

The International Neuroblastoma Risk Group (INRG) tumor staging system has been developed for the stratification of statistical and clinical risks of different subgroups of patients with NB. In the INRG Staging System, extent of locoregional disease is determined by the absence or presence of image-defined risk factors (L1 and L2, respectively). Stage M will be used for widely disseminated disease [18]. Four broad categories of very low risk, low risk, intermediate risk, and high risk were proposed in terms of 5-year event-free survival with rates of >85%, >75 to ≤85%, >50 to ≤75%, and <50%, respectively. The category is based on age at diagnosis, INRG tumor stage, histologic category, grade of tumor differentiation, DNA ploidy, and copy number status at the MYCN oncogene locus and at chromosome 11q.

The treatment strategy in pediatric patients with NB has been well studied; it includes surgical resection, and optimal combination chemotherapy and radiotherapy. However, no standard therapy for adults diagnosed with NB is a consensus yet, due to the scarcity of cases in this population. A complete resection is proposed in low-risk patients, in high-risk patients, combined treatment modalities such as operation, chemotherapy and radiotherapy should be administered [19].

Induction chemotherapy and surgery on the primary tumour are therapeutic options. If there is a partial response, radiotherapy on the remaining tumour is suggested. After induction, high dose chemotherapy and autologous stem cell transplantation are the best approaches.

**Conclusion:-**

Neuroblastoma is a typically pediatric neoplasm, which rarely affects adult. The infrequency with which it occurs may delay time to diagnosis, and therefore it is important to consider in the differential diagnosis of small round blue cell tumors. According to the medical literature modalities used in children such as chemotherapy, surgery, bone marrow transplantation, and radiotherapy could be used in adults as well [20]. Further research focusing on tumor biology and therapy for this rare malignancy in adults may help to improve disease outcome.

**References:-**

1. Whittle SB, Smith V, Doherty E, Zhao S, McCarty S, Zage PE. Overview and Recent Advances in the Treatment of Neuroblastoma. *Expert Rev Anticancer Ther* (2017) 17(4):369–86. doi: 10.1080/14737140.2017.1285230
2. DuBois SG, Kalika Y, Lukens JN, et al. Metastatic sites in stage IV and IVS neuroblastoma correlate with age, tumor biology, and survival. *J Pediatr Hematol Oncol* 1999;21:181–9
3. Siegel R, Naishadham D, Jemal A. Cancer statistics, 2012. *CA Cancer J Clin*. 2012;62(1):10-29. <http://dx.doi.org/10.3322/caac.20138>. PMID:22237781.
4. Kushner BH, Kramer K, LaQuaglia MP, Modak S, Cheung NK. Neuroblastoma in adolescents and adults: the Memorial Sloan-Kettering experience. *Med Pediatr Oncol*. 2003;41(6):508–15.
5. Podda MG, Luksch R, Polastri D, Gandola L, Piva L, Collini P, et al. Neuroblastoma in patients over 12 years old: a 20-year experience at the Istituto Nazionale Tumori of Milan. *Tumori*. 2010;96(5):684–9.
6. Maris JM. “Recent advances in neuroblastoma” *N Engl J Med*. 2010;362:2202-2211.
7. Park JR, Eggert A, Caron H. Neuroblastoma: biology, prognosis, and treatment. *Hematol Oncol Clin North Am*. 2010 24:65-86.
8. Franks L, Bollen A, Seeger RC, et al. Neuroblastoma in adults and adolescents: an indolent course with poor survival. *Cancer*. 1997;79:2028-2035.
9. Castel V, Villamon E, Navarro S, et al. Neuroblastoma in adolescents: genetic and clinical characterization.” *Clin Translational Oncol*. 2010;12:49-54.
10. Esiashvili N, Goodman M, Ward K, et al. Neuroblastoma in adults: incidence and survival analysis based on SEER data. *Pediatr Blood Cancer*. 2007;49: 41-46.
11. Castel V, Villamon E, Navarro S, et al. Neuroblastoma in adolescents: genetic and clinical characterization.” *Clin Translational Oncol*. 2010;12:49-54.
12. Podda MG, Luksch R, Polastri D, Gandola L, Piva L, Collini P, et al. Neuroblastoma in patients over 12 years old: a 20-year experience at the Istituto Nazionale Tumori of Milan. *Tumori*. 2010;96(5):684–9.
13. Rogowitz E, Babiker HM, Kanaan M, Millius RA, Ringenberg QS, Bishop M. Neuroblastoma of the elderly, an oncologist's nightmare: case presentation, literature review and SEER database analysis. *Exp Hematol Oncol*. 2014;3:20.
14. Conter HJ, Gopalakrishnan V, Ravi V, Ater JL, Patel S, Araujo DM. Adult versus Pediatric Neuroblastoma: The M.D. Anderson Cancer Center Experience. *Sarcoma*. 2014;2014:375151.
15. Esiashvili N, Goodman M, Ward K, et al. Neuroblastoma in adults: incidence and survival analysis based on SEER data. *Pediatr Blood Cancer*. 2007;49: 41-46.
16. Castel V, Villamon E, Navarro S, et al. Neuroblastoma in adolescents: genetic and clinical characterization.” *Clin Translational Oncol*. 2010;12:49-54.
17. Hasegawa T, Hirose T, Ayala A, et al. Adult neuroblastoma of the retroperitoneum and abdomen.” Hasegawa T, Hirose, T, Ayala, A. et al. *Am J of Surgical Pathol*. 2001;25:918-924.
18. Cohn SL, Pearson AD, London WB, Monclair T, Ambros PF, Brodeur GM, et al. The International Neuroblastoma Risk Group (INRG) classification system: an INRG Task Force report. *J Clin Oncol*. 2009;27(2):289–97.
19. Schalk E, Mohren M, Koenigsman M, Buhtz P, Franke A, et al. (2005) Metastatic adrenal neuroblastoma in an adult. *Onkologie* 28: 353-355.
20. Franks LM, Bollen A, Seeger RC, Stram DO, Matthay KK (1997) Neuroblastoma in adults and adolescents: an indolent course with poor survival. *Cancer* 79: 2028-2035.