

## **Unavoidable Posterior Lower Segment Caesarean Incision Due To a 180-Degree Uterine Torsion Resulting From a Huge Anterior Uterine Fibroid: A Case Report**

**Onyekpa IJ<sup>1,2</sup>, Odugu BU<sup>1,2</sup>, Okafor II<sup>1</sup>, OFFOR I<sup>1</sup>, Onah LN<sup>1</sup>, Omeke CA<sup>1</sup>, Ofonere CN<sup>1,2</sup>, Ezenweze M<sup>1</sup>, Ugwuanyi TC<sup>1</sup>**

Department of Obstetrics & Gynaecology, Enugu State University of Science & Technology/College of Medicine, Enugu

<sup>1</sup>SEMINO Specialist Hospital, Abakpa-Nike, Enugu

<sup>2</sup>Department of Nursing Services, Enugu State University of Science & Technology Teaching Hospital, Enugu

---

### **ABSTRACT**

**Background:** Uterine rotation is a common occurrence in pregnancy. However, when the rotation is more than 45 degrees it is termed torsion. Uterine torsion is rare and can complicate pregnancy especially in association with uterine anatomical pathologies, pelvic masses and abnormalities and fetal anomalies. The presentation and management vary and depend on the cause, degree of torsion and age of the pregnancy. The rarity of this condition makes this case report worthwhile.

#### **Case Report:**

We report a case of a 30 year old primigravid woman who booked for antenatal care at 16 weeks gestational age following a 3-year history of primary infertility. The pregnancy was complicated with abdominal pain from red degeneration of uterine fibroids and was managed with pentazocine injection severally in the 2<sup>nd</sup> trimester. She presented in labour at 39 weeks but the labour was prolonged for 8 hours, having adequate contractions without any significant improvement in both descent and cervical status. She subsequently had an emergency caesarean delivery through a posterior lower segment incision due to an incidental finding of a 180-degree uterine torsion resulting from huge anterior fibroids; with an outcome of a live female neonate that weighed 3.1kg with good Apgar scores. Two pieces of fibroids were removed from the anterior surface that weighed 1.1kg. The post operative and puerperal periods were uneventful.

**Conclusion:** Uterine torsion in pregnancy, a rare obstetric occurrence and infrequently reported complication occurs mainly in the third trimester and may complicate labour. In the presence of significant uterine fibroid, a possibility of uterine torsion may be entertained when the progress of labour is considered poor without any obvious mechanical cause. In such cases caesarean delivery with possible posterior uterine incision may be carried out.

**KEYWORDS:** Uterine Torsion, Posterior Lower Segment Incision, 180-Degree, Fibroid

---

---

### **ARTICLE DETAILS**

**Published On:**  
**13 July 2022**

**Available on:**  
**<https://ijmscr.org/>**

---

### **INTRODUCTION**

Uterine rotation is a common occurrence in term pregnancy with dextro-rotation being commoner than levo-rotation due to the presence of the sigmoid colon on the left. However, uterine

torsion in pregnancy is a rare occurrence and it is defined as a rotation of the gravid uterus >45 degrees.<sup>1,2</sup> Several studies have reported torsion between 60 to 720 degrees with varying presentations.<sup>3-6</sup> The exact cause of most uterine torsion is not


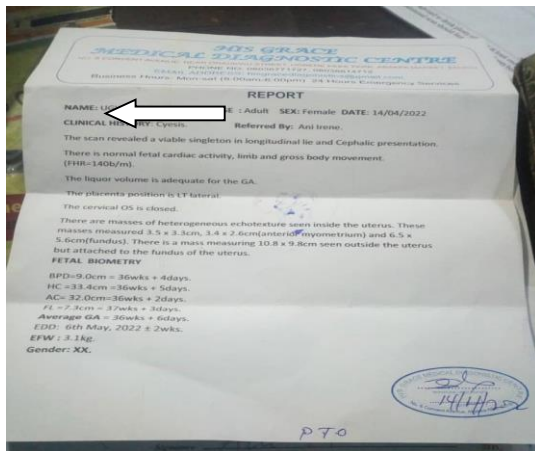
# Unavoidable Posterior Lower Segment Caesarean Incision Due To a 180-Degree Uterine Torsion Resulting From a Huge Anterior Uterine Fibroid: A Case Report

known but pelvic anomalies such as uterine fibroids, congenital uterine anomalies, pelvic adhesions, ovarian tumors and abnormalities of the spine in the with or without fetal anomalies have been implicated. Fibroids complicate a lot of pregnancies especially among the black race and they tend to increase in size during child bearing years. It has been found to complicate about 0.05% to 0.5% of pregnancies.<sup>7-9</sup> Mild uterine torsion maybe asymptomatic but significant torsion may present with poor progress of labour, obstructed labour, intestinal obstruction, abdominal pain, urinary symptoms and even maternal shock.<sup>10</sup> The diagnosis is often made incidentally during caesarean section and the management is usually derotation of the gravid uterus followed by an anterior lower segment incision.<sup>1,10-12</sup> Many cases of posterior uterine incision are unreported but the frequency of uterine fibroid which is a major cause of torsion makes this report important to equip

obstetricians with requisite knowledge and skill to attend to such cases when encountered.

## CASE PRESENTATION

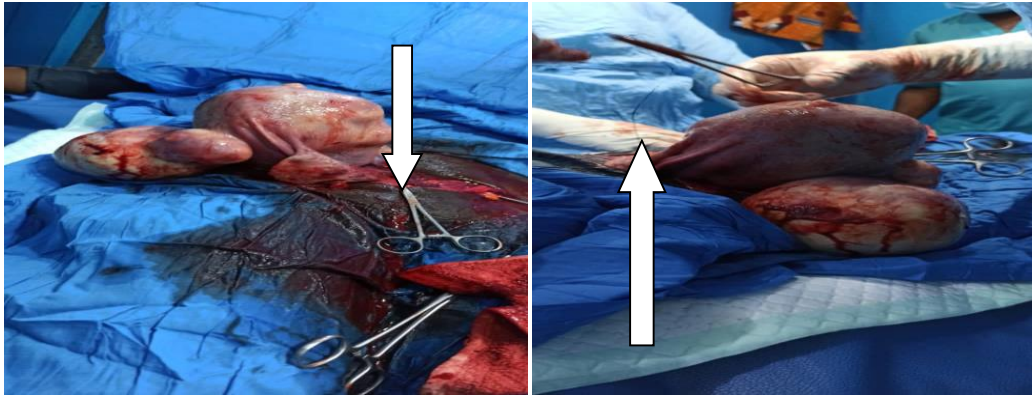
We report a case of a 30 year old primigravid woman booked for antenatal care at 16 weeks gestational age following a 3-year history of primary infertility. At booking she complained of severe abdominal pain but no history of bleeding from the vagina. An abdomino-pelvic ultrasound scan revealed multiple uterine fibroids of varying sizes. She was managed as a case of red degeneration of fibroid in pregnancy with opiod analgesia (pentazocine) on several occasions and the pregnancy was eventually carried to term. At a gestational age of 36 weeks a repeat ultrasound scan revealed no obvious fibroid at the lower segment and she was planned for vaginal delivery. Below is the report of the scan:



She presented in labour at 39 weeks but the labour lasted for 8 hours, having adequate contractions without any significant improvement in both descent and cervical dilatation. However, the fetal heart rate remained within normal range. Decision was taken to revert to caesarean delivery. Incidentally, she was found to have a 180 degree uterine torsion. Attempts to derotate the uterus were unsuccessful owing to huge anterior fibroids held down on the posterior abdominal wall by adhesions. Subsequently a posterior lower segment incision was made into the uterine cavity from where the baby was delivered: a live female neonate that weighed 3.1kg with good Apgar scores. The placenta was manually delivered and the uterus gently exteriorized following which the adhesions were relieved by both sharp and blunt dissection. The uterine incision

was repaired in layers with vicry-2 absorbable suture. The torsion was corrected afterwards. A tourniquet was subsequently applied around the isthmus to control bleeding as two huge anterior upper segment fibroids that weighed 1.1kg were removed. The cavity so created was closed in layers with vicryl-2 suture to achieve haemostasis. The estimated blood loss was 500ml and the post operative and puerperal periods were uneventful. Her pre-operative and post-operative haemoglobin levels were 16g/dl and 15g/dl respectively. She was discharged on the 5<sup>th</sup> day post surgery on oral haematinics, antibiotics and analgesics. At 6 week postpartum visit she had no complaints and had not seen her menses. The uterus was barely palpable per abdomen. She was then referred to the family planning clinic for further contraceptive care.

# Unavoidable Posterior Lower Segment Caesarean Incision Due To a 180-Degree Uterine Torsion Resulting From a Huge Anterior Uterine Fibroid: A Case Report



**Fig. 1. Arrow showing posterior lower segment incision with the huge anterior fibroids**  
**Fig.2. Arrow showing the process of repairing the incision after derotation**

## DISCUSSION

Uterine torsion is a rare occurrence in pregnancy and has been referred to by some author as ‘once in a life time diagnosis’.<sup>2</sup>This is a case of 180 degree torsion of a fibroid uterus at term with a life baby complicated by poor progress of labour. The baby was delivered through a posterior lower segment uterine incision. As expected significant uterine torsion can result in obvious distortion of the uterine anatomy and appearance at surgery that may mislead an unsuspecting surgeon with consequences. The major cause of uterine torsion is uterine fibroids as is in the case of our patient. However, some authors have proposed that certain body movements or posture and positions might trigger the rotation of the uterus in the presence of pre-existing structural abnormalities; and an intrinsic pelvic pathology is found in 66% of all cases of uterine torsion.<sup>13,14</sup> Using MRI evaluation of patients following lower segment caesarean suggested that poor isthmic healing may result in sub-optimal restoration of the normal cervical length. This may lead to torsion. It can also result from abdominal trauma.<sup>15</sup>None of these were found in the index case except fibroids. The incidence of a posterior lower segment incision due to uterine torsion may be under reported as the author has encountered 2 previously unreported cases in the course of his practice.<sup>16</sup>

Understanding and defining the anatomy of the uterus during torsion is important whether anterior or posterior incision is to be made to avoid iatrogenic injuries to major blood vessels and other adjoining structures. The literature is scarce on the post operative complications of posterior incision following torsion but there may be an increased risk of uterine adhesions posteriorly.

## CONCLUSION

Uterine torsion though a rare occurrence can complicate a pregnant uterus at any gestational age but most commonly around term. This condition may necessitate a posterior incision

on the uterus in order to deliver the baby. Awareness of this condition so as to prepare the obstetrician ahead of time in case of any incidental finding of torsion makes this case report expedient.

## REFERENCES

- I. Wilson D, Mahalindham A, Ross S. Third trimester uterine torsion: a case report. *J Obstet Gynaecol Can* 2006;28:531-5
- II. Kremer JAM, van Dongen PWJ. Torsion of the pregnant uterus with a change in placental localization on ultrasound: a case report. *Eur J Obstet Gynaecol Reprod Biol* 1989;31:273-5
- III. Corr JE. Uterine torsion in pregnancy. *Acta Obstet Gynaecol Scand* 1992;71:749-51
- IV. Colombetti G. Su un caso di torsion assiale dell’ utero do. *Minerva Ginecol.* 1964;16:780-82
- V. Corr JE. Axial torsion of the gravid uterus in two successive pregnancies. *Am J Obstet Gynaecol.* 1943;46:749-51
- VI. Cella PL. Rilievi sulla torsion assiale dell’ utero in gravidanz: a proposito di un caso. *Quad Clin Ostet.* 1969;24:503-09
- VII. Rasmussen KL, Knudsen HJ. Effects of uterine fibromas on pregnancy. *Ugeskr Laeger.* 1994;156:7668-7670
- VIII. A O Omigbodun and AO Fawole. “Myomectomy during pregnancy and delivery. Is it safe?- Commentary,” *Tropical Journal of Obstetrics & Gynaecology*,2005;22(1):1-3
- IX. CO Agboghroma, ER Efetie, AC Umezulike, “Unavoidable caesarean myomectomy: a case report,” *Topical Journal of Obstetrics & Gynaecology*, 2005;22(1):81-82

## **Unavoidable Posterior Lower Segment Caesarean Incision Due To a 180-Degree Uterine Torsion Resulting From a Huge Anterior Uterine Fibroid: A Case Report**

- X. Homan H, Moukhah S, Alizadeh M. Asymptomatic torsion of a gravid uterus. *Taiwan J Obstet Gynaecol* 2013;52:599-601
- XI. Taga A, Kondoh E, Hamanishi J, Kawasaki K, Fujita K, Mogami H, et al. transverse fundal uterine incision for delivery of extremely low birth-weight infants. *J Matern Fetal Neonatal Med.*2014;27:1285-7
- XII. Albayrak M, Benian A, Ozdemir I, Demiraran Y, Guralp O. Deliberate posterior low transverse incision at caesarean section of a gravid uterus in 180 degrees of torsion: a case report. *J Reprod Med* 2011;56:181-3
- XIII. Robinson AL, Duvall HM. Torsion of the pregnant uterus. *J Obstet Gynec Br Commonw.*1931;39:55-84
- XIV. Kawakami S, Togash K, Sagon T, Kimura I, Noguchi M, Tkakura K, Mori T, Konishi J. Uterine deformity caused by surgery during pregnancy. *J Comput Assist Tomogr.*1994;18:272-74
- XV. Duplantier N, Begneaud W, Wood R, Dabezies C. Torsion of gravid uterus associated with maternal trauma: a case report. *J Reprod Med.*2002;47:387-88
- XVI. G Deshpande, R Kaul. A case of torsion of the gravid uterus caused by leiomyoma. *Case Rep Obstet Gynaecol* 2011(2011) 206418, <https://doi.org/10.1155/2011/206418> PM