



CODEN [USA]: IAJPBB

ISSN: 2349-7750

## INDO AMERICAN JOURNAL OF PHARMACEUTICAL SCIENCES

SJIF Impact Factor: 7.187

Available online at: <http://www.iajps.com>

Research Article

### HEPATOPROTECTIVE AND NEPHROPROTECTIVE ACTIVITY OF PULP AND FLESH OF FRUIT OBTAINED FROM *CHOEROSPONDIA AXILLARIS* (ROXB.) USING RIFAMPICIN AS AN INDUCER ON ALBINO RATS.

Dharmi Chaudhary<sup>1</sup>, Yogesh H.S<sup>2</sup>., Shivkumar Swamy<sup>1</sup>, V Kusum Devi<sup>2</sup>

<sup>1</sup>Mallige College of Pharmacy, Banglore-560090, Karnataka.

<sup>2</sup>Nitte College of Pharmaceutical Sciences, Banglore-560064, Karnataka.

Article Received: June 2022

Accepted: June 2022

Published: July 2022

**Abstract:**

**Objective:** The aim of the study was to investigate the hepato and nephro protective activity of *Choerospondias axillaris* (Roxb.) peel and flesh extract against Rifampicin induced toxicity in albino rat.

**Methods:** Bioactive functional groups, flavonoids, saponins, tannins, glycosides, polyphenols, carotenoids (provitamin A), vitamins C and E were present in hydroalcoholic extract which was confirmed by respective chemical test and the hepato and nephroprotection activity of ethanolic extract was evaluated against Rifampicin (1g/kg body wt, p.o.). Biomarkers like, ALT, AST, were considered to determine hepatoprotecton. Nephroprotection activity was determine by measuring serum creatinine, uric acid, blood urea nitrogen. Histopathological study of liver and kidney was carried out.

**Results:** Hydroalcoholic extract of *C.axillaries* reduced the level of aspartate transaminase (AST) and alanine transaminase (ALT) in comparison to inducer. The extract also showed nephroprotective activity against rifampicin-induced nephrotoxicity by significantly reducing the levels of uric acid, blood urea nitrogen (BUN), serum creatinine. Histopathological studies of liver and kidney were in agreement with biomarkers.

**Conclusion:** Keywords: *Choerospondias axillaris*, antioxidant and lapsi fruit.

**Corresponding author:**

**Yogesh H.S,**

Nitte College of Pharmaceutical Sciences,

Banglore-560064, Karnataka.

QR code



Please cite this article in press Yogesh H.S et al, *Hepatoprotective and Nephroprotective Activity Of Pulp And Flesh Of Fruit Obtained From choerospondias axillaris (ROXB.) Using Rifampicin As An Inducer On Albino Rats.*, Indo Am. J. P. Sci, 2022; 09(7).



**INTRODUCTION:**

Hepatic system is very vital organ system involved in the body's metabolic activities. The liver is the principal glandular organ in the body and has more functions than any other human organ. The liver plays a noteworthy role in metabolism in the humans as well as in a majority of animals [1]. The reasons for the liver diseases in the developing countries are hepatitis viruses, environmental toxins and parasitic disease. Certain drugs such as antibiotics, chemotherapeutic agents, high doses of paracetamol, carbon tetrachloride (CCL4), thioacetamide (TAA) causes hepatotoxicity.

Kidney is also the important target organ for the toxic effects of drugs xenobiotics and oxidative stress. Oxygen-free radicals have been implicated in several biological processes potentially important in glomerular diseases [2].

Rifampicin produces hepatic dysfunction and elevation of liver enzymes and some fatalities have occurred [3]. Rifampicin also reported to produce nephrotoxicity [4]. Many chemical drugs and radiation therapy were widely used for the treatment of liver and kidney damage. However, these were high expensive, poor compatibility, and cause many side effects [5].

*Choerospondias axillaris* (Roxb.) B.L. Burt and A.W.Hill (Anacardiaceae) is a medicinal plant used in Mongolia. Its fruit (abbreviated as CAF) is commonly used for the treatment of cardiovascular diseases. The constituents of CAF have been investigated chemically and shown to include phenolic compounds and flavonoid content.

In Mongolian medicine several properties, such as treatment of myocardial ischemia, calming nerves, ameliorating blood circulation and improving microcirculation, have been reported for CAF. Also an aqueous extract from *Choerospondias axillaris* fruit was evaluated for its in vivo antioxidant activity [6], and several plants containing antioxidant properties exhibited nephroactivity against gentamicin and cisplatin [7]. Therefore, the objective of this study was to evaluate the hepatoprotective and nephroprotective activity against rifampicin-induced

toxicities on ethanolic extract of peel and flesh obtained from fruit *Choerospondias axillaris* (Roxb.).

**MATERIALS AND METHODS:****Collection and authentication of plant material:**

For this study, peel and flesh will be obtained from fruits of *Choerospondias axillaris* (Roxb.), collected from Kathmandu local market will be identified by National Herbarium and Plant laboratory, Department of Plant Resources, Ministry of Forests and soil Conservation, Government of Nepal. The sample will be identified and authenticated by Dr.Ravikumar, senior Botanist at FRLHT (Foundation for Revitalisation of Local Health Traditions) Jarakabande kaval, post Attur, Yelahanka, Bengaluru (560106). A herbarium specimen was preserved in the college museum for future reference.

**Preparation of crude extract of lapsi fruits:** The crude extracts of the pulp of lapsi fruits were prepared separately by using ethanol described below:

**Ethanol extraction:** The fruits sample were individually washed with tap water and spread over newspaper for air drying under shade. After drying, the fruits were powdered using blender. The course powder was passed through 40 mesh sieve to get fine and uniform powder. A weighed qty of powder then subjected to continuous hot extraction in Soxhlet apparatus with ethanol for 60-70 hrs the mixture was then filtered, the supernatant was concentrated using water bath at temperature of 70 °C. A greasy final material (crude extract of lapsi fruits) obtained was transferred to screw-cap bottles, labeled and stored under refrigerated (4 °C) condition until use.

**Phytochemical screening:** Ethanolic extract of peel and pulp of *Choerospondias axillaris* fruit was subjected to chemical tests for the identification of their constituent. Test for the presence of flavonoid, saponins, tannins, phenolic compd, vitamin c, glycosides, and alkaloids were conducted as per standard procedure.

**RESULTS AND DISCUSSION:**

**Phytochemical test results:** chemical constituent of *Choerospondias axillaris* fruits.

Table-1:

Phytoconstituents	Results
Terpenoids	- -
Flavanoids	+
Glycoside	+
Alkaloids	+
Protein	+
Phenols	+

(+) indicate presence while (-) stand for absence

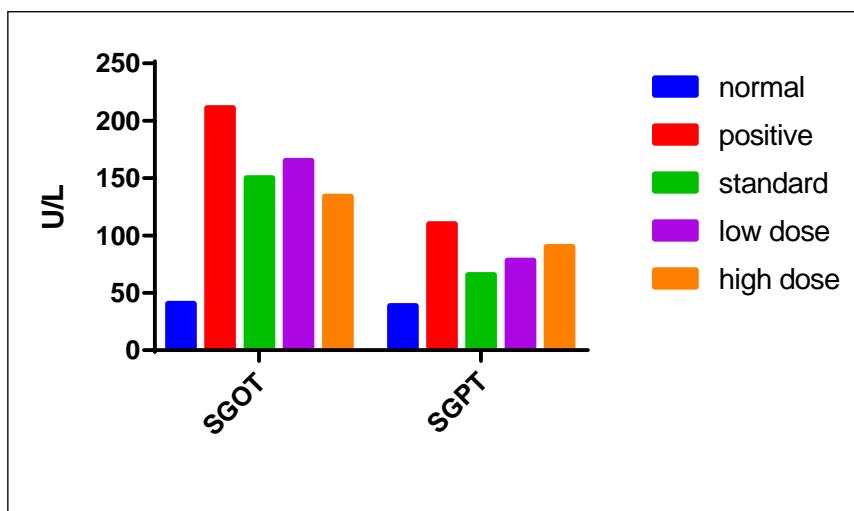
**Hepatoprotective activity of Choerospondias axillaris:** Table given below shows the effects of ethanolic extract of Choerospondias axillaris fruits on the activities of serum ALT, AST in experimental rats. Oral administration of 100g/kg b.w. of rifampicin for 15 days caused a significant increase in the activities of these enzymes when compared with the positive control.

The elevated activities of the assayed enzyme induced by silymarin were significantly attenuated following treatment with low dose and high dose of HAECA (Hydroalcoholic extract of Choerospondias axillaris)

Table-2:

GROUP	Treatment	SGOT(U/L)	SGPT(U/L)
1	Normal saline	40.5±3.02	38.3±3.67
2	Positive control	211±30.7	110±13.8
3	Standard	139±17.3*	65.5±4.98
4	HAECE Low dose	165±16.5ns	78.2±5.88*
5	HAECE High dose	134±11.7*	90.2±10.4***

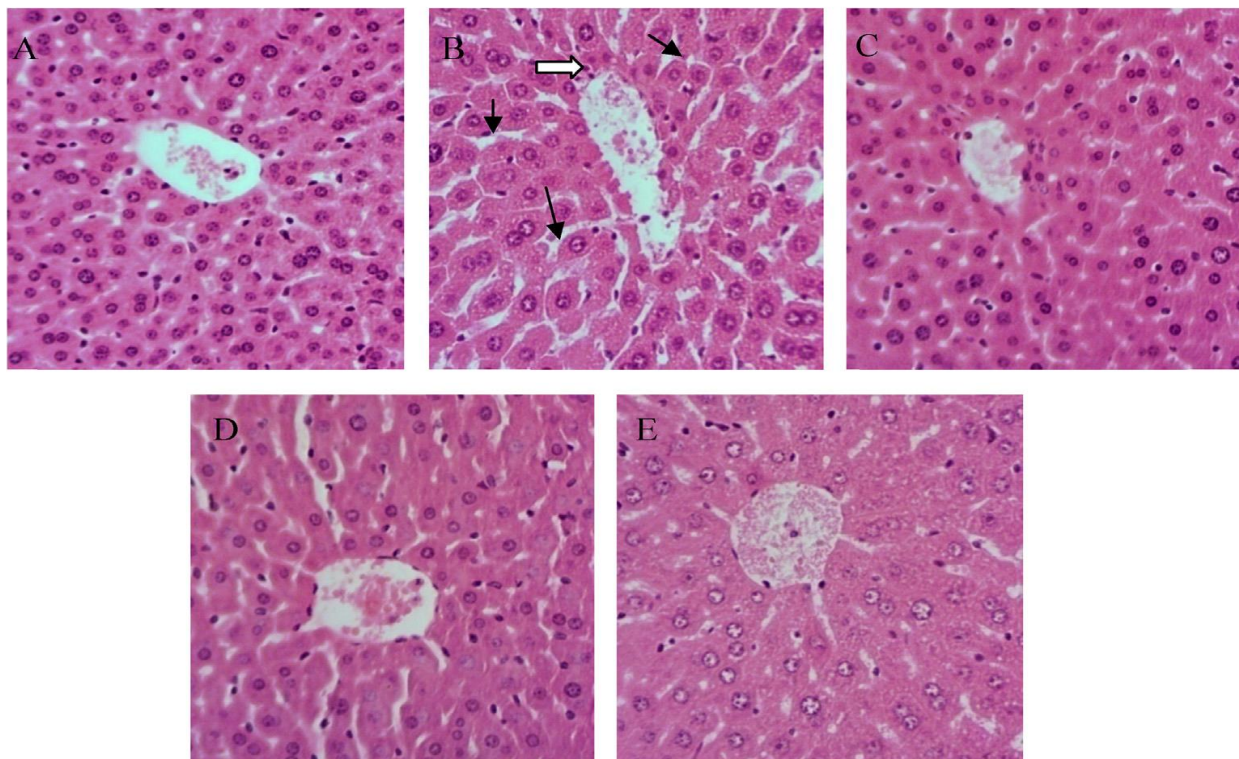
Each value are expressed as mean ± SEM for 6 animals in each group, \*P<0.05; \*\*P<0.01; \*\*\*P<0.001 as compared to Rifampicin treated group. One-way ANOVA followed by Dunnett test



**Figure 1:** Effect of ethanolic extract of Choerospondias axillaris on ALT and AST in Rifampicin induced hepatotoxicity in rats.

**Histopathological results:**

**Figure 1:** Effect of Ethanolic extract of fruits of *Choerospondias axillaris* on histopathological examination of rat liver in rifampicin-induced hepatotoxicity, (a) Group 1 (normal): Showing normal histology of rat liver. (b) Group 2 (Positive control): N-Focal Necrosis, PTI-Extensive portal triad inflammation, CVC-Central vein congestion. (c) Group 3 (Standard): CVC-Central vein congestion, RH-Regenerating hepatocytes.(d) Group 4 (low dose HAECA) mild central vein dilation. (e) Group 5(High dose HAECA): MCD-Mild central vein dilation, VMI-Very mild inflammation



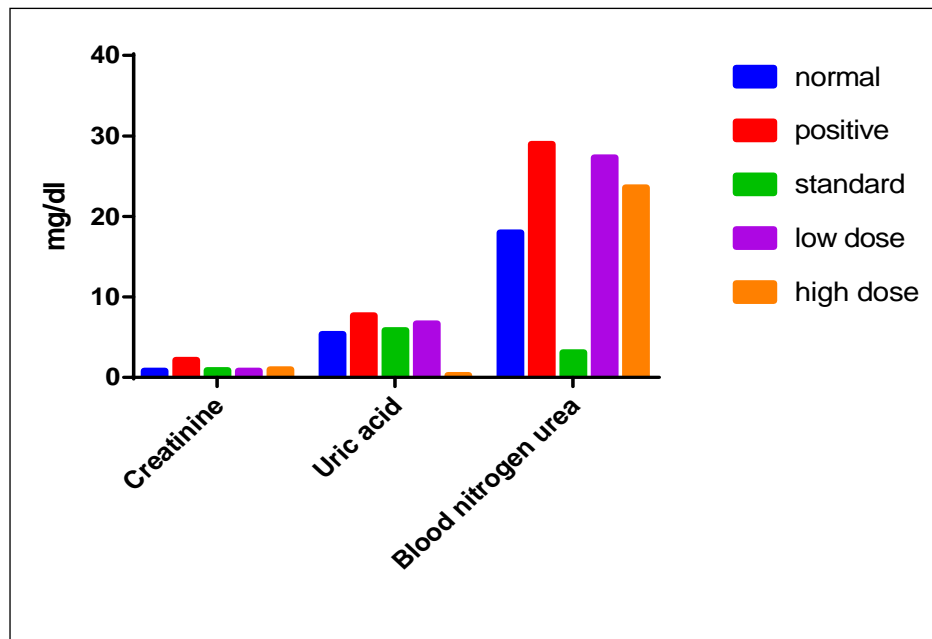
**Fig:2 Effects of HAECA on hepatic morphological analysis: control rat (A), Rifampicin-treated rat (B), rat pretreated with silymarin prior to rifampicin(C), rat pretreated with low dose HAECA (D), High dose of HAECA respectively prior to rifampicin.**

**Nephroprotective activity:**

Effect of extract of *Choerospondias axillaris* on renal markers in the serum of rifampicin induced nephrotoxicity in rats.

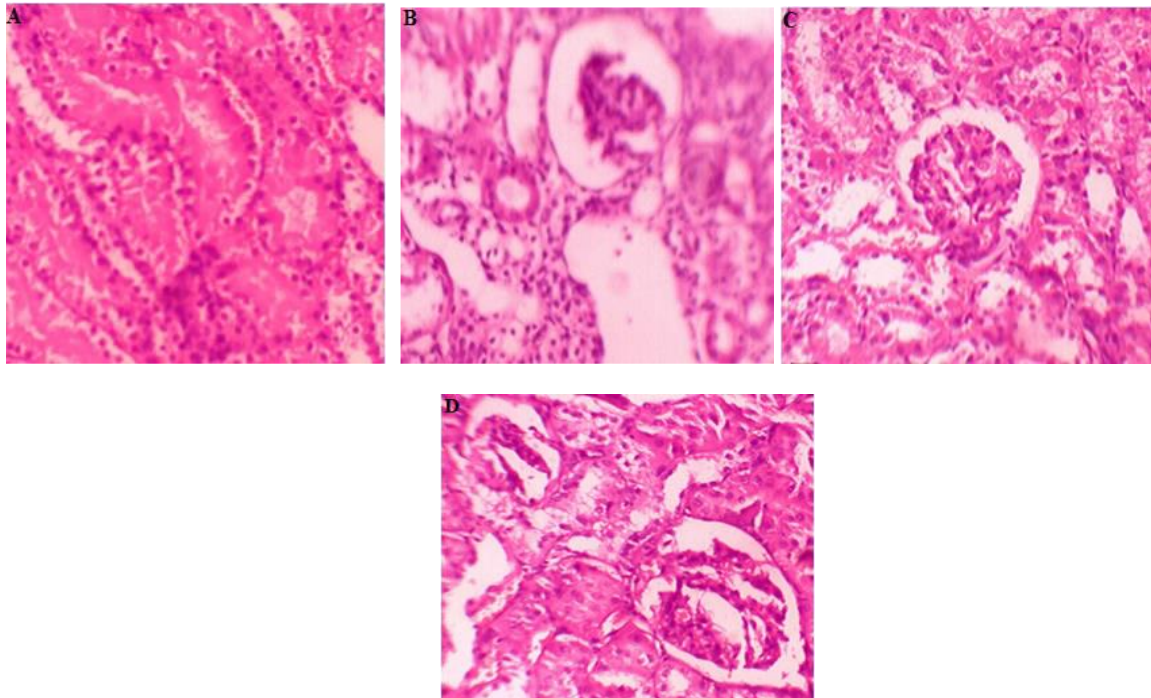
Table-3:

Group	Treatment	Creatinine (mg/dl)	BUN (mg/dl)	Uric acid (mg/dl)
1	Normal saline	0.81±0.0589	18±0.758	5.37±0.306
2	Positive control	2.16±0.419***	29.2±1.51	7.7±0.37***
3	Standard	0.895±0.0573***	23.1±1.36	5.86±0.3***
4	HAECA low dose	0.808±0.0433***	27.3±0.638	6.7±0.467ns
5	HAECA high dose	1±0.0432***	23.6±0.762	5.55±0.325**



**Figure 3:** Effect of Ethanolic extract of *Choerospondias axillaris* on serum Creatinine, Uric acid and Blood urea nitrogen in Rifampicin induced nephrotoxicity in rats.

#### Histopathological reports:



**Figure 4:** Effect of hydroalcoholic extract of fruits of *Choerospondias axillaris* on rifampicin induced nephrotoxicity in rats. A: Normal control; B: Treated with rifampicin (1g/kg, p.o.); C: standard Cystone ; D: Treated with *Choerospondias axillaris* (500 mg/kg).

Acknowledgements: The authors are thankful to Principal, Mallige College of Pharmacy, Bangalore for providing excellent laboratories facilities and his valuable guidance during this work

#### REFERENCES:

1. Sharma K. N. Hepatoprotective activity of some Medicinal Plants against paracetamol induced Liver damage in Rats. *Sodh ganga a reservoir of Indian thesis*, 2002-2013.
2. Nitin M., Ifthekar S.Q., Mumtaz M. et al. Evaluation of hepatoprotective and nephroprotective activity of aqueous extract of *Vigna mungo* (Linn.) Hepper on rifampicin-induced toxicity in albino rats. *Int J Health Allied Sci.* 2012;1:85-91
3. Capelle P, Dbumeaux D, Mora M. Effect of rifampicin on liver function in man. *Gut.* 1972; 13:366-71.
4. Fent K, Mayer E, Zbinden G. Nephrotoxicity screening in rats: a validation study. *Arch Toxicol.* 1988;61:349-58
5. Ramgopal V, Leonard C, Bhatena D. Acute renal failure associated with rifampicin. *Lancet.* 1973; 1:119: 5-6.
6. Wang H, Gao XD, Zhou GC, Cai L & Yao WB. In vitro and in vivo antioxidant activity of aqueous extract from *Choerospondias axillaris* fruit. *Food Chemistry.* 1 February 2008 ;106:3: 888–895
7. Pieta PG. Flavonoids as antioxidants. *Nat Prod.* 2000; 63:1035-42.
8. Nitin M., Ifthekar S.Q., Mumtaz M. et al. Evaluation of hepatoprotective and nephroprotective activity of aqueous extract of *Vigna mungo* (Linn.) Hepper on rifampicin-induced toxicity in albino rats. *Int J Health Allied Sci.* 2012;1:85-91