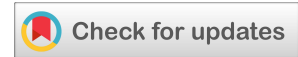

(RESEARCH ARTICLE)



Evaluation of demographic and rare clinical characteristics of patients with thoracic carcinoid tumor in Razi and Aria Hospitals of Rasht during 2006-2019

Manouchehr Aghajanzadeh ^{1,*}, Ali Alavi Foumani ², Azita Tangestaninejad ², Maryam Ahmad Khan Beige ³, Ehsan Hajipour Jafroudi ², Yousha Pourahmadi ³ and Mahsa Mousazadeh ³

¹ Department of Thoracic and general Surgery, Razi Hospital, Guilan University of Medical Sciences, Iran.

² Department of pulmonology, Razi Hospital, Guilan University of Medical Sciences, Iran.

³ Inflammatory Lung Diseases Research Center, Razi Hospital, Guilan University of Medical Science, Iran.

GSC Advanced Research and Reviews, 2022, 11(02), 050-056

Publication history: Received on 22 February 2022; revised on 29 March 2022; accepted on 31 March 2022

Article DOI: <https://doi.org/10.30574/gscarr.2022.11.2.0090>

Abstract

Introduction: Carcinoid tumors are malignant neoplasms of low-malignant neuroendocrine cells. This study tended to evaluate the demographic and rare clinical characteristics of patients with thoracic carcinoid tumor during 2006-2016 at Razi and Aria Hospitals in Rasht.

Materials and Methods: The present study was performed on records of 43 patients with lung carcinoid tumors referred to Razi and Aria Hospitals of Rasht during 2006-2019. Information on age, gender, rare clinical symptoms, smoking history, diagnosis tools, treatment and outcome were analyzed.

Results: Of the 43 patients treated with definitive diagnosis of carcinoid tumor pathology, 31 patients had typical carcinoid tumor and 12 patients had atypical carcinoma (mean age 43.14±15.16 years). The most common clinical symptom was cough and hemoptysis. Two cases presented with Cushing's syndrome. The most common diagnostic method in this study was simultaneous use of both CT scan and bronchoscopy. In 95.3% of cases, the tumor manifested as pulmonary and in 4.7% of cases it was extrapulmonary. Right lower lobe was the most common site of tumor involvement and lobectomy was the most frequent surgical procedure performed.

Conclusion: based upon our study the most common clinical sign of thoracic carcinoid was cough and the tumor was pulmonary in 95.3% of cases. Right lower lobe was the most common site of involvement and the most frequent surgical procedure performed was lobectomy. The outcome was good.

Keywords: Carcinoid tumor; Lung Carcinoid Tumor; Typical Carcinoid Tumor; Atypical Carcinoid Tumor; Extrapulmonary Tumor; Lobectomy

1. Introduction

The incidence of neuroendocrine tumors has been increasing in recent years [1]. Neuroendocrine tumors are uncommon, slow-growing neoplasms with incidence of 1-2 in 100,000 patients [2-4]. Carcinoid tumors were described first in 1882. In 1930, it was classified and designated as bronchial adenoma [5]. Carcinoid tumors originate from neuroendocrine cells and are slow-growing tumors [6]. In terms of embryology, carcinoid tumor originate from any part of the foregut, such as stomach, duodenum, gall bladder, and pancreas as well as from trachea, bronchus and lung [5]. Limited information is currently available on long-term clinical prognosis and prognostic factors of these tumors

* Corresponding author: Manouchehr Aghajanzadeh
Department of Thoracic and general Surgery, Guilan University of Medical Sciences, Iran.

[7]. The use of newer diagnostic techniques, including biochemical, immunohistochemical and molecular methods, has had a significant effect on identification, diversity of histopathological species, clinical behaviour and prognosis of these tumors. The new WHO classification, considering the biological behavior of tumors based on tumor location and differentiation rate, is useful both clinically and in terms of prognostic factors [8]. Neuroendocrine carcinoma is a neoplasm of the neuroendocrine system, which contains organs in which amine precursor uptake and decarboxylation (APUD) cells are uncommon. Neuroendocrine carcinoma has been found in a wide range of organs in humans and animals [9]. In animals, this carcinoma has been reported in the intestines, liver, bile ducts, lungs, gall bladder, esophagus, nasal cavity and skin [10, 11], most of which are highly invasive [14-11]. In the human body, the most common site of neuroendocrine carcinoma is the gastrointestinal tract and the lung [15, 9]. Bronchopulmonary carcinoid tumor comprises 1 to 2% of all malignant lung tumors. Surgery is the most effective treatment of all types of lung carcinoid tumors. Chemotherapy and radiotherapy have no effective role in the treatment of these tumors, although they are used in treatment of advanced carcinoid tumors [16]. Surgical treatment is not recommended in cases where the tumor is locally advanced and encounters adjacent vital structures [17]. Therefore, demographic and clinical characteristics can be helpful in diagnosis, treatment and evaluation of prognosis.

2. Material and methods

2.1. Population and Sampling

Participants included all patients with lung carcinoid tumors who were treated during 2006-2016 at Razi and Aria Hospitals of Rasht (Guilan University of Medical Sciences). Pathologic responses were obtained from Razi Laboratory, Sina Laboratory and Dr. Ashtiani Laboratory. In this study, all patients with lung carcinoid tumors who had undergone surgical treatment over the past 11 years (2006-2016) were evaluated.

2.2. Methods

In this retrospective cross-sectional study, all patients with lung carcinoid tumor who were treated during 2006-2016 at Razi and Aria Hospitals of Rasht (Guilan University of Medical Sciences) and in collaboration with the Sina, Razi, and Dr. Ashtiani's laboratories were examined. In this study, the exact type of tumor and all the corresponding information about the thoracic carcinoid tumor is based on pathology. The extracted data from each patient under study included age, gender, tumor location, metastatic status, tumor location, site of involvement, history of smoking, type of tumor (typic or atypic), resection type, diagnostic methods, signs and symptoms of the disease. Forms were designed as checklists to extract information. Non-probabilistic convenient sampling was used.

2.3. Data Analysis

The collected data was inserted into SPSS software version 22. Descriptive indices including frequency, frequency percentage, mean and standard deviation were used to report descriptive data. Independent-t test was used to determine the relationship between patient gender and age ($p < 0.05$).

2.4. Ethical Considerations

The information obtained from the patient files will be kept confidential and the results will be published in full in the form of information from the studied group and the results will be presented without mentioning their names and personal details. Written informed consent was obtained from all the patients participated in this study.

3. Results

3.1. Gender and Age

Of the 43 patients (39.5%), 17 were male and 26 (60.5%) were female. The mean age of the patients was 43.14 ± 15.16 years. Maximum and minimum age of the patients were 78 and 17 years, respectively. After dividing the age of the patients into 10-year groups, the majority of patients were in the age range of 31-40 years. The mean age of males was 44.82 ± 14.12 years and the mean age of females was 42.03 ± 15.97 years and there was no significant difference between males and females in terms of age ($p = 0.562$).

3.2. Diagnostic Methods

The most common diagnostic method in this study was simultaneous use of CT scan and bronchoscopy with 27 cases (62.8%), followed by bronchoscopy with 9 cases (20.9%) and CT scan with 7 cases (16.3%) (Figure 1).

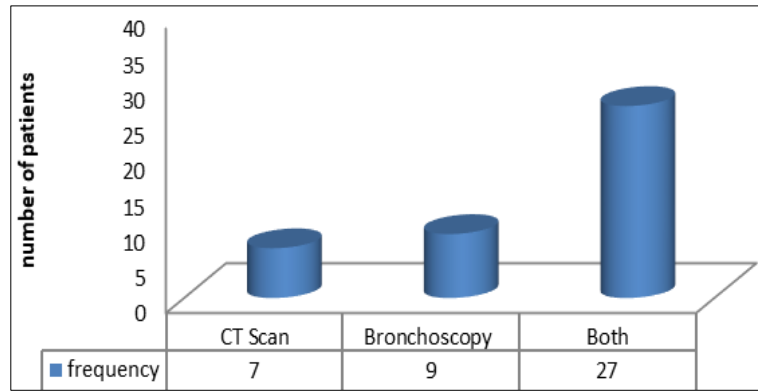


Figure 1 Frequency of diagnostic methods (X-axis depicts diagnostic methods and Y-axis shows percentage of patients)

3.3. Smoking and Symptoms

In this study, 9 patients (20.9%) were smokers, 32.4% (74.4%) had no history of smoking and (4.7%) had quit smoking (Figure 2). The most common symptoms observed in this study were cough, hemoptysis, as well as pneumonia, shortness of breath, fever, chest pain, sputum and Cushing's syndrome (Table 1)

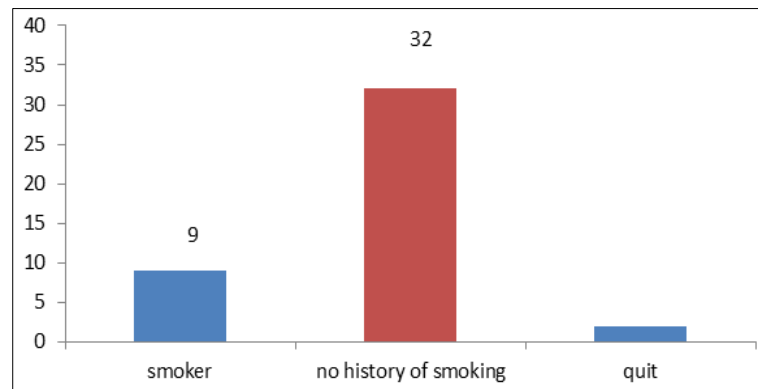


Figure 2 Frequency of smoking in patients (X-axis depicts smoking status and Y-axis shows the percentage of patients)

Table 1 Symptoms by frequency and percentage

Symptoms	N	%
Hemoptysis	36	83.7
Cough	37	86
Shortness of breath	10	23.3
Pneumonia	16	37.2
Chest pain	3	7
Fever	8	18.6
Sputum	2	4.7
Cushing's Syndrome	2	4.7

3.4. Location, Most Affected Site and Type of Tumor

Forty-one (95.3%) cases had pulmonary tumor and 2 (4.7%) cases had extrapulmonary tumor. The most frequent site of lung involvement was right lower lobe with 25.6% (Figure 3). Right lower lobe was the most frequently observed

tumor site (25.6%). There was no significant relationship between smoking and tumor site ($p = 0.511$) (Table 2). In 31 cases (72.1%), the tumor was typical and 12 cases (27.9%) had atypical tumor. There was no significant relationship between type of tumor and age ($p=0.127$). There was no significant relationship between smoking and type of tumor ($p=0.687$).

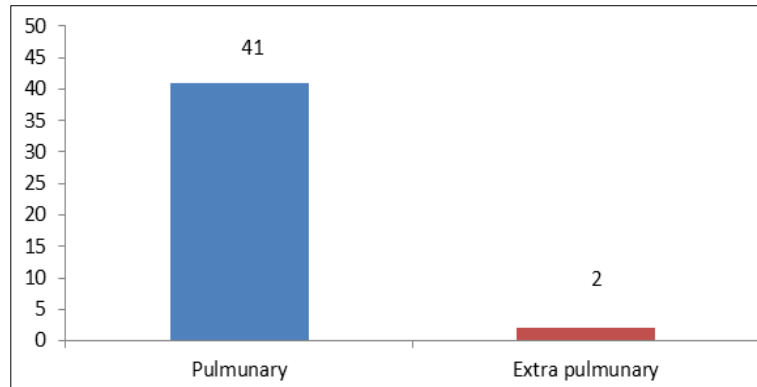


Figure 3 Frequency of tumor site in the studied patients (X-axis depicts tumor site and Y-axis shows percentage of patients)

Table 2 Site of involvement by frequency and percentage

Tumor site	N	%
Right Main Bronchus	7	16.3
Right Upper Lobe	6	14
Right Middle Lobe	2	4.7
Right Lower Lobe	11	25.6
Left Main Bronchus	4	9.3
Left Upper Lobe	5	11.6
Lingula	1	2.3
Left Lower Lobe	3	7
Carina Angle	2	4.7
Posterior Mediastinum	1	2.3
Thymus	1	2.3

3.5. Performed Surgeries

Table 3 Type of surgery by frequency and percentage

Type of surgery	N	%
Lobectomy	26	60.5
Pneumonectomy	4	9.3
Sleeve Resection	3	7
Segmental Resection	5	11.6
Lung Wedge Resection	3	7
Bilobectomy Resection	2	4.7

The most common surgeries included lobectomy (26 cases), followed by segmental resection, pneumonectomy, sleeve resection, lung wedge resection, and bilobectomy (Table 3).

In this study, 43 patients were studied, with 3 cases of recurrence in the atypic group which occurred within 1 and 5 years and one case in the typical group in year 8 undergoing surgical treatment of wedge resection. Ten year survival was observed in the typical form (90%) and in atypic type (60-70%). In recurrent cases, lobectomy or pneumonectomy was performed. There was one case of hospital mortality that occurred during surgery due to tumor aspiration and removal during manipulation, and the patient was not anesthetized with double lumen. The observed complication was atelectasis in 4 patients who recovered with physiotherapy. Air leaks were also observed in two patients who recovered spontaneously. The average length of hospital stay was 6 days.

4. Discussion

Lung carcinoid tumor originates from a specific group of bronchial epithelial cells that have neuroendocrine activity. Carcinoid tumors, despite their slow growth and slow progression, are considered malignant because they have the ability to invade surrounding tissues locally and metastases [18]. The preferred treatment for all types of carcinoid tumors is surgery, since chemotherapy and radiotherapy have little effect in treatment of this disease [19]. Of 43 patients studied, 17 (39.5%) were male and 26 (60.5%) were female. The mean age of the patients was 43.14±15.16 years. Maximum and minimum age of patients were 78 and 17 years, respectively. The majority of people were in the age range of 31-40 years. There was no significant difference between males and females in terms of age. The most common diagnostic method used in this study was simultaneous use of CT scan and bronchoscopy, followed by bronchoscopy and CT scan. Moreover, 20.9% of patients were smokers and most of the symptoms were cough, hemoptysis, and pneumonia, shortness of breath, fever, Chest pain, sputum and Cushing's syndrome, respectively. In 95.3% of the cases, the tumor was pulmonary and in 4.7% of the cases it was extrapulmonary. The most frequent site of lung involvement was in the right lower lobe with 25.6%. In 72.1% of cases, the tumor was typical and in 27.9% it was atypic. There was no significant relationship between tumor type and age. The most common performed surgery was lobectomy (26 cases), followed by segmental resection, pneumonectomy, sleeve resection, lung wedge resection, and bilobectomy resection.

Arab et al. [19] conducted a study in 2007 to evaluate clinical features, diagnostic and therapeutic practices on lung carcinoid tumors at Masih Daneshvari Hospital within 11 years (1997-2007). There was no statistically significant difference between male and female patients, which is consistent with the results of this study. The history of smoking in 14 patients (19.2%) was consistent with the results of our study. The most common clinical symptoms were hemoptysis and cough, which is consistent with the results of our study. The final pathologic response was typical carcinoid in 81.8% and atypic carcinoid in 12.1% and tumor was not found in 6.1%. With respect to the prevalence of typical carcinoid, it is consistent with our results. In another study, Ryan F et al evaluated the clinical and radiologic symptoms and treatment of patients with carcinoid tumor on records of 21 patients with lung carcinoid [20]. Of 21 patients treated with definitive diagnosis of carcinoid tumor pathology, 19 patients had typical carcinoid tumor and 2 patients had atypic carcinoma, which is consistent with our results. As Klöppel G et al reported, the right bronchus was most frequently involved [9]. This is contrary to the results reported by Fink et al. [21] and Anne Naalsund et al. [22] who introduced the right lobe, or Davila DG et al. [23] who reported the lower right and left lobes as the most affected sites. Surgery was the most common treatment in our study and lobectomy was performed more than pneumonectomy, which was similar to other studies [24-27]. Morandi et al. [28] reported in 2006 that carcinoid tumors had an equal prevalence between male and female patients and appeared to occur in women at a younger age than men (although this difference was not statistically significant). There was a history of smoking in 30% of patients with typical carcinoid and 60-80% of patients with atypic carcinoid, but there was no statistically significant difference, which is consistent with our results. Hence; the significance of diagnosis of this tumor lesion is that: First, due to slow tumor growth, and the presence of nonspecific symptoms including cough, shortness of breath and wheezing, it is sometimes confused with pulmonary disease and is treated with inhaled and systemic bronchodilators. Secondly, carcinoid tumor treatment is complete resection of the tumor through surgery. Thirdly, recurrence of the lesion is very low with timely surgical treatment. Therefore, this disease should be considered in patients with chronic cough, recurrent pneumonia, localized or even diffuse pneumonia, stridor, and hemoptysis [29].

5. Conclusion

According to the results of the present study, the majority of patients were in the age range of 31-40 years. There was no statistically significant difference between males and females in terms of age. The most common diagnostic methods applied in this study was simultaneous use of CT scan and bronchoscopy. The most common symptoms observed in this

study were cough and hemoptysis. In 95.3% of the cases, the tumor was pulmonary and in 4.7% of the cases it was manifested as extrapulmonary and the most frequent lung involvement site was the right lower lobe. In 72.1% of the cases it was typical and in 27.9% it was atypical tumor. There was no significant relationship between tumor type and age. The most common surgery was lobectomy (n=26), followed by segmental resection, pneumonectomy, sleeve resection, lung wedge resection and bilobectomy resection.

Compliance with ethical standards

Acknowledgments

We thank all the staff members from Thoracic surgery department of Razi and Aria Hospitals, who provided clinical and technical expertise that greatly assisted the present research. In addition, we express our special thank to the patients who consented to participate in our research.

Disclosure of conflict of interest

The authors declare no conflict of interest.

Statement of informed consent

Informed consent was obtained from all individual participants included in the study.

References

- [1] Kocha W, Maroun J, Kennecke H, Law C, Metrakos P, Ouellet JF, Reid R, Rowsell C, Shah A, Singh S, Van Uum S. Consensus recommendations for the diagnosis and management of well-differentiated gastroenterohepatic neuroendocrine tumours: a revised statement from a Canadian National Expert Group. *Current oncology*. 2010 Jun;17(3):49-64.
- [2] Durante C, Boukheris H, Dromain C, Duvillard P, Leboulleux S, Elias D, de Baere T, Malka D, Lumbroso J, Guigay J, Schlumberger M. Prognostic factors influencing survival from metastatic (stage IV) gastroenteropancreatic well-differentiated endocrine carcinoma. *Endocrine-related cancer*. 2009 Jun 1;16(2):585-97.
- [3] Rosenau J, Bahr MJ, von Wasielewski R, Mengel M, Schmidt HH, Nashan B, Lang H, Klempnauer J, Manns MP, Boeker KH. Ki67, E-cadherin, and p53 as prognostic indicators of long-term outcome after liver transplantation for metastatic neuroendocrine tumors. *Transplantation*. 2002 Feb 15;73(3):386-94.
- [4] Touzios JG, Kiely JM, Pitt SC, Rilling WS, Quebbeman EJ, Wilson SD, Pitt HA. Neuroendocrine hepatic metastases: does aggressive management improve survival?. *Annals of surgery*. 2005 May;241(5):776.
- [5] Roviario G, Varoli F, Romanelli A, Vergani C, Maciocco M. Complications of tracheal sleeve pneumonectomy: personal experience and overview of the literature. *The Journal of Thoracic and Cardiovascular Surgery*. 2001 Feb 1;121(2):234-40.
- [6] Marchevsky AM. Neuroendocrine tumors of the lung. *Surgical Pathology of Lung Neoplasms*. 1990:247-88.
- [7] Modlin IM, Sandor A. An analysis of 8305 cases of carcinoid tumors. *Cancer*. 1997 Feb 15;79(4):813-29.
- [8] Yoon SN, Yu CS, Shin US, Kim CW, Lim SB, Kim JC. Clinicopathological characteristics of rectal carcinoids. *International journal of colorectal disease*. 2010 Sep;25(9):1087-92.
- [9] Klöppel G, Perren A, Heitz PU. The gastroenteropancreatic neuroendocrine cell system and its tumors: the WHO classification. *Annals of the New York academy of sciences*. 2004 Apr;1014(1):13-27.
- [10] Kulke MH, Mayer RJ. Carcinoid tumors. *New England Journal of Medicine*. 1999 Mar 18;340(11):858-68.
- [11] Patnaik AK, Liu SK, Johnson GF. Feline intestinal adenocarcinoma: a clinicopathologic study of 22 cases. *Veterinary Pathology*. 1976 Jan;13(1):1-0.
- [12] Arnold R. Diagnosis and management of neuroendocrine tumors. *United Eur Gastroenterol Week—Neuroendocrine Tumors*. 2001;8:1-2.
- [13] Patnaik AK. Canine and feline nasal and paranasal neoplasms: morphology and origin. *Nasal tumors in animals and man*. 1983;2.

- [14] Patnaik AK. A morphologic and immunocytochemical study of hepatic neoplasms in cats. *Veterinary Pathology*. 1992 Sep;29(5):405-15.
- [15] Patnaik AK, Lieberman PH, Hurvitz AI, Johnson GF. Canine hepatic carcinoids. *Veterinary Pathology*. 1981 Jul;18(4):445-53.
- [16] Al-Khafaji B, Noffsinger AE, Miller MA, Devoe G, Stemmermann GN, Fenoglio-Preiser C. Immunohistologic analysis of gastrointestinal and pulmonary carcinoid tumors. *Human pathology*. 1998 Sep 1;29(9):992-9.
- [17] Naalsund A, Rostad H, Strøm EH, Lund MB, Strand TE. Carcinoid lung tumors–incidence, treatment and outcomes: a population-based study. *European journal of cardio-thoracic surgery*. 2011 Apr 1;39(4):565-9.
- [18] Srirajaskanthan R, Toumpanakis C, Karpathakis A, Marelli L, Quigley AM, Dusmet M, Meyer T, Caplin ME. Surgical management and palliative treatment in bronchial neuroendocrine tumours: a clinical study of 45 patients. *Lung Cancer*. 2009 Jul 1;65(1):68-73.
- [19] Arab M, Shadmehr M, Pezhan S, Farzanegan R, Javaherzadeh M, Daneshvar AG, Jahanshahi N, Abbasi AE. Bronchial Carcinoid Tumors-Evaluation of Our Experience in Diagnosis, Treatment and Results in the patients of Massih Daneshvari Hospital Between 1996-2007. *Iranian Journal of Surgery*. 2008 Feb;15(4):67-72
- [20] Herde RF, Kokeny KE, Reddy CB, Akerley WL, Hu N, Boltax JP, Hitchcock YJ. Primary pulmonary carcinoid tumor: a long-term single institution experience/Primary pulmonary carcinoid tumor. *American journal of clinical oncology*. 2018 Jan;41(1):24.
- [21] Fink G, Krelbaum T, Yellin A, Bendayan D, Saute M, Glazer M, Kramer MR. Pulmonary carcinoid: presentation, diagnosis, and outcome in 142 cases in Israel and review of 640 cases from the literature. *Chest*. 2001 Jun 1;119(6):1647-51.
- [22] Naalsund A, Rostad H, Strøm EH, Lund MB, Strand TE. Carcinoid lung tumors–incidence, treatment and outcomes: a population-based study. *European journal of cardio-thoracic surgery*. 2011 Apr 1;39(4):565-9.
- [23] DAVILA DG, DUNN WF, TAZELAAR HD, PAIROLERO PC. Bronchial carcinoid tumors. In *Mayo Clinic Proceedings* 1993 Aug 1 (Vol. 68, No. 8, pp. 795-803). Elsevier.
- [24] Ducreux M, Baudin E. Treatment strategy of neuroendocrine tumors, *Rev Prat*. 1 Feb 2002; 52 (3) 290-6.
- [25] Filosso PL, Rena O, Donati G, Casadio C, Ruffini E, Papalia E, Oliaro A, Maggi G. Bronchial carcinoid tumors: surgical management and long-term outcome. *The Journal of Thoracic and Cardiovascular Surgery*. 2002 Feb 1;123(2):303-9.
- [26] Divisi D, Crisci R. Carcinoid tumors of the lung and multimodal therapy. *The Thoracic and cardiovascular surgeon*. 2005 Jun;53(03):168-72.
- [27] Cañizares MÁ, García-Fontán EM, Rivo JE, Gonzalez-Piñeiro A. Local recurrence and metastatic disease in a typical N1 carcinoid bronchial tumour. *Clinical and Translational Oncology*. 2005 Jun;7(5):216-8.
- [28] Morandi U, Casali C, Rossi G. Bronchial typical carcinoid tumors. In *Seminars in thoracic and cardiovascular surgery* 2006 Sep 1 (Vol. 18, No. 3, pp. 191-198). WB Saunders.
- [29] Thomas R, Christopher DJ, Balamugesh T, Shah A. Clinico-pathologic study of pulmonary carcinoid tumours–A retrospective analysis and review of literature. *Respiratory medicine*. 2008 Nov 1;102(11):1611-4.