

# Case Report on Fibroid Uterus

1.Dr. Gupta Shubham Lalbabuprasad 1

2.Dr. Anita R. Gune 2

3.Dr. Pramod M Survase 2

4.Ms.Vedangi Pramod Patil 3

5.Ms.Shrishti Sharma 3

1.Dept of Medicine, D Y Patil Medical College ,Kolhapur ,Maharashtra

2.Associate Professor, Department of Anatomy, D.Y. Patil Medical College, D. Y. Patil Education Society (Deemed University), Kolhapur, Maharashtra, India

3.Consulting Obstetrician and Gynaecologist, Shalini Health Clinic,Mumbai

4.Final MBBS Student,D Y Patil Medical College ,Kolhapur ,Maharashtra

5.3<sup>rd</sup> MBBS Student ,Jawaharlal Nehru Medical College,Sawangi (Meghe) Wardha ,Maharashtra

**Abstract:- Uterine fibroids are benign monoclonal neoplasms that arise from the uterine wall's smooth muscle cells. They are common gynaecological tumours in reproductive-age women, although they are uncommon in adolescents. The smooth muscle layer of the uterus is where these tumours normally form. Alternative medical terms for fibroids tumours include leiomyoma . It can range in size . They can be quite large in some extreme circumstances. Because of the widespread use of high-frequency ultrasonography and magnetic resonance imaging for diagnostic purposes, it is now possible to detect such situations at an early stage. The extensive and well-established use of ultrasound in gynaecological clinics ensures that their diagnosis is not missed.Uterine fibroids tumours without symptoms are frequently left untreated. Uterus that have two or three tumours are known as giant fibroids. A solitary fibroid is the most common kind of this type of tumour. Giant uterine fibroid tumours are uncommon tumours and pose major diagnostic and prognostic difficulties for doctors and surgeons.**

**Keywords:-** Fibroid Uterus, Hysterectomy, Leiomyoma.

## I. INTRODUCTION

Leiomyoma, commonly known as fibroid tumours, are benign tumours that typically develop in the uterus.(1) Fibroid are typically much thicker than regular myometrium of the uterine wall, despite the fact that they are fundamentally formed of smooth muscle fibres, which are the structural fibres of the uterine wall. The majority of benign tumours are spherical in shape. They're most commonly discovered inside the uterus. Subserosal fibroids are uterine tumours that are positioned underneath the serosa, which is the membrane layer that surrounds the uterus. These fibroids are usually limited to the uterus's outer layer.(2) They are usually hard, well-defined whorled tumours that have been observed to occur in 70-80% of women prior to or during menopause. The incidence rises with age, and although it has been documented in teens on rare occasions, the specific cause of a leiomyoma is unknown.

Several risk factors have been identified.(3,4,5) Ovarian activity, genetic features, prenatal hormone

exposure, and growth factors may all predispose adolescents to the development of leiomyomata.(2,3,6) The majority of women diagnosed with leiomyoma are asymptomatic and do not require treatment. However, abnormal uterine bleeding is the most common sign in symptomatic patients, with excessive menstrual bleeding being the most common. Abdominal pain, dysmenorrhoea, pressure effect, spontaneous miscarriage, and infertility are some of the other symptoms.(4,5,6,7) Uterine fibroids with no symptoms are occasionally left untreated until a serious emergency scenario emerges.

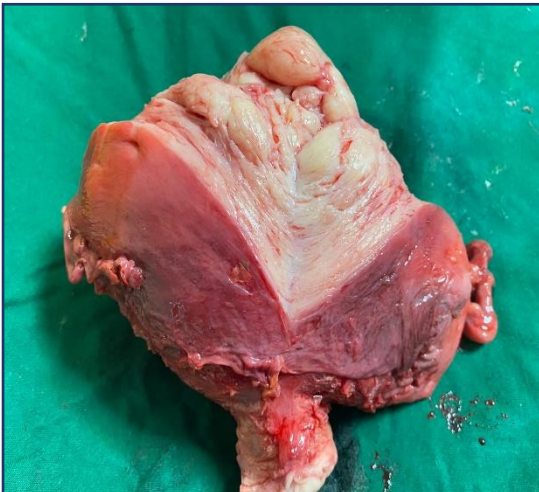Large uterine fibroids, on the other hand, can be difficult to remove since they grow into a massive fibroid mass.(8,9) Close observant ultrasonography examinations are required to identify quickly developing growth fibroids. Complications from extremely big myomas can include respiratory failure owing to diaphragmatic compression or an incarcerated abdominal wall hernia.(10,11)

## II. CASE PRESENTATION

A 22 years old girl ,P2L2 Non tubectomised ,presented the Gynaecology OPD with a painful mass in lower abdomen with gradual enlargement of abdomen for last 4 months. She had a clinical history of nausea, vomiting, weight loss, loss of appetite, pain in the lower abdomen, and intermittent constipation. Menarche occurred when she was 14 years old, and she had been experiencing monthly irregularities and menorrhagia for the previous four months. One year ago, the patient saw a tumour that was gradually growing in size. Her medical, surgical, and family histories had all been unremarkable. She was critically emaciated, anaemic, and had a huge movable abdominal mass that had expanded up to the umbilical region on physical examination. The lump was 13 weeks in size and non-tender on abdominal examination. A lump was felt in the right anterior fornix on pelvic examination, and the cervix was dilated to the left side. The uterus was bigger and more flexible on vaginal examination, and the cervix had an uneven surface and was dilated posteriorly.The raised diaphragm and acute anaemia were most likely to blame for her shortness of breath. Her haemoglobin concentration was 9.0 gm/dl.

Abdominal ultrasonography revealed a huge soft tissue mass arising from the uterine cavity, with partial cystic areas in various locations in the uterus. Mild Endometrial Collection was noted on USG. The results of her intravenous urography were normal. Total Abdominal Hysterectomy was performed after treating anaemia with 3 pint bags of packed cell. An abdominal incision was made in the

midline. The uterus was massively swollen, engulfing the entire abdomen. The uterus was attached to the sacrum posteriorly, occupying the whole pelvis with limited movement. The fallopian tubes and ovaries were not accessible. The resected specimen weighed approximately 3.5 kg. Histopathological report confirmed that it was leiomyoma uterus.



Figure/Picture: 1 :Fibroid uterus

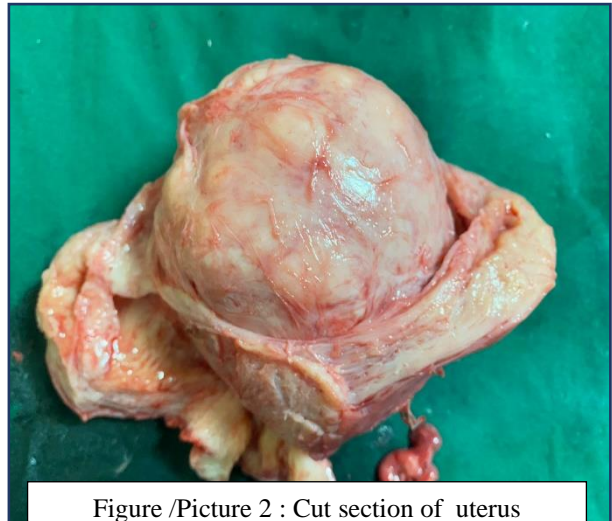


Figure /Picture 2 : Cut section of uterus showing circumscribed intramural fibroid

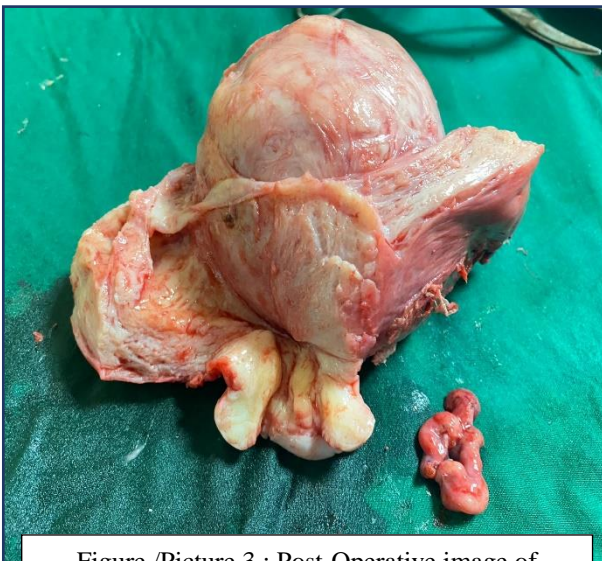


Figure /Picture 3 : Post-Operative image of enucleation of fibroid

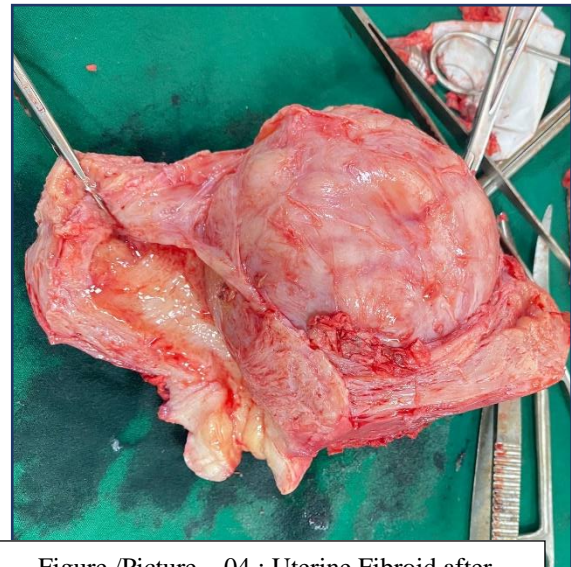


Figure /Picture – 04 : Uterine Fibroid after surgical excision

### III. DISCUSSION

The most frequent benign uterine tumour is leiomyoma/fibroma/fibroid, which is also the most prevalent reason for hysterectomy.(12) Physical examination is frequently used to diagnose them. Around one-third of women in the middle and late stages of their reproductive cycle have fibroids. The above-mentioned tumour weighed 3.5 kg. Fibroid uterine tumours are rather rare.(13) These fibroids frequently cause abnormal menstrual periods, pelvic pain, and pressure symptoms on nearby tissues and organs.

When the urinary bladder, ureters, and other nearby organs are subjected to pressure, they can be lethal in some situations. (14)

The actual cause of uterine fibroids has yet to be determined. However, cytogenetic and genetic investigations indicate that they are caused by somatic mutations in myometrial cells with chromosome 6,7,12, and 14 abnormalities. (15,16)Each fibroid is thought to come from a single muscle cell and is monoclonal in nature. The growth of these fibroids has been shown to be highly

dependent on ovarian hormones.(16) Fibroids have a robust blood supply, therefore abnormalities in uterine vasculature and angiogenic factors have been implicated. Black race, nulliparity, obesity, familial susceptibility, polycystic ovarian syndrome, diabetes, and hypertension are all known risk factors for uterine fibroids. (17)Being of the black race, having a positive first-degree relative with uterine fibroids, nulliparity, and being of reproductive age are all risk factors in this patient.(16,17) Intramural, sub-serous, sub-mucous, cervical, and intra-ligamentary fibroids are characterised by their anatomical location in the uterus.(16) Pedunculated or parasitic leiomyomas have an extrauterine blood supply, mainly from the omentum, and their pedicles have atrophy and resorption.(16,17)

Enlargement of the uterine cavity's surface area, congestion and dilatation of endometrial venous plexuses, imbalance in uterine prostaglandin production, and abnormalities in normal myometrial contractility are all possible processes by which fibroids might induce menorrhagia. (15) Patients with recto-sigmoid compression may also experience persistent pelvic discomfort, dysmenorrhoea, dyspareunia, pelvic pressure, urine symptoms, and, in rare cases, venous thrombosis, constipation, or intestinal obstruction.(15,16,17)

Ultrasound, which is utilised as a first diagnostic tool for myomas, is used to screen them. The accuracy of diagnosis, size, and position of these fibroids tumours, as well as differentiation from an adnexal mass, has greatly increased since the debut of MRI scan as a diagnostic tool. (18)However, MRI has been described as the most expensive technology used for analysing uterine fibroid. A computed tomography (CT) scan has also been used to assess fibroids tumours as a diagnostic characteristic. (19)However, because of the high likelihood of uterine problems such as necrosis and malignant transformation of benign fibroid tumours, using this along with higher instrument to examine instances of uterine fibroids is commonly suggested.(20) Uterine artery embolization, ablative treatments, expectant care, surgery, and medicinal management are all options for treating this fibroid.

Conservative, medicinal, or surgical treatment options are available. Patients who are asymptomatic are treated conservatively. This includes periodic explanations, reassurances, and re-examinations.(16) If anaemia is discovered in symptomatic cases of menorrhagia, it should be treated, like done in our case. Menorrhagia can be treated with tranexamic acid, combined oral contraceptives, or a levonorgestrel-releasing intrauterine device.(15,16) Prescription of a gonadotropin-releasing hormone analogue, which has been used to limit oestrogen production and, as a result, reduces the mass of existing fibroids, making them suitable for laparoscopic surgery.(21) In order to maintain productiveness and menstrual function in young female patients, proper counselling and the possibility of myomectomy is recommended in patients with symptomatic fibroids as well as those with large, asymptomatic fibroids. Females who want to keep their fertility and uterus should have their treatment focused on improving symptom alleviation and quality of life.(22) The primary technical

hazard of surgical excision of big uterine fibroids is the risk of substantial blood loss, notably due to enhanced vascularity of the tumours. There could be other technical concerns, which could raise the risk of ureter injury.(23) Myomectomy can be performed either open or endoscopically (laparoscopy, hysteroscopy). The surgical approach used is determined by the patient's age, the size of the fibroid, the severity of the symptoms, the desire for fertility, and the surgeon's skill.(16,24) Surgical management methods such as hysterectomy, uterine artery embolization, and ablation procedures are only available to women who have had their children as in our case.

#### IV. CONCLUSION

Clinicians are frequently perplexed by the appearance of fibroids. As demonstrated in this case, a fibroid can develop to be rather enormous. In young women who complain of stomach pain and pelvic bulk, uterine fibroids should be investigated. The surgical treatments used to treat uterine fibroids in this age range should have the specific goal of preserving the fertility of the young female patient. For future counselling and effective management of patients, a precise investigation of the genesis of uterine fibroids in this age group is critical.

#### REFERENCES

- [1.] Stewart EA. Uterine fibroids. *The Lancet*. 2001;357(9252):293-8.
- [2.] Reynolds A. Diagnosis and management of uterine fibroids. *Radiologic Technology*. 2007;79(2):157-78.
- [3.] Kumura DS, Siarezi S. A Case of a Prolapsed Fibroid in a 12-Year-Old. *Journal of Pediatric and Adolescent Gynecology*. 2019; doi: 10.1016/j.jpag.2019.08.013 5.
- [4.] Khan AT, Shehmar M, Gupta JK. Uterine fibroids: current perspectives. *International Journal of Women's Health* 2014;6(1):95-114.
- [5.] Parker WH. Etiology, symptomatology, and diagnosis of uterine myomas. *Fertil Steril*. 2007; 87(4):725–36.
- [6.] Kayadibi Y, Ozmen E, Emir H, Emre S, Dervisoglu S, Adaletli I. Subserosal leiomyoma of uterus mimicking an ovarian tumour in adolescent patient. *Japanese Journal of Radiology* 2013; 32(1):48–52.
- [7.] Duhan N, Sirohiwal D. Uterine myomas revisited. *Eur J Obstet Gynecol Reprod Biol*. 2010;152(2):119-25.
- [8.] Sterling KM, Vogelzang RL, Chrisman HB, WorthingtonKirsch RL, Machan LS, Goodwin SC, Andrews RT, Hovsepian DM, Smith SJ, Bonn J. V. Uterine fibroid embolization: management of complications. *Techniques in vascular and interventional radiology*. 2002;5(1):56-66.
- [9.] Evans P, Brunsell S. Uterine fibroid tumors: diagnosis and treatment. *American Family Physician*. 2007;75(10).
- [10.] Oelsner G, et al. Giant uterine tumors: two cases with different clinical presentations. *Obstet Gynecol*. 2003;101(5 Pt 2):1088–91.
- [11.] Exarchos G, et al. Incarcerated giant uterine leiomyoma within an incisional hernia: a case report. *Clin Case Rep*. 2017;5(11):1837–40



- [12.] Gupta S, Manyonda IT. Acute complications of fibroids. *Best Practice & Research Clinical: Obstetrics & Gynaecology*. 2009;23(5):609-17.
- [13.] Hillard PJ. 14 Benign Diseases of the Female Reproductive Tract. *Berek & Novak's gynecology*. 2007:431.
- [14.] Gupta S, Jose J, Manyonda I. Clinical presentation of fibroids. *Best Practice & Research Clinical: Obstetrics & Gynaecology*. 2008;22(4):615-26.
- [15.] Van den Bosch T. Benign disease of the uterus. In: Edmonds DK, Lees C, Bourn T, eds. *Dewhurst's Textbook of Obstetrics and Gynaecology*, 9th edition. Oxford; Wiley-Blackwell Publishing Inc. 2018. p. 823-834.
- [16.] Kwawukume EY, Ekele BA, Danso KA, Emuveyan EE. Editors. *Comprehensive Gynaecology in the Tropics*. Accra: G-pak Limited: 2017; p. 173-186.
- [17.] Bizjak T, Bečić A, But I. Prevalence and Risk Factors of Uterine Fibroids in North-East Slovenia. *Gynecol Obstet (Sunnyvale)* 2016;6:350. doi:10.4172/2161-0932.1000350.
- [18.] Pritts EA. Fibroids and infertility: a systematic review of the evidence. *Obstetrical & Gynecological Survey*. 2001;56(8):483-91.
- [19.] McLucas B. Diagnosis, imaging and anatomical classification of uterine fibroids. *Best Practice & Research Clinical Obstetrics & Gynaecology*. 2008;22(4):627-42.
- [20.] Khan AT, Shehmar M, Gupta JK. Uterine fibroids: current perspectives. *International Journal of Women's Health*. 2014;6:95.
- [21.] Goetsch AL, Kimelman D, Woodruff TK. *Fertility preservation and restoration for patients with complex medical conditions*. Springer; 2017.
- [22.] Vilos GA, Allaire C, Laberge PY, Leyland N, Vilos AG, Murji A, Chen I. The management of uterine leiomyomas. *Journal of Obstetrics and Gynaecology Canada*. 2015; 37(2): 157-78
- [23.] Rovio P. *Uterine leiomyomas-Studies on Etiology, Ultrasound Diagnostics and Surgical Treatment*. Tampere University Press; 2008
- [24.] Ernest A, Mwakalebela A, Mpondo BC. Uterine leiomyoma in a 19-year-old girl: Case report and literature review. *Mal. Med J*. 2016;28(1):31-3