

## Intraocular foreign bodies: A major public health problem

Professor Dr GHEDJATI Nadir<sup>1</sup>

Department of Ophthalmology  
Faculty of Medicine Ouargla  
Algeria

### Abstract

**Introduction:** Intraocular foreign bodies are a major public health problem due to their frequency, their severity and their difficult and costly management. They mainly affect young men in the midst of professional activity and have serious social and medico-legal consequences.

**Case presentation:** We report the case of a 34-year-old patient, who suffered a contusive eye trauma with palpebral tearing of the left eye by barbed wire. The initial ophthalmologic examination found a preserved visual acuity, a transfixing eyelid injury with skin substance loss, a temporal conjunctival injury with hemorrhage and resulting from orbital fat. An orbital x-ray showed the radiopaque foreign bodies with no orbital fracture. The oculo-orbital CT scan was normal. The V3M fundus revealed, on the postoperative day, a small pre-retinal brownish formation, measuring 0.2 mm, located ½ papillary diameter from the center of the fovea, without retinal alteration in front of, and without peripheral retinal lesions. Optical coherence tomography (OCT) showed a small hyperdense infra-millimeter formation, a retinal invasion limited to the fiber optic layer with posterior shadow cone. The patient was put on corticosteroid and antibiotic therapy. Regarding the foreign body, the decision to abstain from treatment has been taken.

**Discussion:** The decision to remove a missed retained intraocular foreign body is complex and depends on multiple factors, including surgical difficulty and the composition, size, and location of the retained foreign body. Removal should be weighed against the possible serious complications of intraocular surgery. If removal is surgically difficult, or the retained material is inert, patients can be managed conservatively with regular monitoring, as in our case.

**Conclusion:** Any traumatic element should be investigated to search an intraocular foreign body, by a careful examination, even if imaging is normal. The indications to operate in emergency are well codified.

**Keywords:** Intraocular foreign bodies, public health problem, brownish formation, retinal invasion, abstain

### Introduction

The intraocular foreign bodies (IOFBs) are a major public health problem ; due to their frequency, their severity and their difficult and costly management. They mainly affect the young man in full period of professional activity, and they entail serious social and medico-legal consequences. If the IOFB is toxic, it should be removed as soon as possible. However, if

the IOFB is inert, it may be managed conservatively with regular monitoring [1].

### Case Presentation

A 34-year-old man, with no known medical illness, experienced a workplace accident. Upon arrival at the hospital, there was a left eyelid injury with no other injury. Ophthalmological examination showed a good

---

<sup>1</sup> Department of Ophthalmology  
Faculty of Medicine Ouargla  
Algeria  
Corresponding: nadirghedjati@hotmail.com

visual acuity in each eye (10/10), with transfixing eyelid injury, skin substance loss, temporal conjunctival injury, sub-conjunctival hemorrhage, and orbital fat issue. Fundus examination was difficult. An orbital radiography showed no IOFB, with no orbital fracture (Figure 1). An orbital scan was normal (Figure 2).

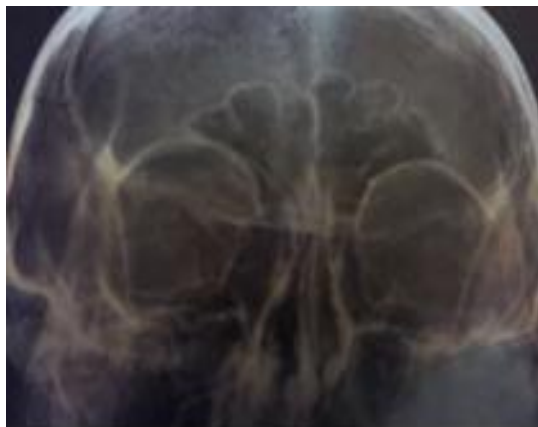

Figure 1. Orbital radiography : normal

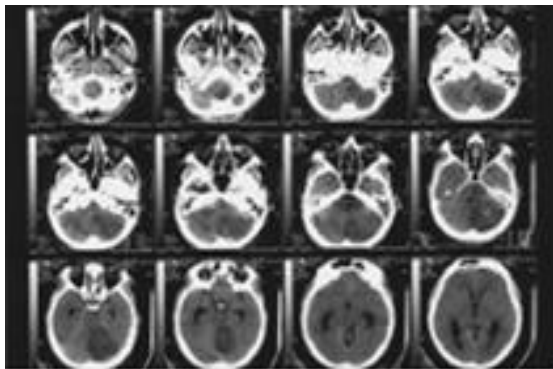


Figure 2. Orbital scan : normal.

On 1 day postoperative (surgical conjunctival exploration), a fundus examination showed a small preretinal brownish lesion, measuring 0.2 mm, located at ½ papillary diameter from the center of the fovea, without in front of and peripheral retinal alteration (Figure 3).

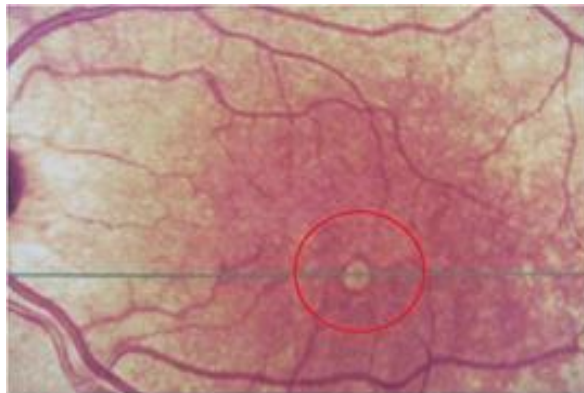


Figure 3. Fundus exam: small preretinal brownish lesion.

Optical coherence tomography (OCT) revealed an infra-millimeter hyperreflective lesion, retinal intrusion limited to the fiber optic layer, and posterior shadow cone (Figure 4). Electro-retinogram (ERG) was normal in both eyes.

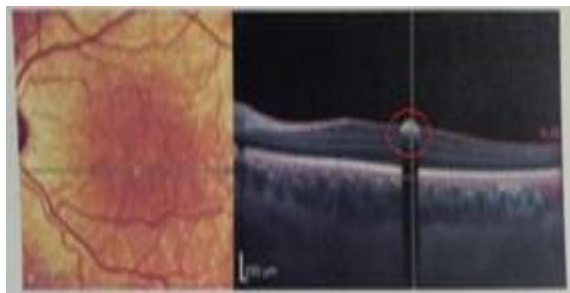


Figure 4. Optical coherence tomography : Infra-millimeter hyperreflective lesion.

The patient was treated conservatively as there was no active inflammation, and the rest of the retina was normal. On subsequent visits, his vision remained good, and there was no sign of inflammation.

## Discussion

Intraocular foreign bodies (IOFBs) can be broadly classified as composed of organic and inorganic materials, with the latter including metals, glass, and plastics. They are also classified as inert or toxic [2]. Following direct mechanical damage, caused by the passage of the foreign body through the ocular tissue, any subsequent complications are influenced by the

composition of the IOFB [3]. Compared with inert IOFBs such as glass, higher rates of endophthalmitis have been observed in patients with organic IOFBs, and higher rates of metallosis in patients with metallic IOFBs [4]. Other complications include secondary glaucoma, retinal detachment, proliferative vitreoretinopathy, and sympathetic ophthalmia [5]. The present patient was treated conservatively, because of many reasons :

- Patient vision remained good : 10/10 R2.
- There was no sign of inflammation : Inert.
- IOFB size : infra-millimeter.
- IOFB location : juxta-foveolar.
- The rest of the retina was normal.

### **Conclusion**

The decision to remove a missed retained IOFB is complex and depends on multiple factors, including surgical difficulty and the composition, size, and location of the retained foreign body. Removal should be weighed against the possible serious complications of intraocular surgery. If removal is surgically difficult, or the retained material is inert, patients can be managed conservatively with regular monitoring.

### **Patient consent**

Patient consent was obtained previously.

### **Conflict of interest**

" No conflict of interest ".

### **Funding**

" No external funding "

### **References**

1. Omoti AE, Dawodo OA, Ogbeide OU. An unusual case of marble intraocular foreign body. *Middle East Afr J Ophthalmol.* 2008, 15 : 39-42.
2. Ng T, Goh P. A patient with an Inert Intraocular Foreign Body. *Cureus* 2019, 11 (9) : e5737.
3. Dhoble PY, Velis GB, Sivakaumar P. Encapsulated metallic intraocular foreign body of long duration presenting with cystoid macular edema and normal full-field electroretinogram. *Oman J Ophthalmol.* 2019, 12 : 50-52.
4. Loporchio D, Mukkamala L, Gorukanti K, Zarbin M, Langer P, Bhagat N. Intraocular foreign bodies : a review. *Surv Ophthalmol.* 2016, 61 : 582-596.
5. Caciula D, Gavris M, Tamasoi I. Penetrating corneal wound with traumatic cataract and intraocular foreign body-case report. *Rom J Ophthalmol.* 2017, 61 : 54-59.