












Chest CT Findings (COVID-19), Analysis of 200 Cases (Postmortem)

Nematollah Nematollahi¹ , Mohammad Reza Mohammadi^{2*} , Mohammad Ali Vakili³ ,
Asieh Sadat Baniaghil⁴ , Maryam Ghelichli⁵ , Mohammad Javad Najafi⁶ ,
Atousa Mortazavi Milani⁶ , Amir Hossein Ghadirian⁶ , Fatemeh Shahrokhi⁶ ,
Hasan Khorshah⁷ , Sepide Sadat Hosseini⁸ 

1. Dept. of Radiology, School of Medicine, 5Azar Hospital, Golestan University of Medical Sciences, Gorgan, Iran
2. Dept. of Neurosurgery, School of Medicine, 5Azar Hospital, Golestan University of Medical Sciences, Gorgan, Iran
3. Dept. of Biostatistics and Epidemiology, School of Medicine, Golestan University of Medical Sciences, Gorgan, Iran
4. Dept. of Midwifery, School of Nursing and Midwifery, Golestan University of Medical Sciences, Gorgan, Iran
5. Dept. of Oral and Maxillofacial Pathology, School of Dentistry, Golestan University of Medical Sciences, Gorgan, Iran
6. School of Medicine, 5Azar Hospital, Golestan University of Medical Sciences, Gorgan, Iran
7. Dept. of Statistics, 5Azar Hospital, Golestan University of Medical Sciences, Gorgan, Iran
8. Dept. of Education, 5Azar Hospital, Golestan University of Medical Sciences, Gorgan, Iran

Article Info

 [10.30699/jambs.30.140.241](https://doi.org/10.30699/jambs.30.140.241)

Received: 2021/04/13;

Accepted: 2021/10/25;

Published Online: 01 Apr 2022;

Use your device to scan and read the article online



Corresponding Information:
Mohammad Reza Mohammadi,
Dept. of Neurosurgery, School of Medicine, 5Azar Hospital, Golestan University of Medical Sciences, Gorgan, Iran
E-Mail: dr.mmohamadi@goums.ac.ir

ABSTRACT

Background & Objective: COVID-19 was first seen in Wuhan-China in December 2019, and became a widely- spreadepidemic and caused a terrifying life-threatening problem in most societies of the world. In Iran, a declaration was made on January 20, 2020, and all health systems were alerted of the disease threats.

Materials & Methods: We collected all chest CT scans of 200 cases diagnosed as COVID-19 who died in 22 hospitals of Golestan Province, Iran. All data were collected in a designed checklist, then statistical evaluation was made using descriptive analysis and Chi-Square test.

Results: The most frequent complaints in patients were dyspnea (38.5%), fever (15%), and dry cough (13%). Hypertension (22.5%), Heart disease (18.5%), and diabetes (15%) were present as underlying diseases. CT scan findings showed Ground Glass Opacity (96%), consolidation (44%), pleural effusion (26.5%), crazy paving (15%), and cardiomegaly (15.5%).

Conclusion: Based on this study, hypertension as an underlying disease was significantly related to Highly Suggestive CT scans. No relation was found between cardiomegaly and death under 48 hours. Our findings Showed Ground Glass Opacity (GGO) in 192 (96%), consolidation in 88 (44%), crazy paving in 30 (15%), cardiomegaly in 30 (15%), and pleural effusion in 53 (26.5%) cases.

Keywords: Ground Glass Opacity, Cardiomegaly, CT Findings, COVID-19



Copyright © 2022. This is an original open-access article distributed under the terms of the Creative Commons Attribution-noncommercial 4.0 International License which permits copy and redistribution of the material just in noncommercial usages with proper citation.

Introduction

December 2019 was the beginning point in time of a very contagious viral disease (–entitled COVID-19 by WHO) in Wuhan, China. An infection that causes acute lower pulmonary tract involvement leading to superimposed septicity. There are many cases with subtle clinical symptoms and milder manifestations but can spread via airborne droplets to others and eventually kill them (1, 2). After the COVID-19 outbreak declaration in Golestan-Iran with a population near 1900000, on January 20, 2020, many patients were referred to the Emergency Departments of 22 hospitals in Golestan Province, Iran.

Unfortunately, some were in bad condition and died with the consequences of acute viral respiratory syndrome. Because of the limitation of access to rRT-PCR kits) due to sanctions, clinical diagnosis was made as per WHO and Ministry of Health guidelines (2).

Materials and Methods

All cases in this study underwent CT scans, and some had rRT-PCR documents and other paraclinical data. PCR samples were gathered and sent to the Virology Department of Golestan University of Medical Sciences (GOUMS). We collected all chest CT scans of 200 cases

diagnosed as COVID-19 who had died in 22 hospitals of Golestan Province and stored them in a separate PACS system. All CT scans were stored in a specific PACS system. A radiologist reported all scans regardless of their initial reports for confirming the diagnosis and transferring data to the checklist provided previously. All scans were reported by a second radiologist again for confirming the diagnosis. Performing CT scans as a valid test even before RT-PCR becomes positive is time-saving and necessary for admission and starting medical care (3, 4).

This study is derived from a research study (Recording Mortality COVID-19 in Golestan-Iran) approved by the deputy Research of GOUMS and the Medical Ethics Committee (Code: IR.GOUMS.REC.1398.390). A cross-sectional study was carried out on 200 cases who died with COVID-19 acute respiratory syndrome in Golestan (North of Iran). All cases had undergone lung CT scans performed through the standard technique with 3 mm thickness and without a gap in supine and no contrast use. Underlying diseases and medical history were obtained from hospital records HIS (Hospital Information System), and PACS (Picture Archiving and Communication

System). Statistical evaluation was made using descriptive analysis and the Chi-Square test. The data analysis was performed using SPSS version 16 (SPSS Inc., IL, USA). The significance level was less than 0.05.

Results

Our cases had mean and standard deviation (SD) age of 64.5 ± 13.57 years, and median of 65, (minimum age 25, maximum 94). After admission 23.6% died before 48 hours, 51.5% in 3-7 days, and 24.9% after 7 days.

In our study 52.5% of the cases were male, and 47.5% female; the mean age was 64.5 ± 13.57 years. No difference was observed between those who were under 70 years of age and those who were over 70. 23.6% of cases died in the first 48 hours after admission, which could be due to advanced disease or late reference.

Acute symptoms of cases referred to Emergency room were dyspnea (38%), fever (15%), dry cough (13%), myalgia (9%), nausea and vomiting (3.5%), runny nose (1%). Initial symptoms are presented in [Table 1](#).

Table 1. Initial Symptoms

		Male		Female		Total	
		Count	%	Count	%	Count	%
Runny Nose	Yes	2	1.90	0	0.00	2	1.00
	No	103	98.10	95	100.00	198	99.00
Body Pain	Yes	10	9.52	8	8.42	18	9.00
	No	95	90.48	87	91.58	182	91.00
Cough	Yes	12	11.43	14	14.74	26	13.00
	No	93	88.57	81	85.26	174	87.00
Dyspnea	Yes	36	34.29	41	43.16	77	38.50
	No	69	65.71	54	56.84	123	61.50
Nausea and Vomiting	Yes	4	3.81	3	3.16	7	3.50
	No	101	96.19	92	96.84	193	96.50
Diarrhea	Yes	0	0.00	0	0.00	0	0.00
	No	105	100.00	95	100.00	200	100.00
Hemoptysis	Yes	0	0.00	0	0.00	0	0.00
	No	105	100.00	95	100.00	200	100.00
Fever	Yes	15	14.29	15	15.79	30	15.00
	No	90	85.71	80	84.21	170	85.00
Sore Throat	Yes	0	0.00	0	0.00	0	0.00
	No	105	100.00	95	100.00	200	100.00
Other	No	100	95.24	90	94.74	190	95.00
	Yes	5	4.76	5	5.26	10	5.00

One hundred cases had no specific symptoms, 25.5% had only one symptom, 19.5% had two, 4.5% had three and 0.5% had four of above symptoms. We had no gastrointestinal and hemoptysis complaints.

Severity of involvement of lung lobes was scored 0-4, (no lobar involvement=0, <25%=1, 25%-50%=2, 50% -

75%=3, >75%=4). Right lower lobe (RLL) was involved in 69%, Left lower lobe (LLL) in 64%, left upper lobe (LUL) in 50%, and Right upper lobe (RUL) in 47.5%. 13.5% of cases had no Right middle lobe (RML) involvement. (Table 2).

Table 2. The severity of Lobar Involvement

		Male		Female		Total	
		Count	%	Count	%	Count	%
RUL	Score 0	6	5.71	6	6.32	12	6.00
	Score 1&2	41	39.05	52	54.74	93	46.50
	Score 3&4	58	55.24	37	38.95	95	47.50
RML	Score 0	14	13.33	13	13.68	27	13.50
	Score 1&2	56	53.33	60	63.16	116	58.00
	Score 3&4	35	33.33	22	23.16	57	28.50
RLL	Score 0	4	3.81	4	4.21	8	4.00
	Score 1&2	22	20.95	32	33.68	54	27.00
	Score 3&4	79	75.24	59	62.11	138	69.00
LUL	Score 0	5	4.76	5	5.26	10	5.00
	Score 1&2	43	40.95	47	49.47	90	45.00
	Score 3&4	57	54.29	43	45.26	100	50.00
LLL	Score 0	2	1.90	4	4.21	6	3.00
	Score 1&2	31	29.52	35	36.84	66	33.00
	Score 3&4	72	68.57	56	58.95	128	64.00

RUL: Right upper lobe
RML; Right middle lobe
RLL: Right lower lobe
LUL: left upper lobe
LLL: Left lower lobe.

Underlying diseases found were hypertension in 45 (22.5%), history of heart problem in 39 (18.5%), diabetes in 30 (15%), renal disease or on dialysis in 10 (5%), malignancy or on chemotherapy in 8(4%), lung disease, asthma and COPD in 6 (3%), nervous disease and seizure in 5 (2.8%), Body Mass Index

(BMI) > 40 in1 (0.5%), no liver disease, other diseases in 10(5%) cases. 110 (55%) Patients had no underlying disease, and 90(45%) had at least one underlying disease.

Underlying diseases are presented in Table 3.

Table 3. Underlying Diseases

		Male		Female		Total	
		Count	%	Count	%	Count	%
History of hypertension	No	83	79.05	72	75.79	155	77.50
	Yes	22	20.95	23	24.21	45	22.50

		Male		Female		Total	
		Count	%	Count	%	Count	%
History of heart disease	No	90	85.71	73	76.84	163	81.50
	Yes	15	14.29	22	23.16	37	18.50
History of diabetes	No	97	92.38	73	76.84	170	85.00
	Yes	8	7.62	22	23.16	30	15.00
History of kidney disease or dialysis	No	99	94.29	91	95.79	190	95.00
	Yes	6	5.71	4	4.21	10	5.00
History of Malignancy or Chemotherapy	No	102	97.14	90	94.74	192	96.00
	Yes	3	2.86	5	5.26	8	4.00
History of lung disease , asthma ,or COPD	No	104	99.05	90	94.74	194	97.00
	Yes	1	0.95	5	5.26	6	3.00
History of nervous disease/seizure	No	102	97.14	93	97.89	195	97.50
	Yes	3	2.86	2	2.11	5	2.50
BMI > 40	No	105	100.00	94	98.95	199	99.50
	Yes	0	0.00	1	1.05	1	0.50
History of liver disease	No	105	100.00	95	100.00	200	100.00
	Yes	0	0.00	0	0.00	0	0.00
Other	No	100	95.24	90	94.74	190	95.00
	Yes	5	4.76	5	5.26	10	5.00

BMI: Body Mass Index.

All CT scans had been collected from 22 hospitals in a separate database PACS; Reports were transferred to the checklist. CT scans were categorized as Highly Suggestive in 171 (85%), Indeterminate in 20 (10%), and Inconsistent in 9 (4.5%) cases. ([Figure 1](#)).

Lungs were involved bilaterally in 196 (98%), and unilaterally in 4 (2%) cases. The other results were as follows: Ground Glass Opacity (GGO) 192 (96%),

consolidation 88 (44%), crazy paving 30 (15%), cardiomegaly 30 (15%), pleural effusion 53 (26.5%), pericardial effusion 7 (3.5%), significant lymphadenopathy (LAP) (>1 cm diameter) 7 (3.5%), bronchiectasis 7 (3.5%), emphysema 5 (2.5%), intrathoracic mass 5 (2.5%), fibrosis 4 (2%), cavity formation 3 (1.5%), and pneumothorax 3 (1.5%). No reverse halo was seen. GGO and consolidation together was seen in 83 (41.5%) cases. ([Table 4](#))

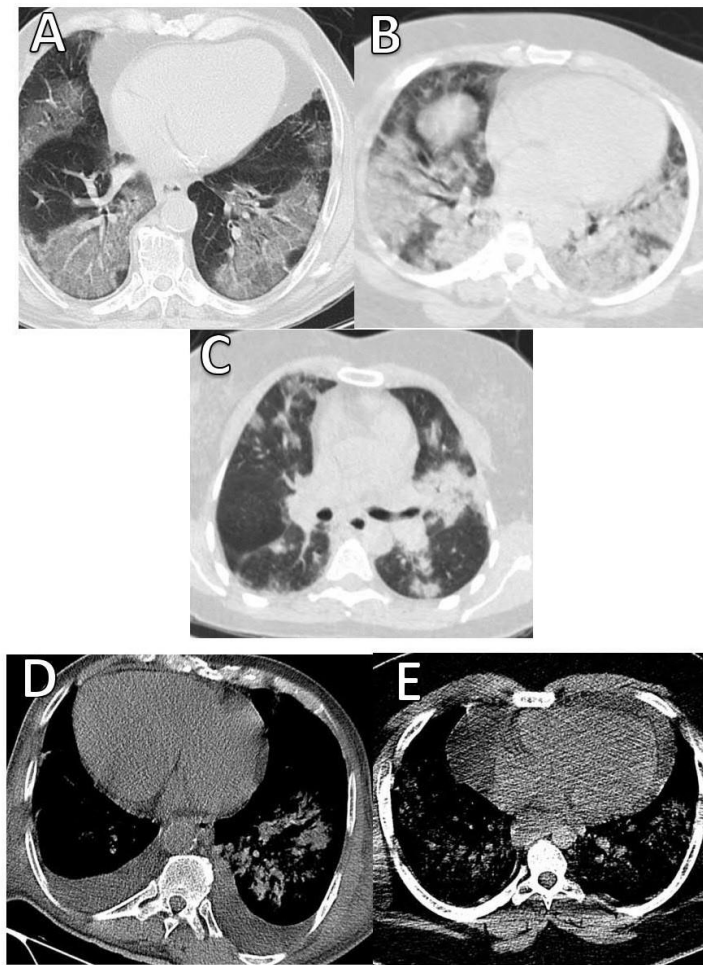


Figure 1. Chest radiography and CT imaging:

A) Multiple bilateral ground-glass densities. B) Bilateral patchy consolidations. C) Patchy consolidations on the left lung and ground glass densities on the right side. D) Cardiomegaly and pleural effusion. E) Cardiomegaly and pericardial effusion associated with pulmonary infiltrations.

Table 4. CT scan findings

		Count	%	Count	%	Count	%
CT Finding	Highly Suggestive	90	85.71	81	85.26	171	85.50
	Indeterminate	10	9.52	10	10.53	20	10.00
	Inconsistent	5	4.76	4	4.21	9	4.50
Lung involvement	Unilateral	2	1.90	2	2.11	4	2.00
	Bilateral	103	98.10	93	97.89	196	98.00
GGO	Yes	101	96.19	91	95.79	192	96.00
	No	4	3.81	4	4.21	8	4.00
Consolidation	Yes	46	43.81	42	44.21	88	44.00
	No	59	56.19	53	55.79	112	56.00
Pleural effusion	Yes	25	23.81	28	29.47	53	26.50
	No	80	76.19	67	70.53	147	73.50
Crazy Paving	Yes	18	17.14	12	12.63	30	15.00

		Count	%	Count	%	Count	%
Cardiomegaly	No	87	82.86	83	87.37	170	85.00
	Yes	14	13.33	17	17.89	31	15.50
Pericardial effusion	No	91	86.67	78	82.11	169	84.50
	Yes	1	0.95	6	6.32	7	3.50
LAP	No	104	99.05	89	93.68	193	96.50
	Yes	3	2.86	4	4.21	7	3.50
Bronchiectasis	No	104	99.05	89	93.68	193	96.50
	Yes	1	0.95	6	6.32	7	3.50
Emphysema	No	102	97.14	93	97.89	195	97.50
	Yes	3	2.86	2	2.11	5	2.50
Intra Thoracic Mass	No	103	98.10	92	96.84	195	97.50
	Yes	2	1.90	3	3.16	5	2.50
Fibrosis	No	104	99.05	92	96.84	196	98.00
	Yes	1	0.95	3	3.16	4	2.00
Cavity formation	No	103	98.10	94	98.95	197	98.50
	Yes	2	1.90	1	1.05	3	1.50
Pneumothorax	No	102	97.14	95	100.00	197	98.50
	Yes	3	2.86	0	0.00	3	1.50
Reverse halo	No	105	100.00	95	100.00	200	100.00
	Yes	0	0.00	0	0.00	0	0.00

Discussion

After the statement of the COVID-19 pandemic by the World Health Organization (WHO) on January 30, 2020, many people died from this new unseen disaster all over the world. In an unequal combat, on one side there were the organizations responsible for saving the lives of humans, and on the other side humanity suffered from disease and its complications with no adequate information (2).

Based on our results, comorbid diseases were hypertension in 45 (22.5%), heart problems in 37 (18.5%), diabetes in 30 (15%), renal diseases in 10 (5%), malignancy or on chemotherapy 8 (4%) cases. Similar to our results, Shi et al., reported accompanying diseases as hypertension in 12 (15%), diabetes in 10 (12%), chronic pulmonary disease in 9 (11%), and cardiovascular disease in 8 (10%) cases (5).

Prominent symptoms with which patients referred to ER were dyspnea 77 (38.5%), fever 30 (15%), and dry cough 26 (13%). Half of the patients (50%) had no significant complaints, but deterioration occurred later. These symptoms also were observed in the

results of Zhou et al., (4), Shi et al., (5), Han et al., (6), Pan et al., (7), Chung et al., (8), and Li et al., (9).

In the first 48 hours after admission 23.6% of the cases died, which could be due to advanced disease or late reference because of low knowledge of the novel disease (5, 6).

The majority (98%) of the cases had involved pulmonary tissue bilaterally, GGO (96%), consolidation (44%), crazy paving (15%), and cardiomegaly (15.5%) which were our prominent findings. In Wei et al., report CT showed rapidly growing ground-glass opacities and progressing peripheral consolidations in both lungs (10).

Fluid leakage to alveoli space leads to non-complete filling of spaces, sparing bronchial tree, seen in X-rays, and CT scan as white areas (GGO). Continuing the process leads to the hardening of alveolar walls and disability in expanding enough, seen as consolidation. Severe changes in pulmonary tissue media by inflammatory cytokines predispose injured tissue to super-imposed infections. In most reported studies GGO⁺ consolidation is the best hallmark for treatment

initiation and following the progression of medical care (9-11). In other studies, the sensitivity of pulmonary CT scans was evaluated as 97% (12- 14).

Cardiomegaly in 31 (15.5%) and Pericardial effusion in 7 (3.5%) cases were also seen. In this group (cardiomegaly and pericardial) hypertension in 35 (17.5%), heart disease in 31.9%, and DM in 22.9% of the cases were reported as the underlying diseases. Patients with hypertension and heart disease do not seem to be more prone to show cardiovascular symptoms. There was no significant relevance between these groups and death under 48 hours (11).

There may be earlyonset or nondiagnosed cardiac problems exacerbated by a virus attack. Viremia causes high temperature, cytokine storm, and inflammatory response of the immune system that may impose more pressure on the myocardium. On the other hand, increasing demand for oxygen will not be responded adequately by disturbed alveolar O₂ change. Viral myocarditis has been reported with other viruses, which is also seen in COVID-19 (15).

A comparison between patients with HTN in a highly suggestive group and an indeterminate group showed no significant relation. Diabetes had no significant association.

We had only 7(3.5%) cases with more than 10 mm diameter lymph nodes. When LAP is seen it can be the sign of advanced disease and superimposed bacterial infection. Yet, LAP is rarely seen in most reports.

The tendency of viruses to invade basilar lobes and posterior parts of lungs was seen in our study, with RLL suffering higher than others (69%) followed by LLL (64%). The right middle lobe has the lowest rate of involvement (28%) in the scores 3and 4. RML was not involved in 13.5%. These findings could be due to the gravity effect, resting position, and anatomical location of bronchi (7, 10, 11).

Conclusion

The pulmonary CT scan is a rapid investigation for screening patients with vague symptoms and helps to initiate treatment decisions earlier before deterioration. In the presence of positive signs in a CT scan, a quick reaction to starting treatment occurs. Our findings showed Ground Glass Opacity (GGO) in 192 (96%), consolidation in 88 (44%), crazy paving in 30 (15%), cardiomegaly in 30 (15%), and pleural effusion in 53 (26.5%) cases. More public information about symptoms is essential for an on time visit. The presence of subtle symptoms does not mean mild involvement; a complete medical assessment should be made for older people and people with risk factors. Hypertension as an underlying disease was significantly related to Highly Suggestive CT scans. Also, cardiomegaly in our study could be a warning sign, although no significant relevance between cardiomegaly and death

under 48 hours' post-admission was found. We think more studies are needed to determine the role of cardiomegaly in acute viral respiratory syndrome.

Acknowledgments

The authors would like to acknowledge Dr. Alijan Tabarraei, Ph.D., Professor of Medical Virology, and Golestan University of Medical Sciences for their cooperation and giving useful consultations to our team. And also, we thank Mohsen Mansouri, M.Sc., and Mohammad Gholamrezaei, M.Sc., Statistics and Information Technology Management Unit of Golestan University of Medical Sciences, for making PACS system data available for the current study.

Ethical considerations

Ethical issues (Including plagiarism, informed consent, misconduct, data fabrication and/or falsification, double publication and/or submission, redundancy, etc.) have been completely observed by the authors. This study is derived from a research study (Recording Mortality COVID-19 in Golestan-Iran) approved by the deputy Research of GOUMS and the Medical Ethics Committee (Code: IR.GOUMS.REC.1398.390).

Conflict of Interest

The authors declare no conflict of interest.

References

1. Zhu N, Zhang D, Wang W, et al. A Novel coronavirus from patients with pneumonia in China, 2019. *N Engl J Med.* 2020;382(8):727-33. [DOI:10.1056/NEJMoa2001017] [PMID] [PMCID]
2. Organization WH. Global surveillance for COVID-19 caused by human infection with COVID-19 virus: interim guidance, 20 March 2020.
3. Dai WC, Zhang HW, Yu J, et al. CT imaging and differential diagnosis of COVID-19. *Can Assoc Radiol J.* 2020;71(2):195-200. [DOI:10.1177/0846537120913033] [PMID] [PMCID]
4. Zhou Z, Guo D, Li C, et al. Coronavirus disease 2019: initial chest CT findings. *Eur Radiol.* 2020;30(8):4398-406. [DOI:10.1007/s00330-020-06816-7] [PMID] [PMCID]
5. Shi H, Han X, Jiang N, et al. Radiological findings from 81 patients with COVID-19 pneumonia in Wuhan, China: a descriptive study. *Lancet Infect*

- Dis. 2020 Apr;20(4):425-34. [DOI:10.1016/S1473-3099(20)30086-4]
6. Han R, Huang L, Jiang H, Dong J, Peng H, Zhang D. Early clinical and CT manifestations of coronavirus disease 2019 (COVID-19) pneumonia. *Am J Roentgenol.* 2020;215(2):338-43. [DOI:10.2214/AJR.20.22961] [PMID]
 7. Pan F, Ye T, Sun P, et al. Time course of lung changes at chest CT during recovery from coronavirus disease 2019 (COVID-19). *Radiology.* 2020;295(3):715-21. [DOI:10.1148/radiol.2020200370] [PMID] [PMCID]
 8. Chung M, Bernheim A, Mei X, et al. CT imaging features of 2019 novel coronavirus (2019-nCoV). *Radiology.* 2020;295(1):202-7. [DOI:10.1148/radiol.2020200230] [PMID] [PMCID]
 9. Li Y, Xia L. Coronavirus disease 2019 (COVID-19): Role of chest CT in diagnosis and management. *Am J Roentgenol.* 2020;214(6):1280-6. [DOI:10.2214/AJR.20.22954] [PMID]
 10. Wei J, Xu H, Xiong J, et al. 2019 Novel coronavirus (COVID-19) pneumonia: serial computed tomography findings. *Korean J Radiol.* 2020 (21);501-4. [DOI:10.3348/kjr.2020.0112] [PMID] [PMCID]
 11. Yoon SH, Lee KH, Kim JY, et al. Chest radiographic and CT findings of the 2019 novel coronavirus disease (COVID-19): Analysis of nine patients treated in Korea. *Korean J Radiol.* 2020;21(4):494. [DOI:10.3348/kjr.2020.0132] [PMID] [PMCID]
 12. Long C, Xu H, Shen Q, et al. Diagnosis of the coronavirus disease (COVID-19): rRT-PCR or CT? *Eur J Radiol.* 2020;126:108961. [DOI:10.1016/j.ejrad.2020.108961] [PMID] [PMCID]
 13. Ye Z, Zhang Y, Wang Y, Huang Z, Song B. Chest CT manifestations of new coronavirus disease 2019 (COVID-19): a pictorial review. *Eur Radiol.* 2020;30(8):4381-9. [DOI:10.1007/s00330-020-06801-0] [PMID] [PMCID]
 14. Inui S, Fujikawa A, Jitsu M, et al. Chest CT findings in cases from the Cruise ship "Diamond Princess" with coronavirus disease 2019 (COVID-19). *Radiol Cardiothorac Imaging.* 2020;2(2):e200110. [DOI:10.1148/ryct.2020200110] [PMID] [PMCID]
 15. Doyen D, Mocerri P, Ducreux D, Dellamonica J. Myocarditis in a patient with COVID-19: a cause of raised troponin and ECG changes. *Lancet.* 2020;395(10235):1516. [DOI:10.1016/S0140-6736(20)30912-0]

How to Cite This Article:

Nematollahi N, Mohammadi M R, Vakili M A, Baniaghil A S, Ghelichli M, Najafi M J, et al . Chest CT Findings (COVID-19), Analysis of 200 Cases (Postmortem), *J Adv Med Biomed Res.* 2022; 30(140): 241-248.

Download citation:

[BibTeX](#) | [RIS](#) | [EndNote](#) | [Medlars](#) | [ProCite](#) | [Reference Manager](#) | [RefWorks](#)

Send citation to:

 [Mendeley](#)  [Zotero](#)  [RefWorks](#) [RefWorks](#)