

Restoring the Lost Smile: A Case Report

Dr. Carrolene Langpoklakpam¹

Dr. Divya Singh²

Dr. Nidhi Gupta³

Dr. Natasha Gambhir⁴

Dr. Rashi Singh⁵

Dr. Vinita Kumari⁶

PG Student¹

Dept. of Pediatric & Preventive Dentistry,
Santosh Dental College & Hospital,
Ghaziabad, Uttar Pradesh, India

Senior lecturer²

Dept. of Pediatric & Preventive Dentistry,
Santosh Dental College and Hospital,
Ghaziabad, Uttar Pradesh, India

Professor & Head of Department³

Dept. of Pediatric & Preventive Dentistry,
Santosh Dental College & Hospital,
Ghaziabad, Uttar Pradesh, India

Professor⁴

Dept. of Pediatric & Preventive Dentistry,
Santosh Dental College & Hospital,
Ghaziabad, Uttar Pradesh, India

Reader⁵

Dept. of Pediatric & Preventive Dentistry,
Santosh Dental College & Hospital,
Ghaziabad, Uttar Pradesh, India

PG Student⁶

Dept. of Pediatric & Preventive Dentistry,
Santosh Dental College & Hospital,
Ghaziabad, Uttar Pradesh, India

Abstract

When a deciduous tooth is lost early than its normal exfoliation time, the teeth next to the edentulous area tend to migrate into the space, leading to the loss of space needed for the normal alignment of the permanent erupting teeth in the arch, leading to overcrowding and other kinds of malocclusion. The most typical application of a space maintainer appliance is to preserve the area formed by the early loss of a primary molar while waiting for its successor permanent teeth to erupt. This paper will describe a case study using an interim fixed functional space maintainer appliance.

Keywords: - Space maintainer, Interim functional space maintainer, early tooth lost, full mouth rehabilitation.

Introduction

Primary teeth are essential for a child's growth and development. It also create spaces for the secondary successor teeth.⁽¹⁾ Primary teeth are also important for appearances, chewing, and pronunciation of speech, as well as promoting healthy development and maturation of jaw.⁽²⁾ When a deciduous tooth is lost early than its normal exfoliation time, the teeth next to the edentulous area tend to migrate into the space, leading to the loss of space needed for the normal alignment of the permanent erupting teeth in the arch, leading to overcrowding and other kinds of malocclusion.⁽³⁾ When an anterior primary tooth is exfoliated before its eruption timing, the teeth on both the side of the edentulous area seldom migrate into the gap. It also causes an unpleasant smile and difficulties and discomfort while biting, i.e. an impairment of function, resulting in a scenario that cannot be ignored.⁽⁴⁾ The primary cause of early exfoliation of posterior teeth is dental caries.⁽⁵⁾ Following the premature loss or extraction of a primary tooth or teeth, space maintainers appliances used to retain arch length. they may be fixed or removable appliance. Primary teeth that have been retained might function as space maintainer. The most typical application of a space maintainer appliance is to preserve the area formed by the early loss of a primary molar while waiting for its successor permanent teeth to erupt.⁽⁶⁾ This paper will describe a case study using an interim fixed functional space maintainer appliance.

History

Fauchard was the first to utilise a horseshoe-shaped precious metal device called a "Bandeau" for arch expansion and tooth alignment.⁽⁷⁾ Davenport et al., in 1880, highlighted the issue of space loss caused by early primary tooth exfoliation.⁽⁶⁾ Angle, the founder of contemporary orthodontics, was credited with proposing the notion of artificially preserving the spaces created by the early loss of primary teeth in 1907.⁽⁷⁾ Liu et al., in 1949, conducted the first known study that sought to estimate space were hampered by a lack of sequentially generated data and measuring method constraints.⁽⁶⁾

Purposes of Space Maintainer

The main purposes of space maintainer are as follows- It helps in maintaining the relative position of existing dentition to prevent loss of arch length, breadth, and perimeter. It is used to preserve the natural occlusal plane as well as anthropoid space. In certain circumstances, anterior space maintainers aid in phonetics, aesthetics, and posterior aids in mastication.⁽⁷⁾

A Case Study

A child 6 years old came to the department of Pediatric and Preventive dentistry with the chief complain of multiple carious teeth. The carious teeth were associated with pain in the maxillary left and right posterior region for the past 1 month. According to the history of present illness given by the patient, Pain started in the maxillary left and right posterior

Access this article online

Website:

www.updent.in

DOI:

10.4880/zenodo.5930358

Quick Response Code:



Corresponding Author:

Dr. Divya Singh

Senior Lecturer

Dept. of Pediatric & Preventive Dentistry,

Santosh Dental College and Hospital,

Ghaziabad, Uttar Pradesh, India

Email: hapz27@gmail.com

Mob: 9811369554

region. It was spontaneous, non-radiating which got aggravated while eating. Pain got relieved only after taking over the counter medication.

Intra oral examination revealed that patient was in mixed dentition stage with multiple grossly decayed teeth.

(Figure: 1)

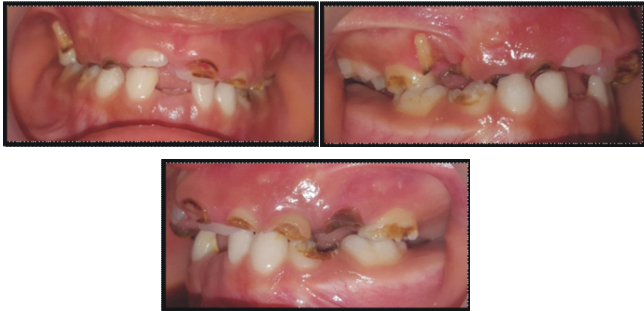

Figure 1: Intra oral photograph (a) Frontal view (b) Right lateral view © Left lateral view

Multiple root stump was observed in the region of 54, 53, 52, 61, 62, 63 and 64. Multiple grossly decayed teeth were found in the region of 55, 65, 74 and 84. **(Figure: 2)**

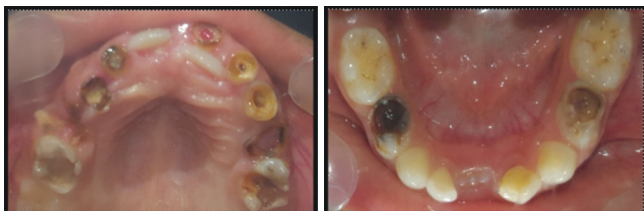

Figure 2: Intra oral photograph (a) maxilla occlusal view (b) mandible occlusal view

Full mouth OPG was advised to the patient in order to evaluate the overall status of the erupting succedaneous teeth as well as the status of the primary teeth. **(Figure 3)**

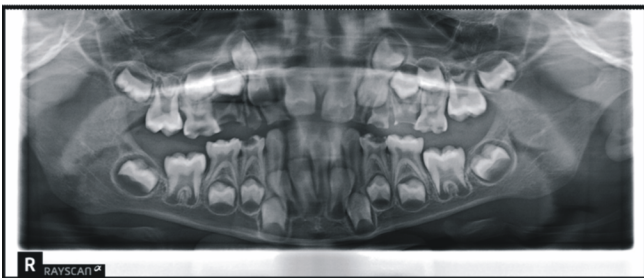


Figure 3: Oral Pantomogram radiograph of the patient

According to the Oral Pantomogram radiograph revealed carious lesion involving pulp with periapical radiolucency in respect with 54, 53, 64, 65. Internal root resorption was seen in 63 and 53. It was also observed that there were carious lesion approaching the pulp of 74, 84.

According to the investigation, extraction of 53, 54, 61, 63, 64, 65 was planned. Pulpectomy was planned for 52, 62 followed by crown build up in order to preserved the teeth as the natural space maintainer till the time of its natural exfoliation. Stainless steel crown was advised for 55, 74 and 84 as shown in **(Figure 4)**.

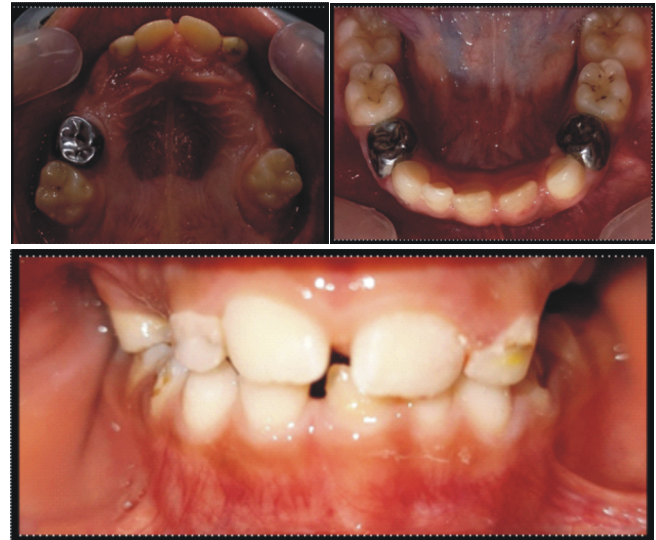

Figure 4: Post op intra oral photograph (a) Maxillary occlusal view (b) Mandibular Occlusal view and (c) frontal view

As an interceptive treatment, a modified Nance palatal arch with incorporation of acrylic tooth in the posterior region was planned. Banding was done in 16 and 26 for interim functional Nance Palatal Arch **(Figure 5)**

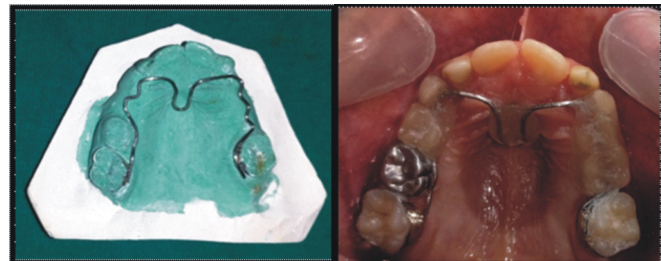


Figure 5: (a) Modified wire banding design for incorporation of the acrylic teeth (b) Post insertion photograph of maxillary occlusal view

After 1 year follow up: Patient came with complain of swelling in the right anterior region tooth region. **(Figure 6)**

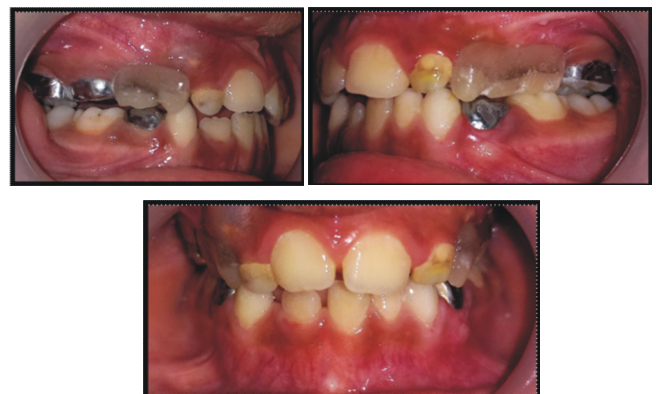

Figure 6: After 1 year follow up (a) Right lateral view (b) Left lateral view © Frontal View

Intra oral Periapical radiograph was taken for 52 and the radiograph revealed that there was external root resorption in 52 with erupting 12. **(Figure 7(a))**

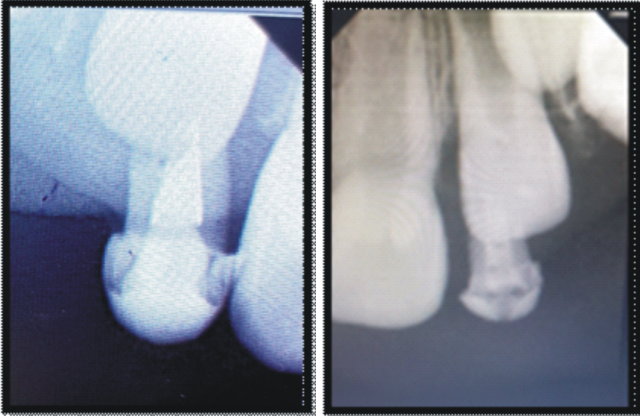


Figure 7 : Intra Oral Peri apical radiograph of (a) 52 (b) 62

Intra oral palpation revealed that 52 had grade 2 mobility. Thus, 52 was extracted under LA without removing the appliance.

After 1 year and 2 months follow up: Patient had grade II mobile 62 and 22 was erupting palatally. So, for investigation Intra oral Periapical radiograph was planned for 62. Where the radiograph revealed root resorption of 62 with erupting 22. (Figure 7, (b))

Extraction of 62 was planned with modification of the appliance as the appliance was hindering the path of eruption of 22. (Figure 8)

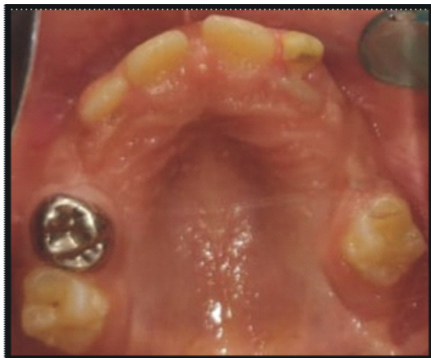

Figure 8 : Intra Oral Photograph showing palatally erupting 22 with retained 62

After extraction of 62, An OPG was advised to evaluate the status erupting succedaneous teeth as well as to further change the design of the appliance.

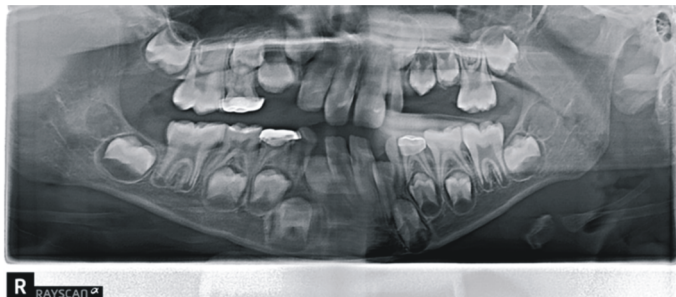


Figure 9: After 1 and 2 months follow up Ortho pantomogram

Discussion

One of the most common causes of malocclusion in permanent dentition is the early loss of a primary tooth. This is mostly due to the teeth next to the space produced by the loss of the deciduous tooth migrating into the space, resulting in a tooth material arch length discrepancy, predisposing the dentition to malocclusion. To address this issue, a number of space maintainers with varied modifications are being developed, which frequently restore the function of the oral cavity. Similarly in the above mention case report, we have tried to establish the normal occlusion as well as prevent further detrimental effect to the occlusion due to multiple carious lesions. In this case report, we had failure of pulpectomy done in 52 after 1 year follow up. The reason of failure of the pulpectomy done in 52 was in accordance with Siqueira et al in 2008⁽⁸⁾ where they stated that primary anterior teeth with periapical lesions had a higher failure rate than teeth absent of periapical abnormalities. Through chemo-mechanical preparation, it is difficult to eliminate all pathogenic bacteria in the periapical tissue, and remaining bacteria might increase the likelihood of postoperative failure. Chen et al. in 2020 also found that pulpectomy had a poor outcome in deciduous teeth with periapical infections.⁽⁹⁾ As the treatment of this patient is still going on, a change in the design of the space maintainer is being planned following a complete mixed dentition analysis.

Conclusion

It is challenging to manage space while improving masticatory performance and maintaining arch integrity in early primary tooth loss. The functional interim Nance palatal arch discussed in this article will be another ideal solution for young children who suffer early loss of multiple posterior teeth.

References

- Schopf PJJooOFdK. Indication for and frequency of early orthodontic therapy or interceptive measures. 2003;64(3):186-200.
- Bijoor RR, Kohli KJNYSDJ. Contemporary space maintenance for the pediatric patient. 2005;71(2):32.
- Goenka P, Sarawgi A, Marwah N, Gumber P, Dutta SJIjocpd. Simple fixed functional space maintainer. 2014;7(3):225.
- Kargul B, Çağlar E, Kabalay UJJodfc. Glass fiber-reinforced composite resin as fixed space maintainers in children: 12-month clinical follow-up. 2005;72(3):109-12.
- Choi B-j, Han Y-s, Kim S-o, Lee C-gjtjotkaopd. Space Loss After Premature Loss Of Primary Incisor. 2002;29(3):407-12.
- Laing E, Ashley P, Naini Fb, Gill Dsjijopd. Space Maintenance. 2009;19(3):155-62.
- Saha N, Pal S. Space Maintainers In Pediatric Dentistry-a Review. 2018.
- Siqueira Jr JF, Rôças INJJoe. Clinical implications and microbiology of bacterial persistence after treatment procedures. 2008;34(11):1291-301. e3.
- Chen Y, Li H, Li M, Yang L, Sun Q, Chen KJIjopd. Analysis of survival and factors associated with failure of primary tooth pulpectomies performed under general anaesthesia in children from South China. 2020;30(2):225-33.