



# A COMPREHENSIVE REVIEW ON: THE GRAVITATING BLACK FUNGUS DISEASE –

<sup>1</sup>Twinkle Rathod, <sup>1</sup>Priyancy Patel, <sup>2</sup> Pinkal H. Patel, <sup>2</sup> S P Srinivas Nayak, <sup>3</sup>Gunosindhu Chakraborty

<sup>1</sup>PharmD (student), <sup>2</sup>Associate Professor, HOD, <sup>3</sup>Principal, Associate Professor

<sup>1</sup>Department of Pharmacy,

<sup>1</sup>Parul Institute of Pharmacy and Research, Vadodara, Gujarat, India

**Abstract:** Lately, the Black fungus disease in light as mucormycosis is a life-threatening fungal infection caused by fungus Mucorales, primarily affecting immunocompromised patients with comorbid conditions. Presenting clinical indices unswervingly depend mainly upon the host's defence mechanism indicating the severity and progression of the infection and site of infection. The mortality rates of mucormycosis remain extortionate since the early confirmative diagnosis remains questionable. There is limited data available for proper management of the disease, though early diagnosis with prompt antifungal treatment is the foremost elementary principle for preventing disease progression and further complications. The need for surgical debridement depends upon the severity and extent of the disease. Still, surgical resection before the progression of mucormycosis greatly impacts cure and the mortality rate declines considerably.

**Key words:** Black Fungus, Mucormycosis, Immunocompromised, Rhino-cerebral mucormycosis, Pulmonary mucormycosis, Antifungal.

## 1. INTRODUCTION

Mucormycosis, also known as zygomycosis, recently in light as black fungus disease, is the infrequent, opportunistic, non-contagious fungal infection engendered by moulds<sup>1,2</sup>. The term *mucormycosis* was first coined by Paul tauf in 1885. The disease is caused by the fungus mucus, belonging to the Family of Mucoraceae, habitually found in soil, and decaying vegetation. In humans, the infection by mucormycosis is caused by asexual spore formation<sup>3</sup>. The fungus enters as fungal spores through the nasopharyngeal route via inhalation, settle on the oral and nasal mucosa, advancing to lungs, gastrointestinal tract, brain, and the other frequent route is by consumption of contaminated food and rarely transdermal inoculation, in case of deep cuts, wounds, severe burns or chronic skin infections often called disseminated<sup>2,3</sup>. Mucoromycetes (the fungus) mature into sporangium. In most of the immunocompromised hosts, the spores will have a finite phagocytic response leading to the formation of hyphae due to which polymorphonuclear leukocytes become less potent in removing hyphae, which invades the metarterioles wherein they propagate within the walls of vessels and lumen, leading to embolization following necrosis, ischemia, and infraction with dry gangrene of surrounding tissues subsequently leading to tissue death<sup>4</sup>. Further, the fungus escalates via hematogenous spread to the paranasal sinuses and consequently to the orbit, meninges, and brain by direct extension. The clinical manifestations are nonspecific, fever (> 38°C), cough, dyspnoea, sputum production, weight loss, chest pain, haemoptysis, rhinorrhoea, cephalgia, ocular pain, vision loss, palpebral edema, facial edema, proptosis<sup>3,5</sup>. Mucorales infections are perceived highly in individuals with diabetes mellitus (mainly diabetic ketoacidosis) or iatrogenic injury and have been associated with outbreaks following natural disasters. Diabetics tend to develop endobronchial lesions. Clinical diagnosis of must include the use of High-Resolution Computed Tomography and Magnetic Resonance Imaging for rhino cerebral, pulmonary, and disseminated mucormycosis. Differential diagnosis of the lesion may include squamous cell carcinoma, chronic granulomatous infection such as tuberculosis, tertiary syphilis, midline lethal granuloma, and other deep fungal infections<sup>6</sup>. The treatment includes the use of, Polyene antifungals which are Amphotericin B (1.0-1.5 mg/kg/day) and azole antifungals such as Isavuconazole and Posaconazole have proven effective. The combination therapy includes echinocandins, iron chelation therapy, others such as proinflammatory cytokines such as interferon-alpha and granulocyte-macrophage colony-stimulating factor enhance the ability of granulocytes to destruct agents of mucormycosis. The surgical procedure depends upon the extent and severity of the disease. Lobectomy and pneumonectomy are widely performed. Surgical resection prior to the progression of mucormycosis has a great impact on cure and the mortality rate declines considerably<sup>7</sup>.

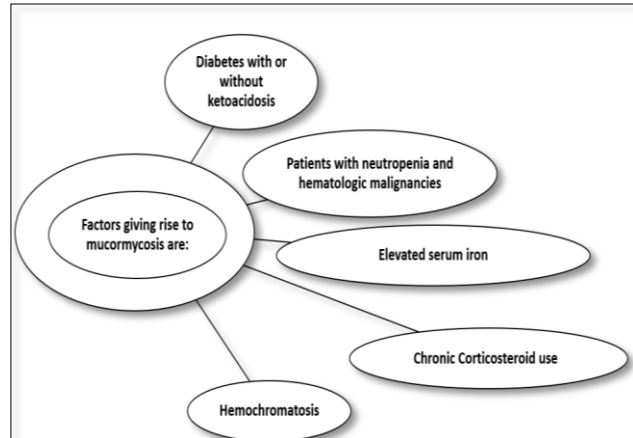
## Definition

Mucormycosis, earlier known as Zygomycosis is defined as consequential, rapidly developing, a life-threatening but a rare fungal infection is caused by a group of fungal molds, called Mucoromycetes, invading vessels of an atrial system causing an embolization with the subsequent necrosis of surrounding the tissue with the involvement of either Rhino-orbital, Cerebral region, Pulmonary, Gastro-intestinal region, Skin and less commonly other organs.

## 2. ETIOLOGY

Mucormycosis extensively affects patients with compromised immune system and chronic disease states.

Factors giving rise to mucormycosis (Figure1.1)



- Diabetics with or without ketoacidosis - Increased blood glucose level leads to stimulation of fungal proliferation which causes decreased chemotaxis and phagocytic efficacy allowing innocuous organisms to thrive in acidic environment. In patients with diabetic ketoacidosis, there is an increased risk of mucormycosis caused by *Rhizopus oryzae*, since these organisms produce enzyme ketoreductases, which permits them to make use of the patient's ketone bodies. Moreover, the ability of transferrin binding to iron is altered in diabetic ketoacidosis, leading to elimination of host defence mechanism and further permitting the growth of *Rhizopus oryzae*<sup>6</sup>.
- Patients with neutropenia and hematologic malignancies - People with haematologic disorders are chiefly susceptible to mucormycosis owing to consequences of chemotherapeutic drugs and cytopenia's. Acute leukaemia is the most common haematological disorder (78%), followed by lymphomas, myelodysplastic syndrome, multiple myeloma and aplastic anaemia. Studies showed mucormycosis to be the third most common fungal infection in haematological malignancies. The occurrence in haematological malignancies of mucormycosis is found to be 4.29 per 100 patients is mostly an underestimation as the disease is diagnosed at later stage. Also, there are no such specific biomarker and cultures might be negative. Moreover, thrombocytopenia in haematological diseases may preclude extraction of tissue specimens for diagnosis. Hence, mucormycosis is typically undiagnosed till advanced stage, or even after post-mortem in almost 85% patients.
- Elevated serum iron - Due to release of iron from binding proteins in presence of acidosis, patients with diabetic acidosis have increased levels of available serum iron. Artis *et al.* showed growth of *R. oryzae* in acidic pH (7.3-6.88) while no growth was observed in alkaline pH (7.78-8.38), when sera of diabetic ketoacidosis patients was taken. Finally, accelerated acidotic conditions decreased the iron-binding capacity of sera collected from healthy humans suggests that acidosis temporarily disrupts the capacity of transferrin to bind iron. Therefore, due to proton-mediated dissociation of iron from transferrin there is increased susceptibility to mucormycosis<sup>3,4</sup>.
- Chronic Corticosteroid use - A potential adverse effect of steroid induced hyperglycaemia in a diabetic patient who is on corticosteroids is extremely susceptible for the development of mucormycosis. Corticosteroids leads to the impairment in ingestion, absorption and phagolysosome fusion of bronchoalveolar macrophages. A case study of diabetic patient taking several short courses of high dose corticosteroids lead to serious life-threatening pulmonary mucormycosis requiring surgical procedure. The use of steroids leads to suppression of immunity which makes it easier for microorganisms to attack host and cause infection. Still, due to limited availability of data, indication for use of steroids is unclear<sup>7</sup>.
- Hemochromatosis - Hemochromatosis means increased serum iron compromising host defences and leads to increase the predisposition to various bacterial and non-bacterial infectious diseases. It exists in two forms that are primary or hereditary and secondary. The former results from inheritance of an abnormal gene at a locus on short arm of chromosome 6 near the HLA locus (6p21). Due to which there is an increased absorption of iron from 1-2mg/day (in normal individuals) to 3-4mg/day across the gastrointestinal tract. Also, there exists mutation of HFE gene, class 1 major histocompatibility complex (MHC) molecule. The latter is seen in patients requiring multiple blood transfusions due to chronic hematologic condition. The retrieval of iron is necessary for bacterial survival and represents a factor for which both host and the pathogen compete. The surplus iron burden does not help in propagation of pathogens, also impairs cell mediated immune responses. Recently emerged an important bridge between innate immunity and iron metabolism which is thought to be responsible for augmentation of the host response to pathogens is hepcidin. Due to high iron concentrations, there exists functional impairment of hepcidin therefore been associated with elevated susceptibility for infections [4].

## 3. TAXONOMY

*Mucor* is a filamentous fungus mainly found in soil, plants, decaying fruits and vegetables. As well as being ubiquitous in nature and a common laboratory contaminant, *Mucor* spp. may cause infections in man, frogs, amphibians, cattle, and swine. Most of the *Mucor* spp. are unable to grow at 37°C and the strains isolated from human infections are usually one of the few thermotolerant *Mucor* spp. The genus *Mucor* contains several species. The most common ones are: *Mucor amphibiorum*, *Mucor circinelloides*, *Mucor hiemalis*, *Mucor indicus*, *Mucor racemosus*, and *Mucor ramosissimus*.

Taxonomic Classification
Kingdom: Fungi
Phylum: Zygomycota
Order: Mucorales
Family: Mucoraceae
Genus: <i>Mucor</i>

**Macroscopic Features** Colonies of *Mucor* grow rapidly at 25-30°C and quickly cover the surface of the agar. Its fluffy appearance with a height of several cm resembles cotton candy. From the front, the color is white initially and becomes greyish brown in time. From the reverse, it is white. *Mucor indicus* is an aromatic species and may grow at temperatures as high as 40°C. *Mucor racemosus* and *Mucor ramosissimus*, on the other hand, grow poorly or do not grow at all at 37°C.

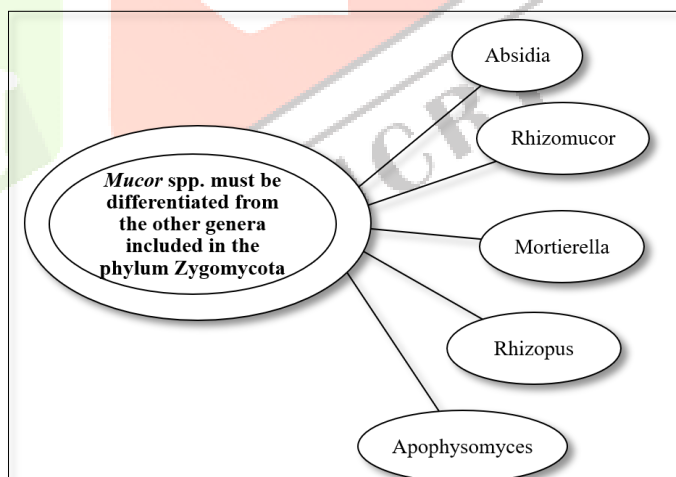
**Microscopic Features** Non septate or sparsely septate, broad (6-15 µm) hyphae, sporangiophores, sporangia, and spores are

GENUS	BEST GROWTH	SPORANGIOPHORE	APOPHYSIS	COLUMELLA	SPORANGIUM	RHIZOID
ABSIDIA	45°C	Branched, Hyaline	Conical, not prominent	Dome shaped	+, usually distinct	-
APOPHYSOMYCES	>42°C	Usually branched, greyish brown	Bell shaped, not prominent	Usually dome shaped, rarely elongated	+	-
MORTIERELLIA	40°C	Branched, Hyaline	-	-	+	+/-
MUCOR	<37°C	Branched or unbranched hyaline	-	+, varying in shapes	-	-
RHIZOMUCOR	54°C	Branched brown	-	Spherical	+	-
RHIZOPUS	45°C	Unbranched and brown mostly	Not prominent	Spherical or elongated	+	-

visualized. Intercalary or terminal arthrospores (oidia) located through or at the end of the hyphae and few chlamydo spores may also be produced by some species. Apophysis, rhizoid and stolon are absent. Sporangiophores are short, erect, taper towards their apices and may form short sympodial branches. Columella are hyaline or dematiaceous and are hardly visible if the sporangium has not been ruptured. Smaller sporangia may lack columella. Sporangia are round, 50-300 µm in diameter, gray to black in color, and are filled with sporangiospores. Following the rupture of the sporangia, sporangiospores are freely spread. A collarette may sometimes be left at the base of the sporangium following its rupture. The sporangiospores are round (4-8 µm in diameter) or slightly elongated. Zygospores, if present, arise from the mycelium. The branching of sporangiophores (branched or unbranched), the shape of the sporangiospores (round or elongated), maximum temperature of growth, presence of chlamydo spores, assimilation of ethanol, and molecular analysis aid in differentiation of *Mucor* spp. from each other.

### Susceptibility

Few data are available on the in vitro susceptibility profile of *Mucor* spp. In an in vitro study comparing the in vitro activity of amphotericin B, ketoconazole, itraconazole, and voriconazole, amphotericin B yielded the lowest MICs against *Mucor* spp. Among the azoles, while the MICs of ketoconazole and itraconazole were comparable, voriconazole yielded considerably high MICs. Similar to the other genera belonging to the phylum Zygomycota, treatment of *Mucor* infections remains difficult. Due to its property to invade vascular tissues, infarction of the infected tissue is common and mortality rates are very high. Early diagnosis is crucial and surgical debridement or surgical resection, as well as antifungal therapy, are usually required. Amphotericin B is the most commonly used antifungal agent. Liposomal amphotericin B and other lipid-based amphotericin B formulations, such as amphotericin B colloidal dispersion have also been used in some cases with zygomycosis. Response rates are unfortunately unsatisfactory. Reversal of immunosuppression is one of the most significant factors influencing the clinical outcome. Adjuvant therapy with cytokines, particularly the colony stimulating factors, has anecdotally been associated with better clinical response. There are also a few data on successful use of fluconazole and terbinafine in treatment of zygomycosis, which require validation. Interestingly, fluconazole in combination with trovafloxacin or ciprofloxacin proved to be effective in a murine model of pulmonary zygomycosis.



Response rates are unfortunately unsatisfactory. Reversal of immunosuppression is one of the most significant factors influencing the clinical outcome. Adjuvant therapy with cytokines, particularly the colony stimulating factors, has anecdotally been associated with better clinical response. There are also a few data on successful use of fluconazole and terbinafine in treatment of zygomycosis, which require validation. Interestingly, fluconazole in combination with trovafloxacin or ciprofloxacin proved to be effective in a murine model of pulmonary zygomycosis.



## PATHOPHYSIOLOGY

The fungus mucor enters as fungal spores via nasal route. According to the environment conditions these tiny fungal spores starts multiplying, the mode of reproduction being asexual spore formation and forms fungal colonies ultimately leading to hyphae formation. When the rate of reproduction is high the colonies emergence will be high leading to damage of the surrounding tissues, hence further spread of the disease to the nasopharyngeal route and rhino orbital region. Now, the infected person's immune system plays major role in fighting against these colonies. The immunocompromised host will be affected easily and also leading to rapid colonies formation and hence chances emergence of severe infection is high. The hyphae hence propagate within the walls of vessel and lumen leading to embolization formation followed by tissue necrosis, ischemia and infraction with dry gangrene of the surrounding tissue ultimately leading to tissue death. This will lead to delayed response to the therapy too with multiple drug regimens at high doses and also the changes of further complication will be at greater extent. In immunocompetent hosts, the body's immune system fights back with the fungus leading to destroying of the colonies and hence the further spread is reduced.

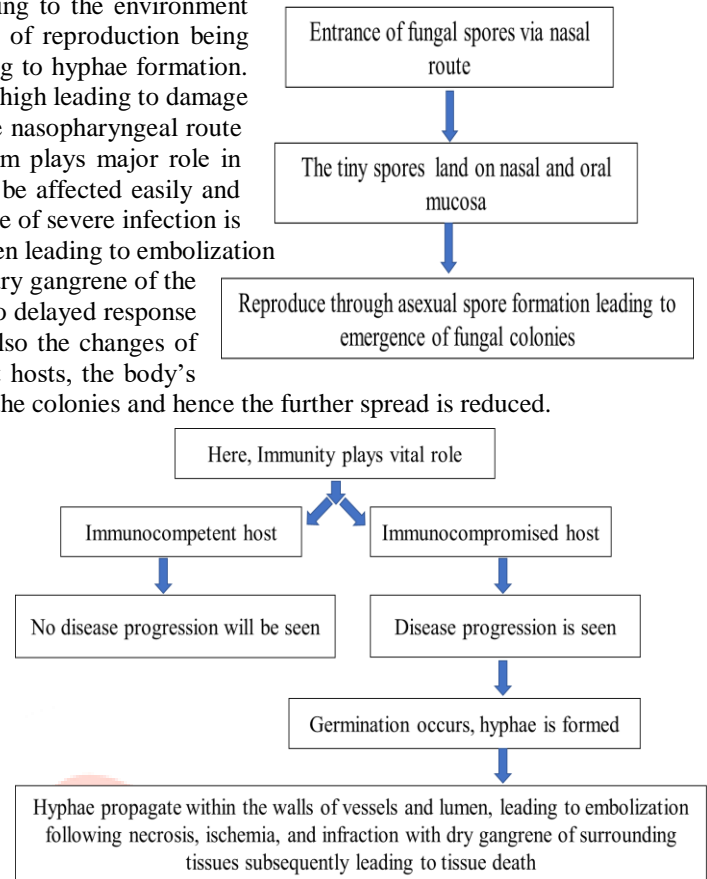
The illustrative sign and symptoms of the above-listed classification are: -

**1. PULMONARY MUCORMYCOSIS** - The most common symptom being non-productive cough and hyperpyrexia, insensitive to broad-spectrum antibiotics, while along the same lines, hemoptysis, pleuritic chest pain, and altered mental status are less common<sup>6</sup>. In rare conditions, there is no question that pulmonary mucormycosis may present as an endobronchial or tracheal lesion, especially in diabetics with ketoacidosis which can cause airway obstruction, resulting in lung collapse, and massive hemoptysis in the existence of surrounding tissue necrosis due to the incursion of hilar blood vessels. It is widely seen in people with malignancy, recent organ or stem cell transplant, or graft versus host disease (GVHD). As a matter of fact, PM is the second most common presentation [6,8].

**2. RHINOCEREBRAL MUCORMYCOSIS** - Demonstrating indications are deviations from the normal functioning of nasal fossa that is dyspnoea, dyssomnia, nasal congestion, blurred vision which may lead to sightlessness, frontal headache, pain in teeth and postnasal drip. Sinusitis accompanied by nasal congestion, nasal discharge and sinus pain [8,9]. Fever and headache including tissue necrosis on the roof of mouth palate, the disintegration of the thin wall of cartilage and bone (septum) that divides nostrils, swelling of the area around the perinasal area, erythema of skin overlying sinus and eye socket and sometimes bluish discoloration of skin near sinuses or eye socket due to cyanosis<sup>7</sup>. If untreated, without a doubt tissue necrosis spread and ultimately leads to invasion of facial structure. Lethargy, dysarthria, partial paralysis, brain abscess, seizure's, cranial neuropathies, coma are typical indications of cerebral mucormycosis. Most common in people with uncontrolled diabetes and with a recent kidney transplant. Other signs are fever, periorbital edema, loss of vision, ophthalmoplegia, periorbital cellulitis, proptosis, and other neurological deficits. The disease can be divided into further three clinical stages: stage I, with clinical features restricted to the Sino-nasal area; stage II, which is categorized by a Sino-orbital infection; and stage III, with intracranial involvement. The preliminary symptoms of ROCM are of sinusitis and periorbital cellulitis and may include eye and/or facial pain and facial numbness followed by blurry vision. Weakening of eye muscles, Bulging or displacement of eye (proptosis), swelling of eye due to fluid build-up (periorbital edema).

**3. CUTANEOUS MUCORMYCOSIS** - Cutaneous mucormycosis can be sorted as primary or secondary. The crucial affected areas of the skin are the upper and lower limbs. Also, might include other areas such as the scalp, face, thorax, back, abdomen, perineum, breast, neck and gluteal area. A simple sore, coarsened area of skin and inflammation of underlying tissue ulcers or blister, tissue necrosis, black skin and fever. It can develop slowly or be severe or sudden onset (fulminant), skin burns, wounds, infections primary cutaneous mucormycosis may be gradual in onset or fulminant. The clinical presentation differs. Firstly, lesions are inured plaques which are erythematous to purple which later become necrotic with an erythematous halo that might mature into an eschar. Few other appearances including targetoid lesions, tender nodules, ulcers, purpuric lesions, and swollen and scaly plaques have been noted. It seems to appear cellulitis and necrosis in cases of burn and wound infections. Secondary cutaneous mucormycosis usually results from a rhino cerebral or disseminated infection and is more recurrent than the primary disease. It has an acute onset and high mortality. The infection usually begins as sinusitis and the most common dermal detection is a necrotic eschar. The patients may also have oral implication with necrotic, black or white ulcers. Other clinical features are fever, periorbital cellulitis, periorbital edema, ophthalmoplegia, proptosis, loss of vision, and other neurological deficits.

**4. GASTROINTESTINAL MUCORMYCOSIS** - Common in adults than in young children, premature or low birth weight, less than one-month age who have had on antibiotics, surgery, medications and with low immunity. When spores are breathed into mouth and swallowed on contaminated food eaten, is responsible for abdominal pain, vomiting of blood, peritoneal inflammation, that is peritonitis, painful bowel (lack of blood flow), Hemorrhagic shock, lesions on the stomach or intestine. That is the only reason behind stomach being the commonest site for Gastrointestinal mucormycosis, tailed by colon and ileum. The most common symptoms are Nonspecific abdominal pain and distention associated with nausea and vomiting while Fever and hemochezia may also occur. An intra-abdominal abscess is frequently seen in the patient.

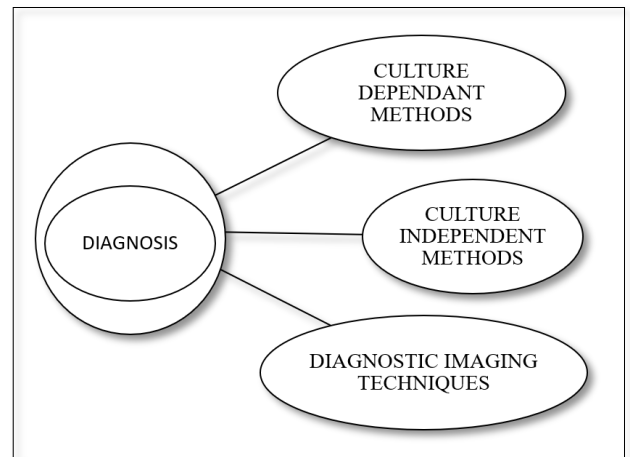


**5. DESSIMINATED MUCORMYCOSIS** - Involves copious body organs including lungs, kidney, bones, heart etc. leading to endocarditis, osteomyelitis etc. Symptoms depends upon the specific organ affected. Critically immunocompromised patients are susceptible to develop disseminated mucormycosis. The principal hallmark for commencing diagnosis is metastatic skin lesion. Disseminated mucormycosis is invariably lethal in absence of appropriate therapy, thus its post-mortem diagnosis is common.

**6. UNCOMMON FORMS OF MUCORMYCOSIS** - Other uncommon local forms of mucormycosis include endocarditis, osteomyelitis, peritonitis, and pyelonephritis. This is due to the advancement of disseminated mucormycosis.

## DIAGNOSIS

**Culture dependent methods** - Direct examination, histopathology, Culture examination of samples of infected tissue is done in laboratory to detect fungus. Histopathology, being a gold standard test for detection of mucormycosis helps to distinguish between aspergillus and Mucorales, having same morphology. Histopathologic examination is done on samples with H&E, Periodic acid Schiff stain or fungal stains such as Grocott methenamine-silver. Direct microscopic examination via calcofluor and Blankophor causes binding of these agents with chitin or cellulose of Mucorales, which fluorescence in presence of UV light showing distinctive features of hyphae of Mucorales which have ribbon like appearance and might be non-septate or pauci-septate. Though above-mentioned techniques need much expertise and skills because sensitivity varies with quality of specimen, individual agent and source, also specimens taken from the suspected cases fails to grow cultures in some cases. At last, culture dependent methods use biopsies of deep tissues, which can be a risk factor for the patients who are highly prone to develop invasive infections.



**Culture independent methods** - With the emergence of molecular methods such as PCR, has improved diagnosis of mucormycosis. A retrospective cohort study by Sarah et al., molecular detection via PCR targeting 18S ribosomal DNA of Mucorales in paraffin-embedded tissue samples of infected specimen was done for diagnosis of mucormycosis. The results confirmed detection via PCR to be an essential method for the diagnosis of black fungus even in culture negative specimens, thus enabling appropriate therapy.

**Diagnostic imaging techniques** – One of the most important principles in the management of mucormycosis is its early detection to achieve beneficial outcomes. Diagnostic imaging plays an important role in cases of pulmonary, extra-pulmonary and disseminated mucormycosis also before performing surgery involving complex areas where it is difficult to distinguish invasive infection. Computed tomography (CT) scanning detects lesions that are usually associated with black fungus which are correlated with other organisms with characteristic lesions. CT scans have sensitivity towards Orbital and cranial areas involved while perineural and intracerebral involvement can be detected via Magnetic resonance imaging (MRI) scanning. As mucormycosis has violent nature it has to be closely monitored so, the above-mentioned techniques must be carried out on frequent intervals which will improve the outcome as well as survival rates.

## TREATMENT

Pharmacology of azoles and L-AMB

Drug	Dosage	Route of administration	Plasma half life and bioavailability	CNS penetration	Excretion
L-AMB	5 mg/kg/day	IV	100-150 hrs -	Low	Urine, Bile, Hepatic, Renal
Voriconazole	Day-1 : 2*6 mg/kg/day Day-2 : 2*4 mg/kg from day 2	PO=IV	6 hr 96%	High	Urine, renal
Posaconazole	Suspension 4*200 mg Delayed release tablet/ IV : 2*300 mg day 1 and 1*300 mg day 2	PO<IV	27-35 hrs Tablet 54%	Low	Faeces, Urine, renal
Isavuconazole	Day-1 3*200 mg Day-2 1*200 mg, maintenance dose	PO=IV	110-115 hrs 98%	High (animal data)	Faeces, urine

**LIMITED UNDERSTANDING OVER THE DISEASE** - Mucormycosis being rare disease, with variety of hosts and infection sites, there is very limited full-bodied data available for its early diagnosis and treatment. The studies conducted till now are based upon single institutional retrospective with inadequate number of patients, presented with varying complaints, symptoms and risk factors. These studies were found to be registered with various methodological flaws, and expert opinions. However, it is important

to have complete understanding over the disease as its early diagnosis is crucial for treating patients and to avoid further complications<sup>1</sup>.

**STRATEGIES FOR THE MANAGEMENT OF MUCORMYCOSIS** - The foremost elementary principles for treating mucormycosis is to prevent progression and complications while improving survival consists of – Figuring the risk factors and risk stratification, reversing the underlying predisposing factors if possible, early and accurate diagnosis, timely management with the proper and effective antifungal agents either monotherapy or combination therapy whichever seems to be necessary along with aggressive surgical debridement of necrotic lesions and further controlling underlying medical condition whenever possible, as the mortality rates have been increased these days.

Apart from the treatment, some precautions should be taken by patients which might help in lowering the risk for developing mucormycosis such as:

- 1) Practicing oral hygiene
- 2) Controlling blood sugar levels who are diabetic
- 3) Twice daily
- 4) Wearing shoes, gloves, long sleeves garments while handling soil, moss or manure during farming or gardening.

### MANAGEMENT OF MUCORMYCOSIS

Mucormycosis usually requires surgical debridement along with the adjunctive medical treatment. The medical treatment with various antifungals has varying degree of susceptibility against different species. Though there is no data available for applying the above differences in treatment.

**POLYENES** - The latest studies compared different amphotericin B (AMB) formulations, considering Lipid formulation of AMB to be the cornerstone and first line therapy for the management of mucormycosis, though the effectiveness of AMB has been seen in laboratory as well as clinical studies. The use of liposomal AMB preparation have proven its efficacy with lesser nephrotoxicity and high safety profile while using high doses for longer period. Still, the major concern while treating the patient must be taking into consideration the host dependent variation that we had earlier discussed.

**TRIAZOLES** - Triazoles works by depleting ergosterol from the cell membrane of fungus. Posaconazole and Isavuconazole are newer triazoles with better in vitro activity with supporting clinical data than the previously used triazoles like fluconazole, voriconazole and itraconazole which have very low or no activity against Mucorales. The effect of Posaconazole is variable against Mucorales with 90% MIC made it to be the first line treatment in case of AMB contraindication. Some studies suggest monotherapy with Posaconazole alone is not recommended in mucormycosis management and hence it can be used as salvage therapy. Another drug that is isavuconazole has thought to have 2-5fold increase in MIC as compared to Posaconazole, along with many other safety advantages being less drug-drug interaction, less toxicity, lesser side effects, no nephrotoxic cyclodextrin in IV formulation, no need for dose adjustment in kidney or liver failure and in obese patients. As it is available in both oral and IV formulation, it has excellent oral bioavailability without any food requirements.

**COMBINATION THERAPY** – Various clinical studies have been conducted on animal models as well as human models to know the survival rates and efficacy of combination therapy in management of mucormycosis, though some of which combination therapy still remains questioning. Combination of Lipid formulations of amphotericin B (LFAB) with caspofungin showed better effectiveness in rhino orbital cerebral involvement in diabetic patients compared to polyenes, while use of Liposomal amphotericin B (LAmB) with micafungin or anidulafungin in neutropenic and diabetic ketoacidosis (DKA) mice study showed improved outcomes. Use of Posaconazole as combination therapy along with polyenes still have limited understanding with no clinical data available. On the other hand, use of Deferoxamine iron chelation therapy in combination with LAmB in DKA mice with disseminated mucormycosis synergistically improved survival rates. However, the most common GI side effects by the use of deferoxamine and renal toxicity have been noted in various clinical trials, though those patients already had underlying comorbidities and so renal failure in these cases seems to be unclear.

**ADJUNCTIVE THERAPY** - Recombinant Pro-inflammatory cytokines, for an example interferon-g and granulocyte macrophage colony stimulating factor has the capability to damage the Mucorales by enhancing the ability of granulocyte. There are limited reports based on granulocyte transfusions, though it can be the life- saving in neutropenic and refractory mucormycosis patients. Lastly, limited data suggest that using appropriate technical expertise and facilities, the Hyperbaric oxygen therapy might be useful.

**SURGERY** – Poor or incomplete antifungal drugs penetration to the site of action can alter desired outcomes, causing blood vessel thrombosis which results into tissue necrosis. Thus, surgical debridement of necrotic tissues in these cases becomes crucial for complete eradication of mucormycosis. Surgery was found to be a sovereign variable for desired outcome among patients with mucormycosis, according to a logistic regression model. Furthermore, patients who did not undergo surgery for mucormycosis had higher mortality rates compared to the patients who underwent surgical debridement. The patients with rhino-cerebral involvement requiring surgical care undergoes drainage of sinuses and may require excision of orbital contents and involved brain. However repeated surgery might be required in some cases of mucormycosis with rhino-cerebral involvement.

**TREATMENT DURATION** – Due to absence of data, there is no such specific time period or duration for therapy.

The only objectives to be focused on for treatment are:

- (1) Complete absence of clinical signs and symptoms of infection,
- (2) Resolution or stabilization of residual radiographic signs of disease on serial imaging,
- (3) Eradication or resolution of underlying immunosuppress



## REFERENCES

1. Hibbett DS, Binder M, Bischoff JF, et al. A higher-level phylogenetic classification of the fungi. *Mycol Res* 2007; 11: 509 – 547 .
2. Chayakulkeeree M, Ghannoum M, Perfect J. Zygomycosis: the reemerging fungal infection. *Eur J Clin Microbiol Infect, Dis* 2006; 25: 215 – 229
3. Bouza E, Muñoz P, Guinea J. Mucormycosis: an emerging disease?. *Clin Microbiol Infect* 2006; 12 ( Suppl. 7 ): 7 – 23
4. Tobón A, Arango M, Fernández D, Restrepo A. Mucormycosis (Zygomycosis) in a heart-kidney transplant recipient: recovery after posaconazole therapy. *Clin Infect Dis* 2003; 36: 1488 – 1491.
5. Roden M, Zaoutis T, Buchanan W, et al. Epidemiology and outcome of Zygomycosis: a review of 929 reported cases. *Clin Infect Dis* 2005; 41: 634 – 653
6. Petrikos G, Skiada A, Lortholary O, Roilides E, Walsh TJ, Kontoyiannis DP. Epidemiology and clinical manifestations of mucormycosis. *Clinical Infectious Diseases*. 2012 Feb 1;54(suppl\_1): S23-34.
7. Ribes JA, Vanover-Sams CL, Baker DJ. Zygomycetes in human disease. *Clin Microbiol Rev* 2000; 13:236–301.
8. <https://drfungus.org/knowledge-base/mucor-species/>
9. Camara-Lemarroy CR, González-Moreno EI, Rodríguez-Gutiérrez R, Rendón-Ramírez EJ, Ayala-Cortés AS, Fraga-Hernández ML, García-Labastida L, Galarza-Delgado DÁ. Clinical features and outcome of mucormycosis. *Interdisciplinary perspectives on infectious diseases*. 2014 Aug 20;2014.
10. Boelaert JR, Fenves AZ, Coburn JW. Deferoxamine therapy and mucormycosis in dialysis patients: report of an international registry.
11. *Am J Kidney Dis* 1991; 18:660–7. 94. Sugar AM. Mucormycosis. *Clin Infect Dis* 1992; 14(Suppl 1):S126–9.
12. Castrejón-Pérez AD, Welsh EC, Miranda I, Ocampo-Candiani J, Welsh O. Cutaneous mucormycosis. *Anais brasileiros de dermatologia*. 2017 May; 92:304-11.
- Ribes JA, Vanover-Sams CL, Baker DJ. Zygomycetes in human disease. *Clin Microbiol Rev* 2000; 13:236–301.
13. Sipsas NV, Gamaletsou MN, Anastasopoulou A, Kontoyiannis DP. Therapy of mucormycosis. *Journal of Fungi*. 2018 Sep;4(3):90.
14. Roden M, Zaoutis T, Buchanan W, et al. Epidemiology and outcome of Zygomycosis: a review of 929 reported cases. *Clin Infect Dis* 2005; 41: 634 – 653
15. Saegeman V, Maertens J, Ectors N, Meersseman W, Lagrou K. Epidemiology of mucormycosis: review of 18 cases in a tertiary care hospital. *Medical Mycology*. 2010 Mar 1;48(2):245-54.
16. Skiada A, Lanternier F, Groll AH, Pagano L, Zimmerli S, Herbrecht R, Lortholary O, Petrikos GL. Diagnosis and treatment of mucormycosis in patients with hematological malignancies: guidelines from the 3rd European Conference on Infections in Leukemia (ECIL 3). *haematologica*. 2013 Apr;98(4):492.
17. Cornely O, Arikan-Akdagli SE, Dannaoui E, Groll AH, Lagrou K, Chakrabarti A, Lanternier F, Pagano LI, Skiada A, Akova M, Arendrup MC. ESCMID and ECMM joint clinical guidelines for the diagnosis and management of mucormycosis 2013. *Clinical Microbiology and Infection*. 2014 Apr;20:5-26.
18. Werthman-Ehrenreich A. Mucormycosis with orbital compartment syndrome in a patient with COVID-19. *The American journal of emergency medicine*. 2021 Apr 1;42:264-e5.
19. Spellberg B, Edwards Jr J, Ibrahim A. Novel perspectives on mucormycosis: pathophysiology, presentation, and management. *Clinical microbiology reviews*. 2005 Jul;18(3):556-69.
20. Skiada A, Lass-Floerl C, Klimko N, Ibrahim A, Roilides E, Petrikos G. Challenges in the diagnosis and treatment of mucormycosis. *Medical mycology*. 2018 Apr 1;56(suppl\_1):S93-101.
21. Update on mucormycosis pathogenesis Ashraf S. Ibrahima,b,c and Dimitrios P. Kontoyiannisd aDivision of Infectious Diseases, Harbor-University of California Los Angeles Medical Center bSt. John's Cardiovascular Research Center, Los Angeles Biomedical Research Institute at Harbor-UCLA Medical Center, Torrance cDavid Geffen School of Medicine at UCLA, Los Angeles, California dDepartment of Infectious Diseases, Infection Control and Employee Health, The University of Texas M. D. Anderson Cancer Center, Houston, Texas, US
22. Ibrahim AS, Spellberg B, Walsh TJ, Kontoyiannis DP. Pathogenesis of mucormycosis. *Clinical Infectious Diseases*. 2012 Feb 1;54(suppl\_1):S16-22.
23. Risum M, Helweg-Larsen J, Petersen SL, Kampmann P, Overgaard UM, El Fassi D, Nielsen OJ, Brabrand M, Rubek N, Munksgaard L, Severinsen MT. Introduction of a Comprehensive Diagnostic and Interdisciplinary Management Approach in Haematological Patients with Mucormycosis: A Pre and Post-Intervention Analysis. *Journal of Fungi*. 2020 Dec;6(4):268.

24. Sipsas NV, Gamaletsou MN, Anastasopoulou A, Kontoyiannis DP. Therapy of mucormycosis. *Journal of Fungi*. 2018 Sep;4(3):90.
25. Jenks JD, Salzer HJ, Prattes J, Krause R, Buchheidt D, Hoeningl M. Spotlight on isavuconazole in the treatment of invasive aspergillosis and mucormycosis: design, development, and place in therapy. *Drug design, development and therapy*. 2018;12:1033.
26. Tedder, M., J. A. Spratt, M. P. Anstadt, S. S. Hegde, S. D. Tedder, and J. E. Lowe. 1994. Pulmonary mucormycosis: results of medical and surgical therapy. *Ann. Thorac. Surg.* 57:1044–1050.
27. Gleissner, B., A. Schilling, I. Anagnostopoulous, I. Siehl, and E. Thiel. 2004. Improved outcome of zygomycosis in patients with hematological diseases? *Leukemia Lymphoma* 45:1351–1360.
28. Dhiwakar, M., A. Thakar, and S. Bahadur. 2003. Improving outcomes in rhinocerebral mucormycosis—early diagnostic pointers and prognostic factors. *J. Laryngol Otol.* 117:861–865.
29. Talmi, Y. P., A. Goldschmied-Reouven, M. Bakon, I. Barshack, M. Wolf, Z. Horowitz, M. Berkowicz, N. Keller, and J. Kronenberg. 2002. Rhino-orbital and rhino-orbito-cerebral mucormycosis. *Otolaryngol. Head Neck Surg.* 127:22–31
30. Peterson, K. L., M. Wang, R. F. Canalis, and E. Abemayor. 1997. Rhinocerebral mucormycosis: evolution of the disease and treatment options. *Laryngoscope* 107:855–862
31. Straatsma, B. R., L. E. Zimmerman, and J. D. M. Gass. 1962. Phycomycosis: a clinicopathologic study of fifty-one cases. *Lab. Invest.* 11
32. Thajeb, P., T. Thajeb, and D. Dai. 2004. Fatal strokes in patients with rhino-orbito-cerebral mucormycosis and associated vasculopathy. *Scand. J. Infect. Dis.* 36:643–648
33. <https://www.ncbi.nlm.nih.gov/pmc/articles/PMC4542574/>

