

Gross Morphological Peculiarities of Tongue in Bewick Swan (*Cygnus columbianus*)

¹Firdous AD, ¹Mausood J, ¹Rezzaque C. Massarat Khan, ¹Andleeb R, ¹Shazia N and ²Umar N

¹Division of Veterinary Anatomy and Histology, FVSC & AH, Shuhama Alusteng,
SKUAST- K

²Department of Wildlife Jammu and Kashmir India

Corresponding author: drromey@gmail.com

Abstract

The present study was conducted on the tongue of the Bewick Swan (*Cygnus columbianus*). The tongue as a prehensile organ is involved in the food intake and in ingestion. Bewick swan is often poached when they migrate to their unusual habitat. Studying of the gross morphological characters besides adding to the knowledge anatomy will also act an aid in identifying during forensic cases and other pathological conditions. The tongue of Bewick Swan consisted of apex, body with lingual prominence and the root. The tongue was attached to the lower bill by the frenulum. The tongue was long and oval shaped characterized by a prominent longitudinal median sulcus which extends up to lingual prominence. Dorsal surface of the tongue along with the lateral borders presented numerous papilla of varying sizes while as ventral surface was smooth.

Keywords: Tongue, Bewick Swan, gross anatomy

Introduction

The name Bewick's swan given by William Yarrell (1830) after the engraver Thomas Bewick, who specialised in illustrations of birds and animals (Uglow, Jenny (2006). *C. columbianus* is the smallest of the Holarctic swans entirely white plumage with black feet, and a bill that is mostly black, with a thin salmon-pink streak or less yellow in the proximal part. Tongues have been divided into three main groups depending upon their structural adaptations which enhance their performance; tongues that are used to catch and intake food, tongues with plenty firm papillae on their dorsal surface used to hold and manipulate the food, and tongues that retain the food in the oral cavity before swallowing. Knowledge of the anatomy of the tongue is important to identify structural features that may influence nutrition, food intake and ingestion, as well as to provide a foundation for recognition of pathology in this region. Many studies on the lingual structure were done in domestic duck (Bello et al., 2015) Muscovy duck (Igwebuikie and Anagor., 2013), Pati duck (Sarma and Anil., 2015) mute swan (Sridevi et al., 2018) but very less in Bewick Swan. In this regard present study was aimed to document the gross morphological peculiarities of Tongue in Bewick Swan which in addition to adding the knowledge of anatomy also helps in identification during vetrolegal cases as well as to provide a foundation for recognition of pathology in this region.

Materials and methods

The poached body of Bewick swan was submitted to Division of Veterinary Anatomy by Department of Wildlife Jammu and Kashmir for preservation. The whole viscera were removed including tongue before preserving the rest of the bird. Tongue was rinsed in fresh water and immersed in 7 per cent formal saline. Various gross morphological parameters were recorded using a digital camera Redmi note 4. Then length and width of the tongue was also recorded with the measuring steel scale. The gross images of tongue with various views showing characteristic features were recorded.

Results and Discussion

Feeding is a complex process in vertebrates and includes ingestion, intraoral transport, and swallowing. The principal action of the tongue during feeding by birds is sieving in ducks and swans, spearing in woodpeckers, brushing in Trichglossidae, capillary tubing in sunbirds, and rasping in vulture (Pasand et al., 2010). Therefore, the structure of a bird's tongue is related to their different feeding habits, habitats, and different lifestyles on the land, in the air, as well as around fresh and sea waters (Emura.,2008). It is adapted for pecking, manipulating, filtering, and swallowing of the food (Erdogan and Iwasaki., 2014). The tongue is a muscular organ which is situated on the floor of the oral cavity and acts as the primary organ of taste as it is covered with papillae and taste buds (Whittow., 2000). The present work revealed that the tongue of Bewick swan was elongated spatula shaped consisted of the root, body with lingual prominence, and apex (Fig. 1). The tongue apex was smooth and non papillated on its dorsal surface and was shovel-shaped. The tongue also presented two surface and two lateral borders. The dorsal surface of the tongue was not flat but gave rounded like appearance while as ventral surface was attached to lower bill by the wide frenulum linguae. The tongue on its dorsal surface was divided by a groove which starts in a very shallow manner from apex, deepens much on the dorsum of body of tongue and then again shallows down towards the root of the tongue.

Two rows of conical papillae differentiate the lingual body from the root as same was recorded in mute swan (Sridevi et al., 2018). The upper row contains bigger papilla while as underneath row contains smaller papilla. The body of the tongue was attached to the lower bill by the wide frenulum linguae. Dorsum of the body and root of the tongue had mechanical papillae with different sizes and shapes. The lateral margins/borders also contain varying sized papilla. The rostral half of the lateral margins had numerous small horny conical papillae in agreement to Reda Mohamed (2019) in Muscovy duck, While the conical papillae in the caudal halves of the side edges of the tongue body were five in number and were broader, with a flattened plate shape and serrated edges with small hairy like papillae in between (Fig. 3). The base of the tongue had a triangular, bell-shaped lingual prominence dorsally, which was an elevated area, with rostral serrated edges and it is divided by the median groove into two symmetrical parts which was in accordance to the finding of El Bakary *et al* (2016) in *Anas crecca*. The lingual prominence also contains horny papilla. From the lingual prominence of the tongue a serrated white strap like structure deepens into the mid dorsal groove. The root of the tongue was in continuity to the laryngeal mound and

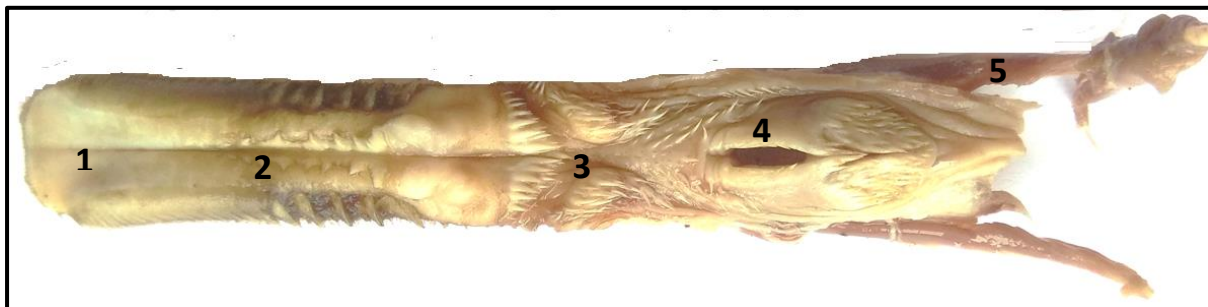

Fig. 1 Tongue of Bewick Swan

1. Apex 2. Body 3. Root 4. Laryngeal mound

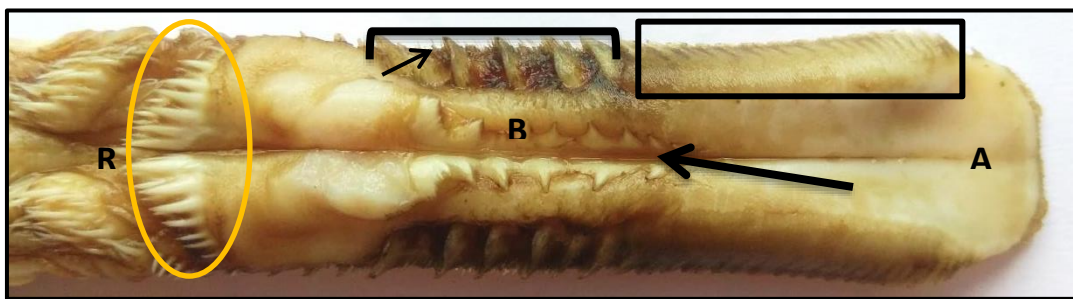


Fig. 2 Dorsum of the Tongue of Bewick Swan showing different papillae

A= Apex, B= Body, R= Root, Rectangular area = small conical papillae, Bracket= large conical papillae, Oval area=papillae on caudal border, Big Arrow= median groove, Small arrow=hairy papilla

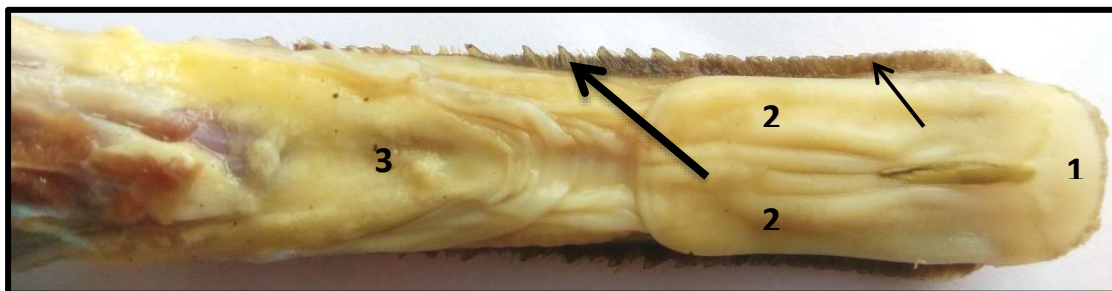


Fig. 3 Ventral surface of the Tongue of Bewick Swan

1. Apex of the tongue and its extension 2. Rectangular body halves 3. Attachment site of the frenulum linguae, Small conical papillae (small arrow), Large conical papillae (big arrow).

also covered by various papillae. There were two lateral mucosal swellings which were rounded papillae with spinal processes resembling filiform papillae. The two swellings were separated by a median ridge, which extended from the tongue base towards the laryngeal mound and containing papilla. Laryngeal mound contains laryngeal opening which also bears papilla. The ventral surface of tongue bears a lingual nail in the shape of rectangular plate on its anterior part which had smooth anterior end and the rest of the rectangular plate was covered by corrugated mucous membrane (Fig. 3). Similar observed by Abdalla et al in duck (2011). The tongue as well as larynx was supported by well-developed hyoid apparatus. The tongue was 7 cm long and 1.70 cm wide at apex narrows down to 1.10 at middle and then again widens at root portion to the equal width of that of apex. The rectangular nail on ventral aspect of tongue was 3.11cm long and 1.7cm wide.

References

- Abdalla KEH, Saleh AM, Abdel Galil Y, Mohamed SA, Alsayed AA. 2011. Post-hatching development of the duck tongue. Gross, morphometric and scanning electron microscopical study. *Egypt J Anat.* 32(1):401–14.
- Bello A, Onu JE, Jimoh MI, Olushola O. 2015. Morphometric observations of the tongue of the domestic duck (*Anas Platyrhynchos Domestica*). *Res J Phytomed;* 1(1):30–2.
- El Bakary NER, Abu-Almaaty AH, Sarah H. Ahmed SH, Hassan MK. 2016. Morphology of *anas crecca* (Common Teal) tongue. *Int J Adv Res;* 4(8):1782–90.
- Emura S, Okumura T, Chen H. 2008. Scanning electron microscopic study of the tongue in the peregrine falcon and common kestrel. *Okajimas Folia Anat Jpn;* 85(1):11–5;
- Erdoğan S, Iwasaki SI. 2014. Function-related morphological characteristics and specialized structures of the avian tongue. *Ann Anat Anatomisc Anzeiger.* 196(2):75–87;
- Igwebuike UM, Anagor TA. Morphology of the oropharynx and tongue of the muscovy duck (*Anas Platyrhynchos*). *Vet Arch* 2013; 83:685–693.
- Pasand AP, Tadjalli M, Mansouri H. 2010. Microscopic study on the tongue of male ostrich. *Eur J Biol Sci.* 2(2):24–31.
- Reda Mohamed. 2019. Histomorphological study on the tongue of the duck in the Caribbean with relation to feeding habit. *Journal of Advanced Veterinary and Animal Research.* 6: 1.,74–81
- Sarma K, Anil Deka A. 2015. Gross anatomical studies on the tongue of pati duck (*Anas platyrhynchos domesticus*). *Indian J Vet Anat;* 27(1):65–6.
- Sridevi P, Sreeranjini AR, Karthikeyan A, Lucy KM, Saranya KS, Ajith JG. 2018. Gross morphology of tongue of the mute swan (*Cygnus olor*). *Pharm Innov J;* 7(4):559–60.
- Uglow, Jenny (2006). *Nature's Engraver: A Life of Thomas Bewick*. Faber and Faber. p. 396. ISBN 978-0226823911.
- Whittow GC. 2000. *Sturkie's avian physiology*. Academic Press, New York, London.