

Root perforations: a review of diagnosis, prognosis and materialsYashvi Verma ¹, Sanjeev Tyagi ², Aishwarya Sahu ³, Anjali Satsangi ⁴¹ Post Graduate Student, Department of Conservative Dentistry and Endodontics, People's Dental Academy, Bhopal ,MP² Dean and Prof. & HOD- Department of Conservative Dentistry and Endodontics ,People's Dental Academy, Bhopal ,MP³ Department of Conservative Dentistry and Endodontics, People's Dental Academy, Bhopal ,MP⁴ Department of Conservative Dentistry and Endodontics, People's Dental Academy, Bhopal ,MP

ARTICLE INFO

Keywords: Root Canal Therapy;
Calcium Hydroxide

ABSTRACT

Root perforation results in the communication between root canal walls and periodontal space (external tooth surface). It is commonly caused by an operative procedural accident or pathological alteration (such as extensive dental caries, and external or internal inflammatory root resorption). Different factors may predispose to this communication, such as the presence of pulp stones, calcification, resorptions, tooth malposition (unusual inclination in the arch, tipping or rotation), an extra-coronal restoration or intracanal posts. The diagnosis of dental pulp and/or periapical tissue previous to root perforation is an important predictor of prognosis (including such issues as clinically healthy pulp, inflamed or infected pulp, primary or secondary infection, and presence or absence of intracanal post). Clinical and imaging exams are necessary to identify root perforation. Cone-beam computed tomography constitutes an important resource for the diagnosis and prognosis of this clinical condition. Clinical factors influencing the prognosis and healing of root perforations include its treatment timeline, extent and location. A small root perforation, sealed immediately and apical to the crest bone and epithelial attachment, presents with a better prognosis. The three most widely recommended materials to seal root perforations have been calcium hydroxide, mineral trioxide aggregate and calcium silicate cements. This review aimed to discuss contemporary therapeutic alternatives to treat root canal perforations. Accordingly, the essential aspects for repairing this deleterious tissue injury will be addressed, including its diagnosis, prognosis, and a discussion about the materials actually suggested to seal root canal perforation.

Introduction

Root perforation is characterized by a communication between the root canal system and the external tooth surface.¹ This issue can be caused by a pathological process (dental caries, root resorption) or an operative procedural accident. Pathological perforations are found in routine clinical exams, whereas iatrogenic root perforations may occur during access cavity opening, root canal preparation or during post preparation.^{2,3,4,5,6,7,8,9,10,11} Procedural operative errors may occur at any time in root canal treatment, and may cause the treatment to fail.¹²

Some factors may predispose to operative procedural accident or errors.¹²

The presence of pulp stones, calcification, misplaced tooth (incorrect inclination in the arch, tipping or rotation), extensive caries, internal root resorption, misidentification of the root canal, an extra-coronal restoration or intracanal posts are factors that may make root canal access difficult, and predispose to root perforation.^{2,3,4,5,6,7,8,9,10,11,12,13,14,15,16,17}

An insufficient access cavity reduces the quality of root canal debridement and may affect the final root canal preparation shape. An exaggerated or misdirected access cavity is also conducive to root perforation, and makes the tooth susceptible to coronal/radicular fracture.

Root perforation, overfilling, endodontic and periodontal lesions, root fracture, periapical biofilm, traumatic dental

injury, instrument fracture, apical periodontitis, and root resorption characterize the complex challenge facing the endodontist, and these may contribute (alone or in association) to a doubtful or poor prognosis.¹²

During the operative procedures, the endodontist must avoid and prevent these noxious events, since intra-operative accidents are risk factors that may result in failure of root canal treatment. Successful root canal treatment entails understanding the risk factors associated with root canal treatment failure.¹²

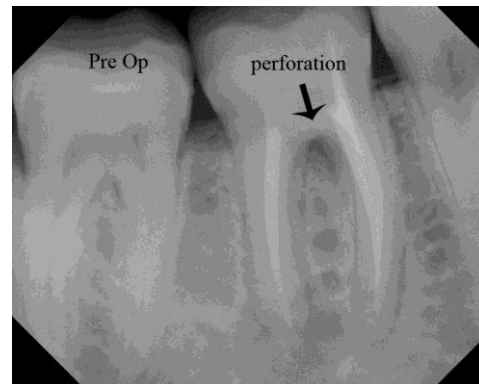
Root perforation may occur in different clinical conditions, which the patient should be immediately informed of, together with the procedures to be followed, the treatment options and the prognosis.¹⁰ It constitutes a serious complication which needs to be diagnosed early and treated immediately and appropriately.¹⁸⁻²⁰ The consequences of root perforation may result in an inflammatory response associated with periodontal tissue and alveolar bone destruction. Depending on the severity of the injury, and possible chronic inflammatory reaction, it may cause the development of granulomatous tissue, proliferation of the epithelium, and, eventually, the development of a periodontal pocket.^{9,19,21,22}

Lack of understanding of root perforations and their consequences, to the extent that could delay diagnosis and treatment, may cause future problems leading to tooth loss. This review aimed to discuss contemporary therapeutic alternatives to treat root canal perforations. Accordingly, the essential aspects for repairing this noxious operative accident will be addressed, including its diagnosis, its prognosis, and a discussion about the materials used to seal root canal perforation.

Diagnosis and prognosis of root perforation

Several clinical findings may be determinant in diagnosing root perforations. The clinical and radiographical exams constitute the basis of root

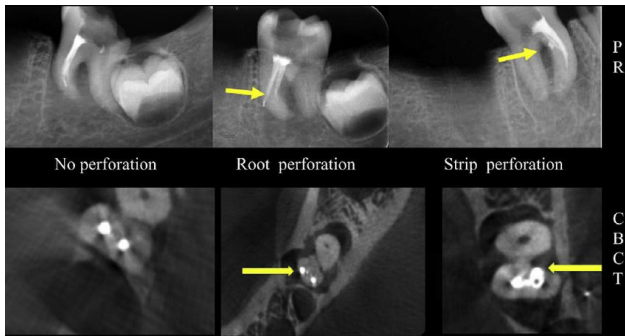
perforation diagnosis.^{5,7,9,10,15,23,24,25,26} During vital root canal preparation (pulp is emptied), the radicular pulp may be removed by pulpectomy (when the pulp is excised, or when root canals are narrow, removal is by fragmentation). After removal of pulp tissue, persistent bleeding during coronal access or root canal preparation may be a sign of perforation. A paper point with blood may also suggest perforation.



Systemic conditions, medications, teeth with an open apex and internal resorption and acute apical periodontitis may be associated excessive bleeding, and be confused with root perforation. Clinically, its diagnosis is a challenge^{10,12,14} however, the apex locator is a technological resource that may help in diagnosing root perforation.^{27,28}

Periapical radiography is the imaging method frequently indicated for endodontic diagnosis, treatment plan, and follow-up.^{23,24}

A radiolucency associated with a communication between the root canal walls and the periodontal space constitutes an important vestige of this procedural accident. The incorporation of cone-beam computed tomography (CBCT) in endodontic procedures ensures new parameters to aid in the diagnosis and prognosis of these pathologic and iatrogenic conditions.²⁹⁻³⁹



Shemesh et al.³⁸ compared ex vivo the sensitivity and specificity of CBCT scans and digital periapical radiographs (PR) in detecting strip and root perforations in 45 curved mesial roots of mandibular molars. The risk in misdiagnosing strip perforations was high with both methods, but CBCT scans showed a significantly higher sensitivity than PR. There was no significant difference between the methods for detection of root perforations. An essential factor to consider is whether or not an endodontically treated tooth is associated with a root perforation. The diagnosis of root perforation in endodontically treated teeth may be complex.

Diagnostic errors occur and constitute a serious problem; errors are frequently detected in association with a metallic or solid structure of higher density, which produces an image artifact, lacking homogeneity and being defined by image contrasts. Misdiagnosis is a serious problem that has encouraged the search for alternatives to reduce the beam hardening effect during image acquisition and reconstruction.^{40,41,42}

Metallic artifacts associated with intracanal posts constitute potential risks for misdiagnosis, particularly when root perforation or bone destruction is suspected.^{29,38,39}

A map-reading strategy to diagnose root perforations near metallic intracanal posts using CBCT images was previously suggested by Bueno et al.²⁹ The strategy suggested minimizing metallic artifacts associated with intracanal post and endodontic material by making

sequential axial slices of each root with an image navigation protocol from the coronal to the apical direction (or apical to coronal), and with axial slices of 0.1 mm/ 0.1 mm. This directional orientation provides precious information concerning the exact localization of vestiges that suggest points of communication between the root canals and the periodontal space, associated with radiolucent areas, suggesting root perforation.

The dynamic navigation of CBCT images has made it a distinct tool by revealing what was once static. In the slices located near the post apex, the beam hardening effect is reduced, because CBCT allows us to capture a lesser amount of metal on the images.²⁹ A new software program able to reduce metallic artifacts in future reconstructions of CBCT images has been tested (e.g., e-Vol DX, CDT, Bauru, SP, Brazil). The appropriate management of CBCT images could reveal abnormalities that are difficult to detect in conventional periapical radiographies.^{35,36,37}

The final diagnosis and choice of clinical therapeutics for these root perforations should always be made in conjunction with the clinical findings. The major potential of CBCT examinations is the possibility of viewing the different planes of all the surfaces and the location of the tooth, at the same time.²⁹ After a root perforation is diagnosed, root canal treatment can be challenging. Root perforation could affect the prognosis of root canal treatment and retreatment.

Three clinical factors have been considered as relevant in the prognosis and healing of root perforations: time (the time between the occurrence of the perforation and the appropriate filling); extent (a small perforation causes less tissue destruction and inflammatory response); location (perforations located apical to the critical zone, involving the level of the crestal bone and the epithelial attachment, are likely to have a good prognosis when the

root canal is accessible and the treatment is appropriate).⁷ Thus, clinical parameters associated with the timeline (avoiding the onset of infection), with the severity of the tissue injury, and with its location in relation to the crestal bone, are factors essential to treatment prognosis.^{7,8,9}

It has been suggested that perforations located apical or coronal to the crest bone and epithelial attachment have a good prognosis.^{7,43,44} The therapeutic factors associated with the clinical protocols used during root canal treatment, and the systemic conditions associated with the periapical healing process of endodontically treated teeth, were recently discussed by Holland et al.⁴⁵

The repair process of endodontically treated teeth depends not only on the adoption of correct clinical approaches to promote better root canal treatment, but also on patient-related factors (such as chronic disease, hormones and age), and those that can change the host's immune defenses and interfere in the treatment outcomes and healing process. Thus, the risk factors of root canal treatment failures (such as systemic disease and periodontal status) must be addressed correctly during the treatment plan.

Treatment success is influenced by the preoperative status of the dental pulp, associated with the presence or absence of a preoperative periapical lesion. The diagnosis of dental pulp and/ or periapical tissue previous to root perforation is an important predictor of prognosis (including such issues as clinically healthy pulp, inflamed or infected pulp, and primary or secondary infection).²⁵ Each clinical case must be analyzed carefully and individually, in order to determine the presence or absence of infection, the extent of perforation, the time elapsed before sealing, and the periodontal risk to the patient, to see whether or not the disease could interfere directly in the prognosis.

The ability to access the perforation area and promote an appropriate sealing, and the pathological conditions, are clinical determinants of success or failure. In root perforation due to over-instrumentation, resulting in over-enlargement of the apical foramen, the treatment consists of determining a new working length, 1-2 mm short of the root apex, in which the main cone will fit tightly. An apical plug with calcium hydroxide should be maintained in the apex, and the remainder of the root canal should be filled.

Clinical and radiographic follow-up should be conducted to determine success or failure. A surgical procedure (periapical surgery) is still an option if failure occurs. Root perforation near the apex presents a good prognosis, and those that are smaller in extent are easier to seal. The survival of an endodontically treated tooth, especially one with a history of root perforation, depends on understanding the biological and mechanical outcomes as multifactorial events over the individual's life span.^{10,12,25}

Tooth type, strategic position of the tooth (or surface of the tooth) and the level of the perforation influence the complexity of treatment. In lateral perforations, the relation of the crestal bone to the perforation may favor a good prognosis and sealing. In furcal perforations in molars, the major issue is the degree of tissue damage and the possibility of communication with the gingival sulcus. The probable extrusion of adhesive materials to seal large perforations constitutes a common occurrence. In small furcal perforations, the prognosis is favorable.^{7,9,11,20} An important clinical feature is the thickness of the gingival and bone tissue, since a better prognosis occurs in patients with thick gingival and bone tissues.⁴⁶

Overall, the sealing of a root perforation has shown a high level of success; however, the impact of new

therapeutic procedures on the prognosis of endodontic therapy should be carefully considered. Materials used to seal root perforations The endodontic literature published over the years presents reports on several intracanal medicaments that have been studied to treat infected root canals.

The material requirements of perforation repair materials vary depending on whether the perforation is located inside (intraradicular) or outside the root canal (extraradicular).

Requirements of root perforation repair materials used in the canal:

- Ability to induce bone and cementum formation;
- Biocompatible;
- Ability to provide a fluid-tight seal; • Bacteriostatic;
- Radiopaque;
- Non-resorbable;
- Non-carcinogenic;
- Readily available;
- Easy-to-use and relatively inexpensive^{23,25,27,28}.

Additional requirements:

- Ability to provide a bacteria-tight seal;
- Unaffected by blood;
- It should be possible to prevent extrusion of the material into the surrounding tissues^{21,23}

Amalgam²⁰; Cavit²¹; Composite; Dentine chips; Foils (Teflon and indium foil, etc.); resin-modified glass-ionomercement (compomer) especially developed for the repair of severe cervical defects based on its good adhesion to dentine; Glass ionomer cement (GIC); Hydroxyapatite (HA); Zinc oxide-eugenol (ZOE) cement reinforced with plastic additives ;Calcium hydroxide; Freeze-dried bone; Mineral trioxide aggregate (MTA) with collagen; Plaster of Paris (calcium sulfate/burnt

gypsum); Tricalcium phosphate have been tested as perforation repair material

Calcium hydroxide has been extensively evaluated, and shows well-documented results.⁴⁷⁻⁸⁰ However, new materials for sealing root perforations of iatrogenic and pathological origin have been made available for endodontics.⁸¹⁻¹⁴¹

Nowadays, the materials demonstrating antibacterial potential for infection control of the root canal system promote healing by mineralized tissue deposition and sealing ability. As such, they were selected to be the focus of attention of this review.⁴⁷⁻¹⁴⁷

Accordingly, three materials to seal root perforations were analyzed retrospectively, based on their biological, antimicrobial and physicochemical characteristics, namely calcium hydroxide, mineral trioxide aggregate and calcium silicate cements (bioceramics).

Mineral trioxide aggregate (MTA)

Mineral trioxide aggregate is still a widely accepted and commonly used repair material for perforations at bone level. MTA improves the prognosis of perforated teeth that would otherwise be classified as compromised.

Mode of action of MTA

The mode of action of MTA is based on the following mechanisms:

- Formation of Ca(OH)₂ and its release of calcium ions;
- Alkaline pH of about 12.532;
- Effects on cytokine production;
- Promotes the differentiation and migration of cells involved in hard tissue formation;
- Formation of hydroxyapatite on the surface of MTA.

Bioceramics

Bioceramics are non-metallic inorganic materials that were already well-known for their applications in the medical field (e.g. for joint replacement) before they were introduced in endodontics around 2008. They can

be used as sealers as well as for orthograde and retrograde root canal filling, root perforation repair, pulp capping and apexification^{76,77}.

Their enhanced biocompatibility gives new bioceramic materials an edge over conventional sealing materials⁷⁸. One *in vitro* study demonstrated the adhesion, proliferation and survival of human bone marrow mesenchymal stem cells, periodontal ligament cells, and dental pulp stem cells on the surface of a newly developed bioceramic material⁷⁹. Another advantage is that, in contrast to MTA, bioceramics do not lead to coronal tooth discoloration⁸⁰.

Clinical overview

The life of an endodontically treated tooth is associated with correct diagnosis and treatment planning, root canal shaping, sanitization, sealing, and, lastly, tooth rehabilitation.²⁵ The successful treatment of a root perforation depends on certain factors, like sealing material, perforation extent and location, time between diagnosis and treatment, presence of contamination and related operator experience, presence of preoperative lesions, communication of the perforation with the oral environment, and type and quality of the final restoration.^{7,130,138}

The material recommended for treatment of root canal perforations should have good physicochemical and biological properties, proper sealing capacity, antimicrobial activity and osteogenic potential.⁴⁵

MTA has been the most widely indicated material to seal root perforations.^{9,10,11,22,45,70,71,72,82-104} Histological studies have shown lateral and furcal perforations that have been repaired with MTA, and that have been found to have mineralized tissue over the material.^{22,89}

Clinical studies have shown that MTA appears to provide a biocompatible and long-term effective seal for root perforation, with a higher success rate.^{111,112,138,146}

Pontius et al.¹⁴⁶ analyzed retrospectively the clinical outcome of 70 perforation repairs performed by 6 endodontic specialists, using a nonsurgical or combined nonsurgical/surgical approach. The success rate for repair of the root perforation was 90%.

Siew et al.¹³⁸, based on a systematic review using clinical studies published from 1950 to mid-2014, evaluated the treatment outcome of repaired root perforations and identified any preoperative factors that could influence the outcome of the repair. Seventeen studies were included for systematic review and 12 qualified for meta-analysis.

An overall pooled success rate of 72.5% (CI, 61.9%–81.0%) was estimated for nonsurgical repair of root perforations. The use of MTA appeared to enhance the success rate to 80.9% (CI, 67.1%–89.8%). The presence of a preexisting radiolucency adjacent to the perforation site fared a lower chance of success after repair. The authors concluded that nonsurgical repair of root perforation results in a success rate of over 70%. Teeth in the maxillary arch and absence of preoperative radiolucency adjacent to the perforation are favorable preoperative factors for healing after perforation repair.

Conclusions

Root perforation during operative procedures should be prevented. Diagnosis and immediate sealing, intensity of aggression, control of contamination, relationship to crestal bone and epithelial attachment are factors that have an impact on the prognosis. Physicochemical, histological and clinical studies have indicated MTA as a good sealer for these situations, but one which lacks a good esthetic outcome.

References

1. American Association of Endodontists. Glossary of endodontic terms. 9th ed. Chicago: American Association of Endodontists; 2016.
2. Nicholls E. Treatment of traumatic perforations of the pulp cavity. *Oral Surg Oral Med Oral Pathol.* 1962 ;15(5):603-12.
3. Seltzer S, Sinai I, August D. Periodontal effects of root perforations before and during endodontic procedures. *J Dent Res.* 1970 ;49(2):332-9.
4. Frank AL, Weine FS. Nonsurgical therapy for the perforative defect of internal resorption. *J Am Dent Assoc.* 1973 ;87(4):863-8.
5. Frank AL. Resorption, perforations, and fractures. *Dent Clin North Am.* 1974;18(2):465-87.
6. Oswald RJ. Procedural accidents and their repair. *Dent Clin North Am.* 1979 ;23(4):593-616.
7. Fuss Z, Trope M. Root perforations: classification and treatment choices based on prognostic factors. *Endod Dent Traumatol.* 1996 ;12(6):255-64.
8. Roda RS. Root perforation repair: surgical and nonsurgical management. *Pract Proced Aesthet Dent.* 2001 ;13(6):467-72.
9. Tsesis I, Fuss Z. Diagnosis and treatment of accidental root perforations. *Endod Topics.* 2006 ;13(1):95-107
10. Estrela C, Biffi JC, Moura MS, Lopes HP. Treatment of endodontic failure. In: Estrela C. *Endodontic Science.* 2nd ed. São Paulo: Artes Médicas; 2009. p917-52.
11. Roda RS, Gettleman BH. Nonsurgical retreatment. In: Hargreaves KM, Berman LH, editors. *Cohen's Pathways of the pulp.* 11th ed. St. Louis: Elsevier; 2016. p. 324-86.
12. Estrela C, Pécora JD, Estrela CRA, Guedes OA, Silva BS, Soares CJ et al. Common operative procedural errors and clinical factors associated with root canal treatment. *Braz Dent J.* 2017 ;28(2):179-90.
13. Seltzer S. *Endodontology: biologic considerations in endodontic procedures.* 2nd ed. Philadelphia: Lea & Febiger; 1988. Root canal failures; p. 439-70.
14. Alhadainy HA. Root perforations: a review of literature. *Oral Surg Oral Med Oral Pathol.* 1994 ;78(3):368-74.
15. Guldner PH. Perforaciones accidentales. Guldner PHA, Langeland K. *Endodoncia: diagnóstico y tratamiento.* Barcelona: Springer; 1995.
16. Friedman S. Retreatment of failures. In: Walton RE, Torabinejad M, editors. *Principles and practices of endodontics.* 2nd ed. Philadelphia: WB Saunders; 1996. p. 336-53.
17. Ruddle CJ. Nonsurgical endodontic retreatment. In: Cohen S, Burns RC, editors. *Pathways of the pulp.* 8th ed. St Louis: Mosby; 2002. p. 875-929.
18. Farzaneh M, Abitbol S, Friedman S. Treatment outcome in endodontics: the Toronto study: Phases I and II: Orthograde retreatment. *J Endod.* 2004 ;30(9):627-33.
19. Touré B, Faye B, Kane AW, Lo CM, Niang B, Boucher Y. Analysis of reasons for extraction of endodontically treated teeth: a prospective study. *J Endod.* 2011 ; 37(11):1512-5.
20. Clauder T, Shin SJ. Repair of perforations with MTA: clinical applications and mechanisms of action. *Endod Topics.* 2006 ;15(1):32-55.
21. Seltzer S. *Endodontology: biologic considerations in endodontic procedures.* 2nd ed. Philadelphia: Lea & Fabiger; 1988. Repair following root canal therapy; p. 389-438.
22. Holland R, Otobani Filho JA, Souza V, Nery MJ, Bernabé PF, Dezan Junior E. Mineral trioxide aggregate repair of lateral root perforations. *J Endod.* 2001 ;27(4):281-4.
23. Grossman LI, Shepard LI, Pearson LA. Roentgenologic and clinical evaluation of endodontically

treated teeth. *Oral Surg Oral Med Oral Pathol.* 1964 ;17(3):368-74.

24. Seltzer S, Bender IB, Smith J, Freedman I, Nazimov H. Endodontic failures—an analysis based on clinical, roentgenographic, and histologic findings. I. *Oral Surg Oral Med Oral Pathol.* 1967 ;23(4):500-16.

25. Estrela C, Holland R, Estrela CR, Alencar AH, SousaNeto MD, Pécora JD. Characterization of successful root canal treatment. *Braz Dent J.* 2014 ;25(1):3-11.

26. Silva JA, de Alencar AH, da Rocha SS, Lopes LG, Estrela C. Three-dimensional image contribution for evaluation of operative procedural errors in endodontic therapy and dental implants. *Braz Dent J.* 2012;23(2):127-34.

27. Kaufman AY, Keila S. Conservative treatment of root perforations using apex locator and thermatic compactor— case study of a new method. *J Endod.* 1989;15(6):267-72.

28. Kaufman AY, Fuss Z, Keila S, Waxenberg S. Reliability of different electronic apex locators to detect root perforations in vitro. *Int Endod J.* 1997 ;30(6):403-7.

29. Bueno MR, Estrela C, De Figueiredo JA, Azevedo BC. Map-reading strategy to diagnose root perforations near metallic intracanal posts by using cone beam computed tomography. *J Endod.* 2011 ;37(1):85-90.

30. Arai Y, Tammissalo E, Iwai K, Hashimoto K, Shinoda K. Development of a compact computed tomographic apparatus for dental use. *Dentomaxillofac Radiol.* 1999 ;28(4):245-8.

31. Mozzo P, Procacci C, Tacconi A, Martini PT, Andreis IA. A new volumetric CT machine for dental imaging based on the cone-beam technique: preliminary results. *Eur Radiol.* 1998;8(9):1558-64.

32. Scarfe WC, Farman AG, Sukovic P. Clinical applications of cone-beam computed tomography in dental practice. *J Can Dent Assoc.* 2006 ;72(1):75-80.

33. Cotton TP, Geisler TM, Holden DT, Schwartz SA, Schindler WG. Endodontic applications of cone-beam volumetric tomography. *J Endod.* 2007 ;33(9):1121-32.

34. Scarfe WC, Farman AG. What is cone-beam CT and how does it work? *Dent Clin North Am.* 2008;52(4):707-30.

35. Patel S, Dawood A, Ford TP, Whaites E. The potential applications of cone beam computed tomography in the management of endodontic problems. *Int Endod J.* 2007 ;40(10):818-30.

36. Estrela C, Bueno MR, Leles CR, Azevedo B, Azevedo JR. Accuracy of cone beam computed tomography and panoramic and periapical radiography for detection of apical periodontitis. *J Endod.* 2008;34(3):273-9.

37. Estrela C, Bueno MR, Azevedo BC, Azevedo JR, Pécora JD. A new periapical index based on cone beam computed tomography. *J Endod.* 2008 ;34(11):1325-31.

38. Shemesh H, Cristescu RC, Wesselink PR, Wu MK. The use of cone-beam computed tomography and digital periapical radiographs to diagnose root perforations. *J Endod.* 2011 ;37(4):513-6.

39. Adel M, Tofangchiha M, Yeganeh LA, Javadi A, Khojasteh AA, Majd NM. Diagnostic accuracy of cone-beam computed tomography and conventional periapical radiography in detecting strip root perforations. *J Int Oral Health.* 2016 ;8(1):75-9.

40. Pauwels R, Araki K, Siewerdsen JH, Thongvigitmanee SS. Technical aspects of dental CBCT: state of the art. *Dentomaxillofac Radiol.* ;44(1):20140224.

41. Katsumata A, Hirukawa A, Noujeim M, Okumura S, Naitoh M, Fujishita M, et al. Image artifact in dental

- cone-beam CT. *Oral Surg Oral Med Oral Pathol Oral Radiol Endod.* 2006 ;101(5):652-7.
42. Azevedo B, Lee R, Shintaku W, Noujeim M, Nummikoski P. Influence of the beam hardness on artifacts in cone-beam CT. *Oral Surg Oral Med Oral Pathol Oral Radiol Endod.* 2008 ;105(4):e48.
43. Lemon RR. Nonsurgical repair of perforation defects. Internal matrix concept. *Dent Clin North Am.* 1992 ;36(2):439-57.
44. Himel VT, Brady J Jr, Weir J Jr. Evaluation of repair of mechanical perforations of the pulp chamber floor using biodegradable tricalcium phosphate or calcium hydroxide. *J Endod.* 1985 Apr;11(4):161-5.
45. Holland R, Gomes JE, Cintra LT, Queiroz ÍO, Estrela C. Factors affecting the periapical healing process of endodontically treated teeth. *J Appl Oral Sci.* 2017 ;25(5):465-76.
46. Regan JD, Witherspoon DE, Foyle DM. Surgical repair of root and tooth perforations. *Endod Topics.* 2005 ;11(1):152-78.
47. Hermann BW. Calciumhydroxyd als mittel zurn behandel und f?llen vonxahnwurzelkan?len. (Doctoral Thesis) W?rzburg; 1920. 50p.
48. Sciaky I, Pisanti S. Localization of calcium placed over amputated pulps in dogs' teeth. *J Dent Res.* 1960 ;39(6):1128-32.
49. Pisanti S, Sciaky I. Origin of calcium the repair wall after pulp exposure in the dog. *J Dent Res.* 1964 ;43(5):641-4.
50. Mitchell DF, Shankwalker GB. Osteogenic potential of calcium hydroxide and other materials in soft tissue and bone wounds. *J Dent Res.* 1958 ;37(6):1157-63.
51. Holland R. Histochemical response of amputated pulps to calcium hydroxide. *Rev Bras Pesqui Med Biol.* 1971;4:83-95.
52. Heithersay GS. Periapical repair following conservative endodontic therapy. *Aust Dent J.* 1970 ;15(6):511-8.
53. Heithersay GS. Calcium hydroxide in the treatment of pulpless teeth with associated pathology. *J Br Endod Soc.* 1975 ;8(2):74-93.
54. Holland R, Mello W, Nery MJ, Bernabe PF, Souza V. Reaction of human periapical tissue to pulp extirpation and immediate root canal filling with calcium hydroxide. *J Endod.* 1977 ;3(2):63- 7.
55. Holland R, Souza V, Nery MJ, Bernabé F, Otoboni Filho JA, Dezan Junior E, et al. Calcium salts deposition in rat connective tissue after the implantation of calcium hydroxidecontaining sealers. *J Endod.* 2002 ;28(3):173-6.
56. Holland R, Nery MJ, Mello W, Souza V, Bernabé PF, Otoboni Filho JA. Root canal treatment with calcium hydroxide. I. Effect of overfilling and refilling. *Oral Surg Oral Med Oral Pathol.* 1979 ;47(1):87-92.
57. Holland R, Nery MJ, Mello W, Souza V, Bernabé PF, Otoboni Filho JA. Root canal treatment with calcium hydroxide. II. Effect of instrumentation beyond the apices. *Oral Surg Oral Med Oral Pathol.* 1979 ;47(1):93-6.
58. Holland R, Nery MJ, Mello W, Souza V, Bernabé PF, Otoboni Filho JA. Root canal treatment with calcium hydroxide. III. Effect of debris and pressure filling. *Oral Surg Oral Med Oral Pathol.* 1979 ;47(2):185-8.
59. Stanley HR, Pameijer CH. Dentistry's friend: calcium hydroxide. *Oper Dent.* 1997 J;22(1):1-3.
60. Tronstad L, Andreasen JO, Hasselgren G, Kristerson L, Riis I. pH changes in dental tissues after root canal filling with calcium hydroxide. *J Endod.* 1981 ;7(1):17-21.

61. Holland R, Souza V. Ability of a new calcium hydroxide root canal filling material to induce hard tissue formation. *J Endod.* 1985 ;11(12):535-43.
62. Trope M, Tronstad L. Long-term calcium hydroxide treatment of a tooth with iatrogenic root perforation and lateral periodontitis. *Endod Dent Traumatol.* 1985;1(1):35-8.
63. Estrela C, Sydney GB, Bammann LL, Felipe Júnior O. Mechanism of action of calcium and hydroxyl ions of calcium hydroxide on tissue and bacteria. *Braz Dent J.* 1995;6(2):85-90.
64. Holland R, Otoboni Filho JA, Souza V, Nery MJ, Bernabé PF, Dezan Júnior E. Calcium hydroxide and a corticosteroidantibiotic association as dressings in cases of biopulpectomy. A comparative study in dogs' teeth. *Braz Dent J.* 1998;9(2):67-76.
65. Estrela C, Pimenta FC, Ito IY, Bammann LL. In vitro determination of direct antimicrobial effect of calcium hydroxide. *J Endod.* 1998 ;24(1):15-7.
66. Estrela C, Pimenta FC, Ito IY, Bammann LL. Antimicrobial evaluation of calcium hydroxide in infected dentinal tubules. *J Endod.* 1999 ;25(6):416-8.
67. Estrela C, Pécora JD, Sousa-Neto MD, Estrela CRA, Bammann LL. Effect of vehicle on antimicrobial properties of calcium hydroxide paste. *Braz Dent J.* 1999 ;10(2):63-72.
68. Holland R, de Souza V, Nery MJ, Otoboni Filho JA, Bernabé PF, Dezan Júnior E. Reaction of rat connective tissue to implanted dentin tubes filled with mineral trioxide aggregate or calcium hydroxide. *J Endod.* 1999 ;25(3):161-6.
69. Seux D, Couble ML, Hartmann DJ, Gauthier JP, Magloire H. Odontoblast-like cytodifferentiation of human dental pulp cells in vitro in the presence of a calcium hydroxidecontaining cement. *Arch Oral Biol.* 1991;36(2):117-28.
70. Holland R, Souza V, Nery MJ, Faraco Júnior IM, Bernabé PF, Otoboni Filho JA et al. Reaction of rat connective tissue to implanted dentin tube filled with mineral trioxide aggregate, Portland cement or calcium hydroxide. *Braz Dent J.* 2001;12(1):3-8.
71. Holland R, Souza V, Murata SS, Nery MJ, Bernabé PF, Otoboni Filho JA et al. Healing process of dog dental pulp after pulpotomy and pulp covering with mineral trioxide aggregate or Portland cement. *Braz Dent J.* 2001;12(2):109-13.
72. Holland R, Souza V, Nery MJ, Faraco Júnior IM, Bernabé PF, Otoboni Filho JA et al. Reaction of rat connective tissue to implanted dentin tubes filled with a white mineral trioxide aggregate. *Braz Dent J.* 2002;13(1):23-6.
73. Holland R, Otoboni Filho JA, de Souza V, Nery MJ, Bernabé PF, Dezan E Jr. A comparison of one versus two appointment endodontic therapy in dogs' teeth with apical periodontitis. *J Endod.* 2003 ;29(2):121-4.
74. Mizuno M, Banzai Y. Calcium ion release from calcium hydroxide stimulated fibronectin gene expression in dental pulp cells and the differentiation of dental pulp cells to mineralized tissue forming cells by fibronectin. *Int Endod J.* 2008 ;41(11):933-8.
75. Thompson SW, Hunt RD. Selected histochemical and histopathological methods. Flórida: Charles C Thomas; 1966. p. 615-46.
76. Siqueira Junior JF, Uzeda M. Disinfection by calcium hydroxide pastes of dentinal tubules infected with two obligate and one facultative anaerobic bacteria. *J Endod.* 1996 ;22(12):674-6.
77. Gomes BP, Ferraz CC, Garrido FD, Rosalen PL, Zaia AA, Teixeira FB et al. Microbial susceptibility to calcium hydroxide pastes and their vehicles. *J Endod.* 2002 ;28(11):758-61.

78. Wucherpfening AL, Green DB. Mineral trioxide aggregate vs Portland cement: two biocompatible filling materials [Abstract]. *J Endod.* 1999;25(4):308.
79. Estrela C, Bammann LL, Estrela CR, Silva RS, Pécora JD. Antimicrobial and chemical study of MTA, Portland cement, calcium hydroxide paste, Sealapex and Dycal. *Braz Dent J.* 2000;11(1):3-9.
80. Mohammadi Z, Dummer PM. Properties and applications of calcium hydroxide in endodontics and dental traumatology. *Int Endod J.* 2011;44(8):697-730.
81. Lee SJ, Monsef M, Torabinejad M. Sealing ability of a mineral trioxide aggregate for repair of lateral root perforations. *J Endod.* 1993 ;19(11):541-4.
82. Torabinejad M, Watson TF, Pitt Ford TR. Sealing ability of a mineral trioxide aggregate when used as a root end filling material. *J Endod.* 1993 ;19(12):591-5.
83. Torabinejad M, Higa RK, McKendry DJ, Pitt Ford TR. Dye leakage of four root end filling materials: effects of blood contamination. *J Endod.* 1994 ;20(4):159-63.
84. Torabinejad M, White DJ. Tooth filling material and use. United States Patent & Trademark Office. Patent Number 5,769,638, , 1995.
85. Torabinejad M, Hong CU, McDonald F, Pitt Ford TR. Physical and chemical properties of a new rootend filling material. *J Endod.* 1995 ;21(7):349-53.
86. Torabinejad M, Hong CU, Pitt Ford TR, Kariyawasam SP. Tissue reaction to implanted super-EBA and mineral trioxide aggregate in the mandible of guinea pigs: a preliminary report. *J Endod.* 1995 Nov;21(11):569-71.
87. Torabinejad M, Rastegar AF, Kettering JD, Pitt Ford TR. Bacterial leakage of mineral trioxide aggregate as a rootend filling material. *J Endod.* 1995 ;21(3):109-12.
88. Torabinejad M, Hong CU, Lee SJ, Monsef M, Pitt Ford TR. Investigation of mineral trioxide aggregate for rootend filling in dogs. *J Endod.* 1995 ;21(12):603-8.
89. Ford TR, Torabinejad M, McKendry DJ, Hong CU, Kariyawasam SP. Use of mineral trioxide aggregate for repair of furcal perforations. *Oral Surg Oral Med Oral Pathol Oral Radiol Endod.* 1995 ;79(6):756-63.
90. Arens DE, Torabinejad M. Repair of furcal perforations with mineral trioxide aggregate: two case reports. *Oral Surg Oral Med Oral Pathol Oral Radiol Endod.* 1996 ;82(1):84-8.
91. Koh ET, Torabinejad M, Pitt Ford TR, Brady K, McDonald F. Mineral trioxide aggregate stimulates a biological response in human osteoblasts. *J Biomed Mater Res.* 1997 ;37(3):432-9.
92. Torabinejad M, Pitt Ford TR, McKendry DJ, Abedi HR, Miller DA, Kariyawasam SP. Histologic assessment of mineral trioxide aggregate as root end filling in monkeys. *J Endod.* 1997 Apr;23(4):225-8.
93. Torabinejad M, Ford TR, Abedi HR, Kariyawasam SP, Tang HM. Tissue reaction to implanted root-end filling materials in the tibia and mandible of guinea pigs. *J Endod.* 1998 ;24(7):468-71.
94. Mitchell PJ, Pitt Ford TR, Torabinejad M, McDonald F. Osteoblast biocompatibility of mineral trioxide aggregate. *Biomaterials.* 1999;20(2):167-73.
95. Torabinejad M, Chivian N. Clinical applications of mineral trioxide aggregate. *J Endod.* 1999 ;25(3):197-205.
96. Ford TR, Torabinejad M, Abedi HR, Bakland LK, Kariyawasam SP. Using mineral trioxide aggregate as a pulpcapping material. *J Am Dent Assoc.* 1996;127(10):1491-4.
97. Ferris DM, Baumgartner JC. Perforation repair comparing two types of mineral trioxide aggregate. *J Endod.* 2004;30(6):422-4.

98. Main C, Mirzayan N, Shabahang S, Torabinejad M. Repair of root perforations using mineral trioxide aggregate: a long-term study. *J Endod.* 2004 ;30(2):80-3.
99. Camilleri J, Montesin FE, Brady K, Sweeney R, Curtis RV, Ford TR. The constitution of mineral trioxide aggregate. *Dent Mater.* 2005;21(4):297-303.
100. Camilleri J, Pitt Ford TR. Mineral trioxide aggregate: a review of the constituents and biological properties of the material. *Int Endod J.* 2006 ;39(10):747-54.
101. Parirokh M, Torabinejad M. Mineral trioxide aggregate: a comprehensive literature review—Part I: chemical, physical, and antibacterial properties. *J Endod.* 2010 ;36(1):16-27.
102. Torabinejad M, Parirokh M. Mineral trioxide aggregate: a comprehensive literature review—part II: leakage and biocompatibility investigations. *J Endod.* 2010 ;36(2):190- 202.
103. Parirokh M, Torabinejad M. Mineral trioxide aggregate: a comprehensive literature review—Part III: Clinical applications, drawbacks, and mechanism of action. *J Endod.* 2010 Mar;36(3):400-13.
104. Komabayashi T, Spångberg LS. Particle size and shape analysis of MTA finer fractions using Portland cement. *J Endod.* 2008 ;34(6):709-11.
105. Küçükkaya Eren S, Parashos P. Adaptation of mineral trioxide aggregate to dentine walls compared with other root-end filling materials: a systematic review. *Aust Endod J.* 2018 .
106. Duarte MA, Aguiar KA, Zeferino MA, Vivian RR, Ordinola-Zapata R, Tanomaru-Filho M et al. Evaluation of the propylene glycol association on some physical and chemical properties of mineral trioxide aggregate. *Int Endod J.* 2012 Jun;45(6):565-70.
107. Duarte MA, Demarchi AC, Yamashita JC, Kuga MC, Fraga SC. pH and calcium ion release of 2 root-end filling materials. *Oral Surg Oral Med Oral Pathol Oral Radiol Endod.* 2003 ;95(3):345-7.
108. Holland R, Bisco Ferreira L, de Souza V, Otoboni Filho JA, Murata SS, Dezan Junior E. Reaction of the lateral periodontium of dogs' teeth to contaminated and noncontaminated perforations filled with mineral trioxide aggregate. *J Endod.* 2007 ;33(10):1192-7.
109. Pace R, Giuliani V, Pagavino G. Mineral trioxide aggregate as repair material for furcal perforation: case series. *J Endod.* 2008 ;34(9):1130-3.
110. Banchs F, Trope M. Revascularization of immature permanent teeth with apical periodontitis: new treatment protocol? *J Endod.* 2004 ;30(4):196-200.
111. Mente J, Hage N, Pfefferle T, Koch MJ, Geletneky B, Dreyhaupt J et al. Treatment outcome of mineral trioxide aggregate: repair of root perforations. *J Endod.* 2010 ;36(2):208-13.
112. Mente J, Leo M, Panagidis D, Saure D, Pfefferle T. Treatment outcome of mineral trioxide aggregate: repair of root perforations-long-term results. *J Endod.* 2014 ;40(6):790- 6.
113. Dammaschke T, Gerth HU, Züchner H, Schäfer E. Chemical and physical surface and bulk material characterization of white ProRoot MTA and two Portland cements. *Dent Mater.* 2005 ;21(8):731-8.
114. Duarte MA, Demarchi ACO, Yamashita JC, Kuga MC, Fraga SC. Arsenic release provided by MTA and Portland cement. *Oral Surg Oral Med Oral Pathol Oral Radiol Endod.* 2005;99(5):648-50.
115. Gonçalves JL, Viapiana R, Miranda CE, Borges AH, Cruz Filho AM. Evaluation of physicochemical properties of Portland cements and MTA. *Braz Oral Res.* 2010 ;24(3):277-83
116. Weldon JK Jr, Pashley DH, Loushine RJ, Weller RN, Kimbrough WF. Sealing ability of mineral trioxide aggregate and super-EBA when used as furcation repair

- materials: a longitudinal study. *J Endod.* 2002 ;28(6):467-70.
117. Saidon J, He J, Zhu Q, Safavi K, Spångberg LS. Cell and tissue reactions to mineral trioxide aggregate and Portland cement. *Oral Surg Oral Med Oral Pathol Oral Radiol Endod.* 2003 ;95(4):483-9.
118. Bernabé PF, Gomes-Filho JE, Rocha WC, Nery MJ, OtoboniFilho JA, Dezan-Júnior E. Histological evaluation of MTA as a root-end filling material. *Int Endod J.* 2007 ;40(10):758- 65.
119. Hashem AA, Hassanien EE. ProRoot MTA, MTA-Angelus and IRM used to repair large furcation perforations: sealability study. *J Endod.* 2008 ;34(1):59-61.
120. Bortoluzzi EA, Araújo GS, Guerreiro Tanomaru JM, Tanomaru-Filho M. Marginal gingiva discoloration by gray MTA: a case report. *J Endod.* 2007 ;33(3):325-7.
121. Duarte MAH, El Kadre GDO, Vivan RR, Tanomaru JMG, Tanomaru Filho M, Moraes IG. Radiopacity of portland cement associated with different radiopacifying agents. *J Endod.* 2009 ;35(5):737-40.
122. Felman D, Parashos P. Coronal tooth discoloration and white mineral trioxide aggregate. *J Endod.* 2013 ;39(4):484-7.
123. Lenherr P, Allgayer N, Weiger R, Filippi A, Attin T, Krastl G. Tooth discoloration induced by endodontic materials: a laboratory study. *Int Endod J.* 2012 ;45(10):942-9.
124. Marciano MA, Costa RM, Camilleri J, Mondelli RF, Guimarães BM, Duarte MA. Assessment of color stability of white mineral trioxide aggregate angelus and bismuth oxide in contact with tooth structure. *J Endod.* 2014 ;40(8):1235-40.
125. Camilleri J. Color stability of white mineral trioxide aggregate in contact with hypochlorite solution. *J Endod.* 2014;40(3):436-40.
126. Marciano MA, Camilleri J, Costa RM, Matsumoto MA, Guimarães BM, Duarte MA. Zinc oxide inhibits dental discoloration caused by white mineral trioxide aggregate angelus. *J Endod.* 2017 ;43(6):1001-7.
127. Atmeh AR, Chong EZ, Richard G, Festy F, Watson TF. Dentin-cement interfacial interaction: calcium silicates and polyalkenoates. *J Dent Res.* 2012 ;91(5):454-9.
128. Butt N, Talwar S, Chaudhry S, Nawal RR, Yadav S, Bali A. Comparison of physical and mechanical properties of mineral trioxide aggregate and Biodentine. *Indian J Dent Res.* 2014 ;25(6):692-7129.
- Camilleri J. Hydration mechanisms of mineral trioxide aggregate. *Int Endod J.* 2007 ;40(6):462-70.
130. Torabinejad M, Parirokh M, Dummer PM. Mineral trioxide aggregate and other bioactive endodontic cements: an updated overview - part II: other clinical applications and complications. *Int Endod J.* 2018 ;51(3):284-317.
131. Damas BA, Wheeler MA, Bringas JS, Hoen MM. Cytotoxicity comparison of mineral trioxide aggregates and EndoSequence bioceramic root repair materials. *J Endod.* 2011 ;37(3):372-5.
132. Dawood AE, Parashos P, Wong RH, Reynolds EC, Manton DJ. Calcium silicate-based cements: composition, properties, and clinical applications. *J Investig Clin Dent.* 2017;8(2):e12195.
133. De-Deus G, Canabarro A, Alves GG, Marins JR, Linhares AB, Granjeiro JM. Cytocompatibility of the ready-to-use bioceramic putty repair cement iRoot BP Plus with primary human osteoblasts. *Int Endod J.* 2012 ;45(6):508-13.
134. Grech L, Mallia B, Camilleri J. Investigation of the physical properties of tricalcium silicate cement-based root-end filling materials. *Dent Mater.* 2013;29(2):e20-8.

135. Jang YE, Lee BN, Koh JT, Park YJ, Joo NE, Chang HS et al. Cytotoxicity and physical properties of tricalcium silicate-based endodontic materials. *Restor Dent Endod.* 2014 May;39(2):89-94. <https://doi.org/10.5395/rde.2014.39.2.89>
136. Kim JR, Nosrat A, Fouad AF. Interfacial characteristics of Biodentine and MTA with dentine in simulated body fluid. *J Dent.* 2015 ;43(2):241-7.
137. Lovato KF, Sedgley CM. Antibacterial activity of endosequence root repair material and proroot MTA against clinical isolates of *Enterococcus faecalis*. *J Endod.* 2011 Nov;37(11):1542-6.
138. Siew K, Lee AH, Cheung GS. Treatment outcome of repaired root perforation: a systematic review and meta-analysis. *J Endod.* 2015 ;41(11):1795-804.
139. Tran XV, Gorin C, Willig C, Baroukh B, Pellat B, Decup F, et al. Effect of a calcium-silicate-based restorative cement on pulp repair. *J Dent Res.* 2012 ;91(12):1166-71.
140. Wang Z. Bioceramic materials in endodontics. *Endod Topics.* 2015;32(1):3-30.
141. Zhang H, Pappen FG, Haapasalo M. Dentine enhances the antibacterial effect of mineral trioxide aggregate and bioaggregate. *J Endod.* 2009 ;35(2):221-4.
142. Candeiro GT, Correia FC, Duarte MA, RibeiroSiqueira DC, Gavini G. Evaluation of radiopacity, pH, release of calcium ions, and flow of a bioceramic root canal sealer. *J Endod.* 2012 ;38(6):842-5.
143. Saghiri MA, Gutmann JL, Orangi J, Asatourian A, Sheibani N. Radiopacifier particle size impacts the physical properties of tricalcium silicate-based cements. *J Endod.* 2015 ;41(2):225-30.
144. Camilleri J, Sorrentino F, Damidot D. Characterization of un-hydrated and hydrated BioAggregate™ and MTA Angelus™. *Clin Oral Investig.* 2015;19(3):689-98.
145. Miller AA, Takimoto K, Wealleans J, Diogenes A. Effect of 3 Bioceramic materials on stem cells of the apical papilla proliferation and differentiation using a dentin disk model. *J Endod.* 2018 Apr;44(4):599-603
146. Pontius V, Pontius O, Braun A, Frankenberger R, Roggendorf MJ. Retrospective evaluation of perforation repairs in 6 private practices. *J Endod.* 2013 ;39(11):1346-58.
147. Silva LA, Pieroni KA, Nelson-Filho P, Silva RA, HernándezGatón P, Lucisano MP et al. Furcation perforation: periradicular tissue response to Biodentine as a repair material by histopathologic and indirect immunofluorescence analyses. *J Endod.* 2017 Jul;43(7):1137-42.