

Ultrasonography role in assessment of the normal parameter of lateral cerebral ventricular atrium in the fetus

294

Papel de la ecografía en la evaluación del parámetro normal de la aurícula ventricular cerebral lateral en el feto

Nawar Alsaegh, Babylon health Directorate, Al-Hilla general teaching hospital, Radiology department, med.nawras.j@uobabylon.edu.iq <https://orcid.org/0000-0002-6120-7158>

Nawras J. Alsalihi, University of Babylon, College of medicine, physiology department. maaroonf@gmail.com <https://orcid.org/0000-0001-9040-8074>
Hassan Falah ALKhfaji*, Babylon health Directorate, Babylon teaching hospital for maternity and pediatrics, Radiology department hassanradiology@gmail.com <https://orcid.org/0000-0003-3326-1314>

Received/Recibido: 06/21/2021 Accepted/Aceptado: 08/15/2021 Published/Publicado: 09/12/2021 DOI: <http://doi.org/10.5281/zenodo.5812192>

Abstract

Objective: Presently, the usual upper limit of lateral cerebral ventricular atrium is 10 mm. and if it is more than 10mm, so it necessitate more radiological appraisal to rule out ventriculomegaly. The aim in this study is measure the mean diameter of the fetal lateral cerebral ventricular atrium during the last two trimesters through utilization of transabdominal ultrasonography in Babylon province. Method: In this perspective cross sectional study 151 fetus in their 2nd and 3rdintrautrin live were included and trans-abdominal ultrasonography was performed for all those fetuses to measure their cerebral lateral ventricular size. Results: The mean age of all participant women was 25.2 ± 5.8 years, primigravida constitute 25% of the participants women (N=37) while the multigravida pregnant ladies constitute 75% (N=114). The mean of the lateral ventricular diameter of the whole study (male and female) and in both 2nd and 3rd trimester was 7.15 ± 1.32 mm, there was significant correlation between the LV diameter and the head circumference ($r, p=0.088, 0.04$). Conclusion: Left ventricular diameter of 10mm is considered as upper limit for its normal size, any measurement more than 10 mm should be considered as alarming sign and may nesses ate further investigations.

Keywords: Ultrasonography, Lateral Cerebral Ventricular Atrium, Fetus

Resumen

Objetivo: Actualmente, el límite superior habitual de la aurícula ventricular cerebral lateral es de 10 mm. y si es superior a 10 mm, por lo que es necesaria una mayor valoración radiológica para descartar ventriculomegalia. El objetivo de este estudio es medir el diámetro medio de la aurícula ventricular cerebral lateral fetal durante los dos últimos trimestres mediante la utilización de la ecografía transabdominal en la provincia de Babilonia. Método: En este estudio transversal en perspectiva se incluyeron 151 fetos en su 2^a y 3^a intra utrina viva y se realizó una ecografía transabdominal a todos esos fetos para medir su tamaño ventricular lateral cerebral. Resultados: La edad media de todas las mujeres participantes fue de $25,2 \pm 5,8$ años, las primigrávidas constituyen el 25% de las mujeres participantes (N = 37) mientras que las mujeres embarazadas multigrávidas constituyen el 75% (N = 114). La media del diámetro ventricular lateral de todo el estudio (hombres y mujeres) y tanto en el segundo como en el tercer trimestre fue de $7.15.1.32$ mm, hubo una correlación significativa entre el diámetro del VI y la circunferencia de la cabeza ($r, p = 0.088, 0.04$). Conclusión: El diámetro del ventrículo izquierdo de 10 mm se considera como límite superior para su tamaño normal, cualquier medida superior a 10 mm debe considerarse como un signo alarmante y puede requerir más investigaciones.

Palabras clave: Ecografía, atrio ventricular cerebral lateral, feto

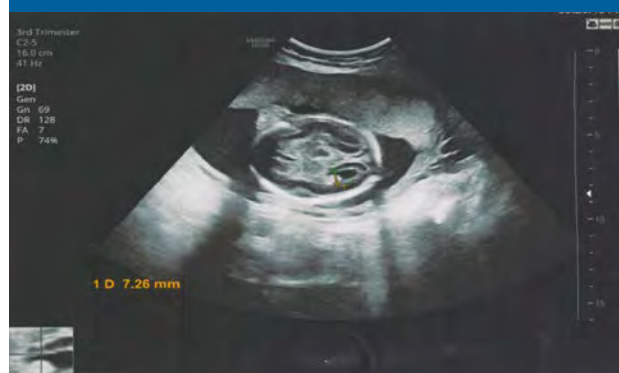Introduction

In human brain, there are two C-shaped structures named as lateral ventricles that comprise a body and atrium in addition to 3 projections that extended into the frontal, temporal, and occipital lobes, named the horns¹. The lateral ventricles start to develop after closing of the neural tube that occur in fourth week of gestation^{2,3} and they continue to expand rapidly, occupying a large majority of the cerebral hemispheres toward the end of the first trimester⁴. Lateral ventricular evolution speeds up during the second trimester, and by 21 weeks, the frontal, temporal, and occipital horns are well-defined. By 31 weeks, the lateral ventricles looks like the adult form⁵. The broadly used description of fetal ventriculomegaly is a transtrigone measurement of ≥ 10 mm at any stage of pregnancy⁶. Fetal ventriculomegaly can be a product of many underlying pathological mechanisms which include blockage of cerebrospinal fluid (CSF) tract, overproduction of CSF, absorption disorder, and inadequate brain development or destruction of brain tissues⁷, or it may be part of many congenital abnormalities that affect the central nervous system⁸. Ventriculomegaly is one of the most common abnormalities that can be detected by transabdominal sonography. Since ventriculomegaly is significantly and harmfully affects fetal prognosis, so the discovery of it is essential for both arrangement the path of delivery and neuro counseling^{9,10}. Further more, as mention previously, ventriculomegaly may be part of lot of congenital abnormalities in the fetus, so the discovery of it may open the door to discover these other abnormalities⁸. For these explanations, calculation of ventricular size has become an important part of routine prenatal sonography. The aim in this study is measure the mean diameter of the fetal lateral cerebral ventricular atrium during the last two trimesters through utilization of transabdominal ultrasonography in Babylon province.

Methods

This prospective cross sectional study was achieved in Iraq, Babylon province for 154 singleton fetuses who had no discernable anomalies during the second and third trimesters of their intrauterine lives. Ethical consent for the study was achieved from the Human Research and Ethics Committee. Detailed history was taken from the mothers regarding ages, parity and past obstetric and medical history according to well-prepared questionnaire. Mothers with diabetes mellitus, hypertension, SLE, alcoholic or with multiple pregnancy was excluded from the study. For all included women, ultrasound scan was performed and assessed by a specialist radiologist for a precision and reliability, accordingly of those 154 women, 3 were excluded from the study since that 2 of them suffering from hypertension and one woman had SLE. The scan had been performed by using a 5 MHz transducer of Samsung HS30 or HS 50 machines, BPD, HC and FL measured for each fetus and FL was used as a standard for gestational age rather than menstrual age because some pregnant were not remembered their last menstrual period, the gender is confirmed as it is considered one of a parameter in this study. The fetal head was examined in real time, the measurement is taken at an axial lateral ventricular plane level which is above a thalamic level that is used routinely to measure BPD, only a single lateral ventricular atrium is measured which is the deeper to the transducer, as the near atrium is usually obscured by reverberation artifact¹¹. The max width of atrium from its inner-to-inner margin is calculated by electronic calipers as the standard for the lateral ventricular size (figure 1). All statistical analyses were performed using SPSS version 19, Descriptive statistics were used to find the mean, standard deviation, and range of the variables. Pearson correlation coefficient was used to determine the correlation of the variables with each other and with bio-data, with P value less than 0.05 was considered to indicate a significant effect.

Figure1. Measurement the width of atrium.



The mean age of all participant women was 25.2 ± 5.8 years, and it was ranged between 17 to 42 years. Primgravid constitute 25% of the participants women (N=37) while the multigravida pregnant ladies constitute 75% (N=114). The mean of the lateral ventricular diameter of the whole study (male and female) and in both 2nd and 3rd trimester was 7.15 ± 1.32 mm, it ranged from 4.7 to 10.22 mm (Table 1).

Table 1. Demographical parameters of all participants

Parameters	Mean \pm SD	Range
Age (Years)	25.2 ± 5.8	17-42
LV diameter (mm)	7.15 ± 1.32	4.7-10.22

Number of pregnant ladies in their 2nd trimester was 99 women, where as those were in their 3rd trimester of pregnancy was 54 lady, and the mean LV cerebral diameter of their fetuses was 7.25 mm and 6.9 mm respectively, with no significant association between LV diameter and no. of trimester ($P > 0.05$) (Table 2).

Table 2. Association between trimester and LV diameter

Trimester	Number	LV Diameter Mean \pm SD	P value
2 nd	99	7.25 ± 1.30	0.16
3 rd	54	6.23 ± 1.26	

P value is significant at $p < 0.05$

Regarding the association between gender and LV diameter, there was no statistically significant association between them ($P > 0.05$), in which there was 53 female fetuses and 46 male fetuses (Table 3).

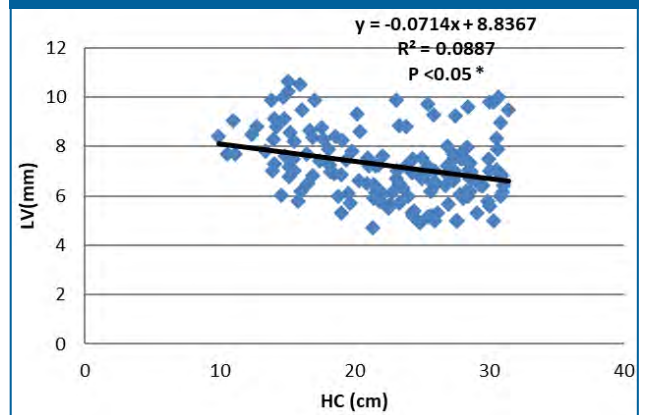
Table 3. Association between gender and the LV diameter

Gender	No. (%)	Mean \pm SD of LV diameter	P value
Female	53(34.4%)	7.098 ± 1.14	0.20
Male	46(29.8%)	7.435 ± 1.463	

P value is significant at $p < 0.05$

The mean head circumference of the fetuses was 22.7 ± 5.6 mm and there was significant correlation between the LV diameter and the head circumference ($r, p=0.088, 0.04$) (Figure 1).

Figure 1. correlation between LV diameter and head circumference



Discussion

In this prospective cross sectional study, the mean of fetal lateral ventricular diameter was 7.21 ± 1.36 mm, which is in consistency with many studies^{12,13}, in their study reported 7.6 ± 0.6 mm, and 7.7 ± 0.7 mm respectively as the mean FLVD for the population they studied. But there was dissimilarity of the value of our study with that of Dukanac et al., Bassey et al. and Udoh et al.^{14,15,16} who stated the mean LVD of their participants to be 6.6 ± 1.4 mm, 6.5 ± 1.3 mm and 6.62 ± 1.21 mm respectively. This value is lower than the value obtained in our study. Previously, many studies suggest 11mm¹⁷ and 12mm¹⁸ as upper limit for normal FLVD, overall in our study and in our Iraqi population 10 mm FLVD is considered the upper normal limit. Regarding to gender, in this study there was no significant association between gender and the width of cerebral fetal lateral ventricle, this finding had similarity with that of Udoh¹⁶ but this is dissimilar to the finding of Godfrey et al.¹⁹ who stated that male had larger LV diameter than female, we can explain that during this intrauterine period the sex hormones are not so effective as during maturity.

The association between trimester of pregnancy or gestational age and the FLVD is not significant in our study, and this is similar to the results of Udoh¹⁶. The lateral ventricular atrium diameter should remain less than 10 mm throughout gestation²⁰. This is very reasonable because if the size of lateral ventricles dramatically increase throughout pregnancy, the diagnosis of hydrocephalus could be not easy⁸ since that the cases of hydrocephalus is generally diagnosed during intrauterine life by the measurement of the fetal lateral ventricular diameter. Significant correlation was found between fetal head circumference with LV diameter, this finding is similar to that of Udoh¹⁶, though fetal cerebral hemispheres have linear relationship with gestation age, and the lateral ventricles occupy large areas of the fetal head.

Left ventricular diameter of 10mm is considered as upper limit for its normal size, any measurement more than 10 mm should be considered as alarming sign and may required further investigations.

References

1. Stratchko L, Filatova I, Agarwal A, et al. The ventricular system of the brain: anatomy and normal variations. 2016;37:72–83 .
2. Sadler TW. Langman's Medical Embryology. Baltimore: Lippincott Williams & Wilkins; 2012:287–308
3. O'Rahilly R, Müller F. Human Embryology & Teratology. New York: Wiley-Liss, 2001, 405–29
4. Lowery LA and Sive H. Totally tubular: the mystery behind function and origin of the brain ventricular system. 2009; 31:446–58.
5. Zhao SX, Xiao YH, Lv FR, Zhang ZW, Sheng B, Ma HL. Lateral ventricular volume measurement by 3D MR hydrography in fetal ventriculomegaly and normal lateral ventricles. J Magn Reson Imaging. 2018 Jul;48(1):266-273.
6. Carta S, Kaelin Agten A, Belcaro C, Bhide A. Outcome of fetuses with prenatal diagnosis of isolated severe bilateral ventriculomegaly: systematic review and meta-analysis. Ultrasound Obstet Gynecol. 2018 Aug;52(2):165-173.
7. Gilmore JH, Smith LC, Wolfe HM, et al. Prenatal mild ventriculomegaly predicts abnormal development of the neonatal brain. Biol Psychiatry. 2008;64(12):1069-1076.
8. Udoh BE, Ugwu AC, Ali AM, Chiegwu HU, Eze JC, Ulu UO. Sonographic assessment of normal fetal cerebral lateral ventricular diameter at different gestational ages among fetuses in Southern Nigeria. CHRISMED J Health Res 2019;6:172-5
9. Gaglioti P, Oberto M, Todros T. The significance of fetal ventriculomegaly: etiology, short- and long-term outcomes. Prenat Diagn. 2009 Apr;29(4):381-8.
10. Griffiths PD, Reeves MJ, Morris JE, Mason G, Russell SA, Paley MN, Whitby EH. A prospective study of fetuses with isolated ventriculomegaly investigated by antenatal sonography and in utero MR imaging. AJNR Am J Neuroradiol. 2010 Jan;31(1):106-11.
11. Sanders, R. & Hall-Terracciano B. Clinical Sonography- A Practical Guide (Fifth Edition); Wolters Kluwer; 2016, P302.
12. Li H, Liang H, Wu H. Magnetic resonance imaging based correlation analysis between calcarine sulcus development and isolated fetal ventriculomegaly. Congenit Anom (Kyoto). 2017 Mar;57(2):52-56.
13. VanHaltren, K., Bethune, M., Curcio, F., Lombardo, P. & Schneider-Kolsky, M. E. Routine sonographic measurement of the near-field lateral ventricle during second-trimester morphologic scans. Journal of Ultrasound in Medicine 2013, 32, 1587–1592.
14. Dukanac Stamenkovic J, Steric M, Srbinovic L, Janjic T, Vrzic Petronijevic S, Petronijevic M, Cetkovic A. Fetal ventriculomegalies during pregnancy course, outcome, and psychomotor development of born children. Clin Exp Obstet Gynecol. 2016;43(1):63-9.
15. Bassey OS, Agunloye AM, Adeyinka AO, Bassey EO, Lawson L, Roberts OA, et al. Ultrasound reference range for diameters of posterior atrium of lateral ventricles for Normal Nigerian foetuses, at the university college hospital (UCH) Ibadan, Nigeria: A cross – Sectional study. Br J Med Med Res 2014;4:3208-19.
16. Udoh B E, Ugwu AC, Ali AM, Chiegwu HU, Eze JC, UluUO, Sonographic assessment of normal fetal cerebral lateral ventricular diameter at different gestational ages among fetuses in Southern Nigeria (2019),6:3;172-175.
17. Society for Maternal-Fetal Medicine (SMFM). Electronic address: pubs@smfm.org, Fox NS, Monteagudo A, Kuller JA, Craigo S, Norton ME. Mild fetal ventriculomegaly: diagnosis, evaluation, and management. Am J Obstet Gynecol. 2018 Jul;219(1):B2-B9.
18. Ipek A, Sayit AT, Idilman IS, Kurt A, Cay N, Unal O, Karabulut E, Keskin HL, Karaoglanoglu M. Choroid plexus separation in fetuses without ventriculomegaly: Natural course and postnatal outcome. J Clin Ultrasound. 2015 Oct;43(8):478-84.
19. Godfrey ME, Friedman KG, Drogosz M, Rudolph AM, Tworetzky W. Cardiac output and blood flow redistribution in fetuses with D-loop transposition of the great arteries and intact ventricular septum: insights into pathophysiology. Ultrasound Obstet Gynecol. 2017 Nov;50(5):612-617.
20. Goynumner G, Yayla M, Arisoy R, Turkmen O. The criterion value of fetal cerebral lateral ventricular atrium width for diagnosis of ventriculomegaly. Clin Exp Obstet Gynecol. 2014;41(1):67-71.