



CODEN [USA]: IAJPBB

ISSN : 2349-7750

**INDO AMERICAN JOURNAL OF
PHARMACEUTICAL SCIENCES**

SJIF Impact Factor: 7.187

Available online at: <http://www.iajps.com>

Research Article

**ENTERIC DUPLICATION CYST; A UNIQUE CLINICAL
PRESENTATION IN AN ADULT FEMALE****Fedaa Abdulwahab¹, Suhair Al Saad², Khalid Al-Sindi^{1*}, Hamdi Al Shinawi³
and Dina Al Sibaie⁴, Mohammed Qamber⁵**

¹Department of Pathology, King Hamad University Hospital, Bahrain., ²Assistant Professor & Consultant General & laparoscopic Surgeon, Bahrain., ³Department of General Surgeon, Arabian Gulf University, Bahrain., ⁴Department of General Surgeon, Al Salam Specialist Hospital, Bahrain., ⁵Department of Radiation Oncology, King Hamad University Hospital, Bahrain.

Article Received: October 2021 **Accepted:** November 2021 **Published:** December 2021**Abstract:**

Enteric Duplication Cysts (EDC) are rare congenital malformations, can occur in any part of the gastrointestinal tract and share the muscular wall as well as the common mesenteric vascular supply of the hosting segment. EDC usually become apparent in early childhood but rarely encountered in adults. These malformations can be asymptomatic; however, in adults can be troublesome and associated with several symptomatic complications. In this paper, we report a unique case of a huge ruptured right paracolic duplication cyst in a 32-year-old female who presented with a chief complaint of a right sided abdominal pain and severe constipation. Based upon computed tomography, a Para-colonic duplication cyst of the right colon was tentatively diagnosed. The cyst which appeared non-communicating to the hosting colonic segment was resected laparoscopically, however, shortly afterward; the patient developed a caecal perforation indicating a limited right hemicolectomy. After case discussion, a dedicated part of literature review is also covered.

Keywords: Enteric; Duplication; Cyst; Colon; Symptomatic; Complications; Adult patients**Corresponding author:****Fedaa Abdulwahab**

Department of Pathology, King Hamad University Hospital, Bahrain.

QR code



Please cite this article in press Fedaa Abdulwahab et al, *Enteric Duplication Cyst; A Unique Clinical Presentation In An Adult Female.*, Indo Am. J. P. Sci, 2021; 08(12).

INTRODUCTION:

Enteric duplication cysts are uncommon congenital malformations that can occur at any part along the gastrointestinal tract, from the mouth to the anus, but most commonly found within the mesenteric side of the small bowel. It is usually lined by an epithelium resembling the affected part of the gastrointestinal tract. [1] In 70% of the cases, the lesions are typically present in infancy or early childhood, nevertheless, rarely found in older patients.[2,3] The frequency of EDCs is about 2-fold higher in women, and they do not tend to run in families.[4] Colonic Duplication Cysts (CDCs) represent 6.8% of all reported EDCs.[5] These duplication cysts usually contain the typical layers of the bowel wall; i.e., mucosa, submucosa, and muscularis propria. However, if CDCs present with secondary complications that may alter their mural structures, at least part of the muscular layer and a lining epithelium are needed to confirm their nature by histomorphologic evaluation. CDCs with secondary complications can also suffer variable fibrosis, inflammation, lymphoid aggregates, necrosis, and calcification.[6] Therefore, it should be minded that some cysts may lack a well-structured layered wall due to such changes due to degeneration or involution.[7] Clinically, CDCs may be asymptomatic incidental findings or present with acute abdomen, intestinal obstruction, and/or bleeding per rectum.[8] Malignant changes have been reported in 67% of CDCs,

therefore, surgical resection is recommended once diagnosed, even in asymptomatic patients.

CASE PRESENTATION:

A 32-year-old married woman with 4 children presented with a 5-year history of localized, intermittent right sided, dull aching abdominal pain and chronic constipation. This patient was diagnosed 3 years ago with a congenital right paracolic duplication cyst, advised surgery by the operating surgeon; however, she denied this recommendation and lost to follow up. In June 2021, she came back requesting, surgical resection. At that time, the abdominal pain was more frequent with fullness after meals, beside a noticeable reduced appetite and weight loss. Likewise, the constipation became worse. It was about one bowel movement per week. She dined any associated vomiting, bleeding per rectum or any significant medical or surgical past history. Her family history included a breast cancer in her mother, otherwise no similar disease. On general physical examination, she was pale with apparent cachexia. Abdominal examination revealed a large, well defined, mobile right sided intra-abdominal mass, (Figure 1) extending from right iliac fossa upwards, approximately measured 20 cm x 15 cm. Abdominopelvic CT scan revealed a 15 cm x15 cm (non-communicating) right paracolic duplication cyst with what could be filled with blood content. (Figure 2)

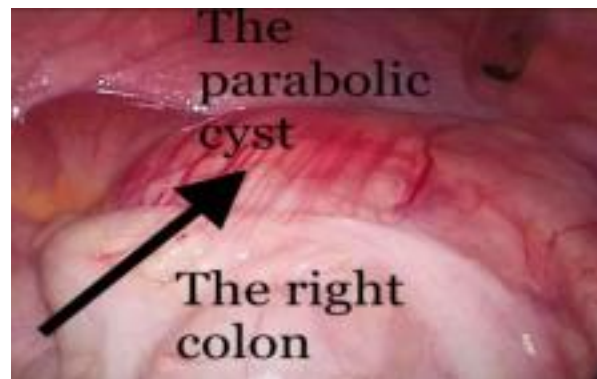

Figure 1: The laparoscopic photo showing the huge right para-colic cyst attached to right colon and both are covered by thin mesentery.

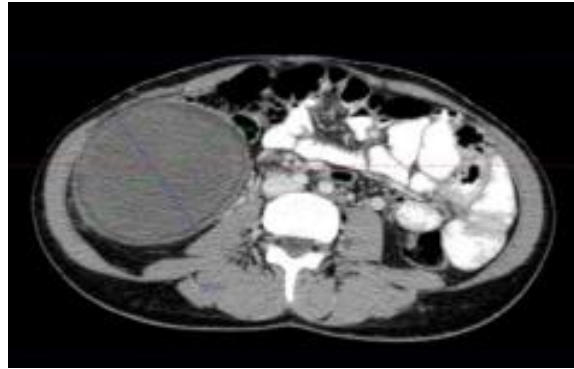


Figure 2: A huge right paracolic cyst, non-communicating (15 x 15 cm²) pushing the right colon to midline.

The decision was to proceed for a diagnostic laparoscopy, aspiration of the cyst followed by its resection. The Laparoscopic exploration indeed, revealed a huge right iliac fossa thin cyst, pushing the right colon almost to the midline. Aspiration attempt was halt; firstly, as the cyst wall was too thin and secondly, it was not containing any kind of fluids but rather a thick cottage cheese-like content. Laparoscopic dissection and excision of the right paracolic duplication cyst (with the content) was performed. The appendix was simultaneously removed as it was in close contact with the cyst wall and became congested during dissection. The resected

cyst and appendectomy were both sent for histopathological evaluation. The gross examination of the right paracolic cyst (Figure 3) which was received partially opened revealed a 95 x 80 x 75 mm greyish tan cyst with mural thickness ranging from 1 mm to 9 mm. The external surface of the cyst was tannish white and included foci of marked congestion and haemorrhage. The inner surface was rough and congested. A 115 x 110 x 35 aggregate, about 85 grams of tannish soft necrotic cyst content was also included. The Appendix appeared normal, measured 45 x 8 mm, and received with a 45 x 15 x 15 mm of attached mesoappendix.

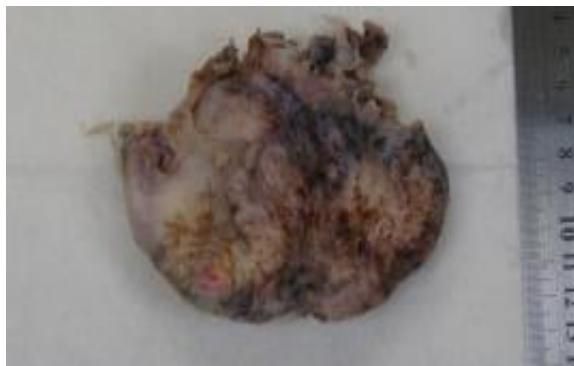

Figure 3: Macroscopic appearance of the paracolic duplication cyst.

The microscopic findings of the right paracolic cyst revealed a unilocular cavity, and though mostly formed by a dense chronic sub-serosal fibro-inflammatory tissue reaction, yet the presence of a well-developed mural muscular layer was evident along with residual foci of intestinal-type lining epithelium confirming its nature as a duplication cyst. (Figure 4) The cyst wall lining mucosa and submucosa were mostly destroyed by marked ischemic necrosis

and largely replaced by a secondary chronic fibroinflammatory tissue reaction which was partly granulomatous. The latter findings were substantiated by the presence of intense vascular engorgement, stromal haemorrhage, loose foreign body (faecal) material with epithelioid histiocytic reaction and giant cell response. Part of the abovedescribed granulomatous process within the markedly thin attenuated cyst wall were clearly perforating and

spilling over into the peri-cystic necrotic mesenteric fat due to focal rupture. (Figures 5) No ectopic gastric or pancreatic tissue is present and neither dysplasia nor neoplasia seen. The Appendix revealed only minor

distal fibrosis, that in part may represent also a localized ischemic insult.

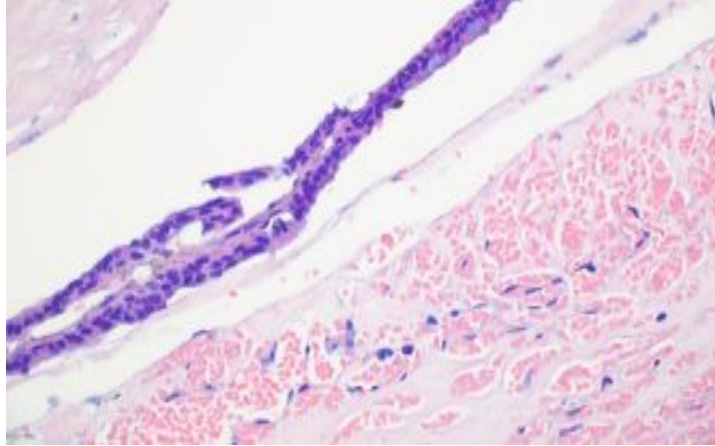


Figure 4: Enteric duplication cyst lined by intestinal type epithelium with Goblet cells. (H&E stained- MPF).

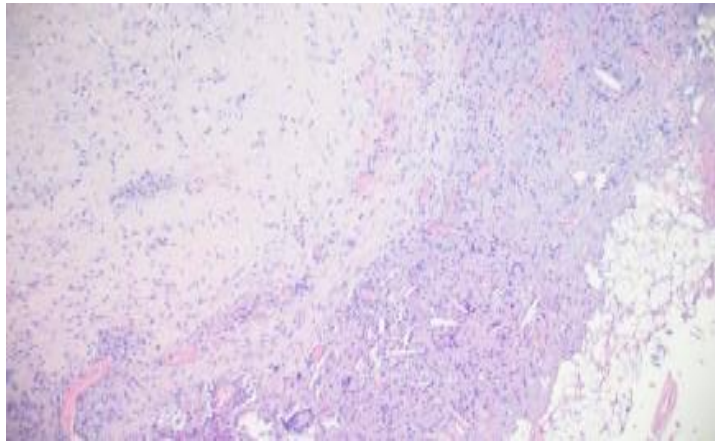


Figure 5: Enteric duplication cyst wall formed by dense fibrosis and granulomatous inflammation at the site of perforation. (H&E stained-MPF).

Post operatively, the first day was uneventful; the patient had good bowel sounds but drained more than 500 ml of serosanguinous over 24 hrs. The next day, patient started vomiting and developed abdominal distension, while her drains collected a greenish fluid. A Suspected right colon perforation was confirmed shortly by a contrast abdominopelvic CT scan. The bowel perforation was within the posterioinferior part of the right cecum. The patient underwent exploratory

laparotomy, peritoneal wash and limited right hemicolectomy with ileostomy. Pathology Examination confirm the presence of an acute ischemic perforation. The patient progressed well postoperatively and a closure of ileostomy was performed after 6 weeks. After two months follow up, she was well and gained weight about 5 kg. (Figures 6-8)

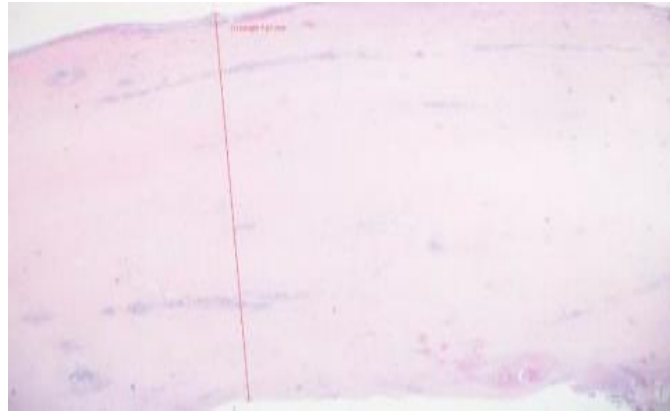


Figure 6: Enteric duplication cyst with thin (0.67 mm) mural segment (H&E stained-LPF)



Figure 7: Enteric duplication cyst with thick fibrous wall and retained attenuated muscular coat (H&E stained-LPF).

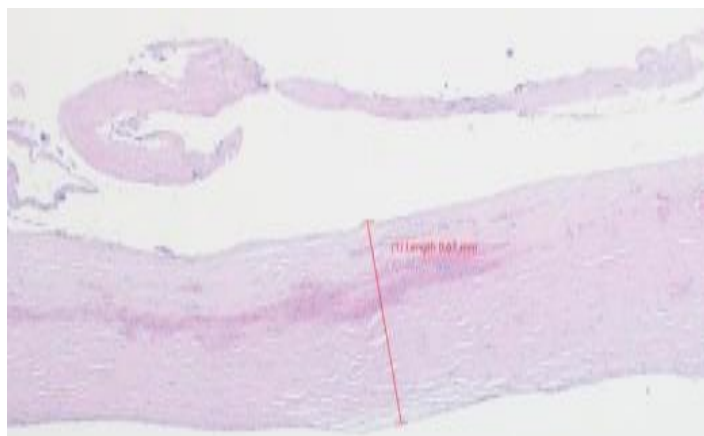


Figure 8: Enteric duplication cyst with thick fibrous wall and retained attenuated muscular coat (IHC -SMA stained-LPF).

DISCUSSION:

Rare cases of EDCs were reported since first described by Wendel in 1911. [4,9,10] The etiology for such lesions is not clear, however, it was hypothesized their origin as persistent fetal enteric diverticula or due failure of intestinal recanalization because of intrauterine vascular occlusion.[11] Two major forms of EDCs are known; a rare tubular form and a most common cystic form.[12] EDCs whether cystic, spherical, or a tubular form are hollow, epitheliumlined structures, that are adherent to the wall of the gastrointestinal tract, often sharing the serosa and supplied by common mesenteric blood vessels. EDCs can be recognized on C.T. scan as smoothly rounded, fluid-filled cysts, or tubular structures with thin, slightly enhancing walls in or adjacent to the wall of part of the alimentary tract. [9] There is no worldwide accepted therapeutic protocol for EDCs. Surgical excision is advised for asymptomatic cases or when complications occur; currently, there is no agreement on the management of asymptomatic cases.[4] In our reported case, the patient had a symptomatic duplication cyst, needed surgical excision but patient waited for 4 years to agree for resection. Though isolated surgical removal of the cyst alone is possible in rare cases when it has an independent blood supply, however, in general, resection of the cyst along with the adjacent bowel is recommended in continuity in a good number of cases due to the usual shared muscular wall and blood supply. [10] Irrespective of the EDCs being communicating or non-communication, clinically, such lesions are commonly found within the ileocecal region in 35% of cases. If left unresected, several complications may happen, such as, volvulus, intussusception, bleeding, inflammatory mass formation with or without subsequent bowel obstruction from adjacent pressure or mass effect. Perforation (as in this case), fistula formation and not to be mentioned the risk of malignant transformation which usually carry a bad prognosis due to delayed diagnosed at advanced stages with distant metastases. [13] Lastly, another point of importance to be minded, as EDCs might also present as multiple concurrent cysts in 10% to 15% of cases, so the managing team should be aware of this scenario![14]

CONCLUSION:

Enteric duplication cysts are uncommon congenital lesions in adults. These cysts are mostly asymptomatic, however, in our case which was already a late intervention for a histologically proved focally perforated Cyst. Earlier intervention and resection are mandatory, and the following take home messages must be considered; firstly, the main overt

two reasons for a brisk medical interference in our case were the relatively big size of the lesion which carry a higher chance of frank rupture, secondly, the chronicity increases the risk of malignant transformation. Finally, as most of these EDCs are right paracolic, and depending on their anatomical location and vascular supply, it is mostly advised to resect them from the outset along with the affected bowel segment in proximity due to the common shared mural and vascular supply. The rare cases thought of having independent vascular supply may also benefit from limited right hemicolectomy combined with cyst resection from the first attempt. This would avoid secondary complications and the need for another surgery.

REFERENCES:

1. Zahir S, Yusaf F, Zada M, Asif N, Akhtar, Abbasi MZ. Duplication cyst in a new born. *Int J Pathol.* 2010; 8(2):84-6.
2. Tong SC, Pitman M, Anupindi SD. Best cases from the AFIP: ileocecal enteric duplication cyst: radiologicpathologic correlation. *Radiographics.* 2002;22(5):1217-22.
3. Choi SO, Park WH, Kim SP. Enteric duplications in children-an analysis of 6 cases. *J Korean Med Sci.* 1993;8(6):482-7.
4. Ríos SS, Noia JL, Nallib IA, et al. Adult gastric duplication cyst: diagnosis by endoscopic ultrasoundguided fine-needle aspiration (EUS-FNA). *Rev Esp Enferm Dig.* 2008;100(9):586-90.
5. Puligandla PS, Nguyen LT, St-Vil D, Flageole H, Bensoussan AL, Nguyen VH, Laberge. Gastrointestinal duplications. *JM J Pediatr Surg.* 2003;38(5):740-4.
6. Mourra N, Chafai N, Bessoud B, Reveri V, Werbrouck A, Tiret E. Colorectal duplication in adults: report of seven cases and review of the literature. *J Clin Pathol.* 2010;63(12):1080-3.
7. Spottswood SE. Peristalsis in duplication cyst: a new diagnostic sonographic finding. *Pediatr Radiol.* 1994; 24(5):344-5.
8. Reiser-Erkan C, Erkan M, Ulbrich E, Nährig J, Kleeff J. Cystic colon duplication causing intussusception in a 25-year-old man: report of a case and review of the literature. *BMC Surg.* 201;10:19.
9. Kim SK, Lim HK, Lee SJ, Park CK. Completely isolated enteric duplication cyst: case report. *Abdominal Imaging.* 2003;28(1):12-4.
10. Srivastava P, Gangopadhyay AN, Kumar V, Upadhyaya VD, Sharma SP, Jaiman RP, et al. Noncommunicating isolated enteric duplication cyst in childhood. *J Pediatr Surg.* 2009;44(7):e9-e10.

11. Choi SO, Park WH, Kim SP. Enteric duplications in children-an analysis of 6 cases. *J Korean Med Sci.* 1993;8(6):482-7.
12. Blank G, Konigsrainer A, Sipos B, Ladurner R. Adenocarcinoma arising in a cystic duplication of the small bowel: case report and review of literature. *World J Surg Oncol.* 2012;10.
13. Jessica Leigh Baumann, Charmi Patel. Enteric duplication cyst containing squamous and respiratory epithelium: an interesting case of a typically pediatric entity presenting in an adult patient. *Case Rep Gastrointest Med.* 2014;2014:790326.
14. Dombale V, Patil BV, Kadam SA, Kerudi BH. Enteric duplication cyst of caecum presenting with intestinal obstruction-a case report. *J Krishna Institute of Med Sci University.* 2012;1(2):147-9.